

## **BOVINE TUBERCULOSIS IN FREE-RANGING CARNIVORES FROM MICHIGAN**

Authors: Colleen S. Bruning-Fann, Stephen M. Schmitt, Scott D. Fitzgerald, Jean S. Fierke, Paul D. Friedrich, et. al.

Source: Journal of Wildlife Diseases, 37(1) : 58-64

Published By: Wildlife Disease Association

URL: <https://doi.org/10.7589/0090-3558-37.1.58>

---

BioOne Complete ([complete.BioOne.org](https://complete.BioOne.org)) is a full-text database of 200 subscribed and open-access titles in the biological, ecological, and environmental sciences published by nonprofit societies, associations, museums, institutions, and presses.

Your use of this PDF, the BioOne Complete website, and all posted and associated content indicates your acceptance of BioOne's Terms of Use, available at [www.bioone.org/terms-of-use](http://www.bioone.org/terms-of-use).

Usage of BioOne Complete content is strictly limited to personal, educational, and non-commercial use. Commercial inquiries or rights and permissions requests should be directed to the individual publisher as copyright holder.

---

BioOne sees sustainable scholarly publishing as an inherently collaborative enterprise connecting authors, nonprofit publishers, academic institutions, research libraries, and research funders in the common goal of maximizing access to critical research.

## BOVINE TUBERCULOSIS IN FREE-RANGING CARNIVORES FROM MICHIGAN

Colleen S. Bruning-Fann,<sup>1,8</sup> Stephen M. Schmitt,<sup>2</sup> Scott D. Fitzgerald,<sup>3</sup> Jean S. Fierke,<sup>2</sup> Paul D. Friedrich,<sup>2</sup> John B. Kaneene,<sup>4</sup> Kathy A. Clarke,<sup>3</sup> Kelly L. Butler,<sup>3</sup> Janet B. Payeur,<sup>5</sup> Diana L. Whipple,<sup>6</sup> Thomas M. Cooley,<sup>2</sup> Janice M. Miller,<sup>6</sup> and Darian P. Muzo<sup>7</sup>

<sup>1</sup> Veterinary Services, Animal and Plant Health Inspection Service, United States Department of Agriculture, East Lansing, Michigan 48823, USA

<sup>2</sup> Wildlife Disease Laboratory, Rose Lake Wildlife Research Station, Michigan Department of Natural Resources, East Lansing, Michigan 48823, USA

<sup>3</sup> Animal Health Diagnostic Laboratory and Department of Pathology, College of Veterinary Medicine, Michigan State University, East Lansing, Michigan 48824, USA

<sup>4</sup> Population Medicine Center, College of Veterinary Medicine, Michigan State University, East Lansing, Michigan 48824, USA

<sup>5</sup> National Veterinary Services Laboratories, United States Department of Agriculture, Ames, Iowa 50010, USA

<sup>6</sup> Agricultural Research Service, United States Department of Agriculture, Ames, Iowa 50010, USA

<sup>7</sup> Department of Fisheries and Wildlife, College of Agriculture and Natural Resources, Michigan State University, East Lansing, Michigan 48824, USA

<sup>8</sup> Corresponding author (email: colleen.s.bruning-fann@usda.gov)

**ABSTRACT:** During a survey of carnivores and omnivores for bovine tuberculosis conducted in Michigan (USA) since 1996, *Mycobacterium bovis* was cultured from lymph nodes pooled from six coyotes (*Canis latrans*) (four adult female, two adult male), two adult male raccoons (*Procyon lotor*), one adult male red fox (*Vulpes vulpes*), and one 1.5-yr-old male black bear (*Ursus americanus*). One adult, male bobcat (*Felis rufus*) with histologic lesions suggestive of tuberculosis was negative on culture but positive for organisms belonging to the *Mycobacterium tuberculosis* complex when tested by polymerase chain reaction. All the tuberculous animals were taken from three adjoining counties where *M. bovis* is known to be endemic in the free-ranging white-tailed deer (*Odocoileus virginianus*) population. There were two coyotes, one raccoon, one red fox, and one bobcat infected in Alpena county. Montmorency County had two coyotes and one raccoon with *M. bovis*. Two coyotes and a bear were infected from Alcona County. These free-ranging carnivores/omnivores probably became infected with *M. bovis* through consumption of tuberculous deer. Other species included in the survey were opossum (*Didelphis virginiana*), gray fox (*Urocyon cinereoargenteus*), and badger (*Taxidea taxus*); these were negative for *M. bovis*.

**Key words:** Coyote (*Canis latrans*), raccoon (*Procyon lotor*), black bear (*Ursus americanus*), bobcat (*Felis rufus*), red fox (*Vulpes vulpes*), *Mycobacterium bovis*, survey, tuberculosis.

### INTRODUCTION

Bovine tuberculosis caused by *Mycobacterium bovis* is endemic in free-ranging white-tailed deer (*Odocoileus virginianus*) in five counties (Alcona, Alpena, Montmorency, Oscoda, and Presque Isle) in the northeastern Lower Peninsula of Michigan (USA) (Schmitt et al., 1997). Since 1996, a survey of free-ranging carnivores and omnivores for tuberculosis has been in progress and results were reported previously (Bruning-Fann et al., 1998). Of the 62 animals reported in 1998 (15 coyotes, 28 raccoons, 11 opossums, five foxes, two badgers, and one bobcat), *M. bovis* was cultured from three coyotes (*Canis latrans*) that were normal in appearance on both gross and histological examination.

This report provides an update of this project. Three factors provided the impetus for examining free-ranging carnivores and omnivores for tuberculosis in northeastern Michigan First was the implication of non-ruminant wildlife as a reservoir of tuberculosis in New Zealand (de Lisle, 1993), Great Britain (Clifton-Hadley, 1996), and Ireland (Collins et al., 1994). Second, the wide host range of *M. bovis* (Francis, 1958). Third, the presence of endemic tuberculosis in free-ranging deer in northeastern Michigan (Schmitt et al., 1997).

### MATERIALS AND METHODS

Wildlife included in this on-going study were those carnivorous and omnivorous mammalian species present in the tuberculosis endemic area whose population density was sufficient to

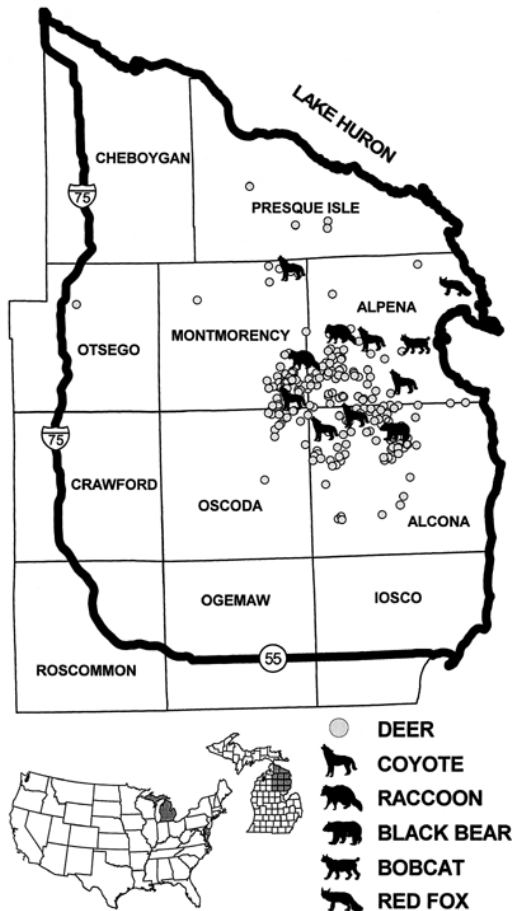


FIGURE 1. Location of *Mycobacterium bovis* infected carnivores and white-tailed deer in Michigan, 1999.

allow collection. Coyote, bobcat (*Felis rufus*), raccoon (*Procyon lotor*), black bear (*Ursus americanus*), red fox (*Vulpes vulpes*), gray fox (*Urocyon cinereoargenteus*), opossum (*Didelphis virginiana*), and badger (*Taxidea taxus*) were surveyed.

The area from which omnivores and carnivores were collected increased since last reported (Bruning-Fann et al., 1998) and included the five tuberculosis endemic counties (Alpena, Alcona, Montmorency, Oscoda, and Presque Isle) and a boundary area surrounding these endemic counties (Fig. 1). The boundary area was defined by two major roadways (I-75 and M-55) and contained approximately one half of each of the counties (Cheboygan, Otsego, Crawford, Roscommon, Ogemaw, and Iosco) that border the endemic counties. The Michigan Department of Natural Resources (MDNR, Lansing, Michigan, USA) recorded

the location where each animal was hunted, trapped, or found dead. The age of the coyotes, bobcats, raccoons, red foxes, gray foxes, opossums, and badgers were categorized as adult or juvenile based on the presence of adult or juvenile dentition (Bookhout, 1994). The bear was aged by cementum annuli analysis (Stoneberg and Jonkel, 1966; Friedrich et al., 1990).

Carcasses of carnivores and omnivores (except for black bears) were necropsied at Michigan State University (MSU, East Lansing, Michigan, USA). Visible lesions and the parotid, mandibular, medial retropharyngeal, bronchial, mediastinal, and mesenteric lymph nodes were collected for histologic examination and mycobacterial culture. Lymph nodes (pooled from each animal) were cultured for mycobacteria. A thorough description of sample collection, processing, examination, and culture has been reported (Bruning-Fann et al., 1998). Black bear heads were obtained from taxidermists, and the parotid, mandibular, and medial retropharyngeal lymph nodes were collected by MSU Fisheries and Wildlife students. Processing, examination and culturing of these tissues was the same as for the other species surveyed. We were unable to examine bear viscera because the carcasses were eviscerated by hunters in the field. A polymerase chain reaction (PCR) test for identification of *Mycobacterium tuberculosis* complex organisms in formalin-fixed, paraffin-embedded tissue was performed as described previously (Miller et al., 1997) on tissue from the bobcat.

## RESULTS

From the start of the survey until June 1999, 294 carcasses were collected and examined grossly for tuberculosis (Table 1). Gross lesions suspicious of tuberculosis were seen in two coyotes (both culture positive), and one adult male bobcat (culture negative, PCR positive) (Table 2). Not all animals obtained in the survey were examined histologically and tissues cultured for mycobacteria due to a variety of reasons. Of the 270 animals examined histologically (106 coyotes, 54 opossums, 52 raccoons, 42 black bears, five red foxes, one gray fox, two badgers, and eight bobcats), seven had microscopic lesions suggestive of tuberculosis (Table 2). Mycobacterial cultures were performed on tissues from 266 animals (106 coyotes, 54 opossums, 48 raccoons, 42 black bears, five red

TABLE 1. Species, sex, and age of carnivores and omnivores surveyed for tuberculosis in Michigan, 1996–99.

| Species    | Female |          |         | Male  |          |         | Sex/Age | Totals |
|------------|--------|----------|---------|-------|----------|---------|---------|--------|
|            | Adult  | Juvenile | Unknown | Adult | Juvenile | Unknown | Unknown |        |
| Badger     | —      | —        | —       | 3     | 1        | —       | —       | 4      |
| Black bear | —      | —        | 14      | —     | —        | 23      | 5       | 42     |
| Bobcat     | 4      | 1        | —       | 3     | —        | —       | —       | 8      |
| Coyote     | 61     | 3        | —       | 44    | 1        | —       | 1       | 110    |
| Gray fox   | 1      | —        | —       | —     | —        | —       | —       | 1      |
| Opossum    | 12     | 3        | —       | 37    | 7        | —       | —       | 59     |
| Raccoon    | 18     | 4        | —       | 39    | 2        | —       | 1       | 64     |
| Red fox    | 2      | —        | —       | 1     | 3        | —       | —       | 6      |
| Total      |        |          |         |       |          |         |         | 294    |

foxes, one gray fox, two badgers, and eight bobcats).

*Mycobacterium bovis* was cultured from six coyotes (four adult females [three previously reported], two adult males), two adult male raccoons, one adult male red fox, and one 1.5-yr-old male black bear (Table 2). The tuberculous animals were taken from three adjoining counties in northeastern Michigan (Fig. 1). Tuberculous animals in Alpena county included two coyotes, one raccoon, one red fox, and

one bobcat. Montmorency county had two coyotes, and one raccoon. Two coyotes and a bear from Alcona county were tuberculous.

Of the six coyotes from which *M. bovis* was cultured, histologic lesions suggestive of tuberculosis were seen in two coyotes. One adult male coyote (C65) had numerous 2 to 3 mm firm, white nodules that were raised above the surface of the lung. The mesenteric lymph nodes were enlarged with gritty, white mottling. Follicle-

TABLE 2. Summary of gross and histologic examination and mycobacterial culture of tuberculosis confirmed and suspicious cases in carnivores and omnivores surveyed in Michigan 1996–99.

| Species             | Identification | Gross lesions    | Histologic lesions | <i>M. bovis</i> cultured | Location             |
|---------------------|----------------|------------------|--------------------|--------------------------|----------------------|
| Black bear          | 3570           | —                | —                  | +                        | USA 44°48'N, 83°37'W |
| Bobcat              | 4987           | + <sup>b</sup>   | + <sup>b,f</sup>   | – <sup>g</sup>           | USA 45°00'N, 83°30'W |
| Coyote <sup>h</sup> | C45            | —                | —                  | +                        | USA 44°50'N, 83°44'W |
| Coyote              | C51            | —                | + <sup>b,e</sup>   | —                        | USA 44°45'N, 83°33'W |
| Coyote <sup>h</sup> | C58            | —                | —                  | +                        | USA 44°53'N, 83°56'W |
| Coyote <sup>h</sup> | C61            | —                | —                  | +                        | USA 44°48'N, 83°50'W |
| Coyote              | C65            | + <sup>b,d</sup> | + <sup>d,e</sup>   | +                        | USA 45°11'N, 83°56'W |
| Coyote              | C88            | —                | + <sup>b,f</sup>   | —                        | USA 45°27'N, 84°06'W |
| Coyote              | C100           | + <sup>b</sup>   | —                  | +                        | USA 44°55'N, 83°35'W |
| Coyote              | 31555          | —                | + <sup>b,f</sup>   | +                        | USA 45°00'N, 83°40'W |
| Raccoon             | C81            | —                | + <sup>a,e</sup>   | —                        | USA 44°55'N, 84°00'W |
| Raccoon             | C83            | —                | —                  | +                        | USA 45°01'N, 83°47'W |
| Raccoon             | C119           | —                | + <sup>c,f</sup>   | +                        | USA 44°58'N, 83°54'W |
| Red fox             | 4997           | —                | —                  | +                        | USA 45°07'N, 83°24'W |

<sup>a</sup> Thoracic lymph nodes.

<sup>b</sup> Mesenteric lymph nodes.

<sup>c</sup> Cranial lymph nodes.

<sup>d</sup> Lungs.

<sup>e</sup> Histologic lesion suggestive of TB without acid-fast bacilli.

<sup>f</sup> Histologic lesion suggestive of TB with acid-fast bacilli seen.

<sup>g</sup> Positive for *M. tuberculosis* complex by PCR examination of paraffin tissue sections.

<sup>h</sup> Previously reported.

ular hyperplasia with multiple granulomas, composed primarily of macrophages and lymphocytes, were seen histologically. Although, no acid-fast bacilli were seen, *M. bovis* was cultured from these tissues. An adult female coyote (31555) had no gross lesions, but histologically a mesenteric lymph node contained a single, large focus of partially mineralized necrotic debris. Low numbers of acid-fast bacilli were observed adjacent to the area of mineralization, and *M. bovis* was cultured from this animal. *Mycobacterium bovis* was also cultured from an adult male coyote (C100), which had markedly enlarged pale mesenteric lymph nodes, but only lymphoid hyperplasia was observed histologically. As previously reported, *M. bovis* was cultured from coyotes C45, C58, and C61 which had no gross or histologic lesions of tuberculosis (Bruning-Fann et al., 1998).

Two additional coyotes were suspicious of tuberculosis. Although no gross lesions were seen in these adult female coyotes, histologic lesions suggestive of tuberculosis were found. The mesenteric lymph nodes of coyote C51 contained multiple necrotic foci, which were partially mineralized but acid-fast organisms were not observed. Coyote C88 had several lymph nodes containing multiple caseogranulomas with central areas of partially mineralized necrotic debris. Moderate numbers of acid-fast bacilli were present in the central debris. Mycobacteria were not isolated from the tissues of either coyote. The cause of the lesions in these coyotes could not be determined as no tissue remained for testing by PCR.

Three raccoons showed evidence of tuberculosis. One raccoon (C119) had both histologic lesions and was positive for *M. bovis* on culture. Although presented in a state of advanced decomposition and lacking abdominal viscera, low numbers of acid-fast bacilli were seen in necrotic foci contained within the cranial lymph nodes of this adult male raccoon. No inflammatory cells were associated with the necrotic foci. An adult female raccoon (C81) had

no gross lesions, but a tracheobronchial lymph node contained caseogranulomas composed of a central area of necrotic debris with partial mineralization. No organisms were seen on acid-fast staining, no mycobacteria were isolated, and no tissue remained for testing by PCR. Raccoon C83 had no gross or histologic lesions suggestive of tuberculosis, but *M. bovis* was isolated from this adult male.

One adult, female bobcat (4987) had enlarged mesenteric lymph nodes (2 cm diameter) with numerous pale, tan nodules (2 mm diameter) on gross examination. Histopathologic examination revealed multifocal caseogranulomas with partially mineralized necrotic debris in the centers, surrounded by lymphocytes and macrophages. Moderate numbers of acid-fast bacilli were present in the necrotic debris. No mycobacteria were isolated from these tissues. However, a PCR test on DNA extracted from paraffin sections of the tissues detected the presence of bacteria belonging to the *M. tuberculosis* complex, a group of organism that includes *M. bovis* (J. M. Miller, pers. comm.).

*Mycobacterium bovis* was isolated from an adult male red fox (4997) and a male, 1.5-yr-old black bear (3570). No gross or histologic lesions were observed in either of these animals. All opossums and badgers were grossly and histologically normal and mycobacteria were not isolated from any of these animals.

#### DISCUSSION

Although bovine tuberculosis has been reported in a wide variety of animals (Francis, 1958), this report provides the first documentation of this disease in two species. This is the first report of bovine tuberculosis in a bobcat. This finding was not unexpected as *M. bovis* has been reported in other felids: leopards (*Panthera uncia* and *Panthera pardus*) (Thorel et al., 1998), lions (*Panthera leo*) (Keet et al., 1996), a cheetah (*Acinonyx jubatus*) (Keet et al., 1996), a tiger (*Panthera tigris*) (Lumeij et al., 1987), and domestic cats (Isaac

et al., 1983). This is also the first report of *M. bovis* in free-ranging raccoons. Bovine tuberculosis has been reported in coatis (*Nasua narica*) (Fox, 1923) which, like raccoons, are members of the family Procyonidae. In addition, this is the first report of gross and histologic lesions suggestive of tuberculosis in coyotes, although *M. bovis* has previously been cultured from this species (Rhyan et al., 1995; Bruning-Fann et al., 1998).

The lack of gross or histologic lesions in the culture positive red fox found in this survey is similar to a previous report where *M. bovis* was cultured from a fox without lesions in England (Little et al., 1982). Tuberculosis has been found in bear, although the report furnished few details as to species or extent of lesions (Fox, 1923). Had all bear tissues been available for examination and culture, it is possible that bovine tuberculosis would have been cultured from additional bears or that lesions could have been observed.

Restriction fragment length polymorphism (RFLP) analysis has been completed for the *M. bovis* isolates from five of the six coyotes, the two raccoons, and the bear. These RFLP patterns were identical to the predominant RFLP pattern seen in *M. bovis* isolated from free-ranging white-tailed deer taken from the five counties where tuberculosis is endemic (D. L. Whipple, pers. comm.). The similarity in RFLP patterns between the *M. bovis* isolates from these carnivores/omnivores and free-ranging deer, and the close geographical proximity of the cases, provides strong evidence of a link between the cases (Fig. 1).

The finding that most of the lesions seen grossly and histologically in the *M. bovis* culture positive coyotes and PCR positive bobcat occurred in the mesenteric lymph nodes suggests exposure by ingestion. Several reports of *M. bovis* infection in carnivores have been attributed to the consumption of tuberculous meat (Francis, 1958; Isaac et al., 1983; Little et al., 1982). In view of this evidence, the most likely

source of infection for these carnivores/omnivores was through the consumption of tuberculous white-tailed deer.

The number, extent and distribution of tuberculous lesions in an infected animal provides an indication of that species' ability to act as a reservoir host since successful disease transmission requires excretion of the infectious agent from the host. While most mammalian species are susceptible to bovine tuberculosis (Francis 1958), only a few non-ruminant species are thought to be reservoirs of *M. bovis*. Brushtail possums (*Trichosurus vulpecula*) and ferrets (*Mustela furo*) in New Zealand (Patterson et al., 1995; Sauter and Morris, 1995) and European badgers (*Meles meles*) in England and Ireland (Nolan and Wilesmith, 1994; O'Reilly and Daborn, 1995) are believed to be reservoir hosts for bovine tuberculosis. These species develop extensive lesions containing tremendous numbers of bacilli. Excretion of *M. bovis* has been demonstrated from these species (Gallagher et al., 1976; Jackson et al., 1995; Morris et al., 1994; Nolan and Wilesmith, 1994; Ragg et al., 1995). Thus far, disseminated lesions with high numbers of bacilli have not been found associated with the native Michigan carnivores or omnivores. The number of tuberculous carnivores and omnivores, the variety of species involved, and the geographic spacing between the cases is more indicative of disease spillover from the free-ranging deer reservoir to these wildlife species rather than endemic tuberculosis in these the carnivores and omnivores. Although it is currently thought that no wildlife other than white-tailed deer serve as a reservoir for tuberculosis in Michigan, continued and expanded wildlife surveys and experimental inoculation studies are in progress.

#### ACKNOWLEDGEMENTS

We thank N. H. Lehman and R. L. Lyon for technical assistance with RFLP analysis, S. Winterstein for the collection of bear tissues, the MDNR, MSU, and USDA personnel who helped with the carnivore/omnivore survey, and the hunters/trappers who participated in the

surveys. This work was funded in part by grant #85295-26490 and the Federal Aid in Wildlife Restoration Act under Michigan Pittman-Robertson Project W-127-R.

#### LITERATURE CITED

- BOOKHOUT, T. A. (EDITOR). 1994. Research and management techniques for wildlife and habitats. United States Fish and Wildlife Service, Bethesda, Maryland, 740 pp.
- BRUNING-FANN, C. S., S. M. SCHMITT, S. D. FITZGERALD, J. B. PAYEUR, D. L. WHIPPLE, T. M. COOLEY, T. CARLSON, AND P. FRIEDRICH. 1998. *Mycobacterium bovis* in coyotes in Michigan. *Journal of Wildlife Diseases* 34: 632–636.
- CLIFTON-HADLEY, R. S. 1996. Badgers, bovine tuberculosis and the age of reason. *British Veterinary Journal* 152: 243–246.
- COLLINS, D. M., G. W. DE LISLE, J. D. COLLINS, AND E. COSTELLO. 1994. DNA restriction fragment typing of *Mycobacterium bovis* isolates from cattle and badgers in Ireland. *The Veterinary Record* 134: 681–682.
- DE LISLE, G. W., K. CREWS, J. DE ZWART, R. JACKSON, G. J. E. KNOWLES, K. D. PATERSON, R. W. MACKENZIE, K. A. WALDRUP, AND R. WALKER. 1993. *Mycobacterium bovis* infections in wild ferrets. *New Zealand Veterinary Journal* 41: 148–149.
- FOX, H. 1923. Disease in captive wild mammals and birds. J. B. Lippincott Company, Philadelphia, Pennsylvania, 665 pp.
- FRANCIS, J. 1958. Tuberculosis in animals and man. Cassell and Company, London, UK, 357 pp.
- FRIEDRICH, P. D., K. L. JACKSON, AND S. M. SCHMITT. 1990. Comparison of two methods for black bear age determination from premolar tooth cementum annuli. Michigan Department of Natural Resources Wildlife Division Report No. 3122. Rose Saha Research Center, East Lansing, Michigan, 5 pp.
- GALLAGHER, J., R. H. MUIRHEAD, AND K. J. BURN. 1976. Tuberculosis in wild badgers (*Meles meles*) in Gloucestershire: Pathology. *Veterinary Record* 98: 9–14.
- ISAAC, J., J. WHITEHEAD, J. W. ADAMS, M. D. BARTON, AND P. COLOE. 1983. An outbreak of *Mycobacterium bovis* infection in cats in an animal house. *Australian Veterinary Journal* 60: 243–245.
- JACKSON, R., M. M. COOKE, J. D. COLEMAN, AND R. S. MORRIS. 1995. Naturally occurring tuberculosis caused by *Mycobacterium bovis* in brushtail possums (*Trichosurus vulpecula*): I. An epidemiological analysis of lesion distribution. *New Zealand Veterinary Journal* 43: 306–314.
- KEET, D. F., N. P. KRIEK, M. L. PENRITH, A. MICHEL, AND H. HUCHZERMAYER. 1996. Tuberculosis in buffaloes (*Syncerus caffer*) in the Kruger National Park: Spread of the disease to other species. *Onderstepoort Journal of Veterinary Research* 63: 239–244.
- LITTLE, T. W. A., C. SWAN, H. V. THOMPSON, AND J. W. WILESMITH. 1982. Bovine tuberculosis in domestic and wild mammals in an area of Dorset. III. The prevalence of tuberculosis in mammals other than badgers and cattle. *Journal of Hygiene* 89: 225–234.
- LUMEIJ, J. T., R. HAJER, K. J. DIK, G. M. DORRESTEIN, AND H. W. ENGEL. 1987. Diagnosis of pulmonary *Mycobacterium bovis* infection in a tiger. *Veterinary Record* 120: 302–304.
- MILLER, J., A. JENNY, J. RHYAN, D. SAARI, AND D. SUAREZ. 1997. Detection of *Mycobacterium bovis* in formalin-fixed, paraffin-embedded tissues of cattle and elk by PCR amplification of an IS6110 sequence specific for *Mycobacterium tuberculosis* complex organisms. *Journal of Veterinary Diagnostic Investigation* 9: 244–249.
- MORRIS, R. S., D. U. PFEIFFER, AND R. JACKSON. 1994. The epidemiology of *Mycobacterium bovis* infections. *Veterinary Microbiology* 40: 153–177.
- NOLAN, A., AND J. W. WILESMITH. 1994. Tuberculosis in badgers (*Meles meles*). *Veterinary Microbiology* 40: 179–191.
- O'REILLEY, L. M., AND C. J. DABORN. 1995. The epidemiology of *Mycobacterium bovis* infections in animals and man—a review. *Tubercle and Lung Disease*. 76(S1): 1–46.
- PATTERSON, B. M., R. S. MORRIS, J. WESTON, AND P. E. COWAN. 1995. Foraging and denning patterns of brushtail possums, and their possible relationship to contact with cattle and the transmission of bovine tuberculosis. *New Zealand Veterinary Journal* 43: 281–288.
- RAGG, J. R., K. A. WALDRUP, AND H. MOLLER. 1995. The distribution of gross lesions of tuberculosis caused by *Mycobacterium bovis* in feral ferrets (*Mustela furo*) from Otago, New Zealand. *New Zealand Veterinary Journal* 43: 338–341.
- RHYAN, J. C., K. AUNE, R. CLARKE, R. MEYER, C. SIROKY, AND L. STACKHOUSE. 1995a. Discovery of bovine tuberculosis in free-ranging mule deer and results of continued wildlife surveillance in the area. In *Proceedings of the Veterinary Epidemiology and Economics Symposium*, United States Department of Agriculture, Animal and Plant Health Inspection Service, Centers for Epidemiology and Animal Health, Fort Collins, Colorado, pp. 1B2–1B4.
- SAUTER, C. M., AND R. S. MORRIS. 1995. Behavioral studies on the potential for direct transmission of tuberculosis from feral ferrets (*Mustela furo*) and possums (*Trichosurus vulpecula*) to farm livestock. *New Zealand Veterinary Journal* 43: 294–300.
- SCHMITT, S. M., S. D. FITZGERALD, T. M. COOLEY, C. S. BRUNING-FANN, L. SULLIVAN, D. BERRY, T. CARLSON, R. B. MINNIS, J. B. PAYEUR, AND J.

- SIKARSKIE. 1997. Bovine tuberculosis in free-ranging white-tailed deer in Michigan. *Journal of Wildlife Diseases* 33: 749–758.
- STONEBURG, R. P., AND C. J. JONKEL. 1966. Age determination of black bears by cementum layers. *The Journal of Wildlife Management* 30: 411–414.
- THOREL, M. F., C. KAROUI, A. VARNEROT, C. FLEURY, AND V. VINCENT. 1998. Isolation of *Mycobacterium bovis* from baboons, leopards and a sea-lion. *Veterinary Research* 29: 207–212.
- WHIPPLE, D. L., P. R. CLARKE, J. L. JARNAGIN, AND J. B. PAYEUR. 1997. Restriction fragment length polymorphism analysis of *Mycobacterium bovis* isolates from captive and free-ranging animals. *Journal of Veterinary Diagnostic Investigation* 9: 381–386.

*Received for publication 18 October 1999.*