



Adenocarcinoma of the Small Intestine in a Ringed Seal from Hudson Bay

Authors: Mikaelian, Igor, Leclair, Daniel, and Inukpuk, Joanassie

Source: Journal of Wildlife Diseases, 37(2) : 379-382

Published By: Wildlife Disease Association

URL: <https://doi.org/10.7589/0090-3558-37.2.379>

BioOne Complete (complete.BioOne.org) is a full-text database of 200 subscribed and open-access titles in the biological, ecological, and environmental sciences published by nonprofit societies, associations, museums, institutions, and presses.

Your use of this PDF, the BioOne Complete website, and all posted and associated content indicates your acceptance of BioOne's Terms of Use, available at www.bioone.org/terms-of-use.

Usage of BioOne Complete content is strictly limited to personal, educational, and non - commercial use. Commercial inquiries or rights and permissions requests should be directed to the individual publisher as copyright holder.

BioOne sees sustainable scholarly publishing as an inherently collaborative enterprise connecting authors, nonprofit publishers, academic institutions, research libraries, and research funders in the common goal of maximizing access to critical research.

Adenocarcinoma of the Small Intestine in a Ringed Seal from Hudson Bay

Igor Mikaelian,^{1,4} Daniel Leclair,² and Joanassie Inukpuk^{3,1} Canadian Cooperative Wildlife Health Centre and Centre Québécois sur la Santé des Animaux Sauvages, 3200 Sicotte, C.P. 5000, Saint-Hyacinthe, Quebec, J2S 7C6, Canada; ² Nunavik Research Centre, Makivik Corporation, P.O. Box 179, Kuujuaq, Quebec, J0M 1C0, Canada (danleclair@sympatico.ca); ³ General Delivery, Umiujaq, Quebec, J0M 1Y0, Canada; ⁴ Present address: Idexx Veterinary Services, 2825 KOVR Drive, West-Sacramento, California 95605, USA (e-mail: Igor-Mikaelian@Idexx.com).

ABSTRACT: Nineteen wild ringed seals (*Phoca hispida*) were killed in winter 1999 to assess the health status of seals harvested in eastern Hudson Bay (Quebec, Canada). One of these seals, an 11-yr-old male, had a poorly differentiated adenocarcinoma that severely constricted the lumen of the distal small intestine. The tumor was characterized by proliferation of polygonal epithelial cells that formed closely packed acini and cords. This appears to be the first reported case of adenocarcinoma of the small intestine in Pinnipedia.

Key words: Adenocarcinoma, case report, *Phoca hispida*, ringed seal, small intestine.

Upon the request of the Corporation of the Northern Village of Umiujaq, (Quebec, Canada) a survey was undertaken in winter 1999 to assess the health status of ringed seal population. In agreement with the local hunters association, 20 seals were harvested in open water areas. A local seal hunter (J.I.) was trained to collect major organs for histopathological and microbiological analyzes, and to recognize common gross abnormalities. The study started in January 1999 and ended in February 1999. Nineteen ringed seals (*Phoca hispida*) and one bearded seal (*Erignathus barbatus*) were killed and inspected. A case of intestinal adenocarcinoma found in one ringed seal is described herein.

An intestinal mass was noted on initial sampling in a male ringed seal. The animal was 11-yr-old as determined by counting the annual dentine annuli of a thin section of a lower canine (Smith, 1973). The animal was old compared to the mean age (5.8 yr) of seals harvested from Umiujaq (D. Leclair, pers. observ.), although ringed seals can live to 43 yr of age (Banfield, 1981). Standard length (SL; 122 cm) and blubber thickness (BT; 4 cm) were mea-

sured, and body condition (BC) was calculated (BT^2/SL) (American Society of Mammalogists, 1967). BC was 0.13 and comparable to other seals previously captured at the same site (D. Leclair, pers. obs.), which indicates that fat reserves of the animal were not depleted.

The intestinal mass was sent on ice from Umiujaq to Nunavik Research Centre (Makivik Corporation, Kuujuaq, Quebec, Canada) for further examination. The other organs of this animal were macroscopically unremarkable and were fixed routinely in 10% buffered formalin. The mass was located in the tunica muscularis of the distal portion of the small intestine. The distance from the pylorus to the mass could not be measured because some sections of the intestine had not been collected. The tumor measured 4 cm in diameter, was nodular, bulged over the serosal surface of the intestine, and caused severe segmental reduction of the intestinal lumen. On cross section, it was composed of a 1 to 12 mm incomplete rim of whitish friable tissue that surrounded sero-hemorrhagic fluid (Fig. 1). Sections of the tumor and of the intestinal tract were fixed in 10% neutral buffered formalin. Formalin fixed tissues were embedded in paraffin, sectioned at 5 μ m, and stained with hematoxylin-phloxine-saffron (Prophet et al., 1994). Subsequent sections of the tumor were stained with Prussian blue (for iron), periodic acid-Schiff (PAS, for neutral mucosubstances) and Grimelius (for cells of the neuroendocrine system) stains (Prophet et al., 1994). Serial sections of the tumor were immunostained for reactivity to cytokeratin (mouse monoclonal

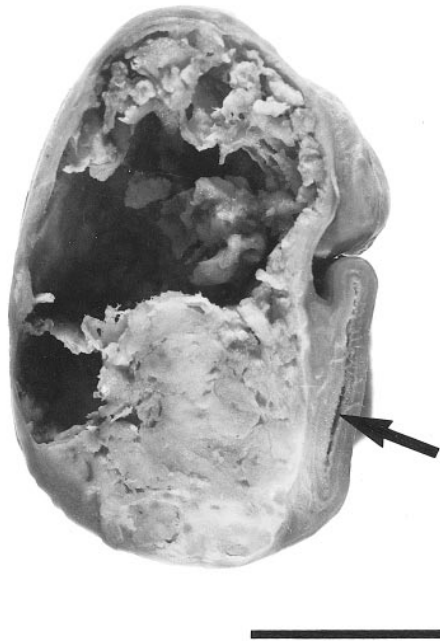


FIGURE 1. Transverse section of formalin-fixed intestinal adenocarcinoma in a ringed seal (*Phoca hispida*) from Hudson Bay. Necrotic tissues at the center of the tumor have been removed. The lumen of the intestine (arrow) is severely constricted. Bar = 1.5 cm.

antibody to human AE-1, working solution; Biomedica, Foster City, California, USA), vimentin (mouse monoclonal antibody to human vimentin, 1:100; Biogenex, San Ramon, California, USA) and leukocyte common antigen (mouse monoclonal antibody to human, working solution; Immunon, Pittsburgh, Pennsylvania, USA) antisera by the avidin-biotin-peroxidase complex method (Haines et al., 1991).

Microscopic examination was hampered by the poor preservation of the tissue. However, the intestinal mass was composed of closely packed acini, cords and individual cells separated by a scant amount of fibrovascular stroma (Fig. 2). Clusters of neoplastic cells were found in lymphatic vessels at the edges of the tumor as well as invading the intestinal wall down to the subserosa. Neoplastic cells were

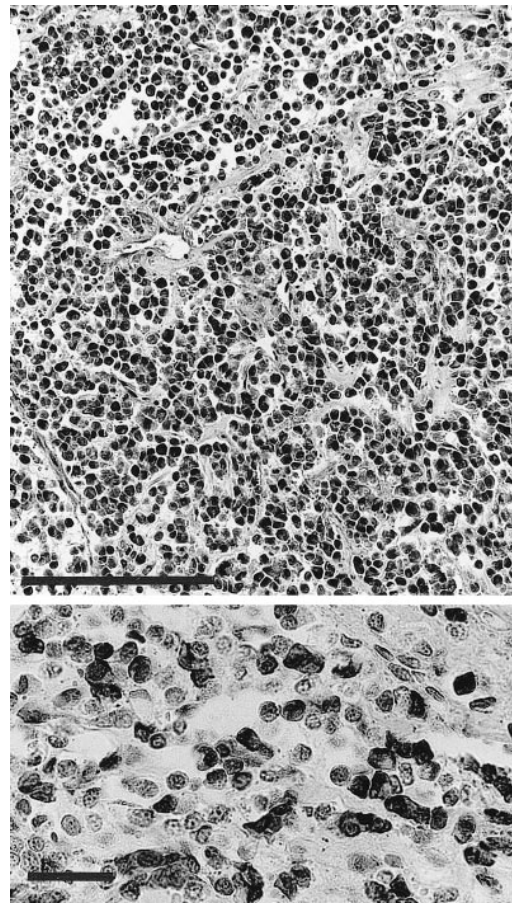


FIGURE 2. Histological section of a poorly differentiated adenocarcinoma in a ringed seal (*Phoca hispida*). The tumor is composed of ill-defined nests and cords of polygonal cells separated by a scant amount of stroma. Bar = 300 μ m. Inset: about 50% cells show strong cytoplasmic staining for cytokeratin. Avidin-biotin-peroxidase complex technique, hematoxylin counterstain. Bar = 50 μ m.

large, polygonal, with distinct cell borders and an abundant amount of delicately granular acidophilic cytoplasm that did not stain with a Grimelius stain. A few cells had a single large optically empty PAS-negative vacuole which displaced the nucleus, conferring a signet ring appearance to the cell. The nucleus of neoplastic cells was eccentric, with a contoured membrane and coarsely clumped chromatin. Nuclear pleomorphism and anisokaryosis were prominent and mitoses were numerous, averaging four mitoses per high power

field ($\times 400$). Approximately 50% neoplastic cells stained positive to cytokeratine (Fig. 2, inset). Neoplastic cells were uniformly negative to vimentin and to leukocyte common antigen. The center of the tumor was necrotic. Microscopic metastases in distant organs were not found.

Based on light microscopic and immunohistochemical examination, this tumor was diagnosed as a poorly differentiated intestinal adenocarcinoma. Histologic sections of the tumor were deposited in the Registry of Veterinary Pathology (Armed Forces Institute of Pathology, Washington DC, USA; accession number 2674668 00).

Adenocarcinomas of the small intestine are rare in man and in most animal species, with the notable exception of sheep and cattle in some parts of the world, and beluga whales (*Delphinapterus leucas*) from the St. Lawrence estuary. The present report appears to be the first epithelial tumor of the small intestine described in a pinniped. This type of tumor has been associated with the ingestion of herbicides in sheep (Newell et al., 1984), ingestion of bracken fern and papillomavirus infection in cattle (Jarrett et al., 1978), and possibly with environmental contamination in beluga whales (De Guise et al., 1995).

Seals from Hudson Bay live in a relatively pristine environment compared to marine mammals from temperate climate environments: tissue concentrations of major organochlorinated compounds in Arctic marine mammals are about 10 to 50 times less than those of ecologically comparable marine mammals from more industrialized shores of North America and Europe (Muir et al., 1990; Norstrom et al., 1990, 1994). Therefore, environmental contamination is an unlikely cause for the tumor herein described.

Although papillomaviruses are not thought to play a major role in the etiology of epithelial tumors of the small intestine in man (zur Hausen, 1996), a bovine papillomavirus has been causally associated with these tumors in cattle exposed to bracken fern (Jarrett et al., 1978). The pre-

sent tumor was not tested for the presence of papillomaviruses.

In the recent years, the number of tumors reported in marine mammals has sharply increased (Gerber et al., 1993; De Guise et al., 1994; Gulland et al., 1996; Bossart et al., 1997). This increased reporting may reflect a real increase in tumor prevalence, or may be partly explained by the increased number of animals being examined by veterinary pathologists. The observation of an adenocarcinoma in one of 19 apparently healthy ringed seals from Hudson Bay highlights the need to explore the actual prevalence of neoplasia in marine mammal species from ecosystems with low levels of environmental contaminants.

LITERATURE CITED

- AMERICAN SOCIETY OF MAMMALOGISTS. 1967. Standard measurements of seals. *The Journal of Mammalogy* 48: 459–462.
- BANFIELD, A. W. F. The mammals of Canada. 1981. National Museum of Natural Sciences, National Museum of Canada: Toronto, Ontario, Canada, 438 pp.
- BOSSART, G. D., R. Y. EWING, A. J. HERRON, C. CRAY, B. MASE, S. J. DECKER, J. W. ALEXANDER, AND N. H. ALTMAN. 1997. Immunoblastic malignant lymphoma in dolphins: histologic, ultrastructural, and immunohistochemical features. *Journal of Veterinary Diagnostic Investigation* 9: 454–458.
- DE GUISE, S., A. LAGACÉ, AND P. BÉLAND. 1994. Tumors in St. Lawrence beluga whales (*Delphinapterus leucas*). *Veterinary Pathology* 31: 444–449.
- , D. MARTINEAU, P. BÉLAND, AND M. FOURNIER. 1995. Possible mechanisms of action of environmental contaminants on St. Lawrence beluga whales (*Delphinapterus leucas*). *Environmental Health Perspectives* 103: 73–77.
- GERBER, J. A., J. ROLETT, L. E. MORGAN, D. W. SMITH, AND L. J. GAGE. 1993. Findings in pinnipeds stranded along the central and northern California coast, 1984–1990. *Journal of Wildlife Diseases* 29: 423–433.
- GULLAND, F. M. D., J. G. TRUPKIEWICZ, T. R. SPRAKER, AND L. J. LOWENSTINE. 1996. Metastatic carcinoma of probable transitional cell origin in 66 free-living California sea lions (*Zalophus californianus*), 1979 to 1994. *Journal of Wildlife Diseases* 32: 250–258.
- HAINES, D. M., AND B. J. CHELACK. 1991. Technical considerations for developing enzyme immunohistochemical staining procedures on formalin-

- fixed paraffin-embedded tissues for diagnostic pathology. *Journal of Veterinary Diagnostic Investigation* 3: 101–112.
- JARRETT, W. F. H., P. E. MCNEIL, W. T. R. GRIMSHAW, I. E. SELDMAN, AND W. I. M. MCINTYRE. 1978. High incidence areas of cattle cancer with a possible interaction between an environmental carcinogen and a papilloma virus. *Nature* 274: 215–217.
- MUIR, D. C. G., C. A. FORD, R. E. A. STEWART, T. G. SMITH, R. F. ADDISON, M. E. ZINCK, AND P. BÉLAND. 1990. Organochlorine contaminants in belugas, *Delphinapterus leucas*, from Canadian waters. *Canadian Journal of Fisheries and Aquatic Sciences* 224: 165–190.
- NEWELL, K. W., A. D. ROSS, AND R. M. RENNER. 1984. Phenoxy and picolinic acid herbicides and small-intestinal adenocarcinoma in sheep. *Lancet* 1301–1305.
- NORSTROM, R. J., AND D. C. G. MUIR. 1994. Chlorinated hydrocarbon contaminants in arctic marine mammals. *The Science of the Total Environment* 154: 107–128.
- , M. SIMON, AND D. C. G. MUIR. 1990. Polychlorinated dibenzo-*p*-dioxins and dibenzofurans in marine mammals from the Canadian North. *Environmental Pollution* 66: 1–19.
- PROPHET, E. B., B. MILLS, J. B. ARRINGTON, AND L. H. SOBIN. 1994. *Laboratory Methods in Histotechnology*. American Registry of Pathology, Washington, D.C., 279 pp.
- SMITH, T. G. 1973. Ringed seals in James Bay and Hudson Bay: population estimates and catch statistics. *Arctic* 28: 170–182.
- ZUR HAUSEN, H. 1996. Papillomavirus infection - a major cause of human cancers. *Biochimica and Biophysica Acta* 1288: F55–F78.

Received for publication 19 July 1999