



## **Trombiculiasis in the Florida Black Bear**

Authors: Cunningham, Mark W., Phillips, Lynette A., and Welbourn, Cal

Source: Journal of Wildlife Diseases, 37(3) : 634-639

Published By: Wildlife Disease Association

URL: <https://doi.org/10.7589/0090-3558-37.3.634>

---

BioOne Complete ([complete.BioOne.org](https://complete.BioOne.org)) is a full-text database of 200 subscribed and open-access titles in the biological, ecological, and environmental sciences published by nonprofit societies, associations, museums, institutions, and presses.

Your use of this PDF, the BioOne Complete website, and all posted and associated content indicates your acceptance of BioOne's Terms of Use, available at [www.bioone.org/terms-of-use](https://www.bioone.org/terms-of-use).

Usage of BioOne Complete content is strictly limited to personal, educational, and non - commercial use. Commercial inquiries or rights and permissions requests should be directed to the individual publisher as copyright holder.

---

BioOne sees sustainable scholarly publishing as an inherently collaborative enterprise connecting authors, nonprofit publishers, academic institutions, research libraries, and research funders in the common goal of maximizing access to critical research.

## Trombiculiasis in the Florida Black Bear

Mark W. Cunningham,<sup>1,2,5</sup> Lynette A. Phillips,<sup>1,3</sup> and Cal Welbourn<sup>4</sup> <sup>1</sup> Department of Pathobiology, College of Veterinary Medicine, University of Florida, Gainesville, Florida 32611, USA; <sup>2</sup> Florida Fish and Wildlife Conservation Commission, 4005 South Main Street, Gainesville, Florida 32601, USA; <sup>3</sup> Current address: Department of Pathobiological Sciences, School of Veterinary Medicine, University of Wisconsin, Madison, Wisconsin 53706, USA; <sup>4</sup> Division of Plant Industry, Bureau of Entomology, Plant Pathology, and Nematology, Gainesville, Florida 32614, USA; <sup>5</sup> Corresponding author (e-mail: cunninm@fwc.state.fl.us).

**ABSTRACT:** We found trombiculid mite (Trombiculidae) infestations in 32 of 101 (32%) free-ranging Florida black bears (*Ursus americanus floridanus*) live-captured or necropsied in Florida from January 1999 to April 2000. Prevalence of chigger infestation was greatest in June with no infestations seen October to March. Chigger infestations were recognized as accumulations of bright orange granular material usually associated with hair shafts. Mites were found in clusters of one to 102 (mean  $\pm$  SD =  $8.5 \pm 19.5$ ) and were distributed primarily over the ventral abdomen and thorax, inguinal and axillary regions, and proximal medial aspect of the extremities. Mites were identified as larval *Eutrombicula splendens*. Cutaneous lesions were seen in two of 32 (6%) infested bears.

**Key words:** Black bear, chigger, dermatitis, *Eutrombicula splendens*, Trombiculidae, trombiculiasis, *Ursus americanus floridanus*.

Trombiculiasis is the infestation of a host by larval mites (Chiggers) of the family Trombiculidae. Trombiculid mite infestations are usually nonspecific and have been reported in a variety of vertebrate hosts. In Florida (USA) chigger infestation has been observed in several mammals including the mountain lion (also known as the Florida panther; *Puma concolor*), bobcat (*Felis rufus*), raccoon (*Procyon lotor*), Virginia opossum (*Didelphis virginiana*), deer, lagomorphs, and rodents (reviewed by Forrester, 1992). Little et al. (1997) reported dermatitis secondary to trombiculid mite infestation in white-tailed deer (*Odocoileus virginianus*) from Georgia (USA). To our knowledge there has been no previously published report of chigger infestation in black bears (*Ursus americanus*). The objectives of this study were to determine the prevalence and describe the gross and histologic changes associated with trombiculiasis in the Florida black bear (*U. americanus floridanus*).

We examined 101 (44 females, 57 males) black bears on 109 occasions. Black bears were live-captured using spring-activated Aldrich leg-hold snares ( $n = 55$  captures of 52 bears) (Johnson and Pelton, 1980), darted and immobilized while free-ranging ( $n = 10$  captures of 7 bears), or handled without anesthesia (neonatal cubs,  $n = 24$ ). Two females were captured once each in snares and again while free-ranging. Live-captured bears were immobilized with tiletamine hydrochloride and zolazepam hydrochloride (Telazol®, Fort Dodge Laboratories, Inc., Fort Dodge, Iowa, USA) at a dosage of approximately 4.5 mg/kg. Dose was based on estimated weight and was administered via a 3 ml dart from a CO<sub>2</sub> powered Telinject® pistol (Telinject USA, 9316 Soledad Canyon Rd, Saugus, California, USA). Bears were captured as part of several ecological studies of the black bear in Florida (Maehr et al., 1999; Florida Fish and Wildlife Conservation Commission, unpubl. data). Necropsied bears died from vehicular collision ( $n = 18$ ), capture-related injury ( $n = 1$ ), or unknown causes ( $n = 1$ ) and were collected opportunistically. Mean ( $\pm$  SD) age of all bears examined, based on examination of cementum annuli ( $n = 30$ ) (Willey, 1974) or tooth wear/replacement ( $n = 71$ ), was  $3.0 \pm 3.3$  yr. Examinations were primarily of bears from the Ocala population (29°10'N, 81°38'W) ( $n = 87$ ) but also included bears from the Chassahowitzka (28°32'N, 82°37'W) ( $n = 11$ ) and Big Cypress (26°15'N, 81°15'W) ( $n = 3$ ) populations. Examinations were performed in all months (see Fig. 1 for sample size by month).

Bears included in this study were ex-

amined for the presence, distribution, and extent of ectoparasites. Subjective scores for chigger infestation were assigned according to the following criteria: no chiggers observed (none), low numbers of small clusters (1–20 mites/cluster) (low), large clusters (>20 chiggers/cluster) occurring at an approximate density of 1–5 clusters/25 cm<sup>2</sup> (moderate), or large coalescing mats of chiggers (severe). Ability to recognize infestations and time constraints resulted in some bears receiving only a cursory examination for chiggers. As a result some low or even moderate infestations may have been overlooked. Therefore prevalences for the categories none, low, and moderate are given only for necropsied bears and bears receiving a thorough examination January 1999 through April 2000. Medical records of 37 black bears captured on 46 occasions July 1994 through December 1997 from the Apalachicola (30°10'N, 84°30'W), Chassahowitzka, and Osceola (30°30'N, 82°30'W) populations (M. W. Cunningham, unpubl. data) were retrospectively evaluated for observation of chigger infestations. These results were combined with the previous data to calculate the prevalence only for severe infestations.

For identification, chiggers were collected from one bear from each of three populations (Chassahowitzka, Osceola, and Ocala) by superficial skin scrapings or biopsy. Chiggers were mounted in a Hoyer's gum-choral media on microscope slides (Krantz, 1978) and identified to species according to C. Welbourn (unpubl. data). Specimens were deposited in the Florida State Collection of Arthropods (FSCA; Division of Plant Industry, Bureau of Entomology, Plant Pathology, and Nematology, Gainesville, Florida, USA; voucher numbers FSCA 1115, 1116, 1117). Three pustules from one bear with a secondary pyoderma were expressed onto a rayon-tipped swab (Culturette®, Becton Dickinson and Company, Cockeysville, Maryland, USA) and cultured (aerobic) on blood agar at the

University of Florida (College of Veterinary Medicine, Gainesville, Florida).

Histologic examination was performed on skin biopsies from the two bears with cutaneous lesions and one infested bear that had no gross evidence of dermatitis. Skin sections were removed from affected regions using a disposable 4 mm biopsy punch (Miltex Instrument Company, Inc., Lake Success, New York, USA), fixed in 10% neutral buffered formalin, embedded in paraffin, sectioned at 5 to 6 µm, and stained with hematoxylin and eosin.

We found trombiculid mite infestation in 32 of 101 (32%) free-ranging Florida black bears examined. All infestations were of low (25 of 32, 78%) or moderate (seven of 32, 22%) intensity and occurred April through September with prevalence (83%) peaking in June (Fig. 1). No chiggers were observed in three bears examined from the Big Cypress population (southern Florida). No bears examined January 1999 through April 2000 (prospective portion of study) and only one examined before January 1999 (retrospective) had a severe infestation (one of 147 examinations, <1%). This bear was an adult female in poor physical condition captured July 1994 in the Osceola population.

Chigger infestations were recognized as accumulations of bright orange granular material usually associated with hair shafts. Larval mites were found in clusters (diameter approximately 0.1 to 1 mm) containing between one and 102 individuals (mean  $8.5 \pm 19.5$ ). Degree of engorgement varied among chiggers within and among clusters. Chiggers were most frequently found on the thin-skinned areas such as the ventral abdomen, inguinal and axillary regions, and proximal medial forelimbs. All mites examined were identified as *Eutrombicula splendens* (Fig. 2).

Cutaneous lesions were observed in two of 32 (6%) infested bears. A 1-yr-old (yearling) male, captive for five months following vehicular collision, was released into the Chassahowitzka population in January 1999. When recaptured in May 1999, a

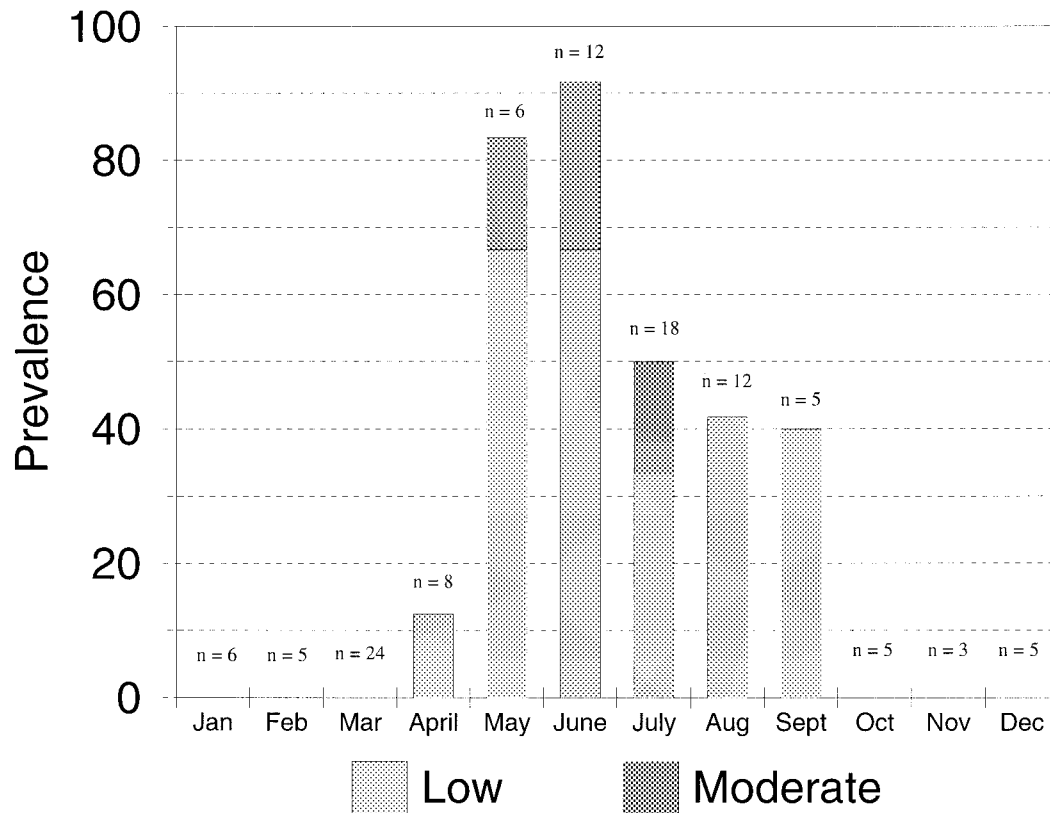


FIGURE 1. Histogram depicting prevalence, intensity, and sample size by month for trombiculid mite infestation in Florida black bears captured or necropsied January 1999 through February 2000. Sample sizes include recaptures.

pustular dermatitis associated with a moderate chigger infestation was observed over the ventral abdomen, inguinal, and axillary regions. A heavy growth of *Staphylococcus intermedius* was cultured from the pustules. The infestation and associated dermatitis had completely resolved by a second recapture in July 1999. The second bear with dermatitis was a 5-mo-old cub necropsied following vehicular collision in July 1999. This cub also had a moderate chigger infestation with crusting and scaling over the entire body, most severe at concentrated sites of chigger infestation in the right inguinal and axillary regions. The cutaneous lesions in this cub were

likely exacerbated by concurrent generalized demodicosis. Alopecia, edema, or excoriations associated with chigger infestations were not observed in these or any other cases.

Histologic examination revealed larval mites closely apposed to the stratum corneum adjacent to follicular ostia. Tubular structures, with thick hyalinized walls, eosinophilic internally and becoming translucent peripherally, were oriented perpendicularly to the surface. These structures, consistent with the stylostomes or feeding tubes, were present within a focally thinned stratum corneum and, in the bears with cutaneous lesions, extended into the




FIGURE 2. *Eutrombicula splendens* larva (mounted in Hoyer's modified gum-choral media) recovered from a Florida black bear captured July 1999 in north central Florida. Bar = 200  $\mu$ m.

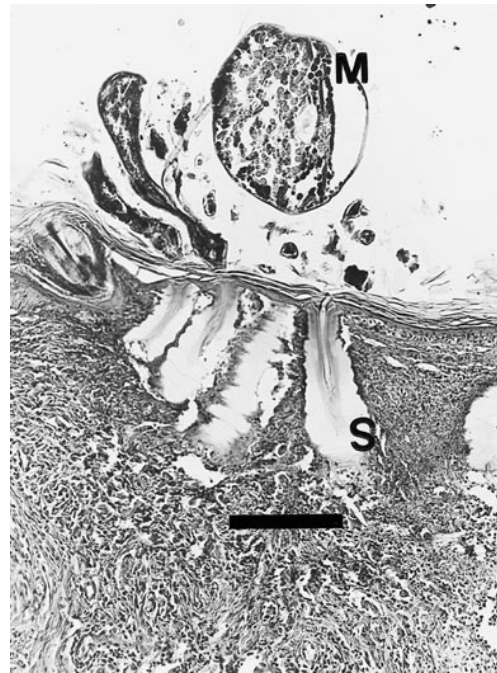

FIGURE 3. Tissue section of host skin with mites (M) closely apposed to epidermis, and stylostomes (S) with surrounding host tissue necrosis. H&E. Bar = 180  $\mu$ m.

superficial dermis. In the yearling, an extensive discrete intracorneal aggregate of necrotic suppurative debris and abundant coccoid bacteria was located beneath the mite. In both the yearling and infested bear without gross evidence of dermatitis, the epidermis adjacent to stylostomes was spongiotic, ulcerated, and necrotic with densely cellular aggregates of neutrophils, histiocytes, and eosinophils extending into the superficial dermis. Results of histologic examination of the cub were similar to the previous two cases except that associated inflammatory cells also included large numbers of plasma cells and mast cells (Figs. 3, 4). *Demodex* sp. mites also were visible in the hair follicles on deeper sections. These follicles exhibited follicular hyperkeratosis with a diffuse, sometimes nodular, perifollicular and dermal infiltrate composed of lymphocytes, plasma cells, mast cells, neutrophils, eosinophils, and histiocytes. The different inflammatory pattern observed in the cub may have

been due to concurrent demodicosis, chronicity of the trombiculiasis, and/or host age differences. Coccoid bacteria were visible only in the bears with grossly apparent cutaneous lesions.

*Eutrombicula splendens* is an important cause of trombiculiasis in humans (Jenkins, 1949) and infests a variety of vertebrate hosts including lizards, birds, and mammals (Wrenn and Loomis, 1984). Only the hexapod larvae are parasitic with other octopod stages free-living predators in the soil and leaf litter. Eggs of trombiculid mites are usually laid singly and, following emergence, the larvae move on to ground vegetation to await passage of a suitable host. The larvae tend to prefer attachment sites where the skin is thin (Jones, 1950). Thinner skin and proximity to the ground and low vegetation probably explain the primarily ventral distribution of chiggers on bears. Association of chigger clusters around hair shafts may result from chiggers making initial contact with



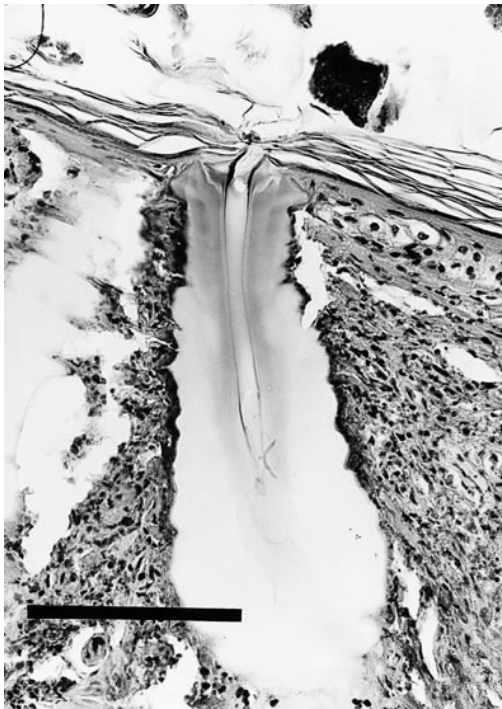


FIGURE 4. Closer view of stylostome seen in Figure 3 H&E. Bar = 100  $\mu$ m.

the hair then crawling down the shaft. At a suitable location on the host the chigger penetrates the stratum corneum with the chelicerae. The mite injects saliva into the wound, causing host tissue necrosis, and feeds on the resulting tissue fluid. This process eventually results in the formation of a stylostome or feeding tube which often penetrates to the dermis (Jones, 1950). *Eutrombicula splendens* larvae are light orange to red in color and range in length from 150 to 600  $\mu$ m depending on the degree of engorgement. The mites usually remain attached for eight to 13 days before detaching, falling to the ground, and completing their life cycle (Rohani, 1976).

*Eutrombicula splendens* is common in moist habitats in eastern North America from Canada to the Gulf states (Jenkins, 1949). Suitable habitat such as mixed hardwood swamps, riverine swamps, or freshwater or salt marshes were common ecosystems in all study areas sampled. In north central Florida, larval trombiculid

mite activity ranges from approximately mid-February to mid-November (Jenkins, 1948). Although sample sizes for winter and spring were small, infestations in bears from north central Florida were limited to April through September with the greatest prevalence of infestation occurring in June. The 22 (17 neonates, two adults) examined in March and four neonates examined in April were captured in dens and thus were less likely to be exposed to chiggers. Seasonal variation in black bear movement, behavior, and habitat preferences also may have influenced seasonal variations in mite infestation.

Although the prevalence of trombiculid mite infestation in bears was high, associated cutaneous lesions were rare. Nevertheless, trombiculiasis adds to the already heavy ectoparasite burden present in black bears from central Florida (Forrester, 1992) and may contribute to ectoparasite-induced declines in health, especially in younger animals.

We wish to acknowledge J. W. McCown, T. Eason, J. Dixon, E. Turkki, J. Smith, D. Maehr, and M. Dunbar for assistance with black bear captures. We also thank P. Ginn and D. Rotstein for review of histological slides and J. Mertins for assistance with chigger identification. We appreciate the assistance of M. Spalding with photography and thank D. J. Forrester for review of the manuscript. This research was supported in part by a contract from the Florida Fish and Wildlife Conservation Commission and is a contribution of Federal Aid to Wildlife Restoration, Florida, Pittman-Robertson Project W-41. This is Florida Agriculture Experiment Stations Journal Series No. R-07649.

#### LITERATURE CITED

- FORRESTER, D. J. 1992. Parasites and diseases of wild mammals in Florida. University Press of Florida, Gainesville, Florida, 459 pp.
- JENKINS, D. W. 1948. Trombiculid mites affecting man. I. Bionomics with reference to epidemiology in the United States. *American Journal of Hygiene* 48: 36–44.
- . 1949. Trombiculid mites affecting man. III.

- Trombicula (Eutrombicula) splendens* Ewing in North America. The Journal of Parasitology 35: 201–203.
- JOHNSON, K. G., AND M. R. PELTON. 1980. Prebaiting and snaring techniques for black bears. Wildlife Society Bulletin 8: 46–54.
- JONES, B. M. 1950. The penetration of the host tissue by the harvest mite, *Trombicula autumnalis* Shaw. Journal of Parasitology 40: 247–260.
- KRANTZ, G. W. 1978. A manual of acarology. Oregon State University Book Stores, Inc., Corvallis, Oregon, 509 pp.
- LITTLE, S. E., K. P. CARMICHAEL, AND P. M. RAKICH. 1997. Trombidiosis-induced dermatitis in white-tailed deer (*Odocoileus virginianus*). Veterinary Pathology 34: 350–352.
- MAEHR, D. S., T. S. HOCTOR, M. W. CUNNINGHAM, J. S. SMITH, AND K. WHITNEY. 1999. Ecology of the black bear in the fragmented landscape of west central Florida: Implications for management. Final Report, University of Kentucky, Department of Forestry, Lexington, Kentucky, 50 pp.
- ROHANI, I. B. 1976. Taxonomy and distribution of chiggers (Acarina: Trombiculidae) in north central Florida. Master's thesis, University of Florida, Gainesville, Florida, 80 pp.
- WILLEY, C. E. 1974. Aging black bears from first premolar tooth sections. The Journal of Wildlife Management 38: 97–100.
- WRENN, W. J., AND R. B. LOOMIS. 1984. Host selectivity in the genus *Eutrombicula* (Acari: Trombiculidae). In Acarology VI, Vol. 1, D. R. Griffiths and C. E. Bowman (eds.). Ellis Horwood Limited, Chichester, UK, pp. 160–165.

Received for publication 15 July 2000.