

## Bronchoscopy of Cetaceans

Authors: Tsang, Kenneth W., Kinoshita, Reimi, Rouke, Natalie, Yuen, Queeny, Hu, Wayne, et. al.

Source: Journal of Wildlife Diseases, 38(1) : 224-227

Published By: Wildlife Disease Association

URL: <https://doi.org/10.7589/0090-3558-38.1.224>

---

BioOne Complete ([complete.BioOne.org](https://complete.BioOne.org)) is a full-text database of 200 subscribed and open-access titles in the biological, ecological, and environmental sciences published by nonprofit societies, associations, museums, institutions, and presses.

Your use of this PDF, the BioOne Complete website, and all posted and associated content indicates your acceptance of BioOne's Terms of Use, available at [www.bioone.org/terms-of-use](https://www.bioone.org/terms-of-use).

Usage of BioOne Complete content is strictly limited to personal, educational, and non - commercial use. Commercial inquiries or rights and permissions requests should be directed to the individual publisher as copyright holder.

---

BioOne sees sustainable scholarly publishing as an inherently collaborative enterprise connecting authors, nonprofit publishers, academic institutions, research libraries, and research funders in the common goal of maximizing access to critical research.

## Bronchoscopy of Cetaceans

Kenneth W. Tsang,<sup>1,2</sup> Reimi Kinoshita<sup>1</sup>, Natalie Rouke<sup>1</sup>, Queeny Yuen<sup>1</sup>, Wayne Hu,<sup>1</sup> and Wah K. Lam,<sup>1</sup>

<sup>1</sup> University Department of Medicine and The Ocean Park, Hong Kong SAR, China; <sup>2</sup> Corresponding author (e-mail: kwtsang@hku.hk)

**ABSTRACT:** Bronchoscopy is a standard diagnostic and therapeutic procedure in respiratory medicine and has been performed on many animal species. Cetaceans suffer considerable morbidity and mortality from lower respiratory tract infections, and it is very difficult to sample lower respiratory tract secretions for microbiology and other analyses. We report our experience on performing fiberoptic bronchoscopy in three bottle-nosed dolphins (*Tursiops truncatus*) and one false killer whale (*Pseudorca crassidens*), which should help other clinicians in performing bronchoscopy in cetaceans.

**Key words:** Bronchoscopy, cetacean, respiratory infections, techniques, *Tursiops truncatus*.

Bronchoscopy was first performed by Killian in 1895 in humans to directly visualize the trachea and bronchi and to remove foreign bodies. Indications for this procedure have gradually expanded and, with the advent of fiberoptic bronchoscopy in the late 1960s, the tracheobronchial tree can now be visualized to the level of subsegmental divisions. This ability, coupled with significant technical improvements in various biopsy instruments, has made bronchoscopy one of the most important techniques in respiratory medicine.

Bronchoscopy is also performed in many animal species to examine airways, retrieve foreign bodies, or for research purposes (Rebar et al., 1980; Pringle et al., 1988; Haley et al., 1989; McCarthy et al., 1989). However, most of these procedures have been performed on land mammals whose airway anatomy is relatively well defined. Bronchoscopy in cetaceans, however, imposes far greater challenge to the bronchoscopist, because detailed methodology has not been reported and the airway anatomy is dissimilar to that of humans. Here we report our experience and protocol for bronchoscopy of three bottle-nosed dolphins (*Tursiops truncatus adun-*

*cus*) and one false killer whale (*Pseudorca crassidens*) in Hong Kong.

Between December 1997 and April 2000, bronchoscopy was performed on three bottle-nosed dolphins and one false killer whale at the Hong Kong Ocean Park for investigation of recurrent pneumonia. All these animals displayed clinical features of lower respiratory tract illness including listing, anorexia, malaise, and transthoracic ultrasonic or radiographic evidence of lung consolidation, high erythrocyte sedimentation rate, and leukocytosis. The procedures were performed either in a veterinary hospital or by a display pool.

The dolphins were fasted for 4–6 hr prior to the procedure. Sedation was achieved by administration of oral diazepam (Pharmacia and Upjohn, New Jersey, USA; 0.16–0.17 mg/kg) or parenteral midazolam (Roche, Basel, Switzerland; 0.04–0.06 mg/kg), which was injected into the muscle craniolateral to the dorsal fin. The cetacean to be examined was hoisted from the pool in a sling onto a thick mattress secured on a platform elevated 30 cm above the ground. Each of the cetaceans was positioned in sternal recumbency with the sling and 6–8 trainers deployed around the animal to minimize movement. The head was stabilized by means of towels wrapped about the rostrum.

Five ml of 4% lignocaine (Pharmacia and Upjohn, New Jersey, USA) were injected into the blowhole of each of the animals using a 20 ml syringe, which contained 15 ml of air in addition to the anesthetic. Injection was performed when the dolphin opened the blowhole. A 55 cm Olympus BF P30 bronchoscope (Olympus, Tokyo, Japan) attached to a video system with television monitor was well lu-

bricated with sterile AQUA jelly (Adams, Leeds, England) and inserted into the blowhole by gentle but consistent pressure. Immediately below the blowhole was a bony nasal passage about 5–7 cm in length and 2–3 cm across in dolphins. The bronchoscope was advanced through this cavity, which often contained abundant mucus which was cleared by suction before the lumen could be easily identified.

The nasopharynx, a tubular hollow space about 4–5 cm in diameter in the dolphins, was easily identified beyond the nasal cavity, and had copious mucoid and tenacious mucus in the animals examined. In the center of the nasopharynx was a beak-like arytenoepiglottideal tube, which appeared pale pink in color. The space between the arytenoepiglottideal tube and the pharyngeal wall, which had abundant mucus, was identified as the nasopharyngeal fornix (Fig. 1a). The glottis was rosette-shaped and was not covered by an epiglottis. The larynx appeared tightly shut although it burst open during respiratory cycles, each of which lasted for a fraction of a second. Two ml of 4% lignocaine was sprayed onto the opened laryngeal spout twice (Fig. 1b), separated by a time interval of 10 sec, before the bronchoscope was inserted through the opened larynx. This was performed with the tip of the bronchoscope at the center of the anaesthetized glottis, as judged by observing the previous openings. Insertion of the bronchoscope via the glottis was relatively difficult procedure because it opened only for a fraction of a second. There was considerable resistance created by the closed glottis. The bronchoscopic view was blurred when the bronchoscope was still within the laryngeal spout, which was about 5–7 cm in the dolphins. Passing the bronchoscope via the arytenoepiglottideal tube could not be performed in one smooth attempt. Instead, this was performed in several stages as the cetacean breathed thereby relaxing the arytenoepiglottideal tube at which time the bronchoscope was advanced gently. Further respi-

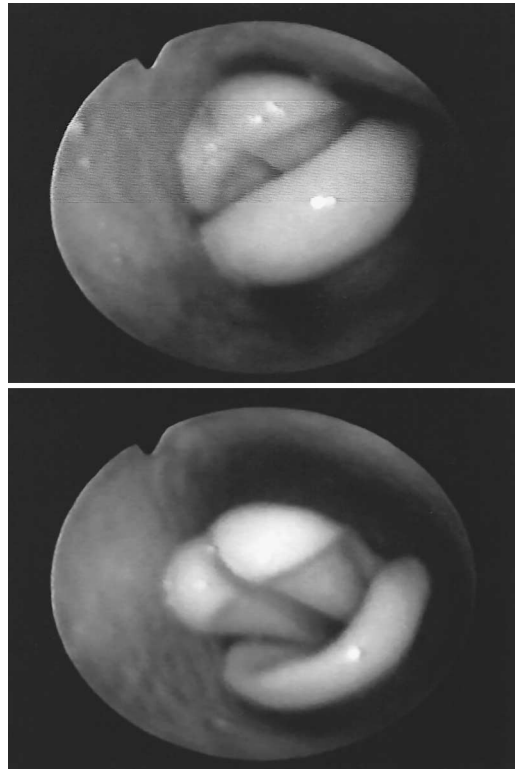


FIGURE 1. Bronchoscopic photographs showing the laryngeal spout situated within the nasopharynx. The glottis was a). shut, and b). opened during respiratory cycle of a bottle-nosed dolphin.

ratory cycles were awaited to advance the bronchoscope through the larynx by gentle steady pressure.

Immediately below the laryngeal spout was a pear-shaped cavity, which was lined by pink trabeculated mucosa that contained abundant mucus glands. This was 4–5 cm on its long axis in the dolphins and led to the easily identified trachea which had complete cartilage rings on its entire wall. Two ml of 2% lignocaine were injected into upper trachea just below the larynx.

The right tracheal bronchus was readily identified about 10 cm below the inferior aspect of the laryngeal spout and branched off the inferior wall of the dolphin tracheas (Fig. 2). The right tracheal bronchus appeared to have three subsegments. Two ml of 2% lignocaine were injected into the accessory bronchus prior to its examination.

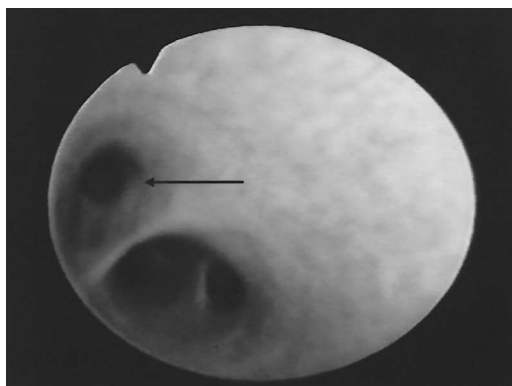


FIGURE 2. A bronchoscopic photograph showing the cartilage-lined right tracheal bronchus (arrow), which branched off the inferior aspect of the trachea of a bottle-nosed dolphin.

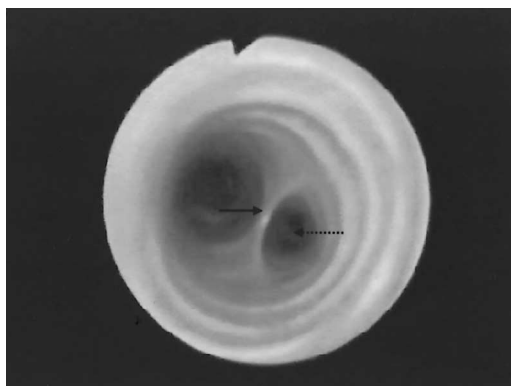


FIGURE 3. A bronchoscopic photograph showing the very sharp "carina" (arrow) and the closely adhered left (dotted arrow) and right main bronchi in a bottle-nosed dolphin. Complete cartilage rings were evident throughout the entire length of the trachea.

The "carina" was situated about 5 cm below the entrance to the accessory bronchus and was "sharp" like the blade of a knife (Fig. 3). It immediately led to the left and right main bronchi, which branched off virtually in parallel. Two ml of 2% lignocaine were injected into the left and right bronchi prior to their examination. Each bronchus branched into three to four subsegments, 3–4 cm from the carina in dolphins. The bronchoscope could only reach the origin of these segments in dolphins and the carina in the false killer whale. There were virtually no secretions in the airways of the cetaceans examined, despite their copious productive cough prior to the procedure.

Bronchoalveolar lavage was performed in two of the dolphins. In order to ensure that appropriate sampling was performed, the pneumonic lung was identified by radiology and transthoracic ultrasound scanning. Briefly, two aliquots of 50 ml warm sterile saline were injected into the appropriate bronchus successively. The second aliquot was injected after no further fluid was obtained from the appropriate bronchus by gentle suction (300 kPa) provided from a Dia-Pump (Narco-Scientific, Shannon, Ireland). Double-sheath microbiological sterile brushes (Medi-Tech, Massachusetts, USA) were used on the main bronchi. Bronchial biopsies were not per-

formed because the bleeding tendency of cetaceans was unknown for this procedure. Exhalation of anesthetics and bronchoalveolar fluid through the blowhole occurred regularly. Because we have encountered cases of dolphins infected by *Burkholderia pseudomallei*, which may be zoonotic, appropriate protective clothing, masks, and spectacles were used. The animals tolerated the procedures well except for some coughing during the procedure, particularly during passing of the bronchoscope through the arytenoepiglottideal tube.

After the procedure, which lasted between 10–20 min, the bronchoscope was removed with one smooth action. The cetaceans were then hoisted into shallow water for 30 min to ensure that there was no dyspnea before they were allowed back to their usual pools.

Use of bronchoscopy is widely accepted in veterinary practice. The technique of bronchoalveolar lavage, which allows direct sampling of the respiratory tract, has been used to obtain cells, proteins, lipids, and select tissue constituents from the lower airway and alveoli of many species. Because it is difficult to obtain lower respiratory tract specimens, treatment of pneumonia, which is a common cause of mortality among cetaceans, often has to be

initiated without proper identification of the pathogen. Bronchoscopic sampling is therefore an attractive technique for sampling of lower respiratory tract specimens under such circumstances.

However, most previous reports on animal, particularly those on cetacean, bronchoscopy lack details on the actual endoscopic procedures and many were performed under general anesthesia (Derksen et al., 1992; Hensel et al., 1994; Reis et al., 1994). Recently, bronchoscopic examination of a bottle-nosed dolphin with a pediatric gastroscope was reported (Hawkins et al., 1997). Another paper described bronchoscopic sampling of an endobronchial lesion leading to the diagnosis of *Aspergillus fumigatus* pneumonia in a bottle-nosed dolphin (Reidarson et al., 1998).

Because cetaceans are air-breathing mammals, the need to have an air-tight seal of the closed glottis is vital. This is particularly important for whales which may dive considerable depths. The complex groups of upper airway muscles in cetaceans provide airtight barriers, which naturally make bronchoscopy a difficult procedure (Lawrence et al., 1965). The standard 55 cm bronchoscope is not long enough to reach the subsegmental levels of most dolphin airways. In addition, without some sedation, dolphins appear to tolerate the procedure poorly. Excessive sedation or general anesthesia are considered undesirable because cetaceans should be returned to water soon after completion of the procedure. Our description of bronchoscopy should assist in the study, investigation, and management of lower respiratory tract diseases in cetaceans.

The authors wish to thank V. Tang, D. Lee, M. Cheong, and S. Yeung of the University of Hong Kong for expert technical assistance. The veterinary assistants of the Hong Kong Ocean Park provided invaluable support.

## LITERATURE CITED

- DERSKEN, F. J., R. F. SLOCOMBE, P. R. GRAY, AND N. E. ROBINSON. 1992. Exercise-induced pulmonary hemorrhage in horses with experimentally induced allergic lung disease. *American Journal of Veterinary Research* 53: 15–21.
- HALEY, P. J., B. A. MUGGENBURG, A. H. REBAR, G. M. SHOPP, AND D. E. BICE. 1989. Bronchoalveolar lavage cytology in cynomolgus monkeys and identification of cytologic alterations following sequential saline lavage. *Veterinary Pathology* 26: 265–273.
- HAWKINS, E. C., F. I. TOWNSEND, G. A. LEWBART, M. A. STAMPER, V. G. THAYER, AND H. L. RHINEHART. 1997. Bronchoalveolar lavage in a dolphin. *Journal of American Veterinary Association* 211: 901–904.
- HENSEL, A., M. GANTER, S. KIPPER, S. KREHON, M. M. WITTENBRINK, AND K. PETZOLDT. 1994. Prevalence of aerobic bacteria in bronchoalveolar lavage fluids from healthy pigs. *American Journal of Veterinary Research* 55: 1697–1702.
- LAWRENCE, B., AND W. E. SCHEVILL. 1965. Gular musculature in delphinids. *Bulletins of Muscle Comparative Zoology (Harvard)* 133: 1–65.
- MCCARTHY, G. M., AND P. J. QUINN. 1989. Bronchoalveolar lavage in the cat: Cytological findings. *Canadian Journal of Veterinary Research* 53: 259–263.
- PRINGLE, J. K., L. VIEL, P. E. SHEWEN, R. A. WILLOUGHBY, S. W. MARTIN, AND V. E. VALLI. 1988. Bronchoalveolar lavage of cranial and caudal lung regions in selected normal calves: Cellular, microbiological, immunoglobulin, serological and histological variables. *Canadian Journal of Veterinary Research* 52: 239–248.
- REBAR, A. H., D. B. DENICOLA, AND B. A. MUGGENBURG. 1980. Bronchopulmonary lavage cytology in the dog: Normal findings. *Veterinary Pathology* 17: 294–304.
- REIDARSON, T. H., J. H. HARRELL, M. G. RINALDI, AND J. MCBAIN. 1998. Bronchoscopic and serologic diagnosis of *Aspergillus fumigatus* pulmonary infection in a bottlenose dolphin (*Tursiops truncatus*). *Journal of Zoo and Wildlife Medicine* 29: 451–455.
- REIS, A., M. TÖTSCH, H. SHENNIB, D. ÖFNER, C. SER-RICK, A. JAMJOOM, N. CHIKHANI, G. MIKUZ, AND R. MARGREITER. 1994. Bronchoalveolar lavage: Results of sequential, selective techniques in viable murines. *American Journal of Respiratory and Critical Care Medicine* 150: 547–550.

*Received for publication 3 December 2000.*