

SUSCEPTIBILITY OF RACCOONS (*PROCYON LOTOR*) TO INFECTION WITH *MYCOBACTERIUM BOVIS*

Mitchell V. Palmer,^{1,2} W. Ray Waters,¹ and Diana L. Whipple¹

¹ Bacterial Diseases of Livestock Research Unit, National Animal Disease Center, Agricultural Research Service, USDA, 2300 N. Dayton Avenue, Ames, Iowa 50010, USA

² Corresponding author (e-mail: mpalmer@nadc.ars.usda.gov)

ABSTRACT: Tuberculosis due to *Mycobacterium bovis* infection is endemic in white-tailed deer (*Odocoileus virginianus*) in the northeastern portion of the lower Michigan peninsula (USA). Various wild carnivores and omnivores, including raccoons (*Procyon lotor*), are infected with *M. bovis* within the endemic area. To investigate the pathogenesis of tuberculosis in raccoons and the likelihood of *M. bovis* transmission from infected raccoons to other susceptible hosts, we experimentally inoculated raccoons with single oral doses of *M. bovis* (ranging from 30 to 1.7×10^5 colony forming units [CFU]), five daily oral doses of *M. bovis* (ranging from 10 to 1×10^5 CFU), or a single intravenous (IV) dose of 1×10^5 CFU of *M. bovis*, from November 1998 through December 2000. Granulomatous lesions consistent with tuberculosis, or tissue colonization with *M. bovis*, were seen in one of five raccoons in the single low oral dose group, one of five raccoons in the multiple low oral dose group, two of five raccoons in the multiple medium oral dose group, five of five raccoons in the multiple high oral dose group, and five of five raccoons in the IV inoculated group. In orally inoculated raccoons, lesions were most common in the tracheobronchial and mesenteric lymph nodes and lung. Excretion of *M. bovis* in saliva or nasal secretions was noted in all IV inoculated raccoons and two of five multiple low oral dose raccoons. *Mycobacterium bovis* was not isolated from urine or feces from any experimentally inoculated raccoons. The need for multiple large oral doses to establish infection, and the low number of orally inoculated raccoons that excreted *M. bovis* in nasal secretions or saliva, suggest that widespread tuberculosis among raccoons is unlikely.

Key words: Bovine tuberculosis, experimental infection, *Mycobacterium bovis*, *Procyon lotor*, raccoon.

INTRODUCTION

Mycobacterium bovis, the causative agent of tuberculosis in cattle and Cervidae, has a broad host range including humans. In 1994, *M. bovis* was found in a free-ranging white-tailed deer (*Odocoileus virginianus*) in Michigan. Since that time, surveys of free-ranging white-tailed deer in Michigan have documented that *M. bovis* infection is endemic in the northeastern Michigan deer population (Schmitt et al., 1997). This represents the first known wildlife reservoir of bovine tuberculosis in the United States. Concomitant with the survey of white-tailed deer, other mammalian species have been examined in the endemic area, including elk (*Cervus elaphus*), opossum (*Didelphus virginiana*), raccoon (*Procyon lotor*), coyote (*Canis latrans*), red fox (*Vulpes vulpes*), bobcat (*Felis rufus*), badger (*Taxidea taxus*), and black bear (*Ursus americanus*). To date, *M. bovis* infection has been documented

in coyotes, raccoons, red fox, bobcat, black bear (Bruning-Fann et al., 1998, 2001), elk, and opossum (S.D. Fitzgerald, pers. comm.). It is thought that omnivorous and carnivorous mammals become infected through scavenging tuberculous deer carcasses.

Numerous small mammals have been experimentally or naturally infected with *M. bovis* (McCoy, 1911; Dunkin et al., 1929; Griffith, 1939; Pulling, 1952; Basak et al., 1976; Joon, 1976; Thorns et al., 1982; Cooke et al., 1993, 1995; Gill and Jackson, 1993; Lugton et al., 1995; Ragg et al. 1995). Prior to the discovery of *M. bovis* in raccoons in Michigan, neither natural nor experimental infection with *M. bovis* had been reported in raccoons. Natural *M. bovis* infection has been reported in a coati (*Nasua narica*), a close relative of the raccoon and member of the family Procyonidae. Disease progressed rapidly and lesions were disseminated (Griffith, 1939).

Due to the lack of information on the pathogenesis of *M. bovis* in raccoons, the objective of the present study was to determine the susceptibility of raccoons to oral infection with *M. bovis*, describe the distribution of lesions in affected animals, and suggest the likelihood of raccoons serving as a mechanism of *M. bovis* transmission in the current outbreak in Michigan.

MATERIALS AND METHODS

Animals

Between November 1998 and December 2000, 37, 6 mo old, male raccoons were obtained from a commercial raccoon supplier (Ruby Fur Farm, New Sharon, Iowa, USA). No history of *M. bovis* infection had been documented in this population. Upon arrival at the National Animal Disease Center, Ames, Iowa (42°03'N, 93°63'W), raccoons were treated for parasites with oral pyrantel pamoate (Pfizer Animal Health, Lee's Summit, Missouri, USA) and subcutaneous injection of ivermectin (600 µg/kg; AgriLabs Ltd., St. Joseph, Missouri), and surgically castrated under anesthesia with intramuscular (IM) ketamine (10 mg/kg) (Fort Dodge Animal Health, Fort Dodge, Iowa) and xylazine (2 mg/kg) (Bayer Corporation, Shawnee Mission, Kansas, USA). The effects of xylazine were reversed by intravenous (IV) injection of yohimbine (0.2 mg/kg) (Lloyd Laboratories, Shenandoah, Iowa).

Inoculation

Mycobacterium bovis strain 1315, originally isolated in 1995 from a free-ranging tuberculous white-tailed deer in Michigan, was used for inoculation. The isolate was incubated at 37 C for 6 wk on Middlebrook's 7H9 liquid media with 10% oleic albumin dextrose citrate (OADC) and 0.05% Tween 80. After incubation, the samples were harvested by centrifugation at 750 × G, and washed twice with 0.01 M phosphate buffered saline (PBS) solution, pH 7.4. After resuspension in PBS solution, serial 10-fold dilutions were inoculated on Middlebrook 7H11 selective agar plates (Becton Dickinson, Cockeysville, Maryland, USA) to determine the number of colony forming units (CFU). Inoculum was frozen at -80 C for future use.

Two to 3 wk after castration, raccoons were randomly assigned to one of eight groups. The single high dose group ($n = 3$) was fed 1.7×10^5 CFU of *M. bovis* in 10 g strawberry pre-

serves. The single medium ($n = 3$) and single low ($n = 3$) dose groups received 1.2×10^3 and 30 CFU of *M. bovis*, respectively, fed in a similar fashion. The multiple high dose group ($n = 5$) received 1×10^5 CFU of *M. bovis* as described above for five consecutive days; likewise, the multiple medium ($n = 5$) and low ($n = 5$) dose groups received 1×10^3 and 10 CFU of *M. bovis*, respectively, for five consecutive days. Positive control raccoons ($n = 5$) received 1×10^5 CFU of *M. bovis* injected in the jugular vein while anesthetized as described above. Negative control raccoons ($n = 8$) received 10 g strawberry preserves containing 1 ml sterile saline. Experimentally inoculated raccoons, both oral and IV groups, were housed according to group in a biocontainment level-3 building. Negative controls were housed similarly in a separate building.

Postmortem examination

Intravenously inoculated raccoons were euthanized 118 days after inoculation. Orally inoculated and saline control groups were euthanized 125 days after inoculation. All animals were anesthetized as described above and euthanized by IV injection of sodium pentobarbital (Sleepaway, Fort Dodge Animal Health). Samples of tonsil; mandibular, parotid, medial retropharyngeal, superficial cervical, tracheo-bronchial, iliac, and mesenteric lymph nodes; lung; liver; spleen; brain; urinary bladder; and kidney were collected for microscopic analysis and bacteriologic culture. Samples of myocardium were collected for microscopic analysis only. Samples collected for microscopic analysis were fixed in neutral buffered 10% formalin, processed routinely, sectioned at 5 µm, stained with hematoxylin and eosin (HE), and examined by light microscopy. Adjacent sections were cut from blocks containing sections with lesions suggestive of tuberculosis and stained by the Ziehl-Neelsen technique for identification of acid-fast bacteria (Sheehan and Hrapchak, 1980). Lesions were judged to be consistent with tuberculosis when granulomas contained acid-fast bacilli.

Tissue samples collected for bacteriologic culture were macerated in phenol red nutrient broth (Becton-Dickinson), decontaminated in 2% NaOH for 10 min, centrifuged for 20 min, and the supernatant decanted. Bactec 12B (Middlebrook 7H12), modified Middlebrook 7H11 (NVSL, Ames, Iowa), Middlebrook 7H10 with OADC, Herrold Egg Yolk (Remel, Lenexa, Kansas), and Stonebrinks media (NVSL) were inoculated with the sediment. The inoculated media were incubated at 37 C for 12 wk and examined for colony formation. Bactec 12B

vials were processed according to manufacturer's instructions (Becton-Dickinson). Mycobacterial isolates were identified using standard growth and biochemical characteristics. Isolates were confirmed to belong to the *M. tuberculosis* complex by genetic probe analysis (AccuProbe, Gen-Probe Inc., San Diego, California, USA). Additional samples collected for microbiologic culture included urine, feces, and swabs of the oral cavity, nasal cavity, deep nasal turbinates, and tonsillar fossa. Swabs, urine, and feces were processed as described (Palmer et al., 2000b). Specimens for bacteriologic culture were considered positive when *M. bovis* was isolated.

Antibody assay

Blood was collected prior to inoculation and at necropsy. Serum was harvested for detection of raccoon immunoglobulin specific for mycobacterial antigens by an enzyme linked immunosorbent assay (ELISA). Wells of 96 well microtiter plates (Immunolon II, Dynatech, Chantilly, Virginia, USA) were coated with either 5 µg/ml *M. bovis* PPD (CSL Limited, Parkville, Australia), 5 µg/ml *M. avium* PPD (CSL Limited), 5 µg/ml *M. bovis* whole cell sonicate, or 20 µg/ml proteinase K-digested *M. bovis* whole cell sonicate. Antigens were diluted in a carbonate-bicarbonate coating buffer (pH 9.6). Antigen-coated wells were incubated overnight at 4 C, washed three times with PBS containing 0.05% Tween 20 (PBST, Sigma, St. Louis, Missouri), and blocked with PBS containing 1% gelatin for 1 hr at 37 C. Wells were washed three times with PBST and test sera (diluted 1:1,000 in PBS plus 0.1% gelatin) added to duplicate wells. Plates were incubated for 1 hr at 37 C and washed three times with PBST. Horseradish peroxidase conjugated anti-raccoon IgG (heavy and light chains; Kirkegaard Perry Laboratories, Gaithersburg, Maryland) diluted 1:500 in PBS plus 0.1% gelatin was added to wells and plates incubated for 1 hr at 37 C. Wells were washed three times with PBST and substrate (3,3',5,5'-tetramethylbenzidine; Kirkegaard Perry Laboratories) added to wells. After a 5 min incubation at room temperature, a stop solution (0.18 M sulfuric acid, Kirkegaard Perry Laboratories) was added to wells and optical density measured at 405 nm using an ELISA plate reader (Molecular Devices, Menlo Park, California).

Statistical analysis

Enzyme linked immunosorbent assay data were analyzed by one-way analysis of variance followed by Tukey-Kramer multiple comparisons test. Differences between groups were

considered significant if probability values of $P < 0.05$ were obtained.

RESULTS

Postmortem examination

No gross or microscopic lesion consistent with tuberculosis was seen in control raccoons or in raccoons receiving a single oral exposure of any dose of *M. bovis*. One of five raccoons receiving multiple high oral doses of *M. bovis* had a single 4–5 mm, firm, round nodular lesion in an enlarged medial retropharyngeal lymph node. No gross lesion was seen in other raccoons receiving multiple doses of *M. bovis*. All IV inoculated raccoons had grossly visible disseminated tuberculosis. Multiple lesions were seen in mandibular, parotid, medial retropharyngeal, superficial cervical, tracheobronchial, and mesenteric lymph nodes; lung; liver; spleen; and kidney (Table 1). Two of five IV inoculated raccoons had diffuse fibrinous to granulomatous pericarditis and epicarditis with adhesion of the pericardial sac to the epicardium and abundant yellow, turbid pericardial fluid containing fibrin tags. Two of five IV inoculated raccoons also had unilateral fistulous tracts associated with granulomatous lesions in the parotid lymph node. One of five IV inoculated raccoons had multiple, grossly visible, 0.3–1.0 cm granulomas within the meninges covering the cerebral cortex.

No microscopic lesion was seen in any raccoon receiving single oral dosages of *M. bovis*. Microscopic lesions consistent with tuberculosis were seen in one of five multiple low dose, one of five multiple medium dose, and five of five multiple high dose orally inoculated raccoons. Tissues affected included tonsil, medial retropharyngeal lymph node, tracheobronchial lymph node, lung, liver, and mesenteric lymph node (Table 2). Tissues from IV inoculated raccoons that contained microscopic lesions consistent with tuberculosis were those in which gross lesions were seen (Table 1). Microscopically, granulomas were most often characterized by aggregates of

TABLE 1. Summary of culture results and gross and microscopic tissue examination of raccoons inoculated IV with 1×10^5 CFU *M. bovis* and euthanized 118 days later.

Tissue	Animal identification					Total
	9	10	11	2	20	
Tonsil	m, b ^a	m, b	m, b	m, b	m, b	5/5
Mandibular LN ^b	g, m, b	g, m, b	m, b	m, b	m, b	5/5
Parotid LN	m, b	g, m, b	m, b	g, m, b	m, b	5/5
Medial retropharyngeal LN	g, m, b	g, m, b	m, b	g, m, b	g, m, b	5/5
Superficial cervical LN	g, m, b	g, m, b	m, b	m, b	m, b	5/5
Tracheobronchial LN	g, m, b	g, m, b	m, b	g, m, b	m, b	5/5
Lung	g, m, b	g, m, b	g, m, b	g, m, b	g, m, b	5/5
Liver	g, m, b	g, m, b	m, b	g, m, b	g, m, b	5/5
Mesenteric LN	g, m, b	g, m, b	m, b	b	m, b	5/5
Iliac LN	g, m, b	m, b		m		3/5
Spleen	m, b	g, m, b	m, b	m, b	m, b	5/5
Myocardium ^c	m	g, m			g, m	3/5
Kidney	g, m, b	g, m, b	g, m, b	g, m, b	g, m, b	5/5
Urinary bladder			b	b		2/5
Brain	b	b		b		3/5
Meninges	g, m, b					1/5

^a g = gross lesion, m = microscopic lesion, b = bacteriologic isolation of *M. bovis*.

^b LN = lymph node.

^c Myocardium not processed for bacteriologic isolation of *M. bovis*.

epithelioid and highly vacuolated macrophages, multinucleated giant cells, moderate numbers of lymphocytes, and central accumulations of neutrophils (Fig. 1). In larger granulomas there was central necrosis and occasional granular mineralization of necrotic debris. Many large granulomas had large (up to 3 mm) central cavities. The lumina of these cavities were filled with homogenous eosinophilic material (Fig. 2).

Acid-fast bacteria were present in moderate to large numbers in granulomas from IV inoculated raccoons; however, in orally inoculated raccoons, acid-fast bacteria were rare, with many granulomas containing only one or two acid-fast bacteria.

Bacteriologic culture

Isolation of *M. bovis* from tissue correlated well with the presence of gross or microscopic lesions consistent with tuberculosis (Tables 1, 2). *Mycobacterium bovis* was also isolated from tissues in which lesions of tuberculosis were not seen, including urinary bladder (2 of 5) and brain (3 of 5) from IV inoculated raccoons.

Antibody assay

Raccoons receiving single or multiple oral inoculations of any dosage of *M. bovis* did not develop detectable antibodies to the *M. bovis* antigens used in the ELISA. Significant elevations ($P < 0.05$) in antigen specific IgG were seen only in the IV inoculated group (data not shown). The response was significantly greater ($P < 0.05$) to *M. bovis* PPD compared to *M. avium* PPD, *M. bovis* whole cell sonicate, or *M. bovis* proteinase K digested whole cell sonicate (Fig. 3).

DISCUSSION

Raccoons may develop tuberculosis after ingestion of *M. bovis*. Consistent infection, however, required multiple oral exposures of high numbers of bacteria. Raccoons are omnivorous and opportunistic carnivores that will eat almost anything (Kaufmann, 1982). The number of bacteria ingested by an individual raccoon feeding on infected carrion is unknown and likely quite variable. However, ingestion of lymph nodes or lungs from tuberculous

TABLE 2. Summary of culture results and gross and microscopic tissue examination of raccoons fed various doses of *M. bovis* once each day for 5 consecutive days and euthanized 125 days later. Low dose (10^3 CFU *M. bovis*), medium dose (1×10^3 CFU *M. bovis*), and high dose (1×10^5 CFU *M. bovis*).

Tissue	Low dose Animal identification					Medium dose Animal identification					High dose Animal identification							
	13	14	3	12	MP	Total	15	24	4	16	17	Total	1	6	7	5	8	Total
Tonsil							m ^a					1/5				m		1/5
Mandibular LN ^b																		
Parotid LN																		
Mr LN ^c	m					1/5							m	m, b		g, m, b	m, b	1/5
Tb LN ^d	b					1/5								b			g, m	3/5
Laung										b		1/5						2/5
Liver														m				1/5
Mesenteric LN														m	m, b			2/5

^a g = gross lesion, m = microscopic lesion, b = bacteriologic isolation of *M. bovis*.

^b LN = lymph node.

^c Mr LN = medial retropharyngeal lymph node.

^d Tb LN = tracheobronchial lymph node.

deer carcasses could provide large numbers of *M. bovis* organisms.

Excretion of *M. bovis* in respiratory secretions or saliva occurred most commonly in raccoons with severe disseminated tuberculosis resulting from IV inoculation. However, two of five raccoons inoculated with multiple low dosages of *M. bovis*, had *M. bovis* in swabs of the nasal cavity or deep nasal turbinates at necropsy. Quantitative bacteriologic culture was not done in this study; therefore, comparison of numbers of organisms excreted by each group is not possible. *Mycobacterium bovis* was not isolated from urine or feces from any raccoon, regardless of inoculation route or severity of disease. In the present study, post-inoculation samples of urine or feces, as well as swabs of the oral and nasal cavities were collected only at the time of necropsy. Sample collection at various times after inoculation would increase the likelihood of detecting *M. bovis* in these samples. *Mycobacterium bovis* has been isolated from urine and feces from experimentally inoculated badgers (Little et al., 1982), experimentally inoculated cattle (Costello et al., 1998), experimentally inoculated white-tailed deer (Palmer et al., 2001), and naturally infected red deer (*Cervus elaphus*) (Lugton et al., 1998). Excretion of *M. bovis* from experimentally inoculated cattle has been shown to be intermittent, especially in the later stages of disease (Costello et al., 1998).

In the present study, raccoons were housed according to dosage group, therefore, horizontal transmission of *M. bovis* between raccoons within a group cannot be discounted. Further studies will be required to evaluate the significance of horizontal transmission of *M. bovis* among raccoons. The habits of raccoons increase the potential for horizontal transmission through saliva or nasal secretions from tuberculous animals. Raccoons may travel as much as 5–8 km and eat as much as 2–3 kg of food in a single night. Raccoons live in dens usually located in a hollow tree, rock crevice, rock pile, chimney, attic,

TABLE 3. Culture results of swabs collected at necropsy, 118 days after intravenous inoculation (IV) of 1×10^5 CFU *M. bovis* (IV inoculated group), or 125 days after 5 consecutive days of ingestion of 10 CFU *M. bovis* (multiple low dose group). Results were considered positive if *M. bovis* was isolated. Only samples containing *M. bovis* are reported.

Swab specimen	Dose group						
	IV inoculated Animal number			Multiple low Animal number			
	11	20	9	2	10	12	3
Oral cavity	+ ^a		+		+		
Nasal cavity					+	+	
Tracheal lumen	+			+			
Deep nasal turbinates	+				+		+
Tonsillar fossa		+	+		+		

^a *M. bovis* isolated from swab.

barn, or abandoned animal burrow. The young, born in the spring, usually leave the den in the fall; however, in some northern climates the young may remain with the dam through the winter. Winter dens usually include a female and her cubs, or

groups of two or three siblings. Raccoons have been known to den with other unrelated raccoons. In one case, 23 raccoons were recorded in one winter den (Mech

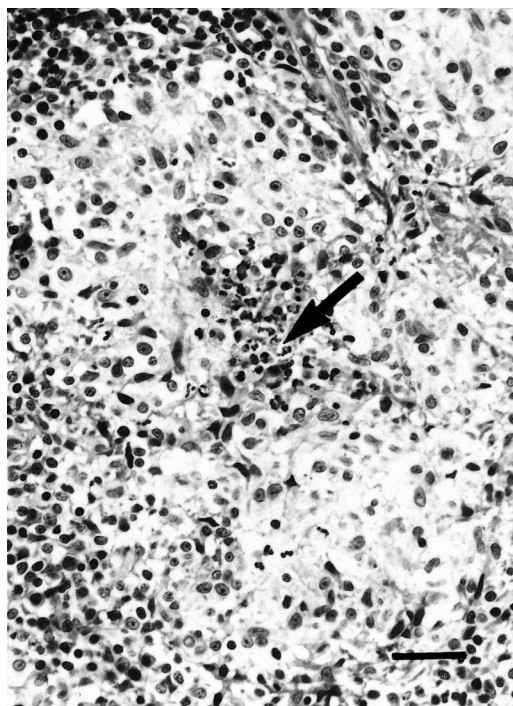


FIGURE 1. Section of lymph node from raccoon ingesting 1×10^5 CFU of *M. bovis* on 5 consecutive days and examined 125 days later. Note aggregate of epithelioid macrophages and central accumulations of neutrophils (arrow). HE. Bar = 55 μ m.

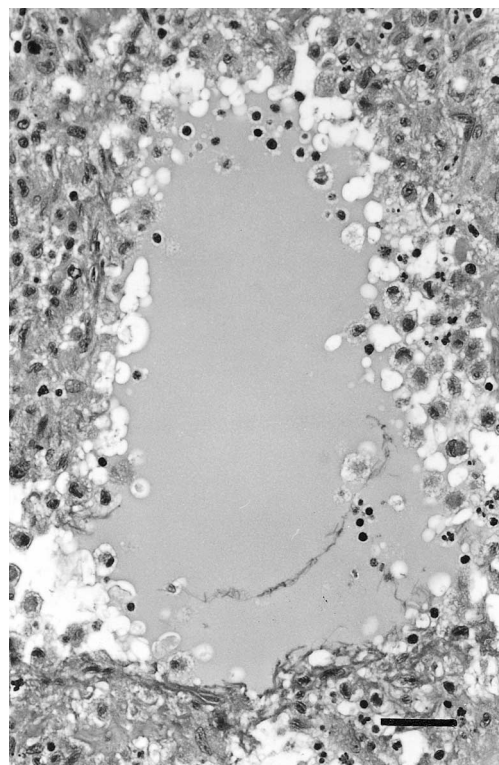


FIGURE 2. Section of lymph node from raccoon ingesting 1×10^5 CFU of *M. bovis* on 5 consecutive days and examined 125 days later. Note central area of granuloma containing homogenous material. HE. Bar = 55 μ m.

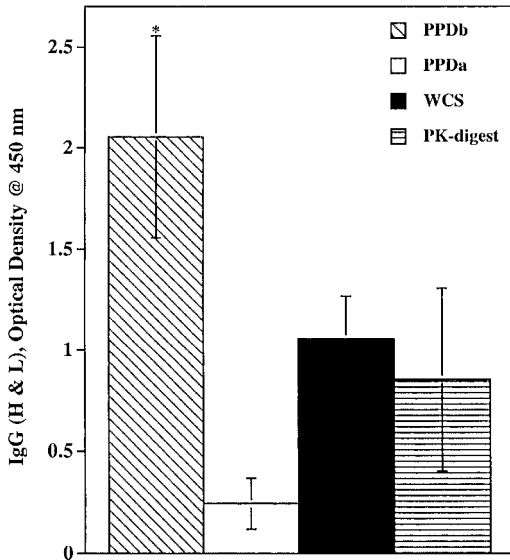


FIGURE 3. Total immunoglobulin, specific for mycobacterial antigens, as measured by ELISA for IgG (heavy and light chains), in raccoons receiving 1×10^5 CFU of *M. bovis* IV, determined 118 days after inoculation. Antigens used in the ELISA included: *M. bovis* PPD (PPDb), *M. avium* PPD (PPDa), *M. bovis* whole cell sonicate (WCS), and proteinase K digested *M. bovis* whole cell sonicate (PK-digest). Values are presented as mean optical density readings for mycobacterial antigen coated wells minus readings for uncoated wells. Serum samples were diluted 1:1,000 in PBS and run in triplicate, $n = 5$. * = $P < 0.05$.

and Turkowski, 1966). Such habits increase the potential for transmission of *M. bovis* between raccoons. Moreover, raccoons commonly den in areas near humans and domestic livestock (i.e. chimneys, barns, etc.) creating a potential for inter-species transmission of *M. bovis*.

Similar to the only report of natural *M. bovis* infection in raccoons (Bruning-Fann et al., 2001), gross lesions were not a key feature of the orally inoculated raccoons in the present study. Furthermore, microscopic lesions in two of three naturally infected raccoons were reported to be in cranial and thoracic lymph nodes, and numbers of acid-fast bacteria were low (Bruning-Fann et al., 2001), similar to the pattern described in the present study.

Fistulous tracts from *M. bovis* infected superficial lymph nodes have been noted

in other species such as brush-tailed possums (*Trichosurus vulpecula*; Jackson et al., 1995) and red deer (Lugton et al., 1998). Such lesions are thought to be responsible for much of the animal to animal transmission in red deer (Lugton et al., 1998). Although such lesions were only seen in the IV inoculated raccoons, the potential exists for such lesions in raccoons with severe disseminated tuberculosis.

Compared to other small mammalian hosts such as ferrets, raccoons are relatively resistant to *M. bovis* infection through oral exposure. A single oral dose of 5×10^6 CFU *M. bovis* fed to ferrets resulted in lesion development and isolation of *M. bovis* in nine of nine ferrets (Cross et al., 2000). Differences in strain of *M. bovis* used for inoculation may also be responsible for differences seen between these two hosts.

Detection of antigen specific antibody did not correlate well with infection status in orally inoculated raccoons in the present study. This may be due to the relatively short course of the study (118–125 days) and the development of lesions in only one to three sites in orally inoculated raccoons. Studies in humans (Lenzini et al., 1977), red deer (Griffin et al., 1991), and white-tailed deer (Palmer et al., 2000a) have found antibody assays most effective in identification of individuals with caseous or liquefactive lesions in multiple organs, generally in the later stages of disease. High levels of circulating antibody are thought to correlate with failure of the immune system to contain progression of the disease (Lenzini et al., 1977). This is supported by the significant antibody response in IV inoculated raccoons, all of which developed disseminated tuberculosis. It is unknown if orally inoculated raccoons would have eventually developed disseminated disease and an antibody response. Further research to determine the long-term outcome of oral inoculation of raccoons with *M. bovis* will be required.

The present study shows that after IV

inoculation of *M. bovis*, raccoons can develop severe disseminated tuberculosis with excretion of *M. bovis* in nasal secretions and saliva; therefore, potential does exist for transmission of *M. bovis* from severely affected raccoons to other susceptible hosts in isolated instances. However, consumption of large repeated doses of *M. bovis* was required to result in consistent infection from oral inoculation. Moreover, excretion of *M. bovis* was not a prominent feature of orally inoculated raccoons, suggesting that oral inoculation, which is most likely to occur in nature, is not likely to result in widespread tuberculosis among raccoons.

ACKNOWLEDGMENTS

The authors thank R. Lyon, J. Mentele, T. Rahner, and L. Dethloff for technical assistance and K. Lies, J. Lies, D. Robinson, L. Wright, D. Weuve, W. Varland, A. Lehmkühl, T. Wolfe, M. Knipper, and T. Krausman for animal care. The authors also thank A. Hamir for his helpful advice.

Names are necessary to report factually on available data, however, the USDA neither guarantees nor warrants the standard of the product, and the use of the name by USDA implies no approval of the product to the exclusion of others that may also be suitable.

LITERATURE CITED

- BASAK, D. K., P. SARKAR, M. K. NIYOGI, AND D. P. SAMANTA. 1976. Tuberculosis zoo animals in Calcutta. *Indian Veterinary Journal* 53: 667–669.
- BRUNING-FANN, C. S., S. M. SCHMITT, S. D. FITZGERALD, J. B. PAYEUR, D. L. WHIPPLE, T. M. COOLEY, T. CARLSON, AND P. FRIEDRICH. 1998. *Mycobacterium bovis* in coyotes from Michigan. *Journal of Wildlife Diseases* 34: 632–636.
- , S. M. SCHMITT, S. D. FITZGERALD, J. S. FIERKE, P. D. FRIEDRICH, J. B. KANEENE, K. A. CLARKE, K. L. BUTLER, J. B. PAYEUR, D. L. WHIPPLE, T. M. COOLEY, J. M. MILLER, AND D. P. MUZO. 2001. Bovine tuberculosis in free-ranging carnivores from Michigan. *Journal of Wildlife Diseases* 37: 58–64.
- COOKE, M. M., R. JACKSON, AND J. D. COLEMAN. 1993. Tuberculosis in a free-living brown hare (*Lepus europaeus occidentalis*). *New Zealand Veterinary Journal* 41: 144–146.
- , ———, ———, AND M. R. ALLEY. 1995. Naturally occurring tuberculosis caused by *Mycobacterium bovis* in brushtail possums (*Trichosurus vulpecula*): II. Pathology. *New Zealand Veterinary Journal* 43: 315–321.
- COSTELLO, E., M. L. DOHERTY, M. L. MONAGHANE, F. C. QUIGLEY, AND P. F. O'REILLY. 1998. A study of cattle to cattle transmission of *Mycobacterium bovis*. *Veterinary Journal* 155: 245–250.
- CROSS, M. L., R. E. LABES, AND C. G. MACKINTOSH. 2000. Oral infection of ferrets with virulent *Mycobacterium bovis* or *Mycobacterium avium*: Susceptibility, pathogenesis and immune response. *Journal of Comparative Pathology* 123: 15–21.
- DUNKIN, G. W., P. P. LAIDLAW, AND A. S. GRIFFITH. 1929. A note on tuberculosis in the ferret. *Journal of Comparative Pathology and Therapeutics* 42: 46–49.
- GILL, J. W., AND R. JACKSON. 1993. Tuberculosis in a rabbit: A case revisited. *New Zealand Veterinary Journal* 41: 147.
- GRIFFIN, J. F. T., S. NAGAI, AND G. S. BUCHAN. 1991. Tuberculosis in domesticated red deer: Comparison of purified protein derivative and the specific protein MPB70 for in vitro diagnosis. *Research in Veterinary Science* 50: 279–285.
- GRIFFITH, A. S. 1939. Infections of wild animals with tubercle bacilli and other acid fast bacilli. *Proceeding of the Royal Society of Medicine* 32: 1405–1412.
- JACKSON, R., M. M. COOKE, J. D. COLEMAN, R. S. MORRIS, G. W. DE LISLE, AND G. F. YATES. 1995. Naturally occurring tuberculosis caused by *Mycobacterium bovis* in brushtail possums (*Trichosurus vulpecula*): III. Routes of infection and excretion. *New Zealand Veterinary Journal* 43: 322–327.
- JOON, L. 1976. The pathogenicity of various mycobacteria on the Korean chipmunk (*Eutamias sibiricus asiaticus*). *International Journal of Leprosy and Other Mycobacterial Diseases* 44: 539–540.
- KAUFMANN, J. H. 1982. Raccoon and allies. In *Wild mammals of North America, Biology, management, and economics*. J. A. Chapman and G. A. Feldhamer (eds.). Johns Hopkins University Press, Baltimore, Maryland, pp. 567–585.
- LITTLE, T. W. A., P. F. NAYLOR, AND J. W. WILESMITH. 1982. Laboratory study of *Mycobacterium bovis* infection in badgers and calves. *Veterinary Record* 111: 550–557.
- LENZINI, L., P. ROTTOLI, AND L. ROTTOLI. 1977. The spectrum of human tuberculosis. *Clinical and Experimental Immunology* 27: 230–237.
- LUGTON, I. W., A. C. JOHNSTONE, AND R. S. MORRIS. 1995. *Mycobacterium bovis* infection in New Zealand hedgehogs (*Erinaceus europaeus*). *New Zealand Veterinary Journal* 43: 342–345.
- , P. R. WILSON, R. S. MORRIS, AND G. NUGENT. 1998. Epidemiology and pathogenesis of *Mycobacterium bovis* infection of red deer (*Cervus*

- elaphus*) in New Zealand. New Zealand Veterinary Journal 46: 147–156.
- MCCOY, G. W. 1911. Tuberculosis among ground squirrels (*Citellus beecheyi*). Journal of Medical Research 25: 189–198.
- MECH, L. D., AND F. J. TURKOWSKI. 1966. Twenty-three raccoons in one winter den. Journal of Mammalogy 47: 529–530.
- PALMER, D. L., WHIPPLE, S. C. OLSEN, AND R. H. JACOBSON. 2000a. Cell mediated and humoral immune responses of white-tailed deer experimentally infected with *Mycobacterium bovis*. Research in Veterinary Science 68: 95–98.
- , ———, D. L. WHIPPLE, J. B. PAYEUR, D. P. ALT, K. J. ESCH, C. S. BRUNING-FANN, AND J. B. KANEENE. 2000b. Naturally occurring tuberculosis in white-tailed deer. Journal of the American Veterinary Medical Association 216: 1921–1924.
- , D. L. WHIPPLE, AND W. R. WATERS. 2001. Experimental deer to deer transmission of *Mycobacterium bovis*. American Journal of Veterinary Research 62: 692–696.
- PULLING, F. B. 1952. An outbreak of bovine tuberculosis in mink and treatment with rimifon. Journal of the American Veterinary Medical Association 121: 389–390.
- RAGG, J. R., H. MOLLER, AND K. A. WALDRUP. 1995. The prevalence of bovine tuberculosis (*Mycobacterium bovis*) infections in feral populations of cats (*Felis catus*), ferrets (*Mustela furo*), and stoats (*Mustela erminea*) in Otago and Southland, New Zealand. New Zealand Veterinary Journal 43: 333–337.
- SCHMITT, S. M., S. D. FITZGERALD, T. M. COOLEY, C. S. BRUNING-FANN, L. SULLIVAN, D. BERRY, T. CARLSON, R. B. MINNIS, J. B. PAYEUR, AND J. SIKARSKIE. 1997. Bovine tuberculosis in free-ranging white-tailed deer from Michigan. Journal of Wildlife Diseases 33: 749–758.
- SHEEHAN, D. C., AND B. B. HRAPCHAK. 1980. Microorganisms. In Theory and practice of histotechnology, 2nd Edition. Mosby Publishing Co., St. Louis, Missouri, pp. 233–251.
- THORNS, C. J., J. A. MORRIS, AND T. W. A. LITTLE. 1982. A spectrum of immune responses and pathological conditions between certain animal species to experimental *Mycobacterium bovis* infection. British Journal of Experimental Pathology 63: 562–572.

Received for publication 16 May 2001.