

Reticuloendotheliosis in Hungarian Partridge

Authors: Trampel, D. W., Pepper, T. M., and Witter, Richard L.

Source: Journal of Wildlife Diseases, 38(2) : 438-442

Published By: Wildlife Disease Association

URL: <https://doi.org/10.7589/0090-3558-38.2.438>

BioOne Complete (complete.BioOne.org) is a full-text database of 200 subscribed and open-access titles in the biological, ecological, and environmental sciences published by nonprofit societies, associations, museums, institutions, and presses.

Your use of this PDF, the BioOne Complete website, and all posted and associated content indicates your acceptance of BioOne's Terms of Use, available at www.bioone.org/terms-of-use.

Usage of BioOne Complete content is strictly limited to personal, educational, and non - commercial use. Commercial inquiries or rights and permissions requests should be directed to the individual publisher as copyright holder.

BioOne sees sustainable scholarly publishing as an inherently collaborative enterprise connecting authors, nonprofit publishers, academic institutions, research libraries, and research funders in the common goal of maximizing access to critical research.

Reticuloendotheliosis in Hungarian Partridge

D. W. Trampel,^{1,4} T. M. Pepper,² and Richard L. Witter^{3,1} Department of Veterinary Diagnostics and Production Animal Medicine, Iowa State University, Ames, Iowa 50011, USA; ² Bessey Microscopy Facility, Department of Biotechnology & Life Sciences, Iowa State University, Ames, Iowa 50011, USA; ³ USDA-ARS, Avian Disease and Oncology Laboratory, East Lansing, Michigan 48823 USA; ⁴ Corresponding author (email: dtrampel@iastate.edu).

ABSTRACT: A large commercial flock of Hungarian partridge (*Perdix perdix*) experienced elevated mortality associated with a wasting disease in May 1998. Postmortem examination of females consistently revealed a distended crop and abnormal gray-white tissue infiltrating the wall of the crop and thoracic esophagus. Neoplasia in male partridge was observed in the liver. Microscopic examination of the crop and thoracic esophagus revealed transmural masses of immature lymphocytes with frequent mitotic figures. Similar cells were observed in the liver of affected males. Virus particles consistent in size and morphology with reticuloendotheliosis virions were observed in neoplastic lymphoid cells via electron microscopy. Reticuloendotheliosis virus was isolated from each of four blood samples. This disease has not previously been reported in Hungarian partridges. Hungarian partridge may represent a potential reservoir of infection for other gamebirds, including prairie chickens.

Key words: Case report, neoplasia, *Perdix perdix*, reticuloendotheliosis.

Reticuloendotheliosis is a neoplastic disease caused by a group of retroviruses that are unrelated antigenically, morphologically, or structurally to avian leukosis viruses (Witter, 1997). Multiple strains of reticuloendotheliosis virus (REV) exist but all belong to a single serotype. Reticuloendotheliosis virus has a world-wide distribution and serologic surveys conducted in several countries have detected antibodies against this virus in 3.3–25% of chicken flocks (Bagust, 1993). One virus in the group, strain REV-T which has been isolated from turkeys, is a replication-defective transforming virus containing a viral transforming oncogene (v-rel) that causes acute neoplasia (Witter, 1997). All other REVs examined to date are nondefective and cause lymphomas after a long latent period and/or immunosuppression combined with stunting. Nondefective REVs

and their natural hosts include duck infectious anemia virus, chick syncytial virus, and spleen necrosis virus of ducks (Witter, 1997).

The Hungarian partridge (*Perdix perdix*) is also known as gray partridge, European partridge, and English partridge (Potts, 1986). This game bird has been widely and successfully introduced from Europe and can be found on the northern plains and prairie regions of the North American continent (Aebisher, 1997). Partridge from the commercial aviculture enterprise described in this report were raised to provide feathers for fishing lures and for food.

Reticuloendotheliosis has been reported in game birds. Neoplastic lesions were described in subcutaneous tissue and internal organs of captive greater prairie chickens (*Tympanuchus cupido pinnatus*) (Drew et al., 1998), Attwater's prairie chickens (*Tympanuchus cupido attwateri*) (Drew et al., 1998), and ring-necked pheasants (*Phasianus colchicus*) (Dren, 1983). In addition, nodules along the digestive tract combined with neoplastic lesions in other internal organs have been reported in Japanese quail (*Coturnix coturnix japonica*) (Schat et al., 1976). This paper describes the first documented case of reticuloendotheliosis in Hungarian partridge.

In May 1998, two captive male Hungarian partridges were submitted to Iowa State University (Ames, Iowa, USA) for diagnostic assistance. The problem was persistent mortality within the breeding flock and affected partridges tended to lose weight and waste away prior to death. Subsequent investigation and examination of additional birds at the breeding farm indicated that more females were affected



FIGURE 1. Female Hungarian partridge with markedly distended crop.

than males. Female partridges continued to eat and drink water but became progressively emaciated and developed markedly enlarged crops that eventually would drag on the floor of their cage.

The breeding flock consisted of 1,600 pairs of Hungarian partridge with one male and one female in a cage. The top of each cage consisted of a sheet metal roof and the back of the cage had a solid wooden wall and floor where nesting occurred. The front, sides, and remainder of the floor were made of wire mesh. All male and female partridges were slightly more than 1 yr old. Approximately 12 hens (0.75% of all hens) died from this wasting disease within the preceding 12 mo. Mortality among male birds was rare and was not associated with an enlarged crop.

Postmortem examinations were performed on four male and six female partridges. The liver and spleen of male birds was slightly enlarged and pale. The crop of female partridges was markedly distended by mucus, feed, and water (Fig. 1). The thoracic esophageal wall between the crop and the proventriculus was thickened and gray-white in color. There was no evidence of any obstruction distal to the thoracic esophagus.

Microscopic examination of formalin-fixed crop and thoracic esophagus from female partridges revealed nodular to diffuse, dense transmural infiltration of immature lymphocytes that extended from the tunica propria immediately beneath

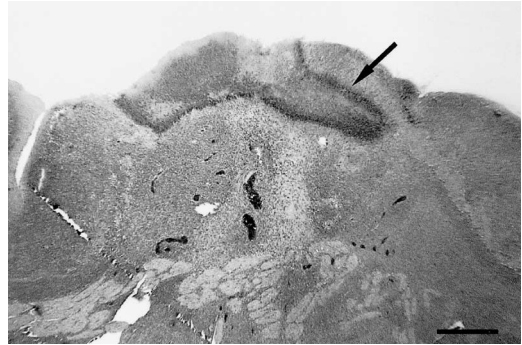


FIGURE 2. Diffuse and dense transmural infiltration of immature lymphocytes in the thoracic esophagus. A focal area of necrosis is present on the ulcerated mucosal surface (arrow). Neoplastic cells are present between smooth muscle bundles of the muscularis externa near the serosal surface. HE. Bar = 116 μ m.

the surface epithelium through all layers of the crop wall to the loose adventitial connective tissue external to the smooth muscle layers of the muscularis externa (Fig. 2). Mucosal stratified squamous epithelium was focally ulcerated, and ulcers were covered by necrotic cell debris enmeshed in fibrin. Immature lymphocytes diffusely distributed in the lamina propria were enmeshed within and surrounded by stromal connective tissue fibers. Nodular lesions in the lamina propria were devoid of connective tissue stromal fibers and consisted entirely of neoplastic immature lymphoid cells. These cells had large round to oval vesicular nuclei with prominent chromatin clumps adjacent to the inner surface of the nuclear envelope (Fig. 3). Each cell had moderate to abundant pale basophilic cytoplasm. Mitotic figures were numerous and an occasional cell was undergoing lysis. Hepatic tissue from male partridges contained wide bands of neoplastic cells morphologically indistinguishable from those in the crop of female partridges. These cells infiltrated the connective tissue stroma surrounding central veins and portal triads. Histologic examination was limited to macroscopically abnormal tissues so the existence of neoplastic cells in other tissues is unknown.

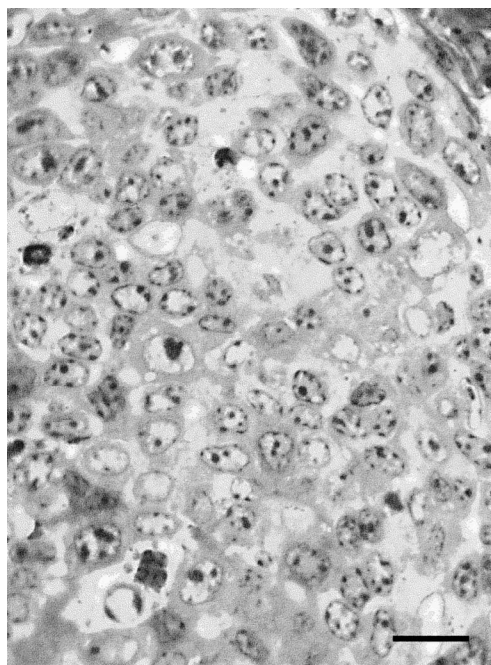


FIGURE 3. Lymphoblasts with large round to oval vesicular nuclei. Toluidine blue. Bar = 24 μ m.

Transmission electron microscopy was used to examine neoplastic cells in the crop wall. Crop fixed in 10% neutral buffered formalin was rinsed (3 times, 15 min each step) and placed into 2% paraformaldehyde, 2% glutaraldehyde in phosphate buffered saline (PBS; pH 7.2). Samples were rinsed in PBS (3 times, 15 min each rinse) and post-fixed with 1% osmium tetroxide in PBS for 1.5 hr at room temperature. Samples were washed in PBS, dehydrated in a graded ethanol series, substituted into pure acetone, infiltrated and embedded using Embed 812 epoxy resin (Electron Microscopy Sciences, Ft. Washington, Pennsylvania, USA), and polymerized at 70 C for 48 hr. Thick and ultra-thin sections were made using a Reichert Ultracut S ultramicrotome (SciScope, Iowa City, Iowa). Thick sections (1.5 μ m) were stained with 1% toluidine blue stain and images captured using a Leitz Orthoplan light microscope (SciScope). Ultra-thin sections (60–90 nm) were collected onto copper grids and counter-stained using 5% uranyl acetate in

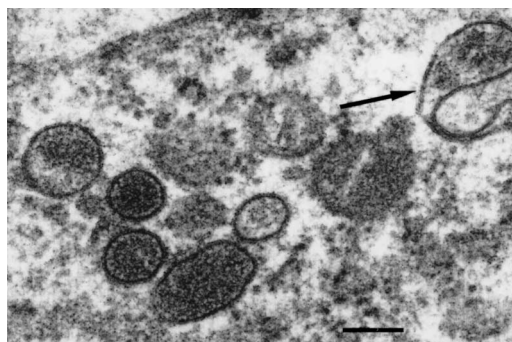


FIGURE 4. Electron micrograph of mature reticuloendotheliosis virions. A uniform space is present between the viral core and the viral envelope. A budding virus particle consisting of electron dense nucleocapsid material at the end of a delicate stalk is shown in sagittal section (arrow). Uranyl acetate and Sato's lead stain. Bar = 157 nm.

50% methanol for 20 min followed by Sato's lead stain for 10 min. Negative images were made using a JEOL 1200EX scanning and transmission electron microscope (Japan Electron Optics Laboratories, Akishima, Japan) and were scanned using a UMAX Powerlook 3000 scanner (UMAX, Data Systems, Inc., Hsinchu, Taiwan) for further image processing.

Virus particles were observed within tumor cells from the wall of the crop and thoracic esophagus (Fig. 4). These particles were round, approximately 110–120 nm in diameter, and had a uniform space between the outer edge of the electron-dense core and the inner edge of the viral envelope. Some cores had a polygonal shape and, in some sections, regularly spaced small electron-dense structures suggestive of peplomers were observed in association with the viral envelope. These particles were consistent in size and morphology with previously published descriptions of REV (Kang et al., 1975).

Attempts were made to isolate Marek's disease virus (MDV), exogenous avian leukosis virus (ALV), and REV at the Avian Disease and Oncology Laboratory (ADOL; East Lansing, Michigan, USA) from heparinized blood samples taken from four female tumor-bearing Hungarian partridges.

For MDV isolations about 10^6 buffy coat cells were inoculated onto secondary monolayer cultures of duck embryo fibroblasts (DEF) or line 0 chicken embryo fibroblasts (resistant to subgroup E endogenous viruses). The embryos were from breeders maintained at the ADOL that tested negative for exogenous avian retroviruses and other common pathogens. The DEF cultures were examined for herpesvirus plaques after 8 and 13 days. The line 0 cell cultures were used for ALV and REV isolation. Following a culture period of 8 days, part of the line 0 cultures were evaluated for ALV group specific antigen (gp27) by enzyme linked immunosorbent assay (Fadly and Witter, 1998). The remaining line 0 cultures were stained with monoclonal antibody 11A25 against REV by indirect immunofluorescence. Antibody 11A25 is produced at the ADOL. A second passage of supernatant fluids from the line 0 cultures was done and also stained for REV antigens. Reticuloendotheliosis virus was isolated from all four blood samples. Marek's disease virus and exogenous ALV were not isolated from any of the samples.

A consistent feature of reticuloendotheliosis in female Hungarian partridges in this outbreak was the presence of neoplastic immature lymphocytes within the wall of the crop and thoracic esophagus. Lymphoid neoplasia in the walls of the crop, proventriculus, and intestines have previously been reported in quail (Carlson et al., 1974) and pheasants (Dren et al., 1983). Reticuloendotheliosis virus infection has been associated with bursal and nonbursal lymphomas (Witter, 1997). Bursal lymphomas are of B-cell origin, as indicated by the presence of surface IgM, develop after a long latent period, and may be found in the bursa of Fabricius. Nonbursal lymphomas are believed to be of T-cell origin, have a latent period as short as 6 wk, are not associated with bursal lesions, and may be accompanied by enlarged peripheral nerves infiltrated by large lymphoid cells (Witter et al., 1986).

The mechanism of oncogenesis for bursal and nonbursal lymphomas is by insertion of the REV provirus into the target cell genome and activation of *c-myc* (Witter, 1997). Both B and T lymphocytes can be target cells for neoplastic transformation (Sasaki and Koyama, 1989; Schat et al., 1992).

It is noteworthy that all blood samples from female partridge with neoplasia in the crop and esophagus were viremic for REV at the same time. If chickens become infected by contact with REV in the environment (such as virions shed in feces), viremia is very short followed by seroconversion and only rarely do tumors develop (Witter, 1997). Thus, it is difficult to find viremic birds. On the other hand, if the virus is transmitted congenitally, birds infected as embryos usually remain viremic for life, do not develop antibodies, and shed virus in their feces. Congenital transmission is more frequent in hens with low antibody titers and tolerant hens frequently develop tumors and shed REV in the albumin of nearly all eggs laid (Witter, 1997). Congenital transmission probably accounts for the high prevalence of viremia in the female Hungarian partridge described in this report.

Wasting disease was not observed in this flock prior to 1994 when an outbreak of avian pox occurred. The flock was subsequently immunized with a commercial quailpox vaccine and later revaccinated with a commercial fowlpox vaccine. Transmission of REV via contaminated fowlpox vaccines has been documented in turkeys and chickens (Fadly et al., 1996; Fadley and Witter, 1997). Field and vaccine strains of fowlpox viruses from Australia, Europe, and the United States have been shown to carry sequences of the REV genome integrated into the fowlpox virus DNA (Hertig et al., 1997). Some pox viruses carry near full-length REV provirus sequences which can generate fully infectious virions when the contaminated pox virus is injected into susceptible chickens. Chickens infected by this mechanism de-

velop an active antibody response against REV. Reticuloendotheliosis may have been introduced into the partridge flock by mosquitoes carrying a field strain of avian pox virus containing an REV provirus or from a contaminated fowlpox vaccine.

Hungarian partridge may represent a potential reservoir of infection for other upland game birds. These birds share habitat on farmlands and grassy fields of the northern plains with the greater prairie chicken, sharp-tailed grouse (*Tympanuchus phasianellus*), bobwhite quail (*Colinus virginianus*), ring-necked pheasant, and wild turkeys (*Meleagris gallopavo*) (Allen et al., 1983). Horizontal transmission of REV may occur following dissemination of infectious virus in feces of infected birds (Witter, 1997) or by blood-sucking insects, such as mosquitoes (Bagust, 1993). The susceptibility of prairie chickens, pheasants, and turkeys to REV has been reported (Dren, 1983; Witter, 1997; Drew et al., 1998).

LITERATURE CITED

- AEBISCHER, N. J. 1997. Gamebirds: Management of the grey partridge in Britain. In *Conservation and the use of wildlife resources*, M. Bolton (ed.). Chapman & Hall, London, UK, pp. 131–151.
- ALLEN, T. B., W. BARRET, S. L. FISHBEIN, P. KOPPER, E. LANOUE, D. F. ROBINSON, R. D. SELIM, AND J. B. TOURTELLOTT. 1983. In *Field guide to the birds of North America*, S. L. Scott (ed.). National Geographic Society, Washington, D.C., pp. 214–222.
- BAGUST, T. J. 1993. Reticuloendotheliosis virus. In *Virus infections of vertebrates*, 4. Virus infections of birds, J. B. McFerran and M. S. McNulty (eds.). Elsevier Science Publishers, B. V. Amsterdam, The Netherlands, pp. 437–454.
- CARLSON, H. C., G. L. SEAWRIGHT, AND J. R. PETTIT. 1974. Reticuloendotheliosis in Japanese quail. *Avian Pathology* 3: 169–175.
- DREN, C. N., E. SAGHY, R. GLAVITS, F. RATZ, J. PING, AND V. SZTOJKOV. 1983. Lymphoreticular tumor in pen-raised pheasants associated with a reticuloendotheliosis like virus infection. *Avian Pathology* 12: 55–71.
- DREW, M. L., W. L. WIGLE, D. L. GRAHAM, C. P. GRIFFIN, N. J. SILVEY, A. M. FADLY, AND R. L. WITTER. 1998. Reticuloendotheliosis in captive greater and Attwater's prairie chickens. *Journal Wildlife Diseases* 34: 783–791.
- FADLY, A. M., AND R. L. WITTER. 1997. Comparative evaluation of in vitro and in vivo assays for the detection of reticuloendotheliosis virus as a contaminant in a live virus vaccine of poultry. *Avian Diseases* 41: 695–701.
- , AND ———. 1998. Oncornaviruses: Leukosis/sarcoma and reticuloendotheliosis. In *A laboratory manual for the isolation and identification of avian pathogens*, J. R. Glisson, D. J. Jackwood, J. E. Pearson, W. M. Reed and D. E. Swayne (eds.). American Association of Avian Pathologists, Kennett Square, Pennsylvania, pp. 185–196.
- , ———, E. J. SMITH, R. F. SILVA, W. M. REED, F. J. HOERR, AND M. R. PUTNAM. 1996. An outbreak of lymphomas in commercial broiler breeder chickens vaccinated with a fowl pox vaccine contaminated with reticuloendotheliosis virus. *Avian Pathology* 25: 35–47.
- HERTIG, C., B. E. H. COUPAR, A. R. GOULD, AND D. B. BOYLE. 1997. Field and vaccine strains of fowlpox virus carry integrated sequences from the avian retrovirus, reticuloendotheliosis virus. *Virology* 235: 367–37.
- KANG, C. Y., T. C. WONG, AND K. V. HOLMES. 1975. Comparative ultrastructural study of four reticuloendotheliosis viruses. *Journal Virology* 16: 1027–1038.
- POTTS, G. R. 1986. The partridge: Pesticides, predation, and conservation. William Collins Sons & Co. Ltd., London, UK, pp. 1–2.
- SASAKI, T., AND H. KOYAMA. 1989. Characterization of cell lines transformed in vivo and in vitro by reticuloendotheliosis virus-T strain. *Avian Pathology* 18: 307–319.
- SCHAT, K. A., J. GONZALEZ, A. SOLORZANO, E. AVILA, AND R. L. WITTER. 1976. A lymphoproliferative disease in Japanese quail. *Avian Diseases* 20: 153–161.
- , W. D. PRATT, R. MORGAN, D. WEINSTOCK, AND B. W. CALNEK. 1992. Stable transfection of reticuloendotheliosis virus-transformed lymphoblastoid cell lines. *Avian Diseases* 36: 432–439.
- WITTER, R. L. 1997. Reticuloendotheliosis. In *Diseases of poultry*, 10th Edition, B. W. Calnek, H. J. Barnes, C. W. Beard, L. R. McDougald and Y. M. Saif (eds.). Iowa State University Press, Ames, Iowa, pp. 467–484.
- , J. M. SHARMA, AND A. M. FADLY. 1986. Nonbursal lymphomas induced by nondefective reticuloendotheliosis virus. *Avian Pathology* 15: 467–486.

Received for publication 27 December 2000.