

## **MEDICAL DILEMMAS ASSOCIATED WITH REHABILITATING CONFISCATED HOUBARA BUSTARDS (CHLAMYDOTIS UNDULATA MACQUEENII) AFTER AVIAN POX AND PARAMYXOVIRUS TYPE 1 INFECTION**

Authors: Bailey, Thomas A., Silvanose, Christudas, Manvell, Ruth, Gough, Richard E., Kinne, Joerg, et al.

Source: Journal of Wildlife Diseases, 38(3) : 518-532

Published By: Wildlife Disease Association

URL: <https://doi.org/10.7589/0090-3558-38.3.518>

---

BioOne Complete ([complete.BioOne.org](https://complete.BioOne.org)) is a full-text database of 200 subscribed and open-access titles in the biological, ecological, and environmental sciences published by nonprofit societies, associations, museums, institutions, and presses.

Your use of this PDF, the BioOne Complete website, and all posted and associated content indicates your acceptance of BioOne's Terms of Use, available at [www.bioone.org/terms-of-use](https://www.bioone.org/terms-of-use).

Usage of BioOne Complete content is strictly limited to personal, educational, and non - commercial use. Commercial inquiries or rights and permissions requests should be directed to the individual publisher as copyright holder.

---

BioOne sees sustainable scholarly publishing as an inherently collaborative enterprise connecting authors, nonprofit publishers, academic institutions, research libraries, and research funders in the common goal of maximizing access to critical research.

## MEDICAL DILEMMAS ASSOCIATED WITH REHABILITATING CONFISCATED HOUBARA BUSTARDS (*CHLAMYDOTIS UNDULATA MACQUEENII*) AFTER AVIAN POX AND PARAMYXOVIRUS TYPE 1 INFECTION

Thomas A. Bailey,<sup>1,4</sup> Christudas Silvanose,<sup>1</sup> Ruth Manvell,<sup>2</sup> Richard E. Gough,<sup>2</sup> Joerg Kinne,<sup>3</sup> Olivier Combreau,<sup>1</sup> and Fred Launay<sup>1</sup>

<sup>1</sup> National Avian Research Center, Environmental Research and Wildlife Development Agency, PO Box 45553, Abu Dhabi, United Arab Emirates

<sup>2</sup> Veterinary Laboratories Agency (Weybridge), New Haw, Addlestone, Surrey, United Kingdom KT15 3NB

<sup>3</sup> Central Veterinary Research Laboratory, PO Box, Dubai, United Arab Emirates

<sup>4</sup> Corresponding author (email: drtombailey@hotmail.com)

**ABSTRACT:** Projects to rehabilitate confiscated animals must carefully consider the risks of disease when determining whether to release these animals back into the wild or to incorporate them into captive breeding programs. Avipox and paramyxovirus type 1 (PMV-1) infections are important causes of morbidity and mortality during rehabilitation of confiscated houbara bustards (*Chlamydotis undulata macqueenii*). This paper presents key findings of an intensive health monitoring program (physical condition, hematology, serology, endoscopy, microbiology, and virology) of two flocks of houbara bustards that survived outbreaks of septicemic avipox and PMV-1 respectively. Mortality in each flock from avipox and PMV-1 infections were 47% and 25% respectively, and the clinicopathologic features and management of each outbreak are presented. Avipox and PMV-1 viruses were not isolated from surviving birds monitored monthly for 11 mo after initial infection nor were septicemic or diphtheritic avipox and PMV-1 infections detected in the captive breeding collection into which surviving birds were ultimately integrated up to 24 mo later. Adenovirus was isolated from four birds during the study demonstrating that novel disease agents of uncertain pathogenicity may be carried latently and intermittently shed by confiscated birds. This paper demonstrates the risk of importing pathogens with illegally traded houbara bustards and reinforces the need for surveillance programs at rehabilitation centers for these birds. We recommend that confiscated houbara bustards integrated into captive breeding programs be managed separately from captive-bred stock. Other measures should include separate facilities for adult birds and rearing facilities for offspring derived from different stock lines and strict sanitary measures. Additionally, health monitoring of confiscated birds should continue after birds are integrated into captive flocks.

**Key words:** Avipox, disease, health monitoring, Houbara bustard, paramyxovirus type 1, quarantine, rehabilitation.

### INTRODUCTION

The houbara bustard (*Chlamydotis undulata macqueenii*) has a high conservation profile because it is the traditional quarry of falconers in Arabia and a number of regional conservation projects have been initiated by influential Arab falconers to safeguard the bustard and their tradition (Launay et al., 1999). There are few reliable data on the exact status of houbara bustard populations in the wild but they are generally considered to have declined over most of their range during the last few decades (Collar, 1996; Goriup, 1997).

There is a large illegal trade in houbara bustards which are trapped in Pakistan,

Iran, and Afghanistan and exported to the Middle East where they are used by some falconers to train their falcons. It has been suggested that 4,000–7,000 houbaras are traded annually in this way from Pakistan alone (Goriup, 1997). Mortality of birds transported to the Middle East is high and this trade may have more impact on the status of the houbara bustard than direct hunting with falcons (Bailey et al., 2000).

In 1998 initiatives were taken in the Emirates of Abu Dhabi and Sharjah to confiscate illegally imported houbara bustards when they entered the United Arab Emirates (UAE), while in Pakistan government agencies confiscate birds as they are smuggled out of the country through air

and seaports. Attempts to rehabilitate and release these birds back into suitable habitats also have been initiated in Pakistan (Ahmed, 1997) and in the UAE at the National Avian Research Center (NARC) of the Environmental Research and Wildlife Development Agency (Bailey et al., 2000).

Any release of confiscated wild animals must include screening and monitoring to address potential negative impacts, as set forth in the International Union for the Conservation of Nature (IUCN) Guidelines for Reintroductions and Confiscated Animals (IUCN, 1995, 2000). There is an increasing demand and urgent need for information and advice on veterinary considerations relating to responsible placement of confiscated wildlife (IUCN, 2000). In a recent paper (Bailey et al., 2000), the diseases occurring in confiscated houbara bustards in the Middle East were reviewed. One of the recommendations was that investigations to monitor the health of houbara bustards that have survived avian viral infections should be initiated.

In 1998 two consignments of illegally traded houbara bustards were confiscated in Abu Dhabi and sent to the NARC quarantine facility for rehabilitation. After their arrival avipox and paramyxovirus type 1 (PMV-1) infections were diagnosed; a health-monitoring program of surviving birds was initiated to follow the recovery from each disease. This paper presents the key findings of the disease outbreaks and monitoring programs for each flock. Such data allow greater understanding of the disease risks associated with any future use of rehabilitated birds and provides a case study that may be useful to other rehabilitation projects.

## MATERIALS AND METHODS

### Background and clinicopathologic investigations

In October 1998 two consignments of houbara bustards (Groups A and B) entered the quarantine unit of NARC (24°N, 55°E, Sweihan, Abu Dhabi Emirate) where they were housed in separate wards. The birds originated from Pakistan. On arrival all birds were given antiparasitic treatments for endoparasites and

trichomoniasis including dimetridazole 3 g/10l water (Emtryl 40% Soluble for Game Birds, Merial Animal Health Ltd., Harlow, Essex, UK), ivermectin 200 µg/kg by intramuscular injection (Ivomec, Merial Animal Health Ltd., UK), and praziquantel 10 mg/kg orally (Droncit tablets, Bayer, Bury St Edmunds, Suffolk, UK). The birds were fed a proprietary bustard maintenance pellet (15.24% protein) offered ad libitum supplemented with mealworm larvae (*Tenebrio molitor*) and cultured mice. Fresh water was provided ad libitum. A soluble multivitamin 1 g/l (Solvit, Micro-Biologicals, Bury St Edmunds) was added to the water.

Within days after arrival, outbreaks of septemic avian pox and PMV-1 infections were diagnosed in Groups A and B respectively. Diagnostic investigations to confirm these diseases included bacteriology, mycology, histopathology, virus isolation, hematology, parasitology, and serology.

### The health monitoring program

On arrival Group A (15 male, 19 female) and Group B (seven male, 17 female) birds were kept in separate quarantine wards. The design and management of the quarantine unit were described by Naldo et al. (1997). After disease outbreaks Group A comprised 13 avipox survivors and Group B comprised 15 PMV-1 infection survivors. Each group was split into flocks of four to six individuals in 3×3 m rooms. After 6 mo six birds from each group were incorporated into the captive bustard collection. Six mo later the remaining birds were similarly incorporated into the captive flock.

### The health monitoring protocol

Birds were examined on arrival, weekly during disease outbreaks, and monthly from December 1998 to October 1999. While the birds were in the quarantine facility monthly health screening examinations included: physical condition assessment and weight (Groups A and B); blood collection for hematology (Groups A and B); blood collection for PMV-1 serology on arrival (Groups A and B); monthly blood collection for PMV-1 serology (Group B); and choanal and cloacal swabs for virus isolation (Groups A and B). Swabs were placed in virus transport media (minimum essential medium containing penicillin, streptomycin, and nystatin, GIBCO Life Technologies, Paisley, Scotland) and frozen at -20 C. Samples were submitted for virus isolation within 3 mo. Blood was collected for avipox serology (Group A) at arrival, 1, 2, 3, 6, 10, and 11 mo and cloacal swabs were taken for aerobic microbiology (Groups A and B) at 2, 6, and 11 mo. Swabs

were collected in Amies charcoal transport medium (Medical Wire and Equipment Co. Ltd, Bath, UK). Choanal swabs were collected for *Chlamydiophila* sp. antigen enzyme-linked immunosorbent assay (ELISA) (Groups A and B) at arrival, 2, 6, and 11 mo, and endoscopy was conducted on left and right sides according to the method described by Samour (1999) at 2 and 11 mo (Groups A and B). Swabs and biopsies of lesions collected during endoscopy were submitted for aerobic bacteriology and fungal culture. Pooled fecal samples were collected for parasitology (Groups A and B) at arrival, 2, 6, and 11 mo. Post-quarantine surveillance and clinical and post-mortem data from the captive flock were reviewed 12 mo after Group A and B birds were integrated with the NARC collection.

#### Laboratory investigations

Aerobic bacteriology (Silvanose et al., 1998), hematology (Samour et al., 1994) PMV-1 antibody ELISA (Svanova Biotech, S-751 83 Uppsala, Sweden) and *Chlamydiophila* sp. antigen ELISA (Ideia, Dako Diagnostics Ltd., Ely, UK) were analyzed according to the manufacturer's instructions at NARC. The methodology for the PMV-1 ELISA was described by Czifra et al. (1996). The Svanova PMV-1 antibody ELISA is based on a monoclonal antibody blocking ELISA which was developed and evaluated for the detection of PMV-1 specific antibodies from any species (Czifra et al., 1996). Samples with a percentage inhibition (PI) >40% were considered positive for antibodies to PMV-1. Samples with a PI between 30–40% were considered borderline cases. Samples with PI ≤30% are considered negative for antibodies to PMV-1. Virus isolation, virus characterization, avipox agar gel precipitation (AGP) (Gough et al., 1988; Alexander et al., 1997), and salmonellae typing were conducted at the Veterinary Laboratories Agency (VLA, New Haw, UK). Histopathology was performed at the Central Veterinary Research Laboratory (CVRL, Dubai, UAE).

#### Statistical analyses

Statistical analyses were conducted using Medcalc software (Medcalc software, Broekstraat 52, Belgium). A difference of  $P < 0.05$  was considered significant. Differences in hematology values between abnormal Group A and B birds and clinically normal birds were analyzed for statistical significance with the unpaired Student's *t*-test. Hematology data from clinically normal birds was derived from the original raw results kindly provided by Dr. J. Samour (Samour et al., 1994). Differences in mortality

between males and females in each group were analyzed for statistical significance with the chi-square test. The difference in weight on arrival between male and female birds that died and male and female birds that survived were analyzed for statistical significance with the unpaired Student's *t*-test.

## RESULTS

### Management of pox and PMV-1 outbreaks

At the outset of mortality both Groups were given enrofloxacin 200 mg/l water (Baytril 10% oral solution, Bayer) until a week after mortality had ended in each group. Group A birds with pox were administered parenteral antibiotics and multivitamins. Birds with oropharyngeal lesions were given supplementary alimentation (Polyaid, Vetafarm, Wagga Wagga, Australia) and oral and parenteral fluid therapy (Bailey, 1999). Electrical and chemical cautery of pox lesions were conducted. Nine birds with lesions recovered. Cases with severe papillomatous lesions were euthanized. Surviving birds were given an inactivated PMV-1 vaccine (Newcavac Nobilis, Intervet UK Ltd, Cambridge, UK) at 1 ml/kg subcutaneously 6 wks after arrival.

Group B birds which developed central nervous system signs suggestive of PMV-1 infection were euthanized within 48 hrs of showing clinical signs and when there was no response to parenteral antibiotics, multivitamins, and fluid therapy. Surviving birds were given a live canary pox vaccine (Poulvac P Canary, Duphar, Holland) administered via the wing web 6 wks after arrival.

### Background and clinicopathologic findings

The key features of the outbreaks of pox and PMV-1 infections are presented in Table 1. On arrival of Group A birds, soft tissue traumatic injuries (wingtip and keel abrasions) were observed in 10 birds (29%). Typical clinical signs of avipox infection were seen in 19 of 34 (56%) Group A birds. Signs included choanal and/or conjunctival inflammation (four), diphtheritic oropharyngeal/choanal lesions (10),

TABLE 1. Key features of the outbreak of avian pox and paramyxovirus type 1 (PMV-1) infections in houbara bustards.

	Group A (Pox virus infected)	Group B (PMV-1)
Number of birds	34	24
Morbidity (% with clinical signs) <sup>a</sup>	19 (56%)	5 (21%)
Total confirmed cases (%)	25 (74%)	6 (25%)
Recovered (number with clinical signs that survived)	9	0
New case period <sup>b</sup>	Arrival to 18 days	4–17 days
Mortality period	9–25 days	5–19 days
Number euthanized	6	3
Mortality (%) <sup>a</sup>	16 (47%)	6 (25%)
Total mortality including other causes	20 (59%)	6 (25%)

<sup>a</sup> With the exception of total mortality, morbidity and mortality data are directly attributable to avipox (Group A) or PMV-1 (Group B).

<sup>b</sup> New case period = period over which cases were diagnosed after arrival at quarantine facility.

glottal lesions (four), ulcerated papillomatous third eyelid lesions (11), dry nodular lesions on the bill (one), and unfeathered part of the limbs (one). One bird had signs of extreme respiratory distress before death. Six birds in which pox was confirmed by virus isolation or histopathology, died acutely without showing any clinical signs. Blood samples were collected from 11 birds with avipox lesions and values are presented in Table 2. Mean red blood cell count (RBC), hemoglobin (Hb), and packed cell volume (PCV) values were significantly lower, while white cell count (WBC), heterophil, lymphocyte, and

monocyte counts, and heterophil:lymphocyte ratio (H:L ratio) were significantly higher compared with normal reference ranges (Samour et al., 1994).

In addition to pox lesions described above, postmortem findings in 16 birds with confirmed pox infections included: esophageal papillomas (one); splenomegaly (14); pulmonary congestion (five); sinusitis (one); tracheal lesions (three); bacterial pulmonary granuloma (one); renal enlargement and congestion (three); proventriculitis (one); pancreatic inflammation, enlargement, and hardening (seven); hepatic inflammation (nine); peritonitis and

TABLE 2. Hematology (mean ± SEM; *P* value) from birds with avipox virus (Group A, *n* = 11) and paramyxovirus type 1 (PMV-1) (Group B, *n* = 5) infections compared to normal ranges for the species.

Parameter	Group A (avipox infected)	Group B (PMV-1 infected)	Normal range <sup>a</sup>
Red blood cells (×10 <sup>12</sup> /l)	1.8±0.15 <sup>b</sup>	ND <sup>d</sup>	2.51±0.06 (1.95–3.36)
Hemoglobin (g/l)	11.3±0.99 <sup>b</sup>	14.1±0.9 <sup>c</sup>	14.97±0.13 (13.3–16.3)
Packed cell volume (%)	38.17±3.19 <sup>b</sup>	43.67±2.4 <sup>c</sup>	47.49±0.53 (42.5–56.5)
White blood cells (×10 <sup>9</sup> /l)	12.84±2.17 <sup>b</sup>	7.1±1.17 <sup>c</sup>	5.81±0.19 (3.2–7.85)
Heterophils (×10 <sup>9</sup> /l)	9.35±2.04 <sup>b</sup>	5.19±0.88 <sup>b</sup>	3.76±0.18 (1.69–5.74)
Lymphocytes (×10 <sup>9</sup> /l)	2.76±0.44 <sup>b</sup>	1.51±0.39 <sup>c</sup>	1.83±0.11 (0.66–3.3)
H:L ratio <sup>e</sup>	6.64±3.79 <sup>c</sup>	4.01±0.93 <sup>b</sup>	2.45±0.25 (0.98–6.58)
Monocytes (×10 <sup>9</sup> /l)	0.72±0.25 <sup>b</sup>	0.53±0.11 <sup>b</sup>	0.14±0.04 (0.0–1.15)

<sup>a</sup> Samour et al., 1994; mean ± SEM (min–max).

<sup>b</sup> Significantly different (*P* < 0.05) using unpaired Student's *t*-test from normal range.

<sup>c</sup> Not significantly different (*P* < 0.05) using unpaired Student's *t*-test from normal range.

<sup>d</sup> ND = no data.

<sup>e</sup> H:L = heterophil:lymphocyte ratio.

TABLE 3. Significant bacteria and fungi isolated from Group A birds (avipox virus infected) at post-mortem examination.

Isolates	Site
<i>Aspergillus fumigatus</i>	Lung (2 <sup>a</sup> ), peritoneal fluid (1), airsac (1)
<i>Candida albicans</i>	Lung (1), airsac (1)
<i>Candida tropicalis</i>	Lung (1), airsac (1)
<i>Escherichia coli</i>	Trachea (1), airsac (2), peritoneal fluid (1), kidney (1), spleen (1), liver (1), lung (1), thoracic fluid (1)
<i>Klebsiella pneumoniae</i>	Lung (2), spleen (1), airsac (1), ceca (1)
<i>Nocardia asteroides</i>	Airsac (1)
<i>Proteus mirabilis</i>	Lung (1), liver (1)
<i>Pseudomonas aeruginosa</i>	Trachea (2), liver (1), airsac (1), peritoneal fluid (1)
<i>Salmonella arizonae</i>	Small intestine (1)
<i>Salmonella reading</i>	Ceca (2), liver (2), lung (1)

<sup>a</sup> Number of isolates indicated in parentheses.

mucoid peritoneal fluid (six); intestinal adhesions (four); intestinal mucosal inflammation (five); airsacculitis (nine); intestinal endoparasites (two); and disseminated fungal granulomas (one). Culture results from samples collected postmortem are presented in Table 3.

Seven cases with obvious avipox papillomas on the skin and/or eyelids were not submitted for histopathology. Formalin-fixed samples from the remaining 13 birds that died in Group A were submitted for histopathology and a diagnosis of avipox infection was confirmed in nine birds. Microscopic lesions in these cases included proliferative dermatitis (five), stomatitis (one), esophagitis (one), tracheobronchitis (five), laryngopharyngitis (three), airsacculitis (one), pancreatitis (one) and necrotizing peritonitis (six) with intracytoplasmic eosinophilic inclusion bodies. Avipox virus was isolated from intestinal swabs collected from two (18%) of 11 birds from Group A. Avipox virus was isolated from cutaneous, oropharyngeal, and visceral lesions collected postmortem. Causes of

death in the four birds that did not die from avipox included aspergillosis (two), coccidial enteritis (one), and foreign body impaction of the intestinal tract (one).

On arrival of Group B birds keel abrasion was observed in one bird. Clinical signs of PMV-1 infection seen in five Group B birds were similar to those described by Bailey et al. (1997) and included dyspnea (one), ataxia (one), head twitching (two), and depression (one). One bird died acutely without showing any clinical signs. Blood samples were collected from five birds showing clinical signs and from which a positive diagnosis of PMV-1 was later confirmed. Hematology values are presented in Table 2. Mean Hb and PCV levels were at the low end of normal reference values (Samour et al., 1994). Mean total WBC and lymphocyte counts were at the high end of normal ranges. Heterophil and monocyte counts and H:L ratio were significantly higher than normal ranges. Gross postmortem findings were inconclusive with the exception of pancreatic inflammation in two cases. No significant bacteria or fungi were isolated from brain, liver, pancreas, and intestinal contents. Significant microscopic findings included edema, gliosis, and nonsuppurative encephalitis and subacute nonsuppurative pancreatitis with necrosis in two cases. Paramyxovirus type 1 was isolated from pooled intestinal and choanal swabs collected from two of five (40%) of postmortem cases from Group B. Rising titers of PMV-1 antibodies were detected in paired serum samples collected from the surviving 15 birds on arrival and 1 mo later (Table 6). One surviving bird in Group B failed to seroconvert.

#### Viral characterization

Avipox virus was isolated on the chorio-allantoic membrane (CAM) of specific pathogen free hen's eggs and identified following electron microscopy (EM) examination. The isolate also grew well in primary chicken embryo cells producing a widespread cytopathic effect. Studies are

TABLE 4. Mean weights (grams; mean±SEM) of male and female birds on arrival at the NARC in Groups A (avipox virus infected) and B (paramyxovirus type 1 infected) that survived compared with birds that died. Differences were not significant ( $P<0.05$ ).

Group	Survived	Died
Female group A	858±23 (n=9) <sup>a</sup>	815±26 (n=7)
Male group A	1236±50 (n=4)	1074±44 (n=9)
Female group B	939±29 (n=12)	889±53 (n=3)
Male group B	1264±11 (n=3)	1213±87 (n=3)

currently in progress at the VLA to compare the houbara poxvirus with other avian poxviruses.

Paramyxovirus was isolated in the allantoic fluid of 9–10 day old embryonated hen’s eggs. The allantoic fluid of the dead eggs was harvested and identified by hemagglutination/hemagglutination inhibition (HA/HI) as PMV-1. The isolate was further characterized by indirect immunoperoxidase (IIP) tests using a panel of monoclonal antibodies and placed in group C1 (velogenic). The intracerebral pathogenicity index (ICPI) test (Official Journal of the European Communities, 1992) was carried out in day-old chicks and proved the isolate to be pathogenic with an ICPI of 1.8.

**Pattern of mortality**

A greater proportion of male birds died from avipox infection compared with female birds in Group A; more males also died in Group B from PMV-1, and in Groups A and B combined from all mortality causes. In Group A the mortality from avipox infection was 60% (9/15) and 37% (7/19) for male and female birds respectively, but the difference was not significant ( $P=0.32$ ). In Group B the mortality from PMV-1 infection was 43% (3/7) and 18% (3/17) for male and female birds respectively, but the difference was not significant ( $P=0.44$ ). The overall mortality

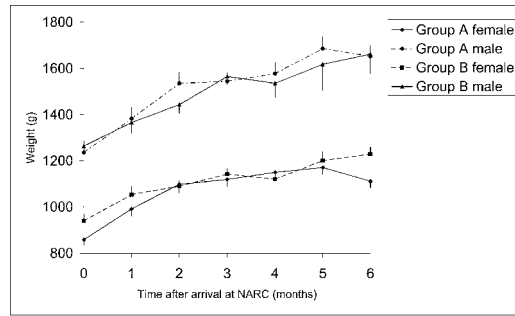


FIGURE 1. Monthly (mean±SEM) weight of Group A (avipox virus infected) and Group B (PMV-1 infected) birds after arrival at the National Avian Research Center.

in Groups A and B from all causes was 59% (13/22) and 36% (13/36) for male and female birds respectively, but the difference was not significant ( $P=0.161$ ).

**Results of the health monitoring program**

*Condition:* The body weight on arrival of all Group A and B birds was lower than normal ranges established at NARC for birds of the same sex and age. Normal bodyweights (mean±SEM) for captive male and female houbara bustards are 1,534±19 g and 1,071±13 g respectively (Samour, 1999). Although the mean weight of birds on arrival at quarantine that survived was greater than the mean weight of birds that died in both Groups A and B, the differences were not significant for any category (Table 4). All birds gained weight from the time that they were admitted to the quarantine center where they had access to a balanced ad libitum diet. Maximum weight gain took place during the first 3 mo (Fig. 1).

*Hematology:* It was not possible to analyze hematology samples from every bird in the first 2 mo during the disease outbreak phase and unfortunately the dataset is incomplete. Additionally, hematology results from birds collected while they were being treated for traumatic injuries (seven), bacterial peritonitis (one), paresia (one), and corneal ulceration (one) were excluded from the dataset.

The datasets of erythrocytic parameters

TABLE 5. Monthly change in mean white cell count, total heterophil count, total lymphocyte count, heterophil:lymphocyte ratio (mean±SEM, *n*) in Group A (avipox virus infected) and Group B (paramyxovirus type 1 infected) birds.

Parameter	Group	Month				
		0 <sup>a</sup>	1	2	3	4
White cell count (×10 <sup>9</sup> /l)	A	14.72±1.39 <sup>b</sup>	8.75±1.67 <sup>b</sup>	6.94±0.91 <sup>c</sup>	6.32±0.623 <sup>c</sup>	5.96±0.89 <sup>c</sup>
		5	4	13	12	11
		6	4	14	15	15
	B	6.22±1.62 <sup>c</sup>	9.7±3.91 <sup>b</sup>	6.52±0.69 <sup>c</sup>	5.63±0.46 <sup>c</sup>	6.33±0.83 <sup>c</sup>
		5	4	13	12	11
		6	4	14	15	15
Heterophil count (×10 <sup>9</sup> /l)	A	9.93±1.42 <sup>b</sup>	ND	4.25±0.71 <sup>c</sup>	3.40±0.40 <sup>c</sup>	3.30±0.57 <sup>c</sup>
		5	ND	13	12	11
		6	ND	14	15	15
	B	4.03±1.39 <sup>c</sup>	ND	3.69±0.59 <sup>c</sup>	2.94±0.23 <sup>b</sup>	3.56±0.73 <sup>c</sup>
		5	ND	13	12	11
		6	ND	14	15	15
Lymphocyte count (×10 <sup>9</sup> /l)	A	4.23±0.36 <sup>b</sup>	ND	2.32±0.25 <sup>b</sup>	2.67±0.21 <sup>b</sup>	2.27±0.29 <sup>c</sup>
		5	ND	13	12	11
		6	ND	14	15	15
	B	1.86±0.29 <sup>c</sup>	ND	2.57±0.26 <sup>b</sup>	2.38±0.23 <sup>b</sup>	2.51±0.18 <sup>b</sup>
		5	ND	13	12	11
		6	ND	14	15	15
Heterophil: lymphocyte ra- tio	A	2.41±0.39 <sup>c</sup>	ND	1.87±0.25 <sup>c</sup>	1.25±0.11 <sup>b</sup>	1.45±0.17 <sup>b</sup>
		5	ND	13	12	11
		6	ND	14	15	15
	B	2.09±0.62 <sup>c</sup>	ND	1.53±0.25 <sup>b</sup>	1.32±0.12 <sup>b</sup>	1.47±0.30 <sup>b</sup>
		5	ND	13	12	11
		6	ND	14	15	15

<sup>a</sup> 0 = arrival at National Avian Research Center.

<sup>b</sup> Significantly different ( $P < 0.05$ ) unpaired Student's *t*-test from normal range.<sup>d</sup>

<sup>c</sup> Not significantly different ( $P < 0.05$ ) unpaired Student's *t*-test from normal range.<sup>d</sup>

<sup>d</sup> Samour et al., 1994; see Table 2.

for Groups A and B were small for the first 2 mo. Consequently erythrocytic parameters from birds in Groups A and B were combined to demonstrate important changes in erythrocytic parameters during this period that are pertinent to the rehabilitation of houbara bustards in general. Mean Hb and PCV values were lower in birds on arrival compared to normal ranges. Hemoglobin values (mean±SEM) were 13±1.03, 14.08±0.35, 16.34±0.29, and 16.12±0.49 g/dl at 0, 2, 3 and 4 mo respectively in Group A and B birds. Packed cell volumes (mean±SEM) were 39.3±2.89, 45.8±1.25, 49.6±0.96, and 49.6±1.14% at 0, 2, 3 and 4 mo respectively in Group A and B birds. Two months after arrival mean RBC, Hb, and PCV for surviving birds in Groups A and B were within normal reference ranges for the species (Samour et al., 1994). Individual and mean flock red cell parameters (RBC, Hb, PCV) remained within normal reference ranges from 2–11 mo in Groups A and B (data not shown).

In Group A, mean WBC, heterophil, and lymphocyte counts were higher than normal reference levels on arrival and at 1 mo (WBC), but were within normal ranges from 2–11 mo (Tables 8, 9 and 10). In Group B mean WBC was within normal ranges on arrival and only exceeded normal reference ranges 1 mo after arrival ( $n=4$ , Table 5). Mean WBC, heterophil, and lymphocyte counts were within normal ranges from 2–11 mo after arrival (Table 5). In nine Group B birds reactive lymphocytes were observed during the second mo after arrival, but similar changes were not observed in Group A. Mean monocyte counts were within normal ranges from 0–11 mo for both Groups A and B (data not shown). In both Groups A and B at 6 mo there was a significant mean leukopenia and heteropenia (Table 5). The reason for this could not be determined and although the timing was not consistent with the isolation of adenovirus from three birds during the third and fourth month, it remains possible that this leucopenia in the sixth



TABLE 5. Extended.

		Month						
		5	6	7	8	9	10	11
5.73±1.24 <sup>c</sup>	4.51±0.41 <sup>b</sup>	5.68±0.51 <sup>c</sup>	7.1±0.94 <sup>b</sup>	4.1±0.41 <sup>b</sup>	6.19±0.75 <sup>c</sup>	5.04±1.01 <sup>c</sup>		
4	11	10	6	5	7	8		
6.47±0.92 <sup>c</sup>	4.36±0.49 <sup>b</sup>	5.26±0.63 <sup>c</sup>	6.57±1.11 <sup>c</sup>	4.63±0.59 <sup>b</sup>	5.55±0.49 <sup>c</sup>	4.54±0.59 <sup>b</sup>		
10	14	12	6	6	10	11		
3.35±1.03 <sup>c</sup>	2.53±0.35 <sup>b</sup>	3.16±0.42 <sup>c</sup>	4.16±0.95 <sup>c</sup>	1.96±0.25 <sup>b</sup>	3.94±0.63 <sup>c</sup>	3.03±0.93 <sup>c</sup>		
4	11	10	6	5	7	8		
3.76±0.77 <sup>c</sup>	2.67±0.40 <sup>b</sup>	3.10±0.47 <sup>c</sup>	4.08±0.74 <sup>c</sup>	2.51±0.33 <sup>c</sup>	3.3±0.40 <sup>c</sup>	2.90±0.54 <sup>c</sup>		
10	14	12	6	6	10	11		
1.94±0.15 <sup>c</sup>	1.73±0.16 <sup>c</sup>	2.05±0.19 <sup>c</sup>	2.64±0.28 <sup>b</sup>	1.91±0.14 <sup>c</sup>	1.95±0.24 <sup>c</sup>	1.70±0.15 <sup>c</sup>		
4	11	10	6	5	7	8		
2.17±0.35 <sup>b</sup>	1.51±0.13 <sup>c</sup>	1.89±0.29 <sup>c</sup>	2.22±0.38 <sup>c</sup>	1.95±0.29 <sup>c</sup>	1.9±0.19 <sup>c</sup>	1.44±0.17 <sup>c</sup>		
10	14	12	6	6	10	11		
1.63±0.41 <sup>c</sup>	1.58±0.26 <sup>c</sup>	1.70±0.30 <sup>c</sup>	1.68±0.44 <sup>c</sup>	1.02±0.09 <sup>b</sup>	1.94±0.26 <sup>c</sup>	1.27±0.37 <sup>c</sup>		
4	11	10	6	5	7	8		
2.12±0.54 <sup>c</sup>	1.83±0.25 <sup>c</sup>	1.93±0.41 <sup>c</sup>	2.15±0.54 <sup>c</sup>	1.34±0.17 <sup>c</sup>	1.89±0.30 <sup>c</sup>	2.06±0.31 <sup>c</sup>		
10	14	12	6	6	10	11		

month could have been related to exposure to adenovirus.

One of the most notable observations in Groups A and B were lower H:L ratios associated with increased proportions of lymphocytes (high end of normal ranges) in many birds (Table 5). In normal houbara bustards the H:L ratio is 2.45±0.25 (0.98–6.5) or in a blood film heterophils comprise 64±1.71% (46–85%) (mean±SEM, range) and lymphocytes comprise 32±0.09% (13–52) of the cells respectively (derived from original data from Samour et al., 1994). This figure is similar to the results of examinations on over 2,500 blood samples from houbara bustards between 1993–2000 at the NARC veterinary laboratory (Silvanose and Bailey, unpubl. obs.). The mean monthly H:L ratios in Groups A and B were consistently lower than the normal mean ratio of 2.45 for the entire monitoring period, and were significantly lower during mo 3 and 4 for Group A and mo 2, 3, and 4 for Group B (Table 5). This was more marked in Group A birds. It was still noticeable at 11 mo when four of seven Group A birds compared with one of

10 Group B birds had an H:L ratio less than one (data not shown).

*Serology:* Sera collected on arrival from 27 of 34 Group A birds was tested for PMV-1 antibodies and all samples were negative. Thirteen of 17 birds (76%) were positive for antibodies against avipox virus on arrival. When 11 birds that survived avipox infection were sampled 1 mo later, 10 were seropositive; the one seronegative bird had been seropositive on arrival. Two months after arrival, pox virus antibodies were detected in three (30%) of 10 surviving birds. Three months after arrival antibodies were detected in one (11%) of nine birds. At six ( $n=10$ ), 10 ( $n=7$ ), and 11 ( $n=7$ ) mo antibodies were detected in two birds both of which were seropositive at 2 mo and seronegative at 3 mo. These results may indicate that there was re-exposure to avipox virus.

Eleven (47%) of 23 birds from Group B were seropositive for PMV-1 on arrival. Two (33%) of six birds that died of PMV-1 infection were seropositive on arrival. Serology results, expressed as PI for the surviving birds in Group B are presented

TABLE 6. Monthly change in paramyxovirus type 1 ELISA titers in Group B birds.

Month	0 <sup>a</sup>	1	2	3	4
Mean (percent inhibition)±SEM	34.9±5.4	73.1±3.2	75.7±2.5	80.7±2.5	78.4±4.1
Range	0.9–68.7	48.9–86.2	59.8–87.6	57.7–88.1	62.1–88.3
n	17	11	11	14	6

<sup>a</sup> 0 = arrival at National Avian Research Center. Does not include data from one bird that failed to seroconvert during the study.

in Table 6. A rising PMV-1 antibody titer following arrival was detected in all but one bird in Group B. This bird failed to seroconvert throughout the duration of the program. In the birds that seroconverted, antibody levels remained high and all 10 birds from which samples were collected 11 mo after arrival were seropositive.

**Virology screening:** No virus was isolated from cloacal and choanal swabs collected from the 34 Group A birds on arrival. Avipox virus was not isolated from cloacal and choanal swabs during the subsequent 11 mo from surviving birds or from feather pulp samples collected 6 and 12 mo after arrival from one and six birds respectively, which had pox lesions. An adenovirus was isolated from pooled cloacal and choanal swabs once from one bird at 4 and 11 mo after arrival and from one bird 4 mo after arrival.

No virus was isolated from cloacal and choanal swabs collected from 24 Group B birds on arrival. Paramyxovirus type 1 virus was not isolated from cloacal and choanal swabs from any surviving birds during the subsequent 11 mo. An adenovirus was isolated from pooled cloacal and choanal swabs on three occasions from two birds 4 and 11 mo after arrival. Studies at the VLA using one-way virus neutralization tests suggested the adenoviruses belong to fowl adenovirus (FAV) serotype 1 group.

**Cloacal microbiology, *Chlamydia* sp. status and parasitology results:** Normal flora (*Escherichia coli*, *Enterococcus* sp., *Serratia* sp., and *Proteus mirabilis*) were isolated from cloacal swabs collected at 2, 6, and 12 mo from Groups A (6, 12, and 6 samples, respectively) and B (8, 12,

and 5 samples, respectively). The only exception was *Salmonella albania* which was isolated from a single bird in Group B once during month 6. All Group A and B birds remained *Chlamydia* sp. antigen negative throughout the trial. *Trichomonas* sp. was observed in pooled fecal samples collected from Groups A and B on arrival, and at 2, and 11 mo. Oropharyngeal swabs were collected from birds with stomatitis on arrival and *Trichomonas* sp. was observed in two of nine birds.

**Endoscopy:** Surviving birds were subjected to endoscopy 2 mo after arrival when the birds were physically normal on clinical examination and there were no external clinical signs associated with avipox or PMV-1 infection. Endoscopy was used on 10 birds in Group A 2 mo after arrival. Abnormalities were observed in all birds including: splenomegaly (two); splenic inflammation (one); adrenomegaly (one); pancreatitis (one); regressing mucoid lesions, plaques, and adhesions on the serosal surfaces of the alimentary tract, liver, and kidney (nine); and evidence of recent air sacculitis (vascularized, opaque, and thickened airsacs) (three). No fungal or bacterial pathogens were isolated from swabs taken from airsacs and adhesions. Internal serosal surfaces had a mucoid appearance. Six birds were further examined using endoscopy 10 mo later. No abnormal findings were recorded from three birds. In three birds the remnants of small adhesions between intestinal loops were noted.

Endoscopy was used on 16 birds from Group B 2 mo after arrival. No abnormal findings were observed in eight birds. Ab-

TABLE 6. Extended.

5	6	7	8	9	10	11
82.7±1.4	78.5±1.5	85.6±1.3	84.7	84.6±2.3	87.7±0.6	85.9±0.6
70.9–89.9	69.8–84.2	77.9–90.2	81.8–87.6	78.1–88.9	85.1–89.9	82.8–88.9
15	10	12	2	4	8	10

normal findings in the other eight birds included: splenomegaly (one); evidence of recent air sacculitis (three); regressing lesions and adhesions on the alimentary tract (three); mild hepatic inflammation (three); and pancreatitis (one). No fungal or bacterial pathogens were isolated from swabs taken from airsacs and adhesions. Two birds with abnormal findings were further examined using endoscopy 10 mo later. The remnants of small adhesions between intestinal loops was observed in one bird.

#### Integration into the captive bustard flock of NARC

At the time of writing, 24 mo after arrival of the birds and 12 mo after their integration into the NARC flock, PMV-1 and avipox infections have not been diagnosed in surviving Group A and B birds, or in other NARC captive bustards at the sites where these rehabilitated birds have been integrated.

The three birds that were positive for adenovirus during the monitoring program were euthanized 21 mo after arrival. Frozen organ samples (brain, liver, spleen, lung, small intestine, large intestine, and kidney) were submitted for virus isolation and no viruses were isolated. Histopathologic examination of internal organs was unremarkable. An additional bird with cutaneous skin lesions from Group A was euthanized at 19 mo. Histopathologic examination of the cutaneous lesions confirmed bacterial dermatitis and no viruses were isolated from skin samples submitted for virus isolation. Adenovirus was isolated from frozen organ samples collected from this bird, but histopathologic examination of internal organs was unremarkable.

#### DISCUSSION

The rehabilitation of confiscated houbara bustards presents serious medical challenges and ethical dilemmas to wildlife agencies in the Middle East. Conservation agencies accept that confiscated animals can be euthanized, incorporated into captive breeding collections, or released back into the wild (IUCN, 2000). Any release of confiscated wild animals must include screening and monitoring to address potential negative impacts, as set forth in the IUCN Guidelines for Reintroductions and Confiscated Wildlife (IUCN, 1998, 2000). It is important to determine whether animals, such as the houbara bustards described in this report that have recovered from serious viral infections can pose a risk to captive and/or free-living populations.

The high morbidity and mortality associated with diphtheritic and septicemic forms of avipox in Group A were similar to those observed in other species (Ritchie, 1995; Tripathy and Reed, 1997; Gerlach, 1999). Mortality rates are highest when diphtheritic lesions cause defects in the mucosal barrier of the alimentary or respiratory tract, allowing secondary bacterial, fungal, or chlamydocphila infections (Ritchie, 1995). Measures to reduce exposure of birds to pathogens should be initiated when birds are received at rehabilitation centers including immediate antibiotic prophylaxis and immune stimulation.

Avipox virus infections generally stimulate the production of antibodies that protect a bird from infection by the same strain of virus for 6–12 mo (Ritchie, 1995). Antibodies to avipox virus in chickens can be detected 1–3 wks after infection (Rit-

chie, 1995) and they persist for more than 15 wks. In houbara bustards, avipox antibodies were also of a short duration and by 3 mo antibodies could not be detected in most birds. However, antibodies were detected in two houbara that were seropositive at 2 mo, seronegative at 3 mo, and then seropositive at 6, 10, and 11 mo after exposure. These results may indicate reactivation of avipox virus and certainly warrant further investigation. It has been suggested that avian poxvirus infections, particularly in a flock situation may remain latent for years (Gerlach, 1999).

Systemic avipox virus infection with lesions of bronchopneumonia, airsacculitis, and diphtheroid enteritis has been described in psittacines, canaries (*Serinus canaria*), and house sparrows (*Passer domesticus*) (Donnelly and Crane, 1984; Gerlach, 1999). To our knowledge this is the first time septicemic avipox virus infection has been reported in houbara bustards. In lovebirds (*Agapornis roseicollis*), intracytoplasmic inclusions have been reported in feather follicles (Tsai et al., 1997) and birds that recover from poxvirus infection may develop persistent infections and intermittently shed virus from the gastrointestinal system, skin, or feathers (Ritchie, 1995). In the current study, avipox virus was not isolated from feather samples of Group A birds. Additionally avipox virus was not isolated from surviving birds 11 mo after initial infection and neither were septicemic and diphtheritic avipox lesions detected in the captive breeding collection into which surviving birds were integrated up to 24 mo later.

The poor body condition of houbara bustards with avipox was probably due to anorexia because lesions on eyelids and diphtheritic oropharyngeal lesions interfered with vision and feeding as is found in other species (Tripathy and Reed, 1997). Supportive care including tube feeding is an important component in the care of pox-affected houbara bustards. *Trichomonas* sp. is common in oropharyngeal and fecal samples from houbara bus-

tards (Silvanose et al., 1998) and we detected this parasite in oropharyngeal swabs from birds with diphtheritic pox lesions. Clinicians should be aware of the potential for confusing diphtheritic avipox lesions with trichomoniasis in houbara bustards.

Diagnosis of PMV-1 infection was confirmed by demonstrating increased antibody titer in paired sera samples from exposed birds and virus isolation from post-mortem organ samples and cloacal/choanal swabs from dead birds. The key features of PMV-1 in houbara bustards are similar to those in other species (Beard and Hanson, 1984; Ritchie, 1995; Gerlach, 1999; Wernery, 1999). In domestic fowl surviving PMV-1 infection, hemagglutinating inhibition antibody titers may remain detectable for 1 yr (Alexander, 1997). In our study, antibody levels were maintained for 11 mo; this may be related to sensitivity of the ELISA. These results are comparable to the long duration of circulating PMV-1 antibodies in psittacine species (Erickson, 1976). Testing for PMV-1 antibodies in confiscated houbara bustards on arrival and 1 mo after arrival should be considered an important health screening procedure by rehabilitation centers. A rising antibody in these birds would indicate a recent infection with the PMV-1 virus. Serologic screening in this manner is more cost effective than virologic screening of individual birds and demonstrates birds were exposed to PMV-1 within the previous year. Psittacine species can shed PMV-1 virus from 28 days to 1 yr after experimental infection (Erickson, 1976; Clubb, 1986). We did not isolate PMV-1 virus from surviving birds 11 mo after initial infection or detect the virus in the captive breeding collection into which surviving birds were integrated up to 24 mo later.

Pancreatitis occurs in several avian viral diseases (Randall and Reece, 1996) and specifically in chickens and pigeons due to PMV-1 infection (Barton et al., 1992; Meulemans et al., 1998). To our knowledge this is the first time pancreatitis has been reported in houbara bustards asso-

ciated with PMV-1 and septicemic avipox virus infections.

Paramyxovirus type 1 was reported in a houbara bustard breeding project in the Kingdom of Saudi Arabia (Ostrowski et al., 1995) and in recently imported houbara bustards in the UAE (Bailey et al., 1997). However, this disease was not detected from 1992 to 2000 in the NARC captive breeding collection where the birds are vaccinated (Bailey et al., 1998) and maintained under controlled conditions. Similarly, the septicemic and diphtheritic form of avipox have not been observed in any species of bustard maintained in NARC captive breeding collections, although cutaneous avipox infection is not uncommon (Bailey et al., 1996). Stress makes chickens more susceptible to PMV-1 infection (Mohamed and Hanson, 1980) as well as activating latent avipox infections (Ritchie, 1995). In our experience in the UAE, PMV-1 and diphtheritic and septicemic avipox are seen only in illegally traded houbara bustards. The susceptibility of smuggled houbara bustards to viral infections is probably related to stress, high stocking densities, and unhygienic transportation conditions.

The mortality of houbara bustards as a direct result of this trade is large and mortality is high even among birds in rehabilitation centers where medical care is provided. At one rehabilitation center in Pakistan 48% of birds admitted died in 1999 (unpubl. data) and avian pox and PMV-1 were important causes of this high mortality. During 1998–2000 mortality was 59% in 454 confiscated houbara bustards submitted to the NARC quarantine unit (unpubl. data). This high mortality emphasizes the importance of medical care and health screening as part of the rehabilitation process.

Endoscopy 2 mo after arrival demonstrated the limitations of a routine physical examination and was a valuable tool to assess lesions in internal organs. These changes may have been associated with earlier episodes of disease and may be ev-

ident long after the bird appears to have recovered. They could influence survival of birds released into the wild.

Birds with viral infections may have inconsistent hemograms due to the immune response and coincidental infections by bacterial and fungal pathogens (Fudge and Joseph, 2000). Skewed H:L ratios were observed in bustards and stone curlews (*Burhinus oedicephalus*) examined in NARC quarantine facilities between 1992 and 1996 (unpubl. data). These birds had recovered from avipox and PMV-1 infections but were otherwise clinically normal (Samour, pers. comm.; unpubl. obs.). Skewed H:L ratios may be useful indicators of previous exposure to viral disease in houbara bustards. The duration of skewed H:L ratios in Group A birds was surprising and may have been related to severity and widespread effects of septicemic avipox infection.

Adenoviruses are a common cause of disease in birds (Capua et al., 1995; Hines et al., 1995; McFerran, 1997) but have not been isolated previously from houbara bustards. Adenovirus was isolated from three birds during the first 11 mo of the study, but not when these individuals were euthanized 21 mo after arrival. Adenovirus was isolated from a Group A bird euthanized 19 mo after arrival though the virus had not been isolated from this bird previously. Adenoviruses are commonly recovered from persistently infected, asymptomatic birds. Asymptomatic adenovirus infections often are not detected until a bird becomes immunocompromised (Ritchie, 1995; Gerlach, 1999). Additional investigations are needed to determine the significance of adenovirus infections in houbara bustards.

Clearly rehabilitation and release into the wild or incorporation into captive flocks entail disease risks, even after intensive medical treatments, comprehensive health screening, and lengthy quarantine periods. Intermittent shedding of adenovirus by three birds in the study and isolation of reovirus from other flocks of con-

confiscated houbara bustards (Bailey et al., 2000) demonstrate that novel disease agents of uncertain pathogenicity may be latently carried and intermittently shed by confiscated birds. This illustrates the difficulty of detecting carrier birds from conventional quarantine screening at 45 days after arrival. There is no published information on adenovirus infections in bustards, although reovirus has been associated with mortality in young Heuglins bustards (*Neotis heuglini*) in Dubai (Wernery, pers. comm.). In general, morbidity and mortality associated with adenovirus infections in birds varies with the host and viral strain (Ritchie, 1995). The susceptibility of juvenile birds to reovirus and adenovirus infections (Ritchie, 1995; McFerran, 1997) is an important reason for excluding these diseases from breeding collections. Investigations to determine the significance of these newly reported viral infections in bustards are warranted.

There is clearly a risk of importing pathogens with illegally traded houbara bustards and our evidence reinforces the need for surveillance programs, in particular virologic screening, at rehabilitation centers for these birds (Shortridge and Burrows, 1997; Bailey et al., 2000). We recommend that confiscated houbara bustards be managed separately from captive-bred stock if they are integrated into captive breeding programs. There should be separate facilities for adult birds and rearing facilities for offspring derived from different stocks and strict sanitary measures. Additionally, health monitoring of confiscated birds should be continued after birds are integrated into captive flocks and should include routine virologic screening of all confiscated birds that subsequently die, in addition to a comprehensive necropsy, histopathologic, and microbiology examinations. Free-living psittacines can act as reservoirs of serious diseases (Schmidt, 1993); the health status of free-living houbara bustards has been insufficiently investigated to ascertain whether some of the diseases detected in illegally trapped wild

birds are present in free-living populations. Thorough assessment of the health status of free-living houbara bustard populations should be considered a priority for agencies involved in rehabilitating and releasing birds into the wild or utilizing confiscated illegally traded houbara bustards in captivity.

#### ACKNOWLEDGMENTS

We thank H. H. Sheikh Khalifa bin Zayed Al Nahyan, President of the ERWDA Board of Directors and H. H. Sheikh Hamdan bin Zayed Al Nahyan, Vice President of the ERWDA and M. Al Bowardi, ERWDA Managing Director, for their support. We also thank J. Naldo, A. Azur, D. Tadena, and J. Howlett from ERWDA, and U. Wernery from the Central Veterinary Research Laboratory, Dubai for their assistance. J. Samour from Prince Fahad bin Sultan Falcon Center kindly provided the original hematology data from his earlier study and commented on the hematology findings and H. Gerlach made helpful comments when the monitoring protocols were designed.

#### LITERATURE CITED

- AHMED, M. 1997. Houbara Foundation International Pakistan. *Arabian Wildlife* 3: 13–15.
- ALEXANDER, D. J. 1997. Newcastle disease and other avian paramyxoviridae infections. *In* Diseases of poultry, B. W. Calnek (ed.). Iowa State University Press, Ames, Iowa, pp. 541–570.
- , R. J. MANVELL, J. P. LOWINGS, K. M. FROST, M. S. COLLINS, P. H. RUSSELL, AND J. E. SMITH. 1997. Antigenic diversity and similarities detected in avian paramyxovirus type 1 (Newcastle disease virus) isolates using monoclonal antibodies. *Avian Pathology* 26: 399–418.
- BAILEY, T. A. 1999. Fluid therapy. *In* Avian medicine, J. Samour (ed.). Harcourt Publishers Ltd, London, pp. 102–106.
- , J. H. SAMOUR, J. NALDO, J. HOWLETT, AND M. TARIK. 1996. Causes of morbidity in bustards in the United Arab Emirates. *Avian Diseases* 40: 121–129.
- , P. K. NICHOLLS, U. WERNERY, J. SAMOUR, J. E. COOPER, AND M. T. O'LEARY. 1997. Avian paramyxovirus type 1 infection in houbara bustards (*Chlamydotis undulata macqueenii*): Clinical and pathological findings. *Journal of Zoo and Wildlife Medicine* 28: 325–330.
- , U. WERNERY, J. H. SAMOUR, AND J. L. NALDO. 1998. Antibody response of kori bustards (*Ardeotis kori*) and houbara bustards (*Chlamydotis undulata macqueenii*) to live and inactivated Newcastle disease vaccines. *Journal of Zoo and Wildlife Medicine* 29: 441–450.

- , C. D. SILVANOSE, J. NALDO, O. C. COMBREAU, F. LAUNAY, U. WERNERY, J. KINNE, R. GOUGH, AND R. MANVELL. 2000. Health considerations of the rehabilitation of illegally traded houbara bustards *Chlamydotis undulata macqueenii* in the Middle East. *Oryx* 34: 325–334.
- BARTON, J. T., A. A. BICKFORD, G. L. COOPER, B. R. CHARLTON, AND C. J. CARDONA. 1992. Avian paramyxovirus type 1 infections in racing pigeons in California. 1. Clinical signs, pathology, and serology. *Avian Diseases* 36: 463–468.
- BEARD, C. W., AND R. P. HANSON. 1984. Newcastle disease. In *Diseases of poultry*, M. F. Hofstad, H. J. Barnes and B. W. Calnek (eds.). Iowa State University Press, Iowa, pp. 542–470.
- CAPUA, I., R. E. GOUGH, P. SCARAMOZZINO, R. LELLI, AND A. GATTI. 1995. Isolation of an adenovirus from an ostrich (*Struthio camelus*) causing pancreatitis in experimentally infected guinea fowl (*Numida meleagris*). *Avian Diseases* 38: 642–646.
- CLUBB, S. 1986. Viral and chlamydial diseases of pet birds. In *Infectious diseases*, F. W. Scott (ed.). Churchill Livingstone, New York, New York, pp. 229–242.
- COLLAR, N. 1996. Bustards. In *Handbook of birds of the world*, 3. Hoatzin to auks, J. Del Hoyo, A. Elliot and J. Sargatal (eds.). Lynx Edicions, Barcelona, Spain, pp. 240–273.
- CZIFRA, G., M. NILSSON, D. J. ALEXANDER, R. MANVELL, S. KECZKEMETI, AND B. E. ENGSTROM. 1996. Detection of PMV-1 specific antibodies with a monoclonal antibody blocking enzyme-linked immunosorbent assay. *Avian Pathology* 25: 691–703.
- DONNELLY, T. M., AND L. A. CRANE. 1984. An epornitic of avian pox in a research aviary. *Avian Diseases* 28: 517–525.
- ERICKSON, G. E. 1976. Viscerotrophic velogenic Newcastle disease in six pet bird species: Clinical response and virus host interactions. Ph.D. Thesis, Iowa State University, Ames, Iowa, pp. 70–87.
- FUDGE, A. M., AND V. JOSEPH. 2000. Disorders of avian leucocytes. In *Laboratory medicine: Avian and exotic pets*, A. M. Fudge (ed.). W.B. Saunders Company, Philadelphia, Pennsylvania, pp. 19–27.
- GERLACH, H. 1999. Viruses. In *Avian medicine: Principles and application*, 1st Edition, B. W. Ritchie, G. J. Harrison and L. R. Harrison (eds.). Wingers Publishing Inc., Lake Worth, Florida, pp. 862–948.
- GORIUP, P. D. 1997. The world status of the houbara bustard *Chlamydotis undulata*. *Bird Conservation International* 7: 373–397.
- GOUGH, R. E., D. J. ALEXANDER, M. S. COLLINS, S. A. LISTER, AND W. J. COX. 1988. Routine virus isolation or detection in the diagnosis of diseases in birds. *Avian Pathology* 17: 893–907.
- HINES, M. E., E. L. STYER, C. A. BALDWIN, AND J. R. COLE. 1995. Combined adenovirus and rotavirus enteritis with *E. coli* septicemia in an emu chick. *Avian Diseases* 39: 646–653.
- INTERNATIONAL UNION FOR THE CONSERVATION OF NATURE. 1995. International Union for the Conservation of Nature guidelines for re-introductions. IUCN/SSC Specialist Group. International Union for the Conservation of Nature, Gland, Switzerland, <http://iucn.org/themes/ssc/pubs/policy/reinte.htm>
- . 2000. International Union for the Conservation of Nature guidelines for the placement of confiscated live animals. IUCN/SSC Re-introduction Specialist Group. IUCN, Gland, Switzerland, 23 pp.
- LAUNAY, F., O. COMBREAU, AND M. AL BOWARDI. 1999. Annual migration of houbara bustard *Chlamydotis undulata macqueenii* from the United Arab Emirates. *Bird Conservation International* 9: 155–161.
- MCFERRAN, J. B. 1997. Adenovirus infections. In *Diseases of poultry*, B. W. Calnek (ed.). Iowa State University Press, Ames, Iowa, pp. 607–642.
- MEULEMANS, G., S. ROELS, T. P. VANDEN BERG, J. GODFRIED, AND M. DECAESSTECKER. 1998. Acute pancreatitis in chickens due to non-virulent Newcastle disease virus. *The Veterinary Record* 143: 300–303.
- MOHAMED, M. A., AND R. P. HANSON. 1980. Effect of social stress on Newcastle disease virus infection. *Avian Diseases* 24: 908–915.
- NALDO, J., J. SAMOUR, AND T. A. BAILEY. 1997. The quarantine station at the National Avian Research Center, Abu Dhabi. *International Zoo Yearbook* 35: 256–261.
- OFFICIAL JOURNAL OF THE EUROPEAN COMMUNITIES. 1992. Introducing Community measures for the control of Newcastle disease. Council directive 92/66/EEC, L260, pp. 1–20.
- OSTROWSKI, S., M. ANCRENAZ, M. SAINT-JALME, AND A. GRETH. 1995. Concurrent avian pox and Newcastle disease in a houbara bustard (*Chlamydotis undulata*). *Avian Pathology* 24: 573–577.
- RANDALL, C. J., AND R. L. REECE. 1996. *Avian histopathology*. Mosby-Wolfe, London, UK, pp. 62–64.
- RITCHIE, B. W. 1995. *Avian viruses: Function and control*. Wingers Publishing, Inc., Lake Worth, Florida, pp. 253–335.
- SAMOUR, J. H. 1999. *Avian medicine*. Harcourt Publishers Ltd, London, England, pp. 60–72.
- , J. C. HOWLETT, M. G. HART, T. A. BAILEY, J. NALDO, AND M. A. D'ALOIA. 1994. Normal haematology of the houbara bustard (*Chlamydotis undulata macqueenii*). *Comparative Haematology International* 4: 198–202.
- SCHMIDT, R. E. 1993. Psittacine birds as reservoirs of serious diseases. In *Zoo and wild animal medicine: Current therapy* 3, M. E. Fowler (ed.).

- W.B. Saunders Company, Philadelphia, Pennsylvania, pp. 244–247.
- SILVANOSE, C., J. SAMOUR, J. NALDO, AND T. A. BAILEY. 1998. Intestinal protozoa and associated bacteria in captive bustards in the United Arab Emirates. *Avian Pathology* 28: 94–97.
- SHORTRIDGE, K. F., AND D. BURROWS. 1997. Prevention of entry of avian influenza and paramyxoviruses into an ornithological collection. *The Veterinary Record* 140: 373–374.
- TRIPATHY, D. N., AND W. M. REED. 1997. Pox. In *Diseases of poultry*, B. W. Calnek (ed.). Iowa State University Press, Ames, Iowa, pp. 643–659.
- TSAI, S. S., T. C. CHANG, S. F. YANG, Y. C. CHI, R. S. CHER, M. S. CHIEN, AND C. ITAKARU. 1997. Unusual lesions associated with avian poxvirus infection in rosy-faced lovebirds (*Agapornis roseicollis*). *Avian Pathology* 26: 75–82.
- WERNERY, U. 1999. Viral diseases. In *Avian medicine*, J. Samour (ed.). Harcourt Publishers Ltd, London, England, pp. 264–265.

*Received for publication 1 May 2001.*