

Echinococcus multilocularis in a European Beaver from Switzerland

Authors: Janovsky, Martin, Bacciarini, Luca, Sager, Heinz, Gröne, Andrea, and Gottstein, Bruno

Source: Journal of Wildlife Diseases, 38(3) : 618-620

Published By: Wildlife Disease Association

URL: <https://doi.org/10.7589/0090-3558-38.3.618>

BioOne Complete (complete.BioOne.org) is a full-text database of 200 subscribed and open-access titles in the biological, ecological, and environmental sciences published by nonprofit societies, associations, museums, institutions, and presses.

Your use of this PDF, the BioOne Complete website, and all posted and associated content indicates your acceptance of BioOne's Terms of Use, available at www.bioone.org/terms-of-use.

Usage of BioOne Complete content is strictly limited to personal, educational, and non - commercial use. Commercial inquiries or rights and permissions requests should be directed to the individual publisher as copyright holder.

BioOne sees sustainable scholarly publishing as an inherently collaborative enterprise connecting authors, nonprofit publishers, academic institutions, research libraries, and research funders in the common goal of maximizing access to critical research.

***Echinococcus multilocularis* in a European Beaver from Switzerland**

Martin Janovsky,^{1,3,4} Luca Bacciarini,¹ Heinz Sager,² Andrea Gröne,¹ and Bruno Gottstein²¹Center for Fish and Wildlife Health, Institute of Animal Pathology, Länggassstrasse 122, CH-3012 Berne, Switzerland; ²Institute of Parasitology, University of Berne, Länggassstrasse 122, CH-3012 Berne, Switzerland; ³Present address: Amt der Tiroler Landesregierung, Veterinärdirektion, Wilhelm-Greilstrasse 25, 6020 Innsbruck, Austria; ⁴Corresponding author (email: m.janovsky@tirol.gv.at)

ABSTRACT: Infection with the larval stage of the cestode parasite *Echinococcus multilocularis* was diagnosed in a European beaver (*Castor fiber*) in central Switzerland. The animal was hit, run over by a car, and died of trauma. It was in normal body condition and no signs of disease were seen. At necropsy, multiple cystic structures up to 1 cm in diameter were found in the liver adjacent to the hilus. Within the parasite vesicles, multiple protoscolices were visible. The species was determined to be *Echinococcus multilocularis* by upon polymerase chain reaction and direct immunofluorescence with MAbG11-FITC. This is the first report of *Echinococcus multilocularis* in European beaver.

Key words: Case report, *Castor fiber*, *Echinococcus multilocularis*, European beaver, liver, parasite, Switzerland.

The European beaver (*Castor fiber*) was extirpated in Switzerland at the beginning of the 19th century and reintroduced between 1957 and 1977 (Winter, 1998). The present population includes approximately 350 animals (Anderegg, 1998). A subadult male beaver weighing 10.0 kg was found dead in August 2000 near a main road in the Canton of Aargau (47°34'N, 08°25'E) close to the River Rhine. It was submitted for necropsy to the Center for Fish and Wildlife Health (Berne, Switzerland). The animal died of trauma and was in normal body condition. The capsule of the liver was ruptured. Near the portal hilus multiple white cysts up to 1 cm in diameter were present (Fig. 1). No pathogenic organisms were isolated from liver, lungs, kidney, and spleen by bacteriologic culture. Pieces of heart, liver, lung, kidney, and spleen were fixed in 10% buffered, neutral formalin. After fixation for 24 hr, tissues were embedded in paraffin; sections were cut at 5 μ m and stained with hematoxylin and eosin. Specimens from

the liver were also stained with periodic acid-Schiff (PAS; Armed Forces Institute of Pathology, 1968).

The portal area of the liver contained multiple echinococcal cysts characterized by a homogeneously PAS-positive bladder wall (laminated layer) adjoining the inner germinal layer with multiple protoscolices protruding from it. These cystic vesicles were surrounded by multiple layers of mature connective tissue, which was infiltrated by moderate numbers of lymphocytes, macrophages, and neutrophils. The connective tissue also exhibited multifocal mineralization. The hepatic parenchyma adjacent to the parasites showed moderate bile duct proliferation and moderate infiltration by lymphocytes and histiocytes, and a few neutrophils.

Specimens of liver including all visible cystic lesions, were submitted to the Institute of Parasitology (Berne, Switzerland). A polymerase chain reaction (PCR) with BG1 and BG2 primers specific for *Echinococcus multilocularis* was performed as previously described (Gottstein and Mowatt, 1991; Diebold-Berger et al., 1997). DNA isolated from lesions served as template for the PCR. A 2.6 kb pair fragment from the genome of *E. multilocularis* was obtained. Direct immunofluorescence using monoclonal antibody MAbG11-FITC (Deplazes and Gottstein, 1991) was conducted on the lesions. This monoclonal antibody is species-specific in similar cases of human *E. multilocularis* infections (Diebold-Berger et al., 1997). In the present investigation, immunostaining of the laminated layer was exhibited.

Echinococcus multilocularis is the causative agent of alveolar echinococcosis (AE), one of the most lethal helminthic in-

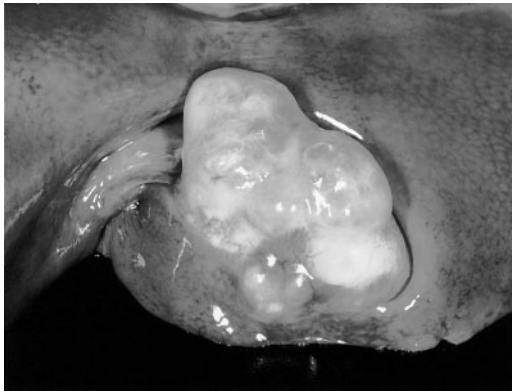


FIGURE 1. Liver from an European beaver from Switzerland. Cysts in the portal area caused by *Echinococcus multilocularis*.

fections of humans (Gottstein et al., 2001). It is endemic in the northern hemisphere. In central Europe, red foxes (*Vulpes vulpes*) are the major reservoir of *E. multilocularis*. Foxes from 21 of 26 Cantons in Switzerland were infected at prevalences varying from 2% to 53%, with an overall mean of approximately 30% (Eckert, 1996). The most common intermediate hosts in central Europe are small rodents such as the common vole (*Microtus arvalis*), water vole (*Arvicola terrestris*), followed by bank vole (*Clethrionomys glareolus*), and muskrat (*Ondatra zibethicus*) (Schmitt et al., 1997). There are numerous reports of “accidental” intermediate hosts. These include medium size rodents such as swamp beavers (*Myocastor cyopus*) (Worbes et al., 1989). However, *E. multilocularis* has not been reported in the European or the American beaver (*Castor canadensis*) (Addison et al., 1987; Romasov, 1992; Nolet et al., 1997). Piechocki (1973) reported *Echinococcus granulosus* in a European beaver from Russia without further description.

To our knowledge, this is the first documentation of AE in a beaver, thus demonstrating its susceptibility to infection with *E. multilocularis*. Of note is the morphologic peculiarity of the metacestode exhibiting a cyst-like structure not usually seen in hepatic lesions in mice. Misdiag-

nosis of *E. granulosus* as the causative agent can be avoided by using hooklet morphology (Wardle and McLeod, 1968), PCR, and immunostaining. In the present case, hooklets were not detectable in the metacestode.

Increased contamination of the Swiss environment with *E. multilocularis* eggs has been anticipated due to the dramatic increase of affected foxes. This has resulted in a high prevalence in some areas in Switzerland (Gottstein et al., 2001) and finding AE in unusual intermediate hosts such as dogs (Haller et al., 1998).

We thank P. Hohler for submitting the beaver for necropsy and the Wildlife section of the Federal Office for Environment, Forest and Landscape (BUWAL) for supporting research on diseases in free ranging wildlife in Switzerland.

LITERATURE CITED

- ADDISON, E. M., I. K. BARKER, AND D. B. HUNTER. 1987. Diseases and parasites of furbearers. In Wild furbearer management and conservation in North America, M. Novak (ed.). Ministry of Natural Resources, Ontario, Canada, pp. 893–909.
- ANDEREGG, R. 1998. Welche Zukunft für den Biber in der Schweiz? Bundesamt für Umwelt, Wald und Landschaft (BUWAL)—Bulletin Umweltschutz 3/98: 34–36.
- ARMED FORCES INSTITUTE OF PATHOLOGY. 1968. Manual of histologic staining methods of the Armed Forces Institute for Pathology, 3rd Edition, L. G. Luna (ed.). The Blakiston Division, McGraw-Hill Book Company, New York, New York, 258 pp.
- DEPLAZES, P., AND B. GOTTSSTEIN. 1991. A monoclonal antibody against *Echinococcus multilocularis* Em2 antigen. Parasitology 103: 41–49.
- DIEBOLD-BERGER, S., H. KHAN, B. GOTTSSTEIN, E. PUGET, J. L. FROSSARD, AND S. REMADI. 1997. Cytologic diagnosis of isolated pancreatic alveolar hydatid disease with immunologic and PCR analyses—A case report. Acta Cytologica 41: 1381–1386.
- ECKERT, J. 1996. Der “gefährliche Fuchsbandwurm” (*Echinococcus multilocularis*) und die alveoläre Echinococose des Menschen in Mitteleuropa. Berliner und Münchner Tierärztliche Wochenschrift 109: 202–210.
- GOTTSSTEIN, B., AND M. R. MOWATT. 1991. Sequencing and characterization of an *Echinococcus multilocularis* DNA probe and its use in the poly-

- merase chain reaction (PCR). *Molecular and Biochemical Parasitology* 44: 183–194.
- , F. SAUCY, P. DEPLAZES, J. REICHEN, G. DEMIERRE, C. ZÜRCHER, A. BUSATO, AND P. PUGIN. 2001. Is a high prevalence of *Echinococcus multilocularis* in wild and domestic animals associated with increased disease incidence in humans? *Emerging Infectious Diseases* 7: 408–412.
- HALLER, M., P. DEPLAZES, F. GUSCETTI, J. C. SARDINAS, I. REICHLER, AND J. ERCKERT. 1998. Surgical and chemotherapeutic treatment of alveolar echinococcosis in a dog. *Journal of the American Animal Hospital Association* 34: 309–314.
- NOLET, B. A., S. BROEKHUIZEN, G. M. DORRENTSTEIN, AND K. M. REINKS. 1997. Infectious diseases as main causes of mortality to beavers *Castor fiber* after translocation to the Netherlands. *Journal of Zoology* 241: 35–42.
- PIECHOCKI, R. 1973. Schutz und Hege des Elbeibibers (*Castor fiber albicus* Matschie). In *Buch der Hege*, H. Stubbe (ed.). VEB Deutscher Landwirtschaftsverlag, Berlin, Germany, pp. 384–412.
- ROMASOV, B. V. 1992. Krankheiten der Biber. *Semioquatische Säugetiere, Wissenschaftliche Beiträge der Universität Halle, Germany*, pp. 199–203.
- SCHMITT, M., F. SAUCY, S. WYBORN, AND B. GOTTSTEIN. 1997. Befall von Schermäusen (*Arvicola terrestris*) mit Metazestoden von *Echinococcus multilocularis* im Kanton Freiburg (Schweiz). *Schweizer Archiv für Tierheilkunde* 139: 84–93.
- WARDLE, R. A., AND J. A. MCLEOD. 1968. The zoology of tapeworms. Hafner Publishing Company, New York, New York, pp. 388–428.
- WINTER, C. 1998. Die Biber, *Castor fiber*, in der Nordostschweiz—Vergangenheit, Gegenwart und Ausblick in die Zukunft. *Mitteilungen der naturforschenden Gesellschaft Schaffhausen, Schaffhausen, Switzerland* 43: 63–72.
- WORBES, H., K. H. SCHACHT, AND J. ECKERT. 1989. *Echinococcus multilocularis multilocularis* in a swamp beaver (*Myocastor coypus*). *Angewandte Parasitologie* 30: 161–165.

Received for publication 3 May 2001.