

EXPERIMENTAL VACUOLAR MYELINOPATHY IN RED-TAILED HAWKS

Authors: Fischer, John R., Lewis-Weis, Lynn A., and Tate, Cynthia M.

Source: Journal of Wildlife Diseases, 39(2) : 400-406

Published By: Wildlife Disease Association

URL: <https://doi.org/10.7589/0090-3558-39.2.400>

BioOne Complete (complete.BioOne.org) is a full-text database of 200 subscribed and open-access titles in the biological, ecological, and environmental sciences published by nonprofit societies, associations, museums, institutions, and presses.

Your use of this PDF, the BioOne Complete website, and all posted and associated content indicates your acceptance of BioOne's Terms of Use, available at www.bioone.org/terms-of-use.

Usage of BioOne Complete content is strictly limited to personal, educational, and non - commercial use. Commercial inquiries or rights and permissions requests should be directed to the individual publisher as copyright holder.

BioOne sees sustainable scholarly publishing as an inherently collaborative enterprise connecting authors, nonprofit publishers, academic institutions, research libraries, and research funders in the common goal of maximizing access to critical research.

EXPERIMENTAL VACUOLAR MYELINOPATHY IN RED-TAILED HAWKS

John R. Fischer,^{1,2} Lynn A. Lewis-Weis,¹ and Cynthia M. Tate¹

¹ Southeastern Cooperative Wildlife Disease Study, College of Veterinary Medicine, The University of Georgia, Athens, Georgia 30602, USA

² Corresponding author (email: jfischer@vet.uga.edu)

ABSTRACT: Avian vacuolar myelinopathy (AVM) was recognized in 1994 as a cause of wild bird mortality when 29 bald eagles (*Haliaeetus leucocephalus*) succumbed to the disease at DeGray Lake, Arkansas (USA). The cause of AVM and its source remain undetermined despite extensive diagnostic and research investigations. Two years later, when AVM killed 26 eagles in the same area in Arkansas, it became apparent that American coots (*Fulica americana*) had identical neurologic signs and lesions, and it was hypothesized that eagles acquired AVM via ingestion of affected coots. In order to test this hypothesis, we fed coot tissues (brain, liver, kidney, muscle, fat, and intestinal tract) to rehabilitated, non-releasable red-tailed hawks (*Buteo jamaicensis*). Five hawks received tissues from coots with AVM lesions, and one hawk received tissues from coots without brain lesions that had been collected at a site where AVM never has been documented. All hawks received 12–70 g/day (mean=38 g) of coot tissues for 28 days. All six hawks remained clinically normal during the study. The birds were euthanatized on day 29 and microscopic lesions of AVM were found in all hawks that received tissues from affected coots, but not in the hawk that received tissues from unaffected coots. This marks the first time that AVM has been produced in birds under laboratory conditions and proves that birds of prey can acquire AVM via ingestion of tissues from affected coots.

Key words: American coot, avian vacuolar myelinopathy, bald eagle, *Buteo jamaicensis*, *Fulica americana*, *Haliaeetus leucocephalus*, intramyelinic edema, neurological disease, red-tailed hawk.

INTRODUCTION

Avian vacuolar myelinopathy (AVM) was recognized in 1994 as a cause of wild bird mortality when 29 bald eagles (*Haliaeetus leucocephalus*) succumbed to the disease at DeGray Lake (Arkansas, USA) (Thomas et al., 1998). In 1996, when AVM killed 26 eagles in the same area in Arkansas, it became apparent that American coots (*Fulica americana*) had identical neurologic signs and lesions, and it was hypothesized that eagles acquired AVM via ingestion of affected coots. Since then, coots with AVM have been found at additional sites in Arkansas, Georgia, North Carolina, South Carolina, and Texas (USA) and bald eagle mortality due to AVM has been documented at some of these locations (J. Fischer, unpubl. data). The cause of AVM and its source remain undetermined despite extensive diagnostic and research investigations. However, a toxicant is suspected because there has been no evidence of infectious agents or inflammatory lesions and AVM lesions resemble those of

other toxicoses due to man-made and natural compounds (Thomas et al., 1998).

Gross lesions are not apparent in birds with AVM. However, there is a consistent microscopic lesion consisting of multiple vacuoles within central nervous system white matter with a predilection for the optic lobe (Thomas et al., 1998). Additional affected sites include white matter tracts within the cerebrum, cerebellum, brainstem, and spinal cord. Rare involvement of the peripheral nervous system, consisting of distention of the axonal sheath with degeneration of the axon, has been observed in coots with AVM (Augsburger et al., 2003). Ultrastructurally, AVM is characterized by splitting of myelin laminae at the intraperiod line, a lesion consistent with intramyelinic edema. Agents known to cause intramyelinic edema in human beings, domestic animals, or laboratory animals include the rodenticide bromethalin (Dorman et al., 1992), hexachlorophene (Towfighi, 1980), triethyltin (Fleming et al., 1991), other manmade compounds, and toxic plants of the genera *Stypandra*

(Huxtable et al., 1980) and *Heliochrysum* (Van der Lugt et al., 1996). None of these compounds or plants has been found during investigation of AVM outbreaks.

Avian vacuolar myelinopathy is characterized clinically by signs of central nervous system disease including difficulty or inability to fly, swim, or walk (Thomas et al., 1998). Severely affected birds may become paralyzed and die. Nearly all eagles with confirmed AVM have been found dead and those found alive died shortly thereafter, despite supportive treatment. There appears to be a poor correlation between clinical signs and the presence of brain lesions because AVM lesions have been found in clinically normal coots collected during AVM outbreaks (J. Fischer, unpubl. data). Furthermore, brain lesions persisted in coots with AVM after the resolution of their neurologic signs in captivity (Larsen et al., 2002). Thus, AVM diagnosis must be based on the presence of microscopic lesions rather than on clinical signs.

American coots often are a major food item of bald eagles, especially immature eagles (Sobkowiak and Titman, 1989). Bald eagles also are considered opportunistic feeders (Johnsgard, 1990) with a hunting strategy that may focus on sick or injured prey, potentially including neurologically impaired coots. Additionally, bald eagles feed on carrion (Griffin et al., 1982) and large numbers of coot carcasses may be available during severe AVM outbreaks (Augspurger et al., 2003). The objective of this study was to determine whether birds of prey develop AVM lesions after consuming American coots in which AVM has been confirmed microscopically.

MATERIALS AND METHODS

From November 2000 to April 2001, American coots were collected from Lake Strom Thurmond/Clarks Hill Lake (33°42'N, 82°20'W) on the Georgia/South Carolina (USA) border during an AVM epizootic (US Fish and Wildlife Service Scientific Collection Permit #MB779238-4, Georgia Department of Natural Resources Permit #29-WSF-00-6, South Carolina Department

of Natural Resources Permit #G-00-16). Coots showing clinical signs of AVM and normal-appearing coots were collected by hand net or by gunshot with steel shot by personnel with the Southeastern Cooperative Wildlife Disease Study (SCWDS, University of Georgia, Athens, Georgia). Negative control coots were collected at Lake Seminole, Georgia (30°48'N, 84°52'W). Avian vacuolar myelinopathy had not been detected in coots at Lake Seminole during the previous 2 yr and coots collected for the present study did not have brain lesions. Age, sex, and weight of all coots were determined and half of the brain was placed in 10% buffered formalin for light microscopy to confirm the presence or absence of AVM lesions. Microscopic lesions of AVM were found in coots with neurologic signs as well as in clinically normal coots collected at Lake Strom Thurmond/Clarks Hill Lake. Lesions of AVM were not apparent in coots from Lake Seminole. Samples of brain, fat, intestinal tract, kidney, liver, and muscle were collected from coots, frozen at -20 C, and later thawed for use in the feeding trial.

Six rehabilitated, non-releasable red-tailed hawks (*Buteo jamaicensis*) were obtained from the Southeastern Raptor Rehabilitation Center at the Auburn University College of Veterinary Medicine (Auburn, Alabama, USA) on 20 March 2001 (University of Georgia IACUC #A2001-10161-0). All hawks had been held in captivity since at least 8 February 2001 and were obtained from areas in southern Alabama and Georgia where previous surveys failed to detect the presence of AVM lesions in coots. Five hawks had sustained wing fractures that precluded release and one hawk had a permanent ocular injury. All hawks appeared in good physical condition despite their permanent injuries and were randomly assigned to receive tissues from AVM-affected or non-affected coots. One hawk in the treatment group had received 14 mg of enrofloxacin intramuscularly for 10 days to resolve a foot infection. The enrofloxacin treatment concluded 5 days before the feeding trial began. The hawks were housed in large enclosed horse stalls and were allowed to acclimate for 2 wk prior to the feeding trial. During this time they were fed previously frozen and thawed, pathogen-free, laboratory mice, as well as tissues from coots without AVM lesions.

Prior to the feeding trial and once weekly during the study, all hawks were weighed, blood samples were collected via puncture of the jugular, brachial, or medial metatarsal vein for complete blood cell counts and serum chemistry analyses and basic physical and neurologic examinations were performed. Sex was determined at necropsy. An avian neurologic

examination, adapted from a protocol for domestic birds (Clippinger et al., 1996), was developed in order to standardize the assessment of neurologic function of the hawks.

The neurologic examination included assessment of the hawk's mental status, level of consciousness, posture, proprioception, gait, and sensory and motor responses. Hawks first were observed from outside the stall to evaluate mentation, posture, and attitude before they became excited from handling. Gait and movement were evaluated as the hawk moved from the perch to the floor when the stall was entered. Following capture, conscious proprioception and motor function were evaluated further by observing the bird's ability to return a wing to a normal, folded position after it had been manually abducted by the observer. Function of cranial nerves II–VI was evaluated by assessing menace response, pupillary light reflex, globe position, palpebral response, and ability to follow a moving object. Function of cranial nerves V and VII was evaluated further by assessing beak function and motor response to facial stimulation. Function of cranial nerve VIII was evaluated by assessing the bird's balance and coordination. Function of cranial nerves IX–XII was indirectly evaluated by observing the bird's ability to handle and ingest food items as well as by observing tongue position and tone.

Five hawks (two adult males, one adult female, one immature male, one immature female) were fed tissues from coots from Lake Thurmond with AVM lesions and one hawk (immature male) received tissues from lesion-free coots from Lake Seminole. Each bird received 12–70 g (mean=38 g) of coot tissues: brain (mean=2 g), fat (mean=3 g), intestinal tract (mean=13 g), kidney (mean=2 g), liver (mean=4 g), and skeletal muscle (mean=14 g) daily for 28 days. Each day, treatment birds received pooled tissues from two to five AVM-affected coots, whereas the control bird received pooled tissues from one to two non-affected coots.

On day 29 all hawks were sedated with a ketamine/xylazine mixture, euthanized with sodium pentobarbital, and a full necropsy was performed. Half of the brain and portions of the spinal cord and sciatic nerve were fixed in 10% buffered formalin, embedded in paraffin, sectioned at 5 μ m, stained with hematoxylin and eosin, and examined by light microscopy. Additional tissues examined by light microscopy included trachea, lung, heart, liver, spleen, kidney, adrenal gland, intestine, pancreas, gonad, and skeletal muscle. For electron microscopy, samples of optic lobe were placed in 2% glutaraldehyde, 2% paraformaldehyde, and

0.2% picric acid in a 0.1 M cacodylate buffer (pH 7.2). Following fixation, the samples were post fixed in 1% osmium tetroxide, dehydrated in a series of alcohols, stained en bloc with uranyl acetate, and embedded in epoxy resins. Sections 1 μ m thick were stained with toluidine blue and examined by light microscopy to select areas with vacuolar lesions of white matter. Ultrathin sections of these areas were stained with uranyl acetate and lead citrate and examined with a JEOL Model JEM-1210 transmission electron microscope (JEOL USA, Inc., Peabody, Massachusetts, USA).

RESULTS

In general, the hawks readily ingested coot tissues each day. However, some hawks occasionally removed and did not consume some tissues, particularly the intestines. Acceptance improved greatly when coot tissues were placed within complete skins that had been removed from thawed mouse carcasses and closed with absorbable suture material. All hawks remained in good physical condition during the trial. Average body weights ranged from 887–1512 g, (females, mean=1,445 g; males, mean=1,120 g; immature birds, mean=1,208 g; adult birds mean=1,249 g). Body weights remained relatively constant during the trial although there were some mild fluctuations. Complete blood cell counts and serum chemistry levels fell within normal reference values for red-tailed hawks (Ivins et al., 1986) with the following exceptions. Mean lactate dehydrogenase levels were mildly elevated above the reference value of 775 IU/l prior to the trial, as well as during the trial in treatment birds (1,200 IU/l) and the control bird (875 IU/l). Mean cholesterol levels prior to and during the trial were mildly elevated above the reference value of 150 mg/dl in treatment birds (179 mg/dl) and the control bird (181 mg/dl).

The hawks appeared normal on physical and neurologic examination prior to the trial and none of the birds developed observable signs of central nervous system disease during the study. Gross lesions, other than the permanent traumatic injuries sustained prior to the study, were not

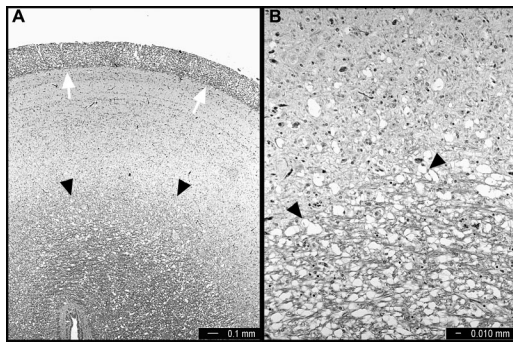


FIGURE 1. Light micrograph of the optic lobe of a red-tailed hawk that consumed tissues from coots with vacuolar myelinopathy. H&E. A. Diffuse vacuolization of white matter is present throughout the stratum opticum (white arrows) and stratum album centrale (black arrowheads). B. Vacuoles are present within the stratum album centrale (black arrowheads) and at the periphery of the adjacent gray matter.

apparent at necropsy. All hawks were in excellent body condition with adequate muscle mass and ample stores of body fat. Significant microscopic lesions were not apparent in sections of sciatic or other peripheral nerve, trachea, lung, heart, liver, spleen, kidney, adrenal gland, intestine, pancreas, gonad, and skeletal muscle.

Microscopic lesions of vacuolar myelinopathy were present in all five hawks that received tissues from coots with AVM. Lesions consisted of mild to moderate vacuolization of white matter and were most prominent in the optic lobe (Fig. 1), white matter tracts of the cerebrum, cerebellum (Fig. 2), brain stem, and spinal cord. Inflammatory changes were not apparent in affected tissues. Transmission electron microscopy of the optic lobe white matter of an affected hawk revealed numerous vacuoles delimited by myelin laminae that had split at the intraperiod line (Fig. 3). Lesions of AVM were not present in the central nervous system of the hawk that received tissues from unaffected coots from Lake Seminole.

DISCUSSION

Although the cause of AVM remains unknown, results of this study confirm that raptors can develop vacuolar myelinopathy

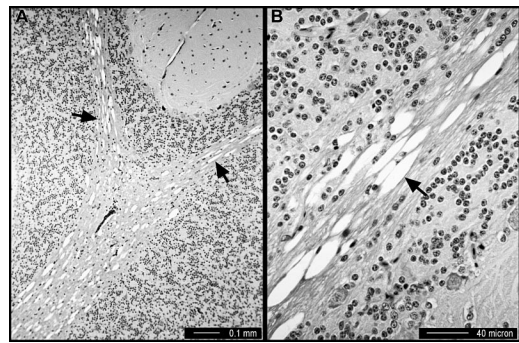


FIGURE 2. Light micrograph of the cerebellum of a red-tailed hawk that consumed tissues from coots with vacuolar myelinopathy. H&E. A and B. Numerous vacuoles (black arrows) are present within the white matter of the cerebellar folia while the granular layer and molecular layer remain unchanged.

of the central nervous system after ingesting tissues from other birds with AVM lesions. This mode of exposure has been suspected since 1996 when coots and bald ea-

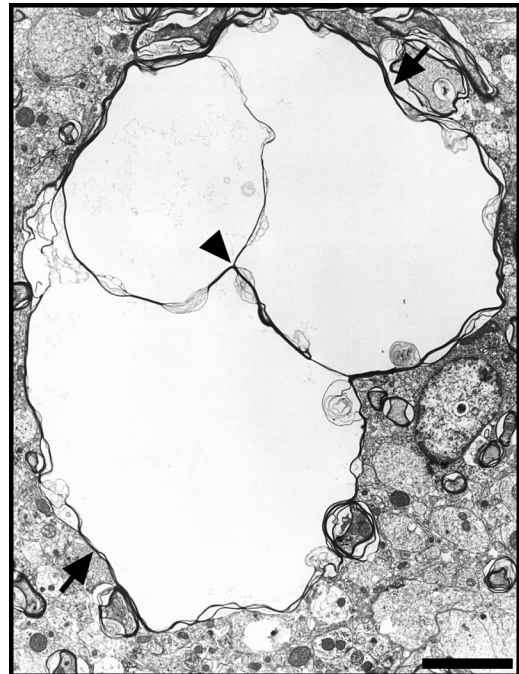


FIGURE 3. Transmission electron micrograph of white matter in the stratum opticum of a hawk that consumed tissues from coots with vacuolar myelinopathy. Multiple vacuoles are delimited by myelin laminae (arrows) that split at the intraperiod line (arrowhead).

gles simultaneously were diagnosed with AVM in southwestern Arkansas (Thomas et al., 1998). Coots can be a major food item of bald eagles (Sobkowiak and Titman, 1989) and it is likely that eagles can more easily acquire coots that are neurologically impaired or have died from AVM.

The lesions in the five hawks that received tissues from coots with AVM were consistent with microscopic changes observed in field cases of AVM in bald eagles and coots (Thomas et al., 1998). Lesions consisted of vacuole formation of varying severity within central nervous system white matter with vacuolization most intense in the optic lobe as previously reported. Ultrastructurally, splitting of myelin laminae at the intraperiod line is consistent with intramyelinic edema as observed in certain natural and experimental toxicoses in humans, domestic animals, and laboratory animals (Towfighi, 1980; Fleming et al., 1991; Huxtable et al., 1980). The lack of apparent inflammation or infectious agents also is suggestive of a possible toxicologic etiology for the lesion.

Hawks in the current study remained clinically normal despite the presence of brain lesions that were diffuse and moderately severe in some birds. The presence of AVM lesions in hawks lacking neurologic signs is consistent with previous observations. Lesions of AVM were present in clinically normal coots collected during the current study as well as in coots in which clinical disease had resolved after birds were taken into captivity (Larsen et al., 2002). The apparent absence of clinical signs could be due to lack of sufficient morphologic changes within the central nervous system, a biochemical rather than a morphologic cause for the clinical signs of AVM, or failure of our examination technique to identify other neurologic deficits that may have been present. It is unknown whether feeding greater volumes of tissues from affected coots or prolongation of the trial would have resulted in clinical neurologic disease in the hawks. Additionally, it is unknown when the lesions first

developed in the hawks. Lesion development has been documented within 1 wk after introduction of sentinel birds at a site experiencing an AVM outbreak (Rocke et al., 2002).

Although AVM was reproduced experimentally in hawks in this study, the dose and duration of exposure to the causative agent necessary to induce brain lesions are unknown. Lesions of AVM have been found as early as 5 days in healthy coots and pen-raised ducks after their release at a site during an AVM outbreak (Rocke et al., 2002). Lesions of AVM developed in experimental hawks consuming an average of less than 38 g/day (or 3% of body weight) for 28 days. The amount of tissue from AVM-affected coots that larger raptors, such as bald eagles, would have to consume before developing clinical signs and/or lesions remains unknown. Additional variables that could influence development of AVM in predatory or scavenging birds include the amount of the causative agent within an affected coot, the amount of prey or carrion without AVM consumed concurrently, and the general health of the bird.

Experimental reproduction of AVM in red-tailed hawks indicates that other species of raptors and possibly other avian scavengers may be susceptible to this disease in addition to bald eagles. Diagnosis of AVM in great horned owls (*Bubo virginianus*) at Lake Thurmond at the same time coots were collected there for this study (J. Fischer, unpubl. data) provides field evidence of susceptibility among this broad avian group. Although AVM has been confirmed only in avian species to date, field and laboratory studies of other vertebrates, particularly fish and mammals, are indicated.

Avian vacuolar myelinopathy can significantly impact local eagle populations. Nationally, bald eagles were upgraded in 1995 from endangered to threatened on the Endangered Species List of the United States Fish and Wildlife Service, (Federal Register, 1995). During the AVM eporn-

tics in southwestern Arkansas during the winters of 1994–95 and 1996–97, it was estimated that 30–65% of the wintering bald eagle population may have died and that 5% of the coot population displayed neurologic signs (Thomas et al., 1998). Although eagle mortality of this magnitude among wintering birds is not thought to measurably impact the national eagle population, deaths of nesting eagles during an AVM epornitic could devastate local eagle populations.

Since the first documentation and description of AVM, the uncertain etiology of the disease has posed a serious dilemma for wildlife managers who currently are unable to prevent additional losses of wildlife resources (Thomas et al., 1998). Additional research is needed to determine the specific cause of AVM and its source, the species susceptibility range, the pathogenesis of disease, the predictability of outbreaks, and the feasibility of management options to prevent or minimize the impact on eagles, coots, and other wildlife resources.

ACKNOWLEDGMENTS

Primary funding was provided by the US Department of the Interior, through Grant Agreement 01ERAG0013 with the Biological Resources Division of the US Geological Survey and by the wildlife management agencies of Alabama, Arkansas, Florida, Georgia, Kansas, Kentucky, Louisiana, Maryland, Mississippi, Missouri, North Carolina, Puerto Rico, South Carolina, Tennessee, Virginia, and West Virginia. Support from the states to SCWDS was provided by the Federal Aid to Wildlife Restoration Act (50 Stat. 917). Additional support was received from the Arcadia Wildlife Preserve, Inc. J. Shellnut and colleagues at the Southeastern Raptor Rehabilitation Center at Auburn University's College of Veterinary Medicine provided the red-tailed hawks and raptor husbandry advice. D. Williamson of the US Army Corps of Engineers and personnel of the Georgia Department of Natural Resources assisted with coot collection. C. Budke, P. Luttrell, and other SCWDS personnel assisted with coot and tissue collections as well as with blood collection, neurologic examinations, and feeding of hawks. M. Ard provided excellent

assistance with transmission electron microscopy.

LITERATURE CITED

- AUGSPURGER, T., J. R. FISCHER, N. J. THOMAS, L. SILEO, R. E. BRANNIAN, K. J. MILLER, AND T. E. ROCKE. 2003. Vacuolar myelinopathy in waterfowl from a North Carolina impoundment. *Journal of Wildlife Diseases* 39: 412–417.
- CLIPPINGER, T. L., R. A. AVERY, AND S. R. PLATT. 1996. The avian neurologic examination and ancillary neurodiagnostic techniques. *Journal of Avian Medicine and Surgery* 10: 221–247.
- DORMAN, D. C., J. F. ZACHARY, AND W. B. BUCK. 1992. Neuropathologic findings in bromethalin toxicosis in the cat. *Veterinary Pathology* 29: 139–144.
- FEDERAL REGISTER. 1995. Final rule to reclassify the bald eagle from endangered to threatened in all the lower 48 states. 60: 36000–36010.
- FLEMING, W. J., E. F. HILL, AND J. J. MOMOT. 1991. Toxicity of trimethyltin and triethyltin to mallard ducklings. *Environmental Toxicology* 10: 255–260.
- GRIFFIN, C. R., T. S. BASKETT, AND R. D. SPARROWE. 1982. Ecology of bald eagles wintering near a waterfowl concentration. USFWS Special Scientific Report Number 247.
- HUXTABLE, C. R., P. R. DORLING, AND D. H. SLATTER. 1980. Myelin oedema, optic neuropathy and retinopathy in experimental *Stypandria imbricata* toxicosis. *Neuropathology and Applied Neurobiology* 2: 221–232.
- IVINS, G. K., G. D. WEDDLE, AND W. H. HALLIWELL. 1986. Hematology and serum chemistries in birds of prey. *In* *Zoo and Wild Animal Medicine*. M. E. Fowler (ed.). W.B. Saunders Company, Philadelphia, Pennsylvania, pp. 434–437.
- JOHNSGARD, P. A. 1990. Hawks, eagles, and falcons of North America: Biology and natural history. Smithsonian Institution Press, Washington D.C., 403 pp.
- LARSEN, R. S., F. B. NUTTER, T. AUGSPURGER, T. E. ROCKE, L. TOMLINSON, N. J. THOMAS, AND M. K. STOSKOPF. 2002. Clinical features of avian vacuolar myelinopathy in American coots. *Journal of American Veterinary Medical Association* 221: 80–85.
- ROCKE, T. E., N. J. THOMAS, T. AUGSPURGER, AND K. MILLER. 2002. Epizootiologic studies of avian vacuolar myelinopathy in waterbirds. *Journal of Wildlife Diseases* 38: 678–684.
- SOBKOWIAK, S., AND R. D. TITMAN. 1989. Bald eagles killing American coots and stealing coot carcasses from greater black-backed gulls. *Wilson Bulletin* 101: 494–496.
- THOMAS, N. J., C. U. METEYER, AND L. SILEO. 1998. Epizootic vacuolar myelinopathy of the central nervous system of bald eagles (*Haliaeetus leu-*

- cocephalus*) and American coots (*Fulica americana*). *Veterinary Pathology* 35: 479–487.
- TOWFIGHI, J. 1980. Hexachlorophene. In *Experimental and clinical Neurology*. P. S. Spencer and H. H. Schaumberg (eds.). Williams and Wilkins, Baltimore, Maryland, pp. 440–455.
- VAN DER LUGT, J. J., J. OLIVIER, AND P. JORDAAN. 1996. Status spongiosis, optic neuropathy, and retinal degeneration in *Heliochrysum argyrosphaerum* poisoning in sheep and a goat. *Veterinary Pathology* 33: 495–502.

Received for publication 10 September 2002.