



Degenerative Encephalopathy in a Coastal Mountain Kingsnake (*Lampropeltis zonata multifasciata*) due to Adenoviral-like Infection

Authors: Raymond, James T., Lamm, Marnie, Nordhausen, Robert, Latimer, Ken, and Garner, Michael M.

Source: Journal of Wildlife Diseases, 39(2) : 431-436

Published By: Wildlife Disease Association

URL: <https://doi.org/10.7589/0090-3558-39.2.431>

BioOne Complete (complete.BioOne.org) is a full-text database of 200 subscribed and open-access titles in the biological, ecological, and environmental sciences published by nonprofit societies, associations, museums, institutions, and presses.

Your use of this PDF, the BioOne Complete website, and all posted and associated content indicates your acceptance of BioOne's Terms of Use, available at www.bioone.org/terms-of-use.

Usage of BioOne Complete content is strictly limited to personal, educational, and non - commercial use. Commercial inquiries or rights and permissions requests should be directed to the individual publisher as copyright holder.

BioOne sees sustainable scholarly publishing as an inherently collaborative enterprise connecting authors, nonprofit publishers, academic institutions, research libraries, and research funders in the common goal of maximizing access to critical research.

Degenerative Encephalopathy in a Coastal Mountain Kingsnake (*Lampropeltis zonata multifasciata*) due to Adenoviral-like Infection

James T. Raymond,^{1,5,6} Marnie Lamm,² Robert Nordhausen,³ Ken Latimer,⁴ and Michael M. Garner^{1,1} North-west ZooPath, 18210 Waverly Drive, Snohomish, Washington 98296-4815, USA; ² Los Angeles Zoo, 5333 Zoo Drive, Los Angeles, California 90027, USA; ³ California Animal Health and Food Safety Laboratory System, P.O. Box 1770, Davis, California 95617, USA; ⁴ Department of Veterinary Pathology, College of Veterinary Medicine, University of Georgia, Athens, Georgia 30602-7388, USA; ⁵ Current address: P.O. Box 1398, Harpers Ferry, West Virginia 25425, USA; ⁶ Corresponding author (email: Zoopath2@aol.com)

ABSTRACT: In March 2000, an approximately 30-yr-old, male coastal mountain kingsnake (*Lampropeltis zonata multifasciata*) presented with disequilibrium and unresponsiveness to stimuli that ultimately lead to euthanasia. Histologically, there were foci of gliosis primarily within the caudal cerebrum, brainstem, and cervical spinal cord. Several glial cells and endothelial cells contained magenta, intranuclear inclusion bodies. Electron microscopy of the inclusions revealed paracrystalline arrays of 79–82 nm, viral-like particles. DNA *in situ* hybridization of sections of formalin-fixed brain using a mixture of two digoxigenin-end-labeled, adenovirus specific, oligonucleotide probes at low and high stringency was positive for adenovirus.

Key words: Adenovirus, DNA *in situ* hybridization, encephalopathy, *Lampropeltis zonata multifasciata*, snake

In January 1996, an approximately 30-year-old, male coastal mountain kingsnake (*Lampropeltis zonata multifasciata*) housed at a southern Californian zoological park (34°3'N, 118°14'W) was observed having mild head and body tremors that for the most part resolved spontaneously in 3 mo. Over the next 4 yr, the tremors continued sporadically and were most evident when the snake was handled. In February 2000, the tremors became progressively worse during feeding resulting in difficulty ingesting food. In March 2000, the snake was euthanized with an intracardiac injection of pentobarbital sodium (Pentosol Injection, Med-Pharmex, Inc., Pomona, California, USA). On the day of euthanasia, the snake was curled upside-down and was nonresponsive to touch. At necropsy, the kingsnake was thin and the kidneys appeared small.

Sections of brain, skin, heart, oral mucosa, fat body, kidney, liver, teeth, eyes,

calvaria, cervical vertebrae, spinal cord, skeletal muscle, gall bladder, pancreas, epididymis, lung, stomach, trachea, and esophagus were fixed in 10% neutral buffered formalin, embedded in paraffin, sectioned at 5.0 µm, and stained with hematoxylin and eosin (HE). For transmission electron microscopy, sections of formalin fixed cerebrum were transferred into modified Karnovsky's fixative, washed with sodium cacodylate, and post-fixed in unbuffered 2% osmium tetroxide reduced by 2.5% potassium ferrocyanide. Sections of cerebrum were then dehydrated through a graded ethanol series, soaked in propylene oxide, infiltrated with epoxy resin (Spurr's Low Viscosity Resin, Ted Pella, Redding, California), sectioned at 70 nm, stained with 6% methanolic uranyl acetate, counterstained with lead citrate, and examined with a transmission electron microscope (EM 10C transmission electron microscope, Carl Zeiss, Thornwood, New York, USA).

For DNA *in situ* hybridization, replicate sections of formalin fixed, paraffin embedded brain were deparaffinized in three changes of limonene for 5 min each. The sections were then rehydrated through graded alcohol solutions to 1× buffer (10× Automation Buffer, Biomedex Corp., Foster City, California). The tissue specimens were digested for 10 min in pepsin solution at 37 C. Pepsin activity subsequently was destroyed by heating the slides at 105 C for 8 min. The tissue sections were rinsed five times in 1× Autobuffer. The sections were then treated with 100% formamide for 5 min at 105 C. The probe solution was then added and the charged

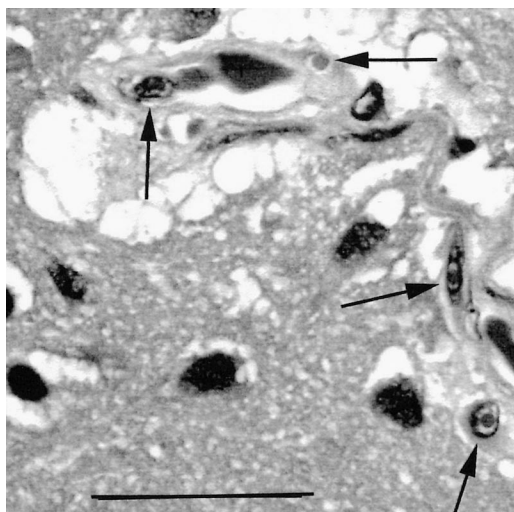


FIGURE 1. Photomicrograph of the cerebrum. There are intranuclear inclusion bodies within endothelial cells lining several small caliber arteries (arrows). There are clear vacuoles and fibrillar material around the arteries. HE stain. Bar=35 μ m.

microscope slides (ProbeOn Plus slides, Fisher Scientific, Pittsburgh, Pennsylvania, USA) were incubated for 5 min at 105 C and then lowered to 32 C for an additional 1 hr of incubation. The probe solution was composed of a cocktail of oligonucleotide probes FN-23 and FN-96. These probes detect an adenovirus structural capsid protein and had previously been used to detect reptilian adenovirus in paraffin embedded tissue sections (Ramis et al., 2000; Perkins et al., 2001). Probe FN-23 is probably responsible for most of the reactivity, but the combination of probes is routinely used for diagnostic work. Following hybridization, the sections were rinsed for 2 min in buffer with Triton X-100 and 1% sheep serum. Sites of hybridization were detected using affinity cytochemistry. Antidigoxigenin antibody (Digoxigenin Detection Kit, Roche Diagnostics, GmbH, Mannheim, Germany) conjugated to alkaline phosphatase was applied (500:1 dilution) and incubated for 1 hr at 37 C. Following incubation, the tissue sections were thoroughly rinsed in buffer and the chromagen solution was applied (nitroblue tetrazolium dye solution) for 1 hr at 37 C.

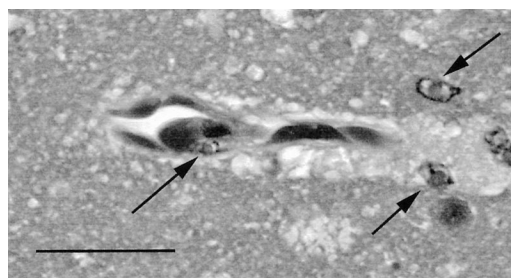


FIGURE 2. Photomicrograph of the brain stem. There are intranuclear inclusion bodies with margination of chromatin in endothelial cells and glial cells (arrows). There is fibrillar material and clear vacuoles within the Virchow-Robin space. HE stain. Bar=25 μ m.

The slides were then rinsed in distilled water, counterstained in 1% fast green dye for 5 min, rinsed, dehydrated, coverslipped, and examined microscopically. The presence of DNA hybrids was detected by the deposition of blue-black pigment (formazan). Both avian and reptilian positive and negative control tissues were used to validate the hybridization procedure.

The kingsnake had microscopic lesions confined to the brain that were centered primarily within the cerebrum. Histologically, several glial cells, endothelial cells, and few epithelial cells lining the lateral ventricles and in the choroid plexuses contained single, magenta to eosinophilic, intranuclear inclusion bodies with margination of chromatin (Figs. 1, 2). Individual endothelial and glial cells with intranuclear inclusion bodies were degenerate and necrotic. There were increased numbers of glial cells forming small nodular aggregates within the gray and white matter. Glial nodules centered primarily around neurons and small caliber blood vessels. The gray matter was multifocally vacuolated. Clear space surrounded several small arteries and capillaries within the neuropil. There were very low numbers of heterophils scattered throughout the neuropil. Multifocally, axons were swollen, dilated, and had spheroid formation. There were also multifocal, variably sized, (<50 μ m), round, eosinophilic, globular bodies within

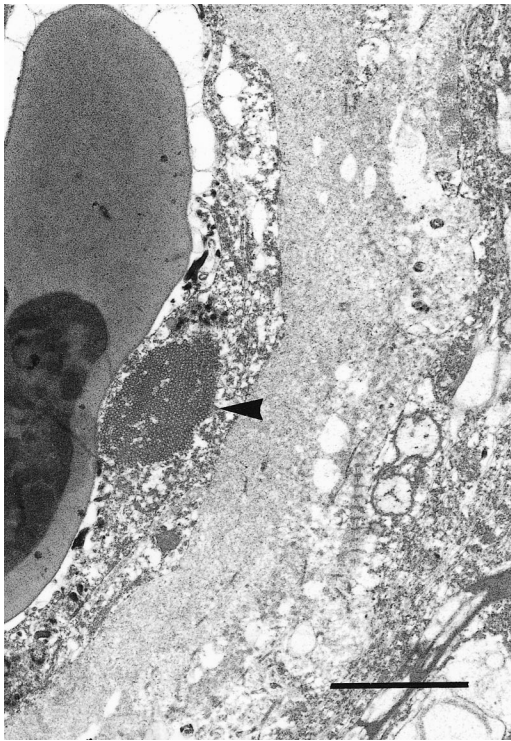


FIGURE 3. Transmission electron micrograph of an arteriole in the cerebrum from the kingsnake. The blood vessel contains a nucleated red blood cell. There is an electron dense body (inclusion) within a degenerate endothelial cell (arrowhead). There is edema fluid around the arteriole. Bar=2.0 μ m.

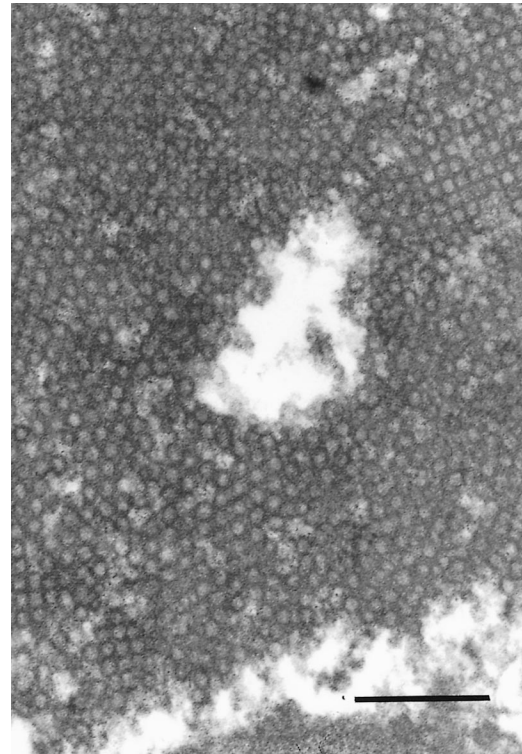


FIGURE 4. The inclusion is composed of many, 79–82 nm, nonenveloped, hexagonal outlined, viral-like particles arranged in a paracrystalline array. The particles had electron lucent cores and electron dense outer rims. Bar=800 nm.

the neuropil. Overall, similar but milder changes were noted within the brain stem and cervical spinal cord. Only a small section of cerebellum was examined microscopically and it was histologically normal.

Transmission electron microscopy of the cerebrum revealed many, 79–82 nm, non-enveloped, hexagonal outlined, viral-like particles arranged in paracrystalline arrays in few endothelial cells and glial cells (Fig. 3). The particles had electron lucent cores and electron dense outer rims (Fig. 4). The size, shape, and formation of paracrystalline arrays are characteristics of *Adenoviridae* (Cheville, 1994). The inclusions appeared intracytoplasmic in cells that had an absence of a recognizable nucleus. There was also similar viral-like arrays extracellular admixed with cellular debris. Endothelial cells with arrays had

swollen mitochondria and vacuolated endoplasmic reticulum. Axons adjacent to affected blood vessels were swollen with dilation of myelin sheaths. There was clear space and fibrillar material within the Virchow-Robin space of few blood vessels.

Following DNA *in situ* hybridization, adenoviral nucleic acid was demonstrated within nuclei of glial cells and fewer endothelial cells (Fig. 5). Chromagen deposition was observed within nuclei, but also exhibited diffusion into the cytoplasm of some cells. Chromagen deposition was intense under conditions of lower stringency, but was somewhat diminished under conditions of high stringency. These observations indicated that adenovirus infection was present in both glial and endothelial cells.

This coastal mountain kingsnake had

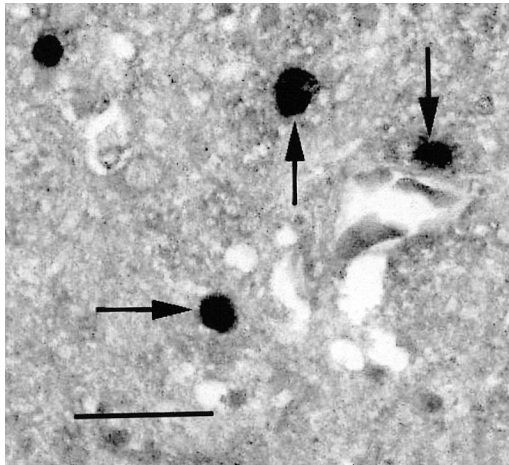


FIGURE 5. Adenoviral DNA within the nuclei of glial cells (arrows). *In situ* hybridization with FN-23 and FN-96 oligonucleotide probes and fast green counterstain. Bar=25 μ m.

progressive neurologic disease, which started as mild head tremors that progressed over a few years to disequilibrium and unresponsiveness to stimuli. Microscopically, there were degenerative lesions within the caudal cerebrum that consisted primarily of glial foci centered around neurons and small caliber blood vessels. Degenerate glial cells and endothelial cells contained intranuclear inclusion bodies. The damaged endothelial cells and glial cells most likely elicited the glial cell proliferation. The clear space and fibrillar material around some of these blood vessels suggested cerebral edema secondary to endothelial damage.

Transmission electron microscopy of the inclusions within the cerebrum revealed paracrystalline arrays of viral-like particles that had features consistent with adenovirus. Herpesvirus was another differential diagnosis based on the histopathologic results, but herpesviruses are 120–180 nm in diameter and enveloped (Cheville, 1994), which were not electron microscopic features of the virus in this snake. Because of the extensive degenerative lesions within the brain, most of the inclusions appeared by electron microscopy to be free within the neuropil, but this may have been from

release of the arrays following lysis of the cells. Arrays noted by electron microscopy within cells appeared intracytoplasmic. This is not a characteristic of adenovirus, which forms intranuclear arrays (Cheville, 1994). Most of the cells with apparent intracytoplasmic arrays either didn't have a nucleus in the visualized field or had a lysed nucleus.

The technique of DNA *in situ* hybridization used in this study was previously used to help positively identify adenovirus as the cause of hepatitis in a boa constrictor (*Boa constrictor*) (Ramis et al., 2000) and a viral enteropathy in a Mojave rattlesnake (*Crotalus scutulatus scutulatus*) (Perkins et al., 2001). DNA *in situ* hybridization helped to identify the intranuclear inclusions in the brain of this kingsnake as adenoviral-like inclusion bodies.

Viral diseases involving the central nervous system are infrequently reported in snakes. Pythons and boa constrictors with inclusion body disease are sometimes afflicted with nonsuppurative meningoencephalitis (Schumacher et al., 1994b). Ophidian paramyxovirus usually causes pneumonia, but has also been associated with central nervous system disease in rattlesnakes (Jacobson et al., 1980). A reovirus has been isolated from the brain of a rattlesnake with neurologic signs but no lesions were noted microscopically within the brain (Vieler et al., 1994). Adenovirus infection has been previously reported in the gastrointestinal tract, liver, kidneys, and heart of snakes (Heldstab and Bestetti, 1984; Jacobson et al., 1985; Schumacher et al., 1994a; Ramis et al., 2000), but there have been no reports of adenoviral infection in the central nervous system of snakes. Approximately 60% of the DNA sequence of an adenovirus from a corn snake (*Elaphe guttata*) has been cloned and sequenced (Farkas et al., 2002), and a complete DNA sequence of a frog adenovirus has been reported (Davison et al., 2000).

Degenerative lesions in the brain with minimal to no associated inflammation is

not a typical presentation for viral infection. Usually, viral infections of the central nervous system elicit a nonsuppurative type of inflammatory response (Jubb and Huxtable, 1993). However, there is a reported case of a rattlesnake with paramyxoviral infection of the central nervous system that had only gliosis and axonal degeneration (Jacobson et al., 1980), which are lesions similar to the degenerative lesions noted in the cerebrum of this kingsnake.

Adenoviral infection can cause different forms of neurological disease in humans and animals. Adenovirus was associated with fatal cerebral edema in infants (Chatterjee et al., 2000) and adenovirus type 7 has been associated with acute encephalopathy in humans (Kim and Gohd, 1983). Reye's syndrome, a primarily juvenile-onset, neurologic disease linked with salicylates, has been associated with different viral infections including adenovirus (Brown, 1974; Daugherty and Heubi, 1985). Patients can develop encephalopathy characterized by cerebral edema and notable absence of inflammation, which was similar to the lesions noted in this kingsnake. Certain strains of mice infected with mouse adenovirus type-1 can develop fatal hemorrhagic encephalopathy (Guida et al., 1995). This disease causes mainly central nervous system signs like tremors, ataxia, and paralysis. Endothelial cells in the brain and spinal cord are sites of viral infection, leading to vasculature damage (Kajon et al., 1998). The adenoviral-like infection in this kingsnake also primarily affected endothelial cells causing vascular damage and cerebral edema.

This kingsnake had an atypical presentation for adenoviral infection. The viral infection centered within the brain and caused degeneration and necrosis of individual endothelial cells and glial cells. This elicited the edema and gliosis noted with the brain. Though DNA *in situ* hybridization on the brain helped to identify the inclusions as adenovirus, virologic cultures

are needed for definitive confirmation of the adenoviral etiology.

The authors thank R. Brown for assistance with preparation of histopathologic specimens.

LITERATURE CITED

- BROWN, J. M. 1974. Reye's syndrome associated with adenovirus type 3 infection. *Medical Journal of Australia* 2: 873–875.
- CHATTERJEE, N. K., W. A. SAMSONOFF, N. BALASUBRAMANIAM, K. R. WILSON, W. SPARGO, AND T. M. CHURCH. 2000. Isolation and characterization of adenovirus 5 from the brain of an infant with fatal cerebral edema. *Clinical Infectious Diseases* 31: 830–833.
- CHEVILLE, N. F. (Editor). 1994. Cytopathology of viral diseases. In *Ultrastructural pathology: An introduction to interpretation*. Iowa State University Press, Ames, Iowa, pp. 502–517.
- DAUGHERTY, C. C., AND J. E. HEUBI. 1985. Reye's syndrome associated with adenovirus infections. *American Journal of Diseases of Children* 139: 1076–1077.
- DAVISON, A. J., K. M. WRIGHT, AND B. HARRACH. 2000. DNA sequence of frog adenovirus. *Journal of General Virology* 81: 2431–2439.
- FARKAS, S. L., M. BENKO, P. ELO, K. URSU, A. DAN, W. AHNE, AND B. HARRACH. 2002. Genomic and phylogenetic analyses of an adenovirus isolated from a corn snake (*Elaphe guttata*) imply a common origin with members of the proposed new genus *Atadenovirus*. *Journal of General Virology* 83: 2403–2410.
- GUIDA, J. D., G. FEJER, L. A. PIROFSKI, C. F. BROSINAN, AND M. S. HORWITZ. 1995. Mouse adenovirus type 1 causes a fatal hemorrhagic encephalomyelitis in adult C57BL/6 but not BALB/c mice. *Journal of Virology* 69: 7674–7681.
- HELDSTAB, A., AND G. BESTETTI. 1984. Virus associated gastrointestinal diseases in snakes. *Journal of Zoo Animal Medicine* 15: 118–128.
- JACOBSON, E. R., J. M. GASKIN, C. F. SIMPSON, AND T. G. TERRELL. 1980. Paramyxo-like virus infection in a rock rattlesnake. *Journal of the American Veterinary Medical Association* 177: 796–799.
- , ———, AND C. H. GARDINER. 1985. Adenovirus-like infection in a boa constrictor. *Journal of the American Veterinary Medical Association* 187: 1226–1227.
- JUBB, K. V. F., AND C. R. HUXTABLE. 1993. The nervous system. In *Pathology of domestic animals*, 4th Edition, K. V. F. Jubb, P. C. Kennedy, and N. Palmer (eds.). Academic Press, Inc., San Diego, California, pp. 383–428.
- KAJON, A. E., C. C. BROWN, AND K. R. SPINDLER. 1998. Distribution of mouse adenovirus type 1

- in intraperitoneally and intranasally infected adult outbred mice. *Journal of Virology* 72: 1219–1223.
- KIM, K. S., AND R. S. GOHD. 1983. Acute encephalopathy in twins due to adenovirus type 7 infection. *Archives of Neurology* 40: 58–59.
- LATIMER, K. S., F. D. NIAGRO, O. C. WILLIAMS, A. RAMIS, M. A. GOODWIN, B. W. RITCHIE, AND R. P. CAMPAGNOLI. 1997. Diagnosis of avian adenovirus infections using DNA in situ hybridization. *Avian Diseases* 41: 773–782.
- PERKINS, L. E., R. P. CAMPAGNOLI, B. G. HARMON, C. R. GREGORY, W. L. STEFFENS, K. LATIMER, S. CLUBB, AND M. CRANE. 2001. Detection and confirmation of reptilian adenovirus infection by in situ hybridization. *Journal of Veterinary Diagnostic Investigation* 13: 365–368.
- RAMIS, A., H. FERNANDEZ-BELLON, N. MAJO, A. MARTINEZ-SILVESTRE, K. LATIMER, AND R. CAMPAGNOLI. 2000. Adenovirus hepatitis in a boa constrictor (*Boa constrictor*). *Journal of Veterinary Diagnostic Investigation* 12: 573–576.
- SCHUMACHER, J., E. R. JACOBSON, R. BURNS, AND R. R. TRAMONTIN. 1994a. Adenovirus-like infection in two rosy boas (*Lichanura trivirgata*). *Journal of Zoo and Wildlife Medicine* 25: 461–465.
- , ———, B. L. HOMER, AND J. M. GASKIN. 1994b. Inclusion body disease in boid snakes. *Journal of Zoo and Wildlife Medicine* 25: 511–524.
- VIELER, E., W. BAUMGARTNER, W. HERBST, AND G. KOHLER. 1994. Characterization of a reovirus isolate from a rattlesnake, *Crotalus viridis*, with neurological dysfunction. *Archives Virology* 138: 341–344.

Received for publication 14 January 2002.