

EXPERIMENTAL INFECTION OF HOUSE FINCHES WITH MYCOPLASMA GALLISEPTICUM

Authors: Kollias, George V., Sydenstricker, Keila V., Kollias, Heidi W., Ley, David H., Hosseini, Parvizez R., et al.

Source: Journal of Wildlife Diseases, 40(1) : 79-86

Published By: Wildlife Disease Association

URL: <https://doi.org/10.7589/0090-3558-40.1.79>

BioOne Complete (complete.BioOne.org) is a full-text database of 200 subscribed and open-access titles in the biological, ecological, and environmental sciences published by nonprofit societies, associations, museums, institutions, and presses.

Your use of this PDF, the BioOne Complete website, and all posted and associated content indicates your acceptance of BioOne's Terms of Use, available at www.bioone.org/terms-of-use.

Usage of BioOne Complete content is strictly limited to personal, educational, and non - commercial use. Commercial inquiries or rights and permissions requests should be directed to the individual publisher as copyright holder.

BioOne sees sustainable scholarly publishing as an inherently collaborative enterprise connecting authors, nonprofit publishers, academic institutions, research libraries, and research funders in the common goal of maximizing access to critical research.

EXPERIMENTAL INFECTION OF HOUSE FINCHES WITH *MYCOPLASMA GALLISEPTICUM*

George V. Kollias,^{1,4} Keila V. Sydenstricker,¹ Heidi W. Kollias,¹ David H. Ley,²
Parvize R. Hosseini,³ Véronique Connolly,³ and André A. Dhondt³

¹ Wildlife Health Laboratory, College of Veterinary Medicine, Cornell University, Ithaca, New York 14853-6401, USA

² Poultry Health Management, College of Veterinary Medicine, North Carolina State University, Raleigh, North Carolina 27606, USA

³ Bird Population Studies, Laboratory of Ornithology, Cornell University, Ithaca, New York 14850, USA

⁴ Corresponding author (email: gvk2@cornell.edu)

ABSTRACT: *Mycoplasma gallisepticum* (MG) has caused an endemic upper respiratory and ocular infection in the eastern house finch (*Carpodacus mexicanus*) after the epidemic first described in 1994. The disease has been studied by a number of investigators at a population level and reports describe experimental infection in group-housed MG-free house finches. Because detailed observation and evaluation of individual birds in group housed passerines is problematic, we studied individually housed house finches that were experimentally inoculated with the finch strain of MG in a controlled environment. To accomplish this, a study was conducted spanning the period of November 2001–April 2002 with 20 MG-free (confirmed by the rapid plate agglutination assay and polymerase chain reaction [PCR] assay) eastern house finches captured in the Cayuga Basin area of central New York (USA) in the summer of 2001. After a period of acclimatization and observation (12 wk), 20 finches were inoculated with a 0.05-ml aliquot of MG (3.24×10^5 colony-forming units/ml) via bilateral conjunctival sac instillations. Two additional finches acted as controls and were inoculated in the same manner with preservative-free sterile saline solution. After inoculation, all finches except the controls exhibited clinical signs of conjunctivitis within 2–6 days. The progression of the disease was evaluated by several methods, including PCR, behavioral observations, and physical examination including eye scoring, body weight, and body condition index. Over a period of 21 wk, MG-infected finches developed signs of disease and recovered (80%), developed signs of disease and progressed to become chronically infected (15%), or died (5%). We hypothesize that the high survival rate and recovery of these finches after infection was associated with the use of controlled environmental conditions, acclimatization, a high plane of nutrition, and low stocking (housing) density, all of which are factors documented to be important in the outcome of MG infections in domestic poultry and other species.

Key words: *Carpodacus mexicanus*, conjunctivitis, eastern house finch, *Mycoplasma gallisepticum*, respiratory infection.

INTRODUCTION

A new strain of *Mycoplasma gallisepticum* (MG) emerged early in 1994 (Ley et al., 1996; Luttrell et al., 1996) and caused an epidemic of conjunctivitis among house finches (*Carpodacus mexicanus*) in eastern North America (Fisher et al., 1997; Dhondt et al., 1998). Within the next few years the epidemic resulted in a major decline in house finch abundance in the eastern part of their range (Hochachka and Dhondt, 2000). One early experiment with house finches held in small flocks (Luttrell et al., 1998) demonstrated high mortality accompanying natural infections of finches with MG. A second study, also involving small captive flocks of house finches ex-

posed to MG under natural conditions, resulted in low mortality, chronic MG infection in some birds, and recovery in most of the finches exhibiting signs of MG infection (Roberts et al., 2001). In a more recent study with experimentally infected western house finches held in flocks, 10 of the 11 individuals exhibiting signs of MG infection died at various times after infection (Farmer et al., 2002). Our unpublished observations from a long-term field study as well as other studies (Luttrell, 1998; Hartup, 2001; Roberts et al., 2001) show that some free-ranging individuals recover from MG infection.

To further evaluate the possible consequences of MG infection in individual

birds, we designed an experiment in which finches were individually caged in environmentally controlled biosafety isolation rooms, and were individually inoculated. We proposed to determine the incubation period, to examine patterns of mortality, and to describe behavioral changes and other factors that might help explain the putative increased mortality in wild MG-infected finches.

MATERIALS AND METHODS

Sites

We captured 22 house finches, year-hatching birds in a 1:1 sex ratio, by using mist nets or Potter traps (Avinet, Inc., Dryden, New York) in Tompkins County, New York, USA (42°51'N, 76°34'W). Eleven birds were captured between 29 June 2001 and 13 July 2001, and the other 11 were captured between 1 October 2001 and 19 October 2001, under permits from New York State Department of Environmental Conservation (permit LCP 99-039, Albany, New York) and a federal collecting permit (PRT 802829).

Animals

All procedures and protocols were reviewed and approved by the Cornell University Institutional Animal Care and Use Committee (protocol 00-90). Upon arrival in the BL-2 biosafety isolation facility (Poultry Virus Isolation Building, College of Veterinary Medicine, Cornell University, Ithaca, New York), all birds were sexed by feather pattern characteristics and identified with color leg bands. The birds were placed into individual wire bar cages (45 cm high×45 cm wide×75 cm long) with sheet metal barriers placed around and between cages to prevent possible mechanical cross-contamination of MG. We housed the 22 birds in a series of identical cages, including the arrangement of perches and water and food bowls, split in two groups of 11 birds each in separate isolation rooms. Water and a pelleted diet (Rodebush, Inc., Cameron Park, California, USA) were provided ad libitum. The birds were allowed to acclimatize for a period of up to 12 wk under controlled environmental conditions before inoculation (temperature 21–24 C, relative humidity 70%, and light cycle adjusted to ambient values). The entire experiment spanned the period of November 2001–April 2002.

Sampling, polymerase chain reaction, serology, microbiology, parasitology, and necropsy

At 30 and 14 days before inoculation, two baseline blood and conjunctival samplings were used to document that the birds were free of MG infection by polymerase chain reaction (PCR) testing (Lauerman, 1998) and by rapid plate agglutination (RPA) (Kleven, 1998). To validate the RPA in part, we compared the results of fresh (<8 hr) plasma samples collected from 18 house finches (MG-infected and non-infected) with plasma samples from the same finches that had been frozen for 4 wk. The RPA results were the same for fresh vs. frozen plasma samples. The 20 birds were inoculated with MG (sixth in vitro broth passage from the original MG house finch isolate, ADRL 7994-1; Ley et al., 1996) by instillation of droplets into both eyes with 0.05 ml of the inoculum (3.24×10^5 colony-forming units/ml). These birds were immediately returned to their individual isolation cages. Two birds (one male and one female) were inoculated with the same volume of nonpreserved sterile physiologic saline to serve as a control in each trial room.

All finches, including controls, were sampled weekly for the first 6 wk postinoculation (PI) and then every other week PI for 10 wk. In addition to the samples taken during the 16-wk study, all birds were sampled again at week 20 and the chronically infected birds were sampled again at week 25. Sampling consisted of screening for MG by using swabs of the conjunctiva (calcium alginate fiber-tipped ultrafine aluminum applicator swab 14-959-78, Fisher, Pittsburgh, Pennsylvania, USA) placed in culture in Frey's medium with 15% swine serum (Kleven, 1998). In addition, at weeks 1, 8, and 16, the choanal clefts of all birds were swabbed by using the same technique. All samples were tested for MG by PCR analysis and culture in Frey's broth medium at weeks 1, 8, and 16 PI (Ley et al., 1996). *Mycoplasma* spp. were identified by direct immunofluorescence (Kleven, 1998) with fluorescein-conjugated antiserum provided by S. H. Kleven (Department of Avian Medicine, University of Georgia, Athens, Georgia, USA).

Physical findings and other data

Weekly blood samples were collected from the left wing vein into two or three lithium-heparinized microcapillary tubes. The plasma was collected and archived at –70 C for later RPA. Birds were weighed weekly and body condition index (BCI), determined weekly by palpation of the pectoral muscles and sternum, was used to estimate muscle mass as an indicator of overall nutritional state. Other general

TABLE 1. Physical sign (eye scoring) system for house finches inoculated with *Mycoplasma gallisepticum*.

Eye score	Description
0	Normal eye: transparent conjunctiva with well-defined vascularization, normal thickness with hydration film covering the cornea. Eyelid feathers intact.
1	Conjunctival discoloration pink but not red, epiphora (watery), periorbital edema slight or absent.
2	Conjunctival discoloration pink but not red, epiphora with mucoid discharge and slight to moderate periorbital edema.
3	Conjunctiva red, epiphora, and feather matting near the eye only, feather loss around the periorbital ring, edema moderate, possible slight chemosis and rhinitis.
4	Conjunctiva, as in 3, epiphora, feather matting extending below the eye over the infraorbital sinus, edema severe including the area over the infraorbital sinus, significant chemosis involving at least 40% of the conjunctiva, and rhinitis.
5	Conjunctival discoloration red to purple, edema severe including the supraorbital area as well as over the infraorbital sinus; significant chemosis involving at least 80% of the conjunctiva, feather loss and matting extending over the entire side of the face, with rhinitis and nare(s) obstruction.

health information was recorded (but is not reported here). This included assessments of numbers of ecto- and endoparasites, the relative occurrence of feather mites found on the primary feathers of both wings, and weekly fecal collections, for flotation, sedimentation, and direct wet mount examinations used for identification and relative abundance of parasites and their ova. We developed an eye scoring system based on several years of field observations of infected house finches (Table 1) to record the physical changes produced in and around each eye, which would be correlated with other measurable parameters (e.g., MG PCR, culture results, and behavioral changes). A necropsy was performed on the finch that died and samples of all organs were fixed in 10% neutral buffered formalin embedded in paraffin, sec-

TABLE 2. Behaviors recorded in house finches experimentally infected with *Mycoplasma gallisepticum*.

Behavior	Description
Moving	Flying, hopping, or flapping wings while perched. May have pauses of up to 4 sec.
Feeding	Eating pelleted diet, or drinking water.
Inactive	Perched, motionless, eyes open or closed, asleep or awake.
Other	Includes perched, but actively looking, bobbing head, grooming behaviors, and a few rare activities such as grasping bars or perch with beak.

tioned at 5 μ m and stained with hematoxylin and eosin for evaluation by light microscopy. Samples of lung, spleen, trachea, liver, intestine, and kidney were frozen at -70°C for later isolation of MG or other pathogens.

Behavioral observation

In addition to weekly biological sample collection, behavioral observations were made on 11 finches for 1 mo before inoculation, and for 1 mo after inoculation. Initial observations were made to develop a baseline for finches that would be experimentally inoculated. Most behaviors were recorded by continuous observation of a single bird's state for a 10-min period (Altman, 1974). The behaviors were divided into four categories (Table 2). However, observations of two behavioral events were recorded separately from the behaviors listed. The two analyzed here are eye scratching, where a bird rubs or scratches one eye while perching, and vocalization, where a bird produces a short, single note. Birds were observed in a predetermined order to minimize disruption of their behavior by the observer. Observations were made either every day or every other day, although two additional longer intervals occurred.

Statistical analysis

We summarized and compared data on individual birds by sex and duration (in weeks) of physical signs. If no physical signs were observed at a single observation time but signs were observed at the preceeding and following time point, the bird was considered to be diseased. Similarly, if physical signs were observed at a single time point, but signs were not observed at the preceeding and following time point, the bird was considered to be recovered.

This allowed us to define a definite duration of physical signs for all birds, and only involved transitions between eye score 1 and eye score 0, which sometimes fluctuated and were subtle changes. We recorded duration of physical signs as the first time bird was considered healthy.

We also summarized data on individual birds by length of time MG was detectable by PCR. This duration was defined as the first negative test after the last positive test was recorded. This method was chosen because we believed the most parsimonious explanation for the lack of PCR detection was a false negative due to low levels of MG in birds near recovery.

We used survival analysis techniques on these data sets because these tests are appropriate for time data and can use information from cases that continue past the end of the experiment. Thus, average durations for both data sets were calculated by using Kaplan-Meier estimates and the Greenwood formula for standard errors. Mantel-Haenszel tests for significant differences based on sex were performed for both durations (Kalbfleisch and Prentice, 1980). These estimates included the ongoing cases as censored cases (at week 21), but were conditional on survival because the single mortality was omitted from the analysis.

RESULTS

Polymerase chain reaction, serology, microbiology, necropsy, and physical findings

All study finches were negative for MG by PCR analysis and culture, and were negative for antibodies to MG by RPA assay before experimental inoculation. Birds became positive to both assays at 1, 8, and 16 wk PI. A total of 132 samples from 22 finches were collected for culture. Of these, only 20 (15%) were positive. At day 7 PI, only two finches (9%) were culture positive (conjunctiva and choana). At 8 wk PI, nine finches (41%) were culture positive and at 16 wk PI, four finches (18%) were culture positive.

The bird that died lacked histologic lesions in representative sections taken from all major organ systems, with two exceptions. Conjunctival tissues and the upper respiratory passages exhibited heterophilic inflammatory changes. These changes were not considered severe enough to have caused the death of the bird, thus the precise cause of death remains unclear.

Throughout the study, body weights ranged from 16 to 22 g (19.95 ± 1.15 ; $n=22$), for all finches, both inoculated and control, with some finches exhibiting a slight increase in body weight. In general, no change was observed in the body weights of the infected or control birds over the course of the study. The BCI remained at 2 or 3 for all individuals.

All MG-inoculated finches exhibited physical signs of conjunctivitis (eye score) and in some cases rhinitis by 4–5 days PI (range 2–6 days). At 4–6 wk PI, five finches developed bilateral signs of periorbital (infraorbital sinus) swelling. The PCR analysis verified that MG was present in the conjunctiva and choana from all inoculated birds at 7 days PI. All of the birds remained PCR positive (number of samples analyzed = 66) from conjunctiva samples up to 3 wk PI.

By week 21 PI, 16 birds appeared to have recovered based on negative conjunctival PCR results and lack of physical signs. One bird died, and two continued to be MG carriers (PCR positive in their conjunctiva, as well as exhibiting physical signs). One control bird exhibited an initial eye score of 1 at 7 days PI and tested MG PCR positive at that time. This finch also showed a brief period (2 days) of reduced activity. Thus, one control finch apparently contracted a mild infection by direct or indirect exposure to MG. The second control finch was PCR negative, and asymptomatic, throughout the entire study. The bird that died had an average eye score of 3.5 ± 0.5 , which was no higher than some of the birds that eventually recovered.

In 66% of the observations of the finches, right and left eyes received the same score, and of these, 96% both eyes scored within 1 increment of the other. Only 4% of such observations were substantially different from each other.

Figure 1 shows the progression of physical signs throughout the study when using the average eye score, and Figure 2 shows the progression of MG presence using percentage of birds scoring PCR positive,

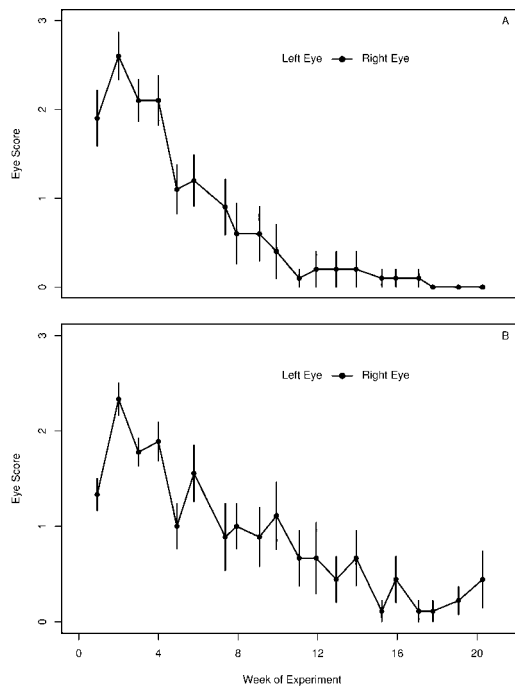


FIGURE 1. Progression of physical signs of conjunctivitis in captive house finches, as marked by eye score (Table 1), over the course of the experiment. (A) Female finches ($n=10$), with one control bird and one bird that died at week 5 excluded. (B) Male finches ($n=9$), with one control bird excluded.

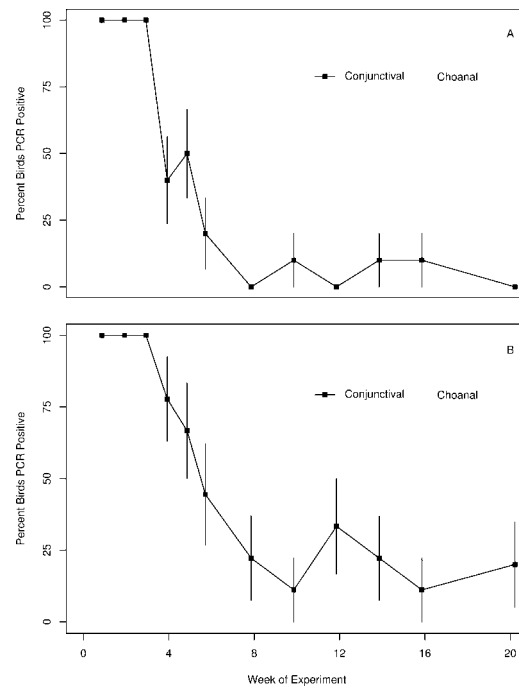


FIGURE 2. Progression of presence of *Mycoplasma gallisepticum* in captive house finches, as detected by polymerase chain reaction, over the course of the experiment. (A) Female finches ($n=10$), with one control bird and one bird that died at week 5 excluded. (B) Male finches ($n=9$), with one control bird excluded.

as detected by PCR analysis (number of samples analyzed = 246). Six finches were excluded from these analyses (one bird that died during the course of the experiment and five birds that continued to exhibit signs of disease). Sixteen birds recovered from MG infection based on physical signs and negative PCR results. The average duration of physical signs in these birds was 10.4 ± 3.4 wk, whereas MG was detected by PCR analysis of conjunctival swabs for 6.3 ± 2.5 wk PI.

Statistical analysis

Physical signs in females ($n=10$) lasted 9.9 wk, with a standard error of 1.1 wk (nine events), whereas physical signs in males ($n=9$) lasted 14.3 wk, with a standard error of 1.6 wk (seven events). The hypothesis that physical signs last a different amount of time in males than in females was not significant, although a po-

tential trend existed ($\chi^2=3.6$, $df=1$, $P=0.06$). Levels of MG detectable by PCR were found in the conjunctiva of females ($n=10$) for 7.1 wk, with a standard error of 1.5 wk (10 events), whereas PCR-detectable levels of MG were found in the conjunctiva of males ($n=9$) for 10.5 wk, with a standard error of 2.1 wk (eight events). The hypothesis that MG is detectable in males for a different amount of time than in females was not significant ($\chi^2=2$, $df=1$, $P=0.15$). Figure 1 shows that MG continued to be detected in the choana of female birds for a much longer period of time than in the conjunctiva, but the limited number of samples did not provide a useful estimate of duration.

Behavioral observations

Behavioral observations revealed depressed motor activity at 4 days PI (Fig.

3). Motor activities were substantially reduced, but other behaviors also declined slightly. Notably, time spent feeding did not decline during the period of observation. Additionally, all finches demonstrated long periods of inactivity (perching at one position for up to 30 min without wing movement, hopping, etc.) and little or no response to the approach of the observer to within 30.5 cm of the cage. As physical signs associated with MG infection progressed, behavior and response to stimuli continued to decrease until the finch made no avoidance response when hand captured. This response was most often associated with severe conjunctival swelling (edema) but not the total closure of the eyelids.

DISCUSSION

Individually caged house finches, maintained indoors at 21–24 °C, 70% relative humidity, and ambient light, and infected with MG exhibit high morbidity (100%) and low mortality (5%). Our results are in part similar to those of other published reports (Luttrell et al., 1998; Roberts et al., 2001; Farmer et al., 2002). In the controlled environmental and housing conditions that we used, experimentally infected finches exhibited much lower mortality, but similar rates of recovery or chronic infection.

The time period from MG inoculation until physical signs of conjunctivitis were observed (incubation period) was determined to be approximately 4 days, which was similar to the results of a recently published similar study (Farmer et al., 2002). This is different from the incubation period of 10–14 days reported when MG is transmitted horizontally in captive groups of house finches (Luttrell et al., 1998; Roberts et al., 2001). The difference could be due to a variety of factors (exposure of each bird with a relatively high infectious dose of organisms, flock dynamics, virulence of infecting doses, etc.) (Ley and Yoder, 1997).

All finches exhibited decreased motor

activity (physical depression) for a period beginning at 4 days PI. We postulate that the high survival rate of these finches relates to their being preconditioned (acclimatized for 12 wk) to their immediate environment, which allowed them to easily locate food and water. This is in contrast to free-ranging finches that become infected with MG and are exposed to stressful environmental factors (e.g., low ambient temperatures and wind chill, predators, and possibly intraspecific aggression, etc.) during the winter months and exhibit high mortality (Hochachka and Dhondt, 2000).

A good correlation ($0.546 < r < 0.712$, 95% confidence interval, $r = 0.637$) was demonstrated between MG PCR and the presence or absence of physical signs (conjunctivitis, rhinitis, or infraorbital sinusitis), whereas *in vitro* isolation of MG was poorly correlated with the presence or absence of the same set of physical signs. This may be related to sample handling, storage, and shipping, rather than the presence or absence of MG in the samples. In a similar study, culture failure was potentially attributed to media failure, inhibitory substances in tissues, and the fastidious nature of MG (Luttrell et al., 1998).

When the choana was sampled for MG PCR analysis, positive results were attained for a longer period of time (see Fig. 2) when compared to results from conjunctival samples. Taken simultaneously (in parallel) these results are of practical significance when sampling finches that may have low numbers of MG present in the conjunctiva or are chronically infected with MG. Studies are underway to further evaluate these results.

Finally, diet (nutrition) and lack of competition for food may have been one of the factors contributing to the high survival rate (95%) and maintenance of body condition (body weight and BCI) of the experimentally infected finches when compared to other published reports. In other studies the diet offered to finches was a

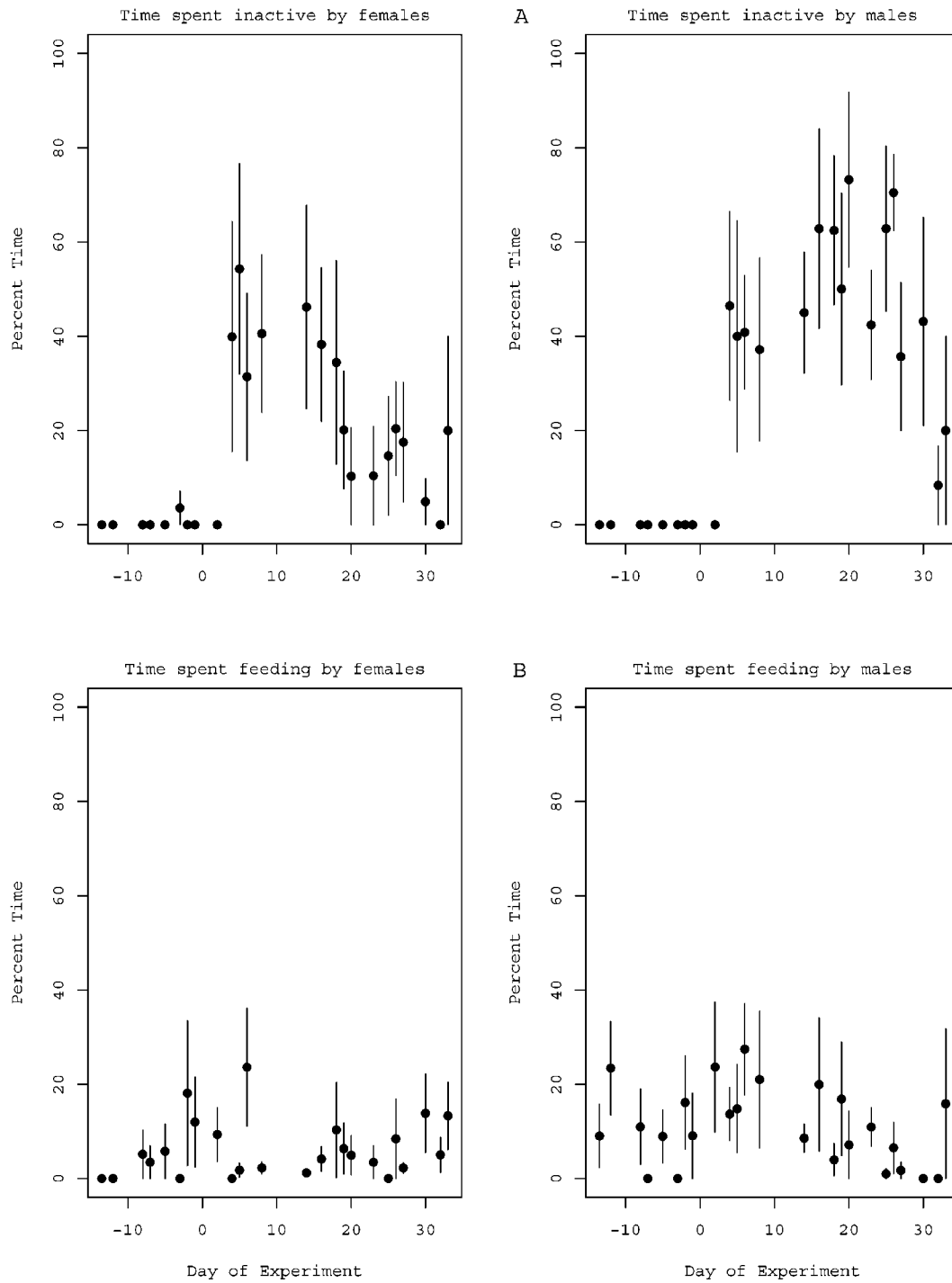


FIGURE 3. Behavioral observations on five female and six male house finches, based on 240 10-min observations.

standard seed mix, which has been documented to be deficient in a number of nutrients, including vitamin A, which is known to be important for epithelial integrity. In our study, a nutritionally complete extruded commercially prepared passerine diet was used.

In conclusion, our study has added to the existing body of published information relating to MG infection in eastern house finches by documenting, through laboratory, observational, and physical methods, the progression and eventual outcome of the disease in individually housed finches, when compared to similar studies where finches were held in small groups or flocks.

ACKNOWLEDGMENTS

The authors would like to thank W. Hochachka, S. Huyan, E. Swarthout, C. Satyshur, and B. Lucio for their contributions. This study was funded by a joint National Science Foundation (NSF) grant (DEB-0094456) supporting the collaborative study of the ecology of infectious diseases. Any opinions, findings, and conclusions or recommendations expressed in this material are those of the authors and do not necessarily reflect the views of the NSF.

LITERATURE CITED

- ALTMAN, J. 1974. Observational study of behavior sampling methods. *Behavior* 49: 227–265.
- DHONDT, A. A., D. L. TESSAGLIA, AND L. SLOTHOWER. 1998. Epidemic mycoplasmal conjunctivitis in house finches from eastern North America. *Journal of Wildlife Diseases* 34: 265–280.
- FARMER, K. L., G. E. HILL, AND S. R. ROBERTS. 2002. Susceptibility of a naïve population of house finches to *Mycoplasma gallisepticum*. *Journal of Wildlife Diseases* 36: 282–286.
- FISHER, J. J., D. E. STALLKNECHT, M. P. LUTTRELL, A. A. DHONDT, AND K. A. CONVERSE. 1997. Mycoplasmal conjunctivitis in wild songbirds: The spread of a new contagious disease in a mobile host population. *Emerging Infectious Diseases* 31: 69–72.
- HARTUP, B. K., G. V. KOLLIAS, AND D. H. LEY. 2001. Mycoplasmal conjunctivitis in songbirds from New York. *Journal of Wildlife Diseases* 36: 257–264.
- HOCHACHKA, W. M., AND A. A. DHONDT. 2000. Density-dependent decline of host abundance resulting from a new infectious disease. *Proceedings of the National Academy of Science* 97: 5303–5306.
- KALBFLEISCH, J. D., AND R. L. PRENTICE. 1980. The statistical analysis of failure time data. John Wiley and Sons, New York, New York, 321 pp.
- KLEVEN, S. H. 1998. Mycoplasmosis. In *A laboratory manual for the isolation and identification of avian pathogens*, D. E. Swayne, J. R. Glisson, M. W. Jackwood, J. E. Pearson and W. M. Reed (eds.). American Association of Avian Pathologists, Kennett Square, Pennsylvania, pp. 74–80.
- LAUERMAN, L. H. 1998. Mycoplasma PCR assays. In *Nucleic acid amplification assays for diagnosis of animal diseases*, L. H. Lauerman (ed.). American Association of Veterinary Laboratory Diagnosticians, Turlock, California, pp. 41–42.
- LEY, D. H., AND H. W. J. YODER. 1997. *Mycoplasma gallisepticum* infection. In *Diseases of poultry*, 10th Edition, B. W. Calnek, H. J. Barnes, C. W. Beard, L. R. McDougald, and Y. M. Saif (eds.). Iowa State University Press, Ames, Iowa, pp. 194–207.
- , J. E. BERKHOF, AND J. M. McLAREN. 1996. *Mycoplasma gallisepticum* isolated from house finches (*Carpodacus mexicanus*) with conjunctivitis. *Avian Diseases* 40: 480–483.
- LUTTRELL, M. P., J. R. FISCHER, D. E. STALLKNECHT, AND S. H. KLEVEN. 1996. Field investigation of *Mycoplasma gallisepticum* infections in house finches (*Carpodacus mexicanus*) from Maryland and Georgia. *Avian Diseases* 40: 335–341.
- , D. E. STALLKNECHT, J. R. FISHER, C. T. SEWELL, AND S. H. KLEVEN. 1998. Natural *Mycoplasma gallisepticum* infection in a captive flock of house finches. *Journal of Wildlife Diseases* 34: 289–296.
- ROBERTS, S. R., P. M. NOLAN, AND G. F. HILL. 2001. Characterization of mycoplasmal conjunctivitis in captive house finches (*Carpodacus mexicanus*) in 1998. *Avian Diseases* 45: 70–75.

Received for publication 30 December 2002.