



## **Eastern Equine Encephalitis in a Free-ranging White-tailed Deer (*Odocoileus virginianus*)**

Authors: Tate, Cynthia M., Howerth, Elizabeth W., Stallknecht, David E., Allison, Andrew B., Fischer, John R., et al.

Source: Journal of Wildlife Diseases, 41(1) : 241-245

Published By: Wildlife Disease Association

URL: <https://doi.org/10.7589/0090-3558-41.1.241>

---

BioOne Complete ([complete.BioOne.org](https://complete.BioOne.org)) is a full-text database of 200 subscribed and open-access titles in the biological, ecological, and environmental sciences published by nonprofit societies, associations, museums, institutions, and presses.

Your use of this PDF, the BioOne Complete website, and all posted and associated content indicates your acceptance of BioOne's Terms of Use, available at [www.bioone.org/terms-of-use](https://www.bioone.org/terms-of-use).

Usage of BioOne Complete content is strictly limited to personal, educational, and non - commercial use. Commercial inquiries or rights and permissions requests should be directed to the individual publisher as copyright holder.

---

BioOne sees sustainable scholarly publishing as an inherently collaborative enterprise connecting authors, nonprofit publishers, academic institutions, research libraries, and research funders in the common goal of maximizing access to critical research.

## Eastern Equine Encephalitis in a Free-ranging White-tailed Deer (*Odocoileus virginianus*)

Cynthia M. Tate,<sup>1,2</sup> Elizabeth W. Howerth,<sup>1,3</sup> David E. Stallknecht,<sup>1,2</sup> Andrew B. Allison,<sup>1,2</sup> John R. Fischer,<sup>1,3</sup> and Daniel G. Mead<sup>1,2,4</sup> Southeastern Cooperative Wildlife Disease Study; <sup>2</sup> Department of Medical Microbiology and Parasitology; <sup>3</sup> Department of Pathology, College of Veterinary Medicine, University of Georgia, Athens, Georgia 30602, USA; and <sup>4</sup> Corresponding author (email: dstall@vet.uga.edu).

**ABSTRACT:** Eastern equine encephalitis (EEE) was diagnosed in a free-ranging, adult, male white-tailed deer (*Odocoileus virginianus*) from Houston County, Georgia, USA, in July 2001. The yearling buck had neurologic disease and died during transport to our diagnostic facility. Eastern equine encephalitis virus (EEEV) was isolated in Vero cell culture and identified by reverse-transcriptase polymerase chain reaction; as well, EEEV antigen was detected in brain by immunohistochemistry. This is the first report of fatal EEEV infection in a white-tailed deer. Antibodies to EEEV were demonstrated by microtiter neutralization in 14 of 99 (14%) of the white-tailed deer from Georgia sampled in fall 2001. Most antibody-positive deer originated from the Coastal Plain physiographic region. Eastern equine encephalitis virus should be considered a possible cause of neurologic disease in white-tailed deer where it may occur.

**Key words:** Antibodies, eastern equine encephalitis, eastern equine encephalitis virus, immunohistochemistry, neurologic disease, white-tailed deer.

Eastern equine encephalitis virus (*Alphavirus, Togaviridae*, EEEV) is the causative agent of eastern equine encephalitis, an acute neurologic disease of humans, horses, swine, and birds (Pursell et al., 1972; Peters and Dalrymple, 1990). The virus is focally endemic in eastern North America, the Caribbean, and Central and South America (Morris, 1988). enzootic maintenance of EEEV in North America is attributed to a cycle involving the highly ornithophilic mosquito *Culiseta melanura* and avian amplifying hosts roosting near wetland *C. melanura* breeding sites (Crans, 1962; Morris, 1988; Komar et al., 1999). Although *C. melanura* has been documented to feed on mammals, including humans, horses, swine, and deer (Moussa et al., 1966; Chamberlain et al., 1969), it is hypothesized that sporadic epidemics and epizootics of EEE occur due

to the activity of bridge vectors, such as the mosquitoes *Aedes vexans* and *Coquillettidia perturbans* (Crans and Schulze, 1986; Cupp et al., 2003). White-tailed deer (*Odocoileus virginianus*) from Florida, Iowa, Nebraska, New York, North Dakota, Texas, Wisconsin, and Wyoming, USA, and Quebec, Canada, have been serologically tested for antibodies to EEEV (Trainer and Hanson, 1969; Whitney et al., 1969; Hoff et al., 1973; Whitney, 1973; Bigler et al., 1975; Forrester, 1992). Although antibodies to EEEV are reported from white-tailed deer sampled in Florida, USA (Bigler et al., 1975; Forrester, 1992) and North Dakota, USA (Hoff et al., 1973), clinical disease due to EEEV has not been documented in this species.

Here, we describe a fatal case of EEE in a naturally infected, free-ranging white-tailed deer, and we report the prevalence of EEEV antibodies in Georgia, USA, white-tailed deer during the harvest season immediately following detection of this case.

On 1 July 2001, employees of Warner Robbins Air Force Base (32°37'N, 83°35'W), in Houston County, Georgia, USA, found a 12-mo-old, male white-tailed deer, described to be “in a slumber.” Once aroused, the deer allowed a rope harness to be placed over its head, and it was led into a crate for transport to the Southeastern Cooperative Wildlife Disease Study (SCWDS), College of Veterinary Medicine, University of Georgia, Athens, Georgia, USA. The deer died in transit.

A necropsy was performed, and representative samples from major organs (brain, liver, lungs, trachea, spleen, kidney,

skeletal muscle, adrenal glands, gastrointestinal tract, and integument) were preserved in 10% buffered formalin for histopathologic and immunohistochemical analyses. Immunohistochemical staining for detection of EEEV, using mouse anti-EEEV monoclonal antibody, was performed on brain, lung, gastrointestinal tract, spleen, and liver as described by Gottdenker et al. (2003). As a matter of routine testing for all cervid brains, immunohistochemical staining for the detection of prion protein was performed on a section of obex (Spraker et al., 2002). Fresh sections of brain were submitted for fluorescent antibody tests for rabies virus (Valleca and Forrester, 1981) and *Listeria monocytogenes* (Johnson et al., 1995). Fresh spleen and lung samples were submitted for isolation of epizootic hemorrhagic disease (EHD) and bluetongue (BT) viruses using calf pulmonary artery endothelial cells (Quist et al., 1997). Additional virus isolations were attempted on frozen samples of lung, heart, spleen, brain, and kidney, using Vero cells.

The affected deer was in fair physical condition, with adequate stores of body fat. There was evidence of old bruising around the anus, as well as lacerations on the legs and neck. The antlers were bloody. However, there was no evidence of trauma on the calvarium, in the cranial vault, or to the brain, vertebral column, spinal cord, major muscle groups, or viscera. The buck was approximately 7% dehydrated, and cerebrospinal fluid was transparent and dark yellow. Serosanguinous fluid (approximately 75 ml) was present in the abdominal and thoracic cavities. The lungs were heavy, hemorrhagic, and edematous. Froth was present in the trachea and main bronchi. There were a few petechiae on the surfaces of the heart and pulmonary artery. Edges of the liver were rounded, and renal parenchyma bulged on the cut surface. The rumen was filled with water and a few willow leaves, and the abomasum contained green, watery contents. The bladder was full of urine containing a

large amount of sediment, and the rectum contained fecal pellets. Gross lesions were not apparent in the ear canals, oral cavity, nasal cavity, eyes, esophagus, spleen, adrenal glands, or testes.

Microscopic findings included multifocal encephalitis and meningitis. Leptomeninges throughout the brain had diffuse, but primarily perivascular, infiltration of moderate to large numbers of lymphocytes, lesser numbers of plasma cells, and few neutrophils. In the cerebrum, many vessels were surrounded by a mixed inflammatory infiltrate of moderate to large numbers of lymphocytes, plasma cells, and neutrophils, and there were scattered foci of chromatolytic or shrunken necrotic neurons with adjacent gliosis admixed with few neutrophils and cell debris. Scattered, chromatolytic Purkinje cells and foci of status spongiosus were present in cerebellum. Perivascular and parenchymal inflammatory changes were more pronounced in the brain stem, particularly the midbrain and caudally, in which there were multiple foci, resembling micro-abscesses, of chromatolytic and necrotic neurons surrounded by neutrophils admixed with fewer glial cells and lymphocytes.

In the lung, there was diffuse, severe congestion and multifocal hemorrhages, as well as alveolar and perivascular edema. There was diffuse renal and splenic congestion. In the kidney, there was multifocal hemorrhage, and within renal medullary interstitium, there were randomly scattered foci of moderate numbers of lymphocytes and plasma cells. One section of intestine was focally hemorrhagic. Lesions were not apparent in sections of oral mucosa, esophagus, lymph node, tonsil, skeletal muscle, liver, adrenal glands, abomasum, rumen, bladder, or testis. Heart was not available for microscopic examination. Eastern equine encephalitis virus antigen was detected by immunohistochemistry in the cytoplasm of scattered dying neurons and their processes in brain stem nuclei (Fig. 1). Viral antigen was not detected by

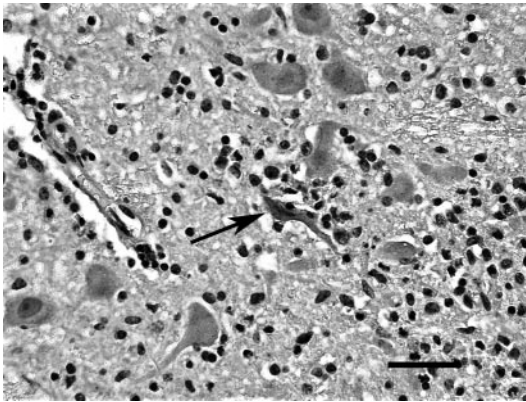


FIGURE 1. Eastern equine encephalitis virus immunohistochemical staining in an inflammatory focus in brain stem nucleus of a white-tailed deer. Note the necrotic immunopositive neuron (arrow) and multiple, swollen, chromatolytic, immunonegative neurons. Fast-red chromagen with hematoxylin counterstain. Bar = 20  $\mu$ m.

immunohistochemistry in other areas of the brain or other tissues.

Vero cells inoculated with brain tissue showed cytopathic effects within 24 hr. Subsequently, total RNA was extracted from these cultures, using the QIAmp Viral RNA Mini-Kit (QIAGEN, Inc., Valencia, California, USA). The virus was identified as EEEV based on positive reverse-transcriptase polymerase chain reaction results (Huang et al., 2001) with confirmation by the Division of Vector-Borne Infectious Diseases, Centers for Disease Control, Fort Collins, Colorado, USA. Test results for chronic wasting-disease prions, rabies virus, *L. monocytogenes*, and EHD and BT viruses were negative.

In light of the diagnosis of EEEV infection in this deer, serologic testing was per-

formed on 99 serum samples collected from hunter-killed white-tailed deer during October and November 2001 (Table 1). Samples were tested for antibodies to EEEV by microtiter neutralization as described (Elvinger et al., 1996). Antigen consisted of 100 50% tissue-culture infectious doses (TCID<sub>50</sub>) of the EEEV isolated from the affected deer. Neutralization at a serum dilution of 1:10 or higher was considered positive. All EEEV antibody-positive samples also were tested against 100 TCID<sub>50</sub> of a Georgia, USA, isolate of Highlands J virus (*Alphavirus, Togaviridae*) using the same protocol.

Neutralizing antibodies to EEEV were detected in 14 (14%) of tested deer (Table 1). Positive titers ranged from 10 to 320. Age classes of EEEV antibody-positive deer ranged from 1.5 yr to 4.5 yr. The majority (92%) of EEEV antibody-positive deer were from two locations in the Coastal Plain physiographic region. Of Coastal Plain deer tested, 13 (32%) were positive for EEEV antibodies. Neutralizing antibodies to Highlands J virus were not detected in EEEV seropositive deer. Additionally, antibody cross-reactivity between the two viruses was not observed.

Histologic findings in the central nervous system of the affected deer were similar to those of EEEV infection in horses (Del Piero et al., 2001). Gross lesions, such as edema and hemorrhage of the lungs, pleural and peritoneal effusion, and petechiation of pulmonary artery, were suggestive of hemorrhagic disease, a common cause of mortality in white-tailed deer in the southeastern United States during late

TABLE 1. Antibodies to eastern equine encephalitis virus in white-tailed deer, Georgia, USA, in 2001.

Location <sup>a</sup>	Physiographic region	Prevalence (percent positive)	Antibody titer range
Berry College WMA	Ridge and valley	0/20 (0%)	—
Lake Russell	Piedmont	1/19 (5%)	40
Nilo Plantation	Coastal plain	2/20 (10%)	320
Dixon Memorial Forest	Coastal plain	11/20 (55%)	10–320
Ossabaw Island	Barrier island	0/20 (0%)	—

<sup>a</sup> Latitude and longitude: Berry College (34°19'N, 85°10'W); Lake Russell (34°32'N, 83°24'W); Nilo Plantation (31°27'N, 84°15'W); Dixon Memorial Forest (31°09'N, 82°14'W); Ossabaw Island (31°47'N, 81°06'W).



summer and fall (Howerth et al., 2001). However, neither EHD nor BT viruses, the causative agents of hemorrhagic disease, were isolated.

This case of EEE preceded two equine cases in Houston County, Georgia, USA. These cases were diagnosed on 11 August 2001 and 13 September 2001. Houston County is located in the Coastal Plain physiographic region, which is an area known to be enzootic for EEEV (Pursell et al., 1972). During the deer hunting season immediately following this clinical case, antibodies to EEEV were detected in 32% of deer sampled from two Coastal Plain locations in Georgia, USA. At one of those sites, Dixon Memorial Forest located in Ware County, 55% of deer sampled were seropositive for EEEV. The fact that over half of the deer sampled at this location were seropositive could mean that deer may be frequently exposed to the virus in endemic locations. It is interesting to note that a fatal human case of EEE was documented in adjacent Charlton County, Georgia, USA, during this same year (Georgia Department of Human Resources, Division of Public Health; Kelly, pers. comm.).

Because there are no reports of disease due to EEEV in deer, coupled with a relatively high antibody prevalence at endemic sites, we believe that deer are commonly infected with this virus in Georgia but are relatively refractory to clinical disease. It is our belief that EEE is not an important disease in white-tailed deer in the southeastern United States. However, EEEV infection should be included in the differential diagnosis of neurologic disease and should be considered from a biosafety standpoint when developing necropsy and supportive diagnostic protocols for white-tailed deer.

Work was supported by the Federal Aid to Wildlife Restoration Act (50 Stat. 917) and through sponsorship of SCWDS from fish and wildlife agencies in Alabama, Arkansas, Florida, Georgia, Kansas, Kentucky, Louisiana, Maryland, Mississippi,

Missouri, North Carolina, Oklahoma, Puerto Rico, South Carolina, Tennessee, Virginia, and West Virginia. Additional support was provided by the Georgia Department of Human Resources through the Centers for Disease Control and Prevention's "Epidemiology and Laboratory Capacity for Infectious Diseases" grant program, contract 27-93-25328.

#### LITERATURE CITED

- BIGLER, W. J., E. LASSING, E. BUFF, A. L. LEWIS, AND G. L. HOFF. 1975. Arbovirus surveillance in Florida: Wild vertebrate studies 1965–1974. *Journal of Wildlife Diseases* 11: 348–356.
- CHAMBERLAIN, R. W., W. D. SUDIA, P. H. COLEMAN, J. G. JOHNSTON, JR., AND T. H. WORK. 1969. Arbovirus isolations from mosquitoes collected in Waycross, Georgia, 1963, during an outbreak of equine encephalitis. *American Journal of Epidemiology* 89: 82–88.
- CRANS, W. J. 1962. Bloodmeal preference studies with New Jersey mosquitoes. *Proceedings of the New Jersey Mosquito Exterminators Association* 49: 120–126.
- , AND T. L. SCHULZE. 1986. Evidence incriminating *Coquillettidia perturbans* (Diptera: Culicidae) as an epizootic vector of eastern equine encephalitis. Isolation of EEE virus from *C. perturbans* during an epizootic among horses in New Jersey. *Bulletin of the Society of Vector Ecology* 11: 178–184.
- CUPP, E. W., K. KLINGLER, H. K. HASSAN, L. M. VIGUERS, AND T. R. UNNASCH. 2003. Transmission of eastern equine encephalomyelitis virus in central Alabama. *American Journal of Tropical Medicine and Hygiene* 68: 495–500.
- DEL PIERO, F., P. A. WILKINS, E. J. DUBOVI, B. BIOLATTI, AND C. CANTILE. 2001. Clinical, pathologic, immunohistochemical and virologic findings of eastern equine encephalomyelitis in two horses. *Veterinary Pathology* 38: 451–456.
- ELVINGER, F., C. A. BALDWIN, A. D. LICETT, K. N. TANG, AND D. E. STALLKNECHT. 1996. Prevalence of exposure to eastern equine encephalitis virus in domestic and feral swine in Georgia. *Journal of Veterinary Diagnostic Investigation* 8: 481–484.
- GOTTDENKER, N. L., E. W. HOWERTH, AND D. G. MEAD. 2003. Natural infection of a great egret (*Casmerodius albus*) with eastern equine encephalitis virus. *Journal of Wildlife Diseases* 29: 702–706.
- FORRESTER, D. J. 1992. White-tailed deer. In *Parasites and diseases of wild mammals in Florida*, D. J. Forrester (ed.). University Press of Florida, Gainesville, Florida, pp. 275–353.
- HOFF, G. L., C. J. ISSEL, D. O. TRAINER, AND S. H.

- RICHARDS. 1973. Arbovirus serology in North Dakota mule and white-tailed deer. *Journal of Wildlife Diseases* 9: 291–295.
- HOWERTH, E. W., D. E. STALLKNECHT, AND P. D. KIRKLAND. 2001. Bluetongue, epizootic hemorrhagic disease, and other orbivirus-related diseases. *In* *Infectious diseases of wild mammals*, 3rd Edition. E. S. Williams and I. K. Barker (eds.). Iowa State University Press, Ames, Iowa, pp. 77–97.
- HUANG, C., B. SLATER, W. CAMPBELL, J. HOWARD, AND D. WHITE. 2001. Detection of arboviral RNA directly from mosquito homogenates by reverse-transcription polymerase chain reaction. *Journal of Virological Methods* 94: 121–128.
- JOHNSON, G. C., W. H. FALES, C. W. MADDOX, AND J. A. RAMOS-VARA. 1995. Evaluation of laboratory tests for confirming the diagnosis of encephalitic listeriosis in ruminants. *Journal of Veterinary Diagnostic Investigation* 7: 223–228.
- KOMAR, N., D. J. DOHM, M. J. TURRELL, AND A. SPIELMAN. 1999. Eastern equine encephalitis in birds: Relative competence of European starlings (*Sturnus vulgaris*). *American Journal of Tropical Medicine and Hygiene* 60: 387–391.
- MORRIS, C. D. 1988. Eastern equine encephalitis. *In* *The arboviruses: Epidemiology and ecology*, Vol. 3, P. T. Monath (ed.). CRC Press, Boca Raton, Florida, pp. 1–20.
- MOUSSA, M. A., D. J. GOULD, M. P. NOLAN JR., AND D. E. HAYES. 1966. Observations on *Culiseta melanura* (Coquillett) in relation to encephalitis in southern Maryland. *Mosquito News* 26: 385–393.
- PETERS, C. J., AND J. M. DALRYMPLE. 1990. Alphaviruses. *In* *Fields virology*, Vol. 1, 2nd Edition, B. N. Fields, and D. M. Knipe (eds.). Raven Press, New York, New York, pp. 713–751.
- PURSELL, A. J., J. C. PECKHAM, J. R. COLE JR., W. C. STEWART, AND F. E. MITCHELL. 1972. Naturally occurring and artificially induced eastern encephalomyelitis in pigs. *Journal of the American Veterinary Medical Association* 161: 1143–1147.
- QUIST, C. F., E. W. HOWERTH, D. E. STALLKNECHT, J. BROWN, T. PISELL, AND V. F. NETTLES. 1997. Host defense responses associated with experimental hemorrhagic disease in white-tailed deer. *Journal of Wildlife Diseases* 33: 584–599.
- SPRAKER, T. R., R. R. ZINK, B. A. CUMMINGS, M. A. WILD, M. W. MILLER, AND K. I. O'ROURKE. 2002. Comparison of histological lesions and immunohistochemical staining of proteinase-resistant prion protein in a naturally occurring spongiform encephalopathy of free-ranging mule deer (*Odocoileus hemionus*) with those of chronic wasting disease of captive mule deer. *Veterinary Pathology* 39: 110–119.
- TRAINER, D. O., AND R. P. HANSON. 1969. Serologic evidence of arbovirus infections in wild ruminants. *American Journal of Epidemiology* 90: 354–358.
- VELLECA, W. M., AND F. T. FORRESTER. 1981. Laboratory methods for detecting rabies. Centers for Disease Control, Atlanta, Georgia, 159 pp.
- WHITNEY, E. 1973. Serologic evidence of group A and B arthropod-borne virus activity in New York State. *American Journal of Tropical Medicine and Hygiene* 12: 417–424.
- WHITNEY, E., A. P. ROZ, G. A. RAYNER, AND R. DIEBEL. 1969. Serologic survey for arbovirus activity in deer sera from nine counties in New York State. *Bulletin of the Wildlife Disease Association* 5: 392–397.

*Received for publication 10 May 2004.*