



## Lead Poisoning in Whooper and Tundra Swans

Authors: Nakade, Tetsuya, Tomura, Yoshihiro, Jin, Kazuo, Taniyama, Hiroyuki, Yamamoto, Mutsuki, et al.

Source: Journal of Wildlife Diseases, 41(1) : 253-256

Published By: Wildlife Disease Association

URL: <https://doi.org/10.7589/0090-3558-41.1.253>

---

BioOne Complete ([complete.BioOne.org](https://complete.BioOne.org)) is a full-text database of 200 subscribed and open-access titles in the biological, ecological, and environmental sciences published by nonprofit societies, associations, museums, institutions, and presses.

Your use of this PDF, the BioOne Complete website, and all posted and associated content indicates your acceptance of BioOne's Terms of Use, available at [www.bioone.org/terms-of-use](https://www.bioone.org/terms-of-use).

Usage of BioOne Complete content is strictly limited to personal, educational, and non - commercial use. Commercial inquiries or rights and permissions requests should be directed to the individual publisher as copyright holder.

---

BioOne sees sustainable scholarly publishing as an inherently collaborative enterprise connecting authors, nonprofit publishers, academic institutions, research libraries, and research funders in the common goal of maximizing access to critical research.

## Lead Poisoning in Whooper and Tundra Swans

Tetsuya Nakade,<sup>1,7</sup> Yoshihiro Tomura,<sup>1</sup> Kazuo Jin,<sup>2</sup> Hiroyuki Taniyama,<sup>3</sup> Mutsuki Yamamoto,<sup>1</sup> Aya Kikkawa,<sup>1</sup> Kunitaro Miyagi,<sup>1</sup> Eiji Uchida,<sup>1</sup> Mitsuhiko Asakawa,<sup>4</sup> Takeshi Mukai,<sup>5</sup> Masahiko Shirasawa,<sup>5</sup> and Mamoru Yamaguchi<sup>6</sup> <sup>1</sup> Department of Small Animal Clinical Sciences, School of Veterinary Medicine, Rakuno Gakuen University, 582 Bunkyo-dai-Midorimachi, Ebetsu, Hokkaido 069-8501, Japan; <sup>2</sup> Hokkaido Institute of Public Health, Sapporo 060-0816, Japan; <sup>3</sup> Laboratory of Veterinary Pathology, School of Veterinary Medicine, Rakuno Gakuen University, 582 Bunkyo-dai-Midorimachi, Ebetsu, Hokkaido 069-8501, Japan; <sup>4</sup> Laboratory of Veterinary Parasitology, School of Veterinary Medicine, Rakuno Gakuen University, 582 Bunkyo-dai-Midorimachi, Ebetsu, Hokkaido 069-8501, Japan; <sup>5</sup> Sapporo Maruyama Zoo, Sapporo 064-0959, Japan; <sup>6</sup> Muscle Biology Research Lab, Department of Veterinary Biosciences, Ohio State University, Columbus, Ohio 43210, USA; <sup>7</sup> Corresponding author (email: tnakade@rakuno.ac.jp)

**ABSTRACT:** Six weak whooper swans (*Cygnus cygnus*) and two weak tundra swans (*Cygnus columbianus*) were found at Swamp Miyajima (Hokkaido, Japan) in May 1998. Anorexia, depression, green watery feces, pale conjunctiva, and anemia were observed. Radiographs showed from six to 38 suspected lead pellets in the gizzard. Blood lead concentrations were 2.5–6.7 µg/g (mean±SD=4.6±1.14 µg/g) on day 1. After blood collection, the birds were treated with calcium disodium ethylenediaminetetraacetate (CaEDTA) given intravenously and force fed. Despite treatment, seven birds died the next day. Green, bile-stained livers and pale or green kidneys were observed on necropsy. Microscopically, bile pigment was widespread in the liver and acid-fast intranuclear inclusion bodies were observed in renal tubular epithelium. Lead concentrations in livers and kidneys were 14.0–30.4 µg/g and 30.2–122 µg/g wet weight, respectively. Only one bird survived and this whooper swan continued to be treated with CaEDTA and activated charcoal. No lead shot was observed in the proventriculus and gizzard by radiography on day 64 and the blood lead concentration decreased from 2.9 µg/g to 0.09 µg/g during that same period. After 4 mo of rehabilitation, the whooper swan was returned to the wild. Lead intoxication continues to be a problem at Swamp Miyajima.

**Key words:** *Cygnus columbianus*, *Cygnus cygnus*, lead poisoning, lead shot, rehabilitation, Swamp Miyajima, tundra swan, whooper swan.

Lead poisoning in free-flying waterfowl in Japan has been reported for more than a decade (Honda et al., 1990; Ochiai et al., 1992, 1993, 1999). The first case of lead poisoning caused by ingestion of shotgun pellets by whooper swans (*Cygnus cygnus*) was reported at Swamp Miyajima (Hokkaido, Japan; 43°20'N, 141°43'E) in 1989

(Ochiai et al., 1992). Swamp Miyajima is a small, open, shallow freshwater swamp of 41 ha surrounded by rice paddies. The swamp is the northernmost concentration of greater white-fronted geese (*Anser albifrons*) in Japan. Every spring and autumn, as many as 40,000 white-fronted geese, 590 whooper swans, and 8,600 tundra swans (*Cygnus columbianus*) use the swamp. To prevent lead poisoning, the waterfowl hunt was voluntary controlled beginning in the autumn of 1989, gravel was applied, and the bottom of the lake was covered with a fine mesh net in 1989 and 1990.

On May 1998, eight weak swans remained at Swamp Miyajima after the spring migration. These swans were sent to the Rakuno Gakuen University Veterinary Teaching Hospital (Ebetsu, Hokkaido, Japan) for diagnosis and treatment. General weakness, inappetence, green watery feces, and pale conjunctiva were observed. Radiographs were taken and whole blood was collected from the medial metatarsal vein into heparinized tubes for complete blood counts and determination of blood lead concentrations. Lead concentrations were determined by atomic absorption spectrophotometry.

Clinical and hematologic findings are shown in Table 1. Four swans were anemic and had poikilocytosis. Blood lead concentrations on day 1 after arrival were elevated and varied from 2.5 µg/g to 6.7 µg/g (mean±SD=4.6±1.14 µg/g). Radiographs showed 6–38 suspected lead pellets in the gizzard. Dilation of the proventriculus was observed in six swans.

TABLE 1. Clinical and hematologic findings in eight lead-poisoned swans.

Swan no.	Species	Sex <sup>a</sup>	Body weight (kg)	Hematocrit (%)	Poikilocytes <sup>b</sup>	Blood lead concentration ( $\mu\text{g/g}$ )	No. lead pellets in proventriculus and gizzard	Dilated proventriculus <sup>b</sup>	Clinical result
1	Whooper	M	6.2	NE <sup>c</sup>	+	6.7	25	+	Died
2	Whooper	M	4.4	40	+	3.8	10	+	Died
3	Whooper	F	7.0	45	+	4.8	14	-	Died
4	Whooper	Unknown	5.8	28	+	2.9	6	-	Survived
5	Tundra	F	3.5	27	+	5.5	8	+	Died
6	Whooper	F	4.4	29	+	5.9	13	+	Died
7	Tundra	M	3.8	30	+	2.5	8	+	Died
8	Whooper	M	5.3	40	+	4.6	38	+	Died

<sup>a</sup> M = male; F = female.

<sup>b</sup> + = present; - = not observed.

<sup>c</sup> NE = not examined.

Lead poisoning in these birds was diagnosed on the basis of anemia and poikilocytosis, the presence of suspected lead pellets in the gizzard as detected by radiography, and elevated blood lead concentrations. Treatments included intravenous injection of calcium disodium ethylenediaminetetraacetate (CaEDTA) into a medial metatarsal vein at 30 mg/kg body weight. Glucose solution (5%) was force fed (50 ml/kg body weight with vitamins). Swans were maintained in warm conditions, but seven of them died on day 2 after arrival.

Postmortem examination was conducted on the swans that died and lead shot was recovered from gizzard. The lead shot varied in size and were in different stages of dissolution. The proventriculus was dilated and contained water plants, mud, and pebbles. Gross findings included pale or green kidneys and green bile-stained livers. Liver and kidney were fixed in 10% buffered formalin and processed routinely for histology. Tissue sections were stained with hematoxylin and eosin and Ziehl-Neelson acid-fast stain. Microscopically there was widespread bile pigmentation in the liver. Acid-fast intranuclear inclusion bodies were observed in renal tubular epithelium (Fig. 1). Greatly elevated lead concentrations were found in the liver and kidney (Table 2).

The only surviving swan (swan 4) was treated with CaEDTA and activated charcoal (spherical carbonaceous absorbent; Kremezin, Kurehakagaha, Tokyo, Japan) orally at 600 mg twice daily by forced feeding. Fifty g of commercial ground chicken feed were mixed with 200 ml of commercial high-calorie liquid nutrient for dogs (CliniCare, Abbott, North Chicago, USA) and the mixture was administered orally twice daily for 10 days. Forced feeding was stopped on day 11 but the bird was treated with CaEDTA and activated charcoal until day 64. The blood lead concentration decreased from day 1 until day 64 (Fig. 2). The swan recovered strength and appetite, and the feces changed from green and watery to normal as the blood lead concentration decreased. The six lead shot seen in this bird by radiography on day 1 gradually reduced in size, and no lead shot was observed in the gizzard by radiography on day 64.

We believed that the swan had recovered from lead poisoning by day 71; it was transferred for rehabilitation at the Maruyama Zoo (Sapporo, Hokkaido, Japan) on day 84. After 3 mo of rehabilitation, the whooper swan was released to the wild.

The blood lead levels found in these swans were markedly elevated (Dumoncaux and Harrison, 1994; Pain, 1996; Bauck and LaBonde, 1997) and liver lead

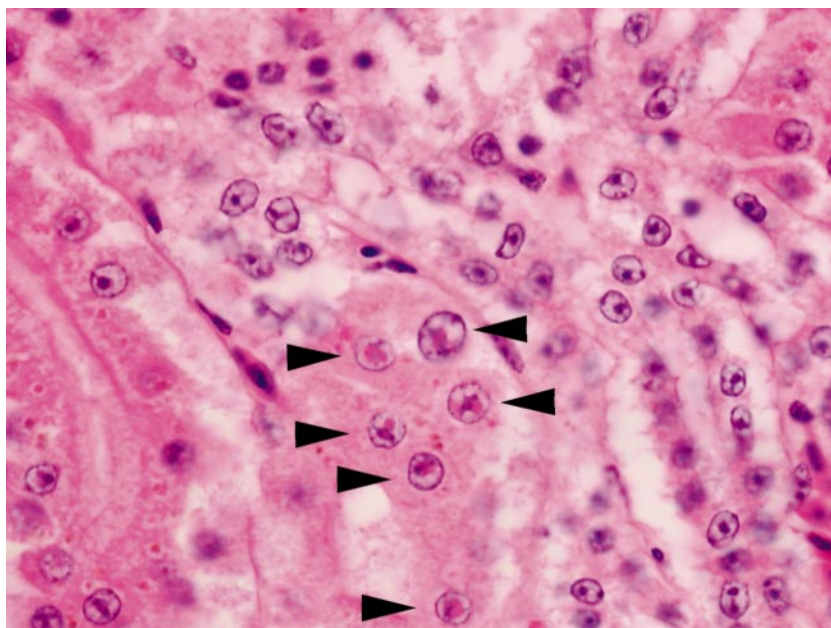


FIGURE 1. Eosinophilic intranuclear inclusion bodies, that were acid-fast, in the epithelium of the renal tubules (arrows). Hematoxylin and eosin stain.

levels from seven swans were within the range considered lethal in waterfowl (Pain, 1996), confirming lead intoxication.

We chose to administer CaEDTA to the lead-poisoned bird rather than conduct surgery to remove the lead pellets. Lead is effectively chelated by EDTA salts (Kowalczyk, 1984; LaBonde, 1991; Dumonceaux and Harrison, 1994; Bauck and LaBonde, 1997; Jenkins, 1997) and puts lead into a soluble form to allow for excretion. Activated charcoal was given orally to reduce the toxicity of long-term EDTA treatment and because it binds small lead particles and inhibits lead absorption. In

the swan that survived, most of the ingested pellets had not been digested by the gizzard and the proventriculus was not dilated. We believe that treatment for lead intoxication in swans is most likely to be successful if blood lead levels are relatively low and no dilation of the proventriculus occurs. Thus, early detection and treatment of swans that have ingested lead pellets improves chances of survival. A few lead-poisoned birds have been found every year at Swamp Miyajima since 1998. The government of Japan has designated this

TABLE 2. Lead concentrations in the tissues of seven lead-poisoned swans.

Swan no.	Liver ( $\mu\text{g/g}$ )	Kidney ( $\mu\text{g/g}$ )
1	30.4	110.0
2	17.2	30.2
3	14.0	33.7
5	16.3	37.5
6	16.8	122.0
7	22.7	34.6
8	16.8	31.2

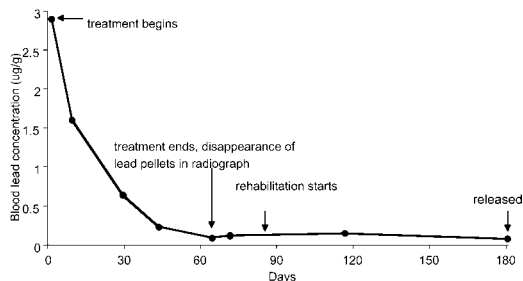


FIGURE 2. Changes in blood lead concentrations in a lead-poisoned whooping swan (swan 4) during treatment. The blood lead concentration decreased to 0.09  $\mu\text{g/g}$  at day 64.

site a wetland under the Ramsar Convention in 2003. To prevent lead poisoning in waterfowl in Japan, we believe that use of lead shot should be prohibited.

This work was supported by a grant-in-aid for High Technological Research Center (Rakuno Gakuen University) from the Ministry of Education, Science, Sports and Culture of Japan.

#### LITERATURE CITED

- BAUCK, L., AND J. LABONDE. 1997. Toxic diseases. *In* Avian medicine and surgery, R. B. Altman, S. L. Clubb, G. M. Dorrestein, and K. Quesenberry (eds.). W. B. Saunders Company Ltd., Philadelphia, Pennsylvania, pp. 604–613.
- DUMONCEAUX, G., AND G. J. HARRISON. 1994. Toxins. *In* Avian medicine: Principles and application, B. W. Ritchie, G. J. Harrison, and L. R. Harrison (eds.). Wingers Publishing Inc., Lake Worth, Florida, pp. 1030–1052.
- HONDA, K., D. P. LEE, AND R. TAKATSUKAWA. 1990. Lead poisoning in swans in Japan. *Environmental Pollution* 65: 209–218.
- JENKINS, R. J. 1997. Avian critical care and emergency medicine. *In* Avian medicine and surgery, R. B. Altman, S. L. Clubb, G. M. Dorrestein, and K. Quesenberry (eds.). W. B. Saunders Company Ltd., Philadelphia, Pennsylvania, pp. 839–864.
- KOWALCZYK, D. 1984. Clinical management of lead poisoning. *Journal of the American Veterinary Medical Association* 184: 858–860.
- LABONDE, J. 1991. Avian toxicology. *In* Pet avian medicine, The Veterinary Clinics of North America: Small Animal Practice, W. J. Rosskopf, Jr., and R. W. Woerpel (eds.). W. B. Saunders Company Ltd., Philadelphia, Pennsylvania, pp. 1329–1342.
- OCHIAI, K., K. JIN, C. ITAKURA, M. GORYO, K. YAMASHITA, N. MIZUNO, T. FUGINAGA, AND T. TSUZUKI. 1992. Pathological study of lead poisoning in whooper swans (*Cygnus cygnus*) in Japan. *Avian Diseases* 36: 313–323.
- , K. HOSHIKO, K. JIN, T. TSUZUKI, AND C. ITAKURA. 1993. A survey of lead poisoning in wild waterfowl in Japan. *Journal of Wildlife Diseases* 29: 349–352.
- , T. KIMURA, K. UEMATSU, T. UMEMURA, AND C. ITAKURA. 1999. Lead poisoning in wild waterfowl in Japan. *Journal of Wildlife Diseases* 35: 766–769.
- PAIN, D. J. 1996. Lead in waterfowl. *In* Environmental contaminants in wildlife: Interpreting tissue concentrations, W. N. Beyer, G. H. Heinz, A. W. Redmon-Norwood (eds.). Lewis Publishers, Boca Raton, Florida, pp. 251–264.

*Received for publication 12 January 2003.*