
DISSEMINATED VISCERAL COCCIDIOSIS IN INDO-GA FLAP-SHELLED TURTLES, LISSEMYS PUNCTATA ANDERSONII

Authors: K. L. Helke, T. K. Cooper, J. L. Mankowski, and S. L. Poynt

Source: Journal of Wildlife Diseases, 42(4) : 788-796

Published By: Wildlife Disease Association

URL: <https://doi.org/10.7589/0090-3558-42.4.788>

BioOne Complete (complete.BioOne.org) is a full-text database of 200 subscribed access titles in the biological, ecological, and environmental sciences published by societies, associations, museums, institutions, and presses.

Your use of this PDF, the BioOne Complete website, and all posted and associated content indicates your acceptance of BioOne's Terms of Use, available at www.bioone.org/terms-of-use.

Usage of BioOne Complete content is strictly limited to personal, educational, and non-commercial use. Commercial inquiries or rights and permissions requests should be directed to the individual publisher as copyright holder.

DISSEMINATED VISCERAL COCCIDIOSIS IN INDO-GANGETIC FLAP-SHELLED TURTLES, *LISSEMYS PUNCTATA ANDERSONII*

K. L. Helke,^{1,2,4} T. K. Cooper,^{1,2} J. L. Mankowski,^{1,2} and S. L. Poynton^{1,3}

¹ Department of Molecular and Comparative Pathobiology, The Johns Hopkins University School of Medicine, Broadway Research Building, Room 863, 733 North Broadway Street, Baltimore, Maryland 21205-2196, USA

² Department of Pathology, The Johns Hopkins University School of Medicine, 720 Rutland, Ross 558, Baltimore, Maryland 21205-2019, USA

³ Leibniz Institute for Freshwater Ecology and Inland Fisheries, Muggelseedamm 310, Berlin D12587, Germany

⁴ Corresponding author (email: khelke1@jhmi.edu)

ABSTRACT: Eimerioriniid coccidia commonly infect vertebrates and might contribute to morbidity and mortality under captive conditions. The common genus *Eimeria* typically shows tissue specificity, usually being limited to the epithelium of the gut; disseminated infections are rare in vertebrates. Disseminated visceral coccidiosis was found in two wild-caught adult female Indo-gangetic flap-shelled turtles (*Lissemys punctata andersonii*) that died while in captivity at a zoo. Sporulated oocysts of *Eimeria* spp. were found in lung and liver of one turtle and in auditory canal, nasal mucosa, pharynx, lung, liver, kidney, spleen, and intestine of the second. Two distinct species of *Eimeria* were indicated for the latter case by polymerase chain reaction amplification and sequencing of a portion of the 18S rRNA gene; one species was present in nasal mucosa and liver, with a separate species in lung, spleen, and intestine. Severity of inflammation was correlated with coccidial density. Coccidia were in melanomacrophages in liver and spleen; in the interstitium of auditory canal, nasal mucosa, pharynx, lung, and intestine; and within the interstitium and epithelial cells of the renal tubules in kidney. We suggest these disseminated infections might have been facilitated by a compromised immune system.

Key words: Coccidia, disseminated, *Eimeria*, *Lissemys punctata*, turtle.

INTRODUCTION

Eimerioriniid coccidia (Apicomplexa, Eucoccidiorida, Eimeriorina) commonly infect a diversity of vertebrate hosts, and although most infections in nature are self-limiting, coccidiosis can cause morbidity and mortality under captive conditions (Barnard and Upton, 1994). The most common coccidian affecting vertebrates is the genus *Eimeria* (Eimeriidae), with at least 120 species described from reptiles (Barnard and Upton, 1994). *Eimeria* is characterized by oocysts containing four sporocysts, each of which contains two sporozoites; the life cycle is direct, with transmission by ingestion of sporulated oocysts. *Eimeria* species usually show tissue specificity, with infection being limited to the epithelium of the gut or to a specific organ (McCully et al., 1970). Within reptiles, *Eimeria* most frequently occurs in the gastrointestinal tract, followed by the gall bladder, bile ducts, and liver (Levine, 1988); only

occasionally have infections been reported from other sites, such as the spleen and kidney (Levine, 1988; Barnard and Upton, 1994).

Although rare, disseminated coccidiosis has been reported in chelonians. Among the parasites having a direct (homoxenous) life cycle, *Caryospora cheloniae* has been cited as the cause of epizootic mortality in both mariculture-reared hatchling and wild subadult green turtles *Chelonia mydas* (Leibovitz et al., 1978; Gordon et al., 1993). Among the parasites with an indirect (heteroxenous) life cycle, *Haemogregarina* spp., *Haemoproteus* spp. (hemogregarine and hemosporine, respectively), *Sarcocystis* spp., and *Toxoplasma* spp. (eimeriorines) all have been reported in disseminated infections of chelonians (Stone and Manwell, 1969; Lainson and Shaw, 1971; Keymer, 1978; Barnard and Upton, 1994).

In this report, we describe disseminated *Eimeria* infection in wild-caught, captive-held, freshwater Indo-gangetic flap-

shelled turtles, *Lissemys punctata andersonii*. The infection was associated with lymphocytic and plasmacytic eustachitis, rhinitis, pharyngitis, pneumonia, and enteritis.

MATERIALS AND METHODS

Postmortem

Two captive, wild-caught (India or Pakistan) adult female Indo-gangetic flap-shelled turtles were presented for necropsy by the Maryland Zoo in Baltimore, USA. Case 1 (1.1 kg) was submitted approximately 24 hr after being found dead in its enclosure; it was previously noted to be healthy. Case 2 (1.35 kg) had a 2-mo history of lethargy, dyspnea, and edema before death; was treated with furosemide, antibiotics, and corticosteroids; and eventually died. Both animals received numerous doses of metronidazole and levamisole for flagellate (presumed) and strongyle (confirmed) burdens. No coccidian oocysts were observed on fecal exam for either case.

Postmortem examinations were performed on both turtles, and samples of the head, heart, lung, liver, spleen, kidney, gastrointestinal (GI) tract, skeletal muscle, and nodules (found throughout the coelom, musculature, and viscera) were fixed in 10% neutral buffered formalin and processed for paraffin embedding. The fixed head was placed in formic acid-sodium citrate until decalcification was complete; it was then treated similarly to the other tissues. Sections approximately 5 μ m thick were cut, placed on negatively charged glass slides, and stained with hematoxylin and eosin (H&E). Sterile cultures of the nodules were taken in both cases.

Coccidian identification

Morphometrics: To visualize morphology of the coccidian oocysts within the various tissues, additional sections were stained with Giemsa, Gomori-methenamine silver (GMS), Periodic acid-Schiff (PAS), and Ziehl-Neelsen acid-fast stains (Gardiner et al., 1988). For identification to genus, we considered the appearance of the sporulated oocysts—namely, the number of sporocysts contained therein and the number of sporozoites per sporocyst. Identification to genus was made according to the most recent edition of *The Illustrated Guide to the Protozoa* (Perkins et al., 2000).

Measurements of sporulated oocysts were made with an ocular micrometer in a Nikon E400 light microscope (Nikon Instruments, Melville, New York). Three measurements of

10 sporulated oocysts (diameter of oocyst, length and width of sporocyst) were taken in each of five tissues (nasal mucosa, lung, liver, spleen, and intestine). In the auditory canal, pharynx, and kidney, few parasites were seen, precluding morphometric analysis. Measurements of each of the three parameters were compared among sporulated oocysts in the five tissues: initially by analysis of variance and subsequently by one-tailed *t*-tests if a significant difference was found. Differences were considered significant if $P < 0.05$.

The absence of fresh material precluded assembly of comprehensive morphometric data for the coccidians, which should include measurements on the basis of observations of fresh oocysts (Bandoni and Duszynski, 1988). Furthermore, our efforts to further identify the parasites on the basis of transmission electron microscopy were not successful because of poor quality of tissue preservation; both animals were submitted for necropsy some hours after death and tissues had been fixed in formalin.

Molecular taxonomy: For DNA extraction from archived blocks from case 2, a 10- μ m section was removed from the face of the block and placed on a glass slide, and tissue from the area of interest was sterilely removed and collected in a sterile Eppendorf tube. The DNA was extracted with a DNeasy kit (QIAGEN Inc., Valencia, California, USA) from seven individual tissues: the auditory canal, nasal mucosa, pharynx, lung, liver, spleen, and intestine. No kidney tissue remained to be tested.

Primers encompassing a 686-base pair (bp) region of the *Eimeria* 18S gene were designed from consensus sequences of six representative *Eimeria* species (GenBank accession number)—*E. arizonensis* (AF307878), *E. arnyi* (AY613853), *E. chaetodipi* (AF339489), *E. gruis* (AB205168), *E. peromysci* (AF339492), and *E. rioarribaensis* (AF307877)—as well as consideration of 18S sequences from *Caryospora bigenetica* (AF060976), *Choleoecimeria* sp. (AY043207), *Lankesterella minima* (AF080611), *Sarcocystis hirsuta* (AF017122), and *Toxoplasma gondii* (L37415). Primer sequences were 18S forward: 5' GGAGGG-CTGTGTTTATTAGATAC 3' and 18S reverse: 5' CAACTGTCCCTATTAATCAT-TACCT 3' (Integrated DNA Technologies, Coralville, Iowa, USA). Polymerase chain reaction was performed with Takara Ex Taq DNA polymerase (Takara Mirus Bio Inc., Madison, Wisconsin, USA) on a Bio-Rad iCycler thermal cycler (Bio-Rad Laboratories, Hercules, California, USA). The negative

control reaction had no added DNA template. Products of polymerase chain reactions were run out on a 1.5% agarose gel in tris–acetate–ethylenediamine–tetraacetic acid buffer with the 1 kb Plus DNA Ladder (Invitrogen, Carlsbad, California, USA) and visualized with ethidium bromide on an Eagle Eye II gel imager (Stratagene, La Jolla, California, USA). Appropriately sized bands (686 bp) from individual tissues were excised from the gel, and the DNA was extracted with a QIAquick gel extraction kit (QIAGEN) and then ethanol precipitated.

Sequencing was performed by the Sanger fluorescent dideoxy chain termination method on a 3730 DNA Analyzer (Applied Biosystems, Foster City, California, USA). Raw sequence data were aligned and trimmed with Sequencher version 3.1.2 (Gene Codes Corp., Ann Arbor, Michigan, USA), and the 588-bp (nasal mucosa and liver) and the 591-bp (lung, spleen, and intestine) consensus sequences were compared with all existing GenBank sequences by the nucleotide BLAST algorithm (www.ncbi.nlm.nih.gov/BLAST/).

RESULTS

Pathologic findings

One turtle had numerous pale yellow, firm, 1–4-mm-diameter nodules that were solid and dry throughout the viscera. Nodules were found throughout the lungs, musculature, within the endocardium and myocardium of the heart, within the kidney, and free within the coelom. The second turtle also had pale yellow, soft to firm, 5–40-mm-diameter caseous nodules accompanied by severe edema within all coelomic soft tissues. Microscopically, the nodules were bacteria-laden granulomas in both cases, containing numerous extracellular gram-positive rods and cocci and gram-negative rods. Bacterial culture revealed *Providencia alcalifaciens* and *Proteus mirabilis*.

One turtle had coccidian oocysts in lung and liver that were variably associated with inflammation, the severity of which correlated with coccidia density. Other findings included skeletal myositis and pancarditis; myxosporidia were present within renal tubules. All gastrointestinal tissues were severely autolyzed. The second turtle had

coccidian oocysts in the interstitium of the auditory canal, nasal mucosa, pharynx, lung, liver, spleen, kidney, and intestine, as well as in renal tubular epithelial cells. Associated inflammation varied, increasing with oocyst density (Fig. 1). Myxosporidia were within the renal tubules, but although nephritis was present, it was not associated with these parasites.

Within liver and spleen, coccidian oocysts were within melanomacrophages (Fig. 2a) that were surrounded by uninfected melanomacrophages. In the auditory canal, nasal mucosa, pharynx, and lung, oocysts appeared to be primarily intracellular (unknown cell type) within the interstitium. In areas with few parasites, there was no inflammation; however, as the density of oocysts increased, lymphocytes and plasma cells infiltrated the interstitium. In kidney, the oocysts were both within the interstitium, in which they appeared to be intracellular (unknown cell type), and within the renal tubular epithelium. Coccidian oocysts were present throughout the lamina propria of intestine and extended into the submucosa, accompanied by a moderate diffuse lymphoplasmacytic infiltrate.

The myxosporidian in renal tubules was identified morphologically according to Lom and Arthur (1988) and Lom and Dyková (1992) as *Myxidium mackiei* Bosanquet 1910. It was characterized by longitudinally striated fusiform spores with pointed ends, each spore having two pyriform polar capsules, one at each end of the spore (Helke and Poynton, 2005). Paired spores were present in large polysporic plasmodia, which occluded approximately 10% of the tubules (Helke and Poynton, 2005).

Coccidian morphometrics

In all tissues, the thin-walled oocysts were spherical to compressed spherical and contained four ovoid sporocysts, each of which contained two sporozoites (tetrasporocystic, dizoic); the club-shaped spor-

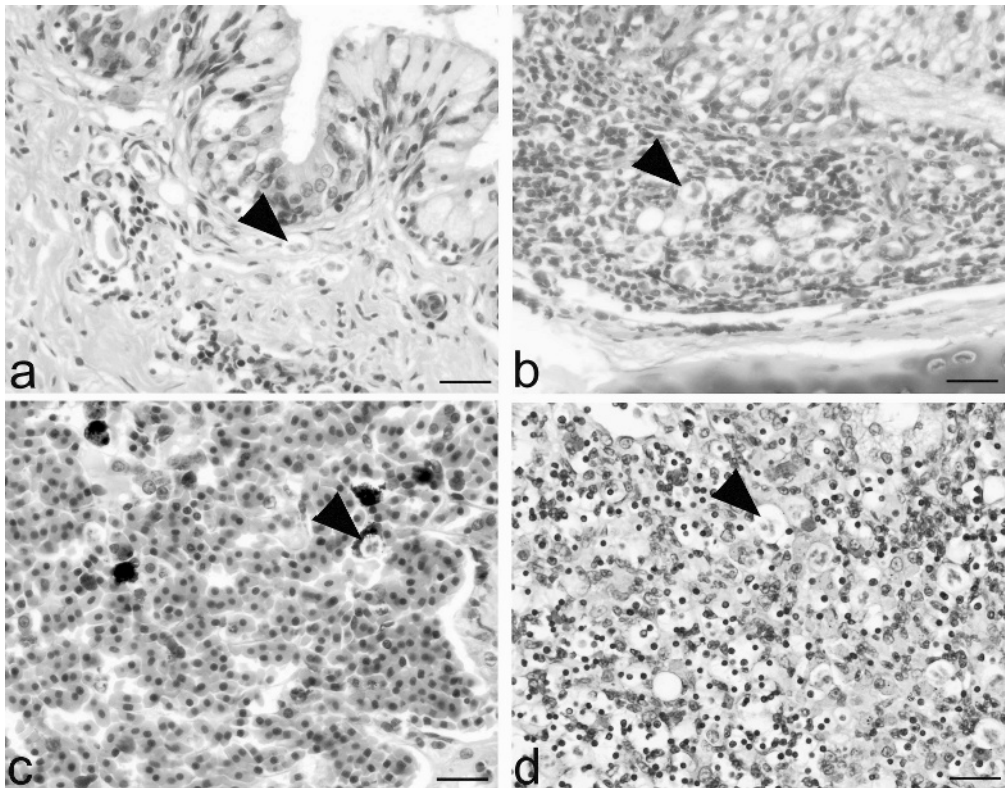


FIGURE 1. Disseminated sporulated oocysts of *Eimeria* in the Indo-gangetic flap-shelled turtle *Lissemys punctata andersonii*. Hematoxylin and eosin stained sections. Arrowheads point to sporulated oocysts. Note that the severity of inflammation was related to the density of parasite infection; compare mild inflammation in low-density infection (a, c) with severe inflammation in high-density infection (b, d). H&E stained histologic sections. (a) Auditory canal. The oocyst is within the submucosa of the auditory canal. There is mild lymphoplasmacytic inflammation surrounding organisms. Bar=0.2 μ m. (b) Nasal mucosa. Within the nasal mucosa, oocysts are present within the submucosa and are surrounded by severe lymphoplasmacytic inflammation. Bar=0.2 μ m. (c) Pharynx. Within the pharynx, there are sparse oocysts with minimal associated inflammation. Bar=0.2 μ m. (d) Lung, high-density infection. In the interstitium of the lung, with a high density of oocysts, there is severe lymphoplasmacytic inflammation. Bar=0.2 μ m.

ozoites were arranged head to tail as evident by the opposed orientations of the two sporozoite nuclei (Fig. 2b). This morphology was consistent with *Eimeria* (Perkins et al., 2000). Sporocysts were slightly PAS positive. Sporozoites were strongly Ziehl-Neelsen acid-fast positive and strongly gram positive; they contained one basophilic curvilinear nucleus in the center of each sporozoite.

Oocysts and sporocysts from the nasal mucosa differed morphometrically from those in lung, liver, spleen, and intestine (the four other tissues from which morphometrics were available; Table 1). Oo-

cysts from the nasal mucosa were significantly smaller than those in all other tissues (except the liver). Furthermore, the sporocysts from the nasal mucosa were significantly longer and wider than those in all other tissues (except that their width was not significantly different from that of sporocysts from the intestine). Oocysts from the four sites other than the nasal mucosa were not distinguishable from each other; however, sporocysts from the intestine were significantly larger than those in all other tissues (except width was not significantly different in intestine and nasal mucosa). We did not see any

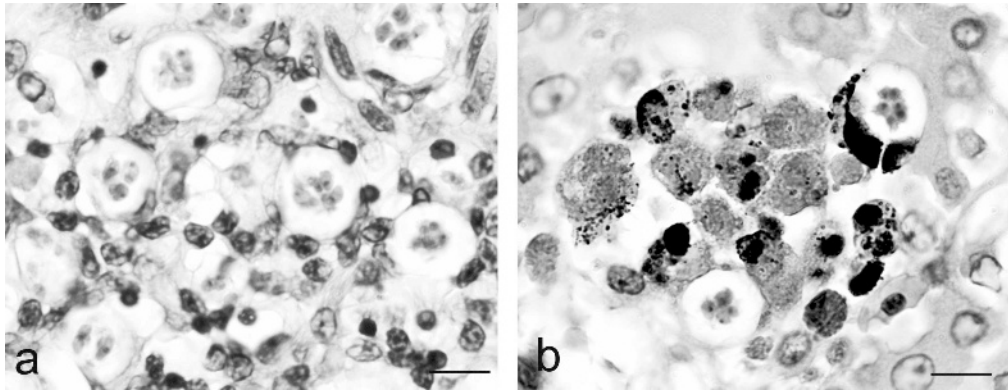


FIGURE 2. Disseminated *Eimeria* infection in the Indo-gangetic flap-shelled turtle *Lissemys punctata andersonii*. H&E stained histologic sections. Sporulated oocysts contain four sporocysts, each with two sporozoites. (a) Sporulated oocyst within macrophages in the liver. The cell nucleus is displaced to the periphery of the cell by sporulated oocysts. (b) In melanomacrophage centers within the liver, sporulated oocysts are present within the cytoplasm of the melanomacrophages. Both bars=0.1 μ m.

structures that we recognized as unsporulated oocysts or asexual stages in any of the tissues.

Molecular taxonomy

GenBank included 33 species of *Eimeria* with which to make comparisons. Sequences also were present for *Caryospora*, *Choleoeimeria*, *Goussia*, *Lankere-stella*, *Sarcocystis*, and *Toxoplasma*. No sequences were available for *Haemogregarina*. Alignment of sequence data from

samples of nasal cavity and liver and of lung, spleen, and intestine confirmed the identification of the organisms as *Eimeria*. Sequences amplified from the pharynx aligned with several types of algae and were interpreted as environmental contaminants. No sequences were obtained from the auditory canal.

Alignment of raw sequence data demonstrated the presence of two similar but genetically distinct *Eimeria* that consistently differed at 18 of almost 600 base

TABLE 1. Morphometrics of sporulated oocysts of *Eimeria* from histologic sections of five different tissues from an Indo-gangetic flap-shelled turtle.^a Measurements are range with mean and standard deviation.

Tissue	Oocyst diameter (μ m) ^b	Sporocyst length (μ m) ^c	Sporocyst width (μ m) ^c
Nasal mucosa	10.6–12.4	4.7–8.2	2.3–4.7
	11.6 \pm 0.5	6.2 \pm 1.1	2.8 \pm 0.7
Lung	12.2–14.7	3.4–4.9	1.4–2.9
	13.5 \pm 1.0	4.1 \pm 0.8	2.1 \pm 0.4
Liver	10.6–13.5	2.9–4.9	1.7–2.9
	12.0 \pm 1.2	4.1 \pm 0.8	2.2 \pm 0.4
Spleen	11.8–14.2	3.5–4.9	1.3–3.3
	13.2 \pm 1.1	4.3 \pm 0.5	2.2 \pm 0.5
Intestine	10.6–17.0	3.9–6.1	2.3–3.5
	13.0 \pm 2.0	5.2 \pm 0.6	2.8 \pm 0.4

^a Morphometrics are not included for the auditory canal, pharynx, and kidney because few parasites were seen in these tissues and no further material was available for study. Histologic sections have been deposited in the US National Parasite Collection, USDA, ARS, BARC East, Building 1180, Beltsville, Maryland, 20705-2350, USA (email: ehohberg@anri.barc.usda.gov). Their accession numbers are USNPC 095009.00, 095010.00, 095011.00, and 095012.00.

^b Measurements of 10 oocysts per tissue, except nasal cavity ($n=9$).

^c Measurements of 10 sporocysts per tissue.

pairs. The parasites in the nasal mucosa and liver (588 bp) were distinct from those in the lung, spleen, and intestine (591 bp). Comparison of these 18 loci with 18S sequences from a turtle (M59398.1), an alligator (M59383.1), and a sphenodon (AF115860) reduced the possibility of a chimera.

Both organisms aligned most closely to *Eimeria arnyi* (AY613853) found in the feces of the prairie ringneck snake (*Diadophis punctatus arnyi*) (Upton and Oppert, 1991). Alignment was less stringent with other species of *Eimeria*, which characteristically mature in the digestive tract. Sequences were deposited in GenBank under the accession numbers DQ072716 and DQ167480.

DISCUSSION

To our knowledge, this is the first report of sporulated oocysts of *Eimeria* in the auditory canal, nasal mucosa, pharynx, and lung, of a reptile. *Eimeria* species usually undergo asexual and sexual development within the gastrointestinal tract; however, there are species in which sporulation occurs in extraintestinal locations; for example, *Eimeria innominata* in the liver of Indo-gangetic flap-shelled turtles (Kar, 1944), and *Eimeria legeri* in hepatocytes of the bungoma (a freshwater turtle, *Cryptopus granosus*; Simond, 1901).

It has been suggested by Long (1970) that efficacy of host immune responses can determine the choice of site for development, with immune suppression increasing the chances that infections generally limited to the GI tract might be disseminated and undergo development in other sites. We suggest that the disseminated infections we observed could have been facilitated by a compromised immune system. Both animals had myriad bacteria-laden granulomas, which could have overwhelmed the immune system. In addition, case 2 had been treated with corticosteroids, which can be immunosuppressive.

The site of infection for eimerioriniid coccidia varies considerably among host taxa. In mammals, birds, and reptiles, infections are mainly intestinal; in fish, about one third of infections are non-intestinal; and in invertebrates, infections are often nonintestinal (Perkins et al., 2000). Among birds, both whooping cranes (*Grus americana*) and sandhill cranes (*Grus canadensis*) have been shown to have disseminated visceral coccidiosis (*Eimeria* sp.) involving the nares, trachea, lung, air sacs, heart, liver, spleen, and intestines, with a variable amount of associated granulomatous inflammation (Carpenter et al., 1980; Levine, 1982, 1988; Parker and Duszynski, 1986; Novilla et al., 1989). In the disseminated coccidiosis of cranes, the oocysts in the tissues were not sporulated (exogenous sporulation), which contrasts with the infection in the turtles, in which the *Eimeria* oocysts in all eight tissues were sporulated (endogenous sporulation). Overstreet (1981) has suggested that *Eimeria* species in poikilothermic hosts (such as turtles) and homeothermic hosts (such as cranes) might have distinct traits; in the former, endogenous development is affected by temperature and age, sporogony occurs in the host, and an intermediate host might be required.

The route of dissemination of the *Eimeria* from the initial site of infection, presumably the intestine, to the other locations in these two turtles is not known. However, for other disseminated coccidial infections, the route is suggested to be via the reticuloendothelial system, white blood cells, or both (Levine, 1988; Ball et al., 1989). A possible scenario for the parasites in these turtles is that the sporocysts are ingested and escape the GI system via the reticuloendothelial system and traffic to the lungs to mature and reproduce (Ball et al., 1989). From the lungs, parasites can be coughed to the oropharynx, travel to the nasal mucosa, and move into the Eustachian tube and auditory canal. Although sexually mature

parasites were found in seven extraintestinal sites in the turtles, some of the locations, such as the auditory canal and spleen, are locations from which the oocysts could not readily be shed and disseminated from the host to perpetuate the life cycle.

Several authors have discussed the role of macrophages in the transport of *Eimeria*. Shelton et al. (1968) suggested that macrophages engulf sporozoites as they enter the epithelium and carry them through the lamina propria to other sites, where they invade the epithelial cells, and that an abnormal host-parasite relationship allows development within macrophages (Shelton et al., 1968). Because turtles have melanomacrophage centers similar to those in fish that act as antigen presentation sites (Agius and Roberts, 2003), it cannot be ruled out that the oocysts are engulfed and taken to these melanomacrophage centers in the liver and spleen for antigen presentation and recognition.

Commonly reported pathology associated with *Eimeria* infection includes destruction of infected cells and surrounding tissue, resulting in necrosis and hemorrhage, and cellular infiltration and architectural change (Gardiner et al., 1988). In our cases, the parasites appeared to be predominantly intracellular within the interstitium. When parasites were within melanomacrophages and rare renal tubular epithelial cells, they incited no discernible inflammation. Whereas in remaining areas, the resultant inflammation was lymphoplasmacytic, and severity was dependent on coccidia density. There was little to no destruction of surrounding tissue associated with the parasite, except within the intestine and lung, where severe enteritis was associated with a heavy parasite burden. Although overt enterocyte damage and loss was not observed, the enteritis associated with the coccidian organisms likely compromised gastrointestinal function.

The *Eimeria* infection might have per-

sisted in the turtles since they were imported from India or Pakistan in 2001. Because species of *Eimeria* are known to have a very narrow host range (Bowman, 1995), it is unlikely they acquired the parasites from other animals at the zoo.

Although Perkins et al. (2000) consider only one genus, *Eimeria*, to be characterized by thin-walled oocysts with four dizoic sporocysts, other authors also recognize *Choleoeimeria* and *Goussia* as additional valid genera with these morphologic characteristics. Although the latter two genera are similar to *Eimeria*, *Choleoeimeria* has elongated oocysts and bivalved sporocysts lacking Stieda bodies, and sporulation is endogenous (Paperna and Landsberg, 1989; Lainson, 2003). *Goussia* has bivalved sporocysts united by a suture, and lacking Stieda bodies (Lom and Dyková, 1992; Azevedo, 2001), and sporogony can be endogenous or exogenous (Lom and Dyková, 1992; Molnar, 1996).

Three species of *Eimeria* have previously been reported from the Indoganggetic flap-shelled turtle (Duszynski et al., 2000). *Eimeria irregularis* and *Eimeria koormae* have been reported from the intestine (Das Gupta, 1938; Kar, 1944), and *E. innominata* has been reported from the liver (Kar, 1944). The parasites we observed appeared distinct from *E. innominata* and *E. irregularis*; the sporozoite nucleus was curvilinear, and in *E. innominata* and *E. irregularis*, it is spherical (Kar, 1944). Sequences for *E. irregularis*, *E. koormae*, and *E. innominata* were not available for molecular comparison.

Four other species of *Eimeria* are known from turtles and tortoises from India and Ceylon: *E. legeri* (Simond, 1901), *Eimeria mitraria* (Laveran and Mesnil, 1902), *Eimeria triangularis* (Chakravarty and Kar, 1943), and *Eimeria trionyxae* (Chakravarty and Kar, 1943). The parasites detected in this study were distinct from both *E. mitraria* and *E. triangularis*; oocysts were spherical rather than asymmetrically ellipsoid (*E. mitraria*) or triangular (*E. triangul-*

laris; Laveran and Mesnil, 1902; Chakravarty and Kar, 1943). Sequences for these four species were not available.

Dimensions of parasites in the nasal mucosa were different from those observed in four other tissues (lung, liver, spleen, and intestine), suggesting a mixed infection. Molecular data indicated that a dual infection was present, with one organism present in the nasal mucosa and liver and a different organism present in the lung, spleen, and intestine. The finding of concurrent infection by multiple species of coccidia within a single host species is not unusual (Bowman, 1995); with chelonians, as many as seven *Eimeria* species have been recorded for a single host species (McAllister et al., 1995).

The cause of death in both cases was believed to be related to the presence of bacteria-laden granulomas, with coccidian infection as a secondary factor. Disseminated coccidiosis is likely underreported in turtles because most studies on coccidial infections in turtles are limited to morphologic descriptions of parasites found in the feces, and thus reflect intestinal infections.

ACKNOWLEDGMENTS

We thank the veterinary staff at the Maryland Zoo in Baltimore for submitting these cases for postmortem investigation, and we thank Pat Wilcox (Department of Molecular and Comparative Pathobiology, Johns Hopkins University School of Medicine) for preparing the histologic sections. We are grateful to Mohammad Reza Saghari Fard (Leibniz Institute of Freshwater Ecology and Inland Fisheries, Berlin, Germany) and Jan Landsberg (Florida Fish and Wildlife Conservation Commission) for assistance with literature. Funding for this study was provided to K.L.H. and T.K.C. by National Research Service Award RR07004.

LITERATURE CITED

- AGIUS, C., AND R. J. ROBERTS. 2003. Melanomacrophage centers and their role in fish pathology. *Journal of Fish Diseases* 26: 499–509.
- AZEVEDO, C. 2001. Fine structure of sporogonic stages of *Goussia clupearum* (Apicomplexa: Eimeriidae) in the liver of infected fish (*Belone belone* L.), using light and electron microscopy. *Parasitology Research* 87: 326–330.
- BALL, S. J., R. M. PITTILO, AND P. L. LONG. 1989. Intestinal and extraintestinal life cycles of eimeriid coccidia. *Advances in Parasitology* 28: 1–54.
- BANDONI, S. M., AND D. W. DUSZYNSKI. 1988. A plea for improved presentation of type material for coccidia. *Journal of Parasitology* 74: 519–523.
- BARNARD, S. M., AND S. J. UPTON. 1994. A veterinary guide to the parasites of reptiles, Vol. I. Protozoa Kreiger, Malabar, Florida, 154 pp.
- BOWMAN, D. D. 1995. *Georgi's parasitology for veterinarians*, 6th Edition. W.B. Saunders, Philadelphia, Pennsylvania, 430 pp.
- CARPENTER, J. W., T. R. SPRAKER, AND M. N. NOVILLA. 1980. Disseminated visceral coccidiosis in whooping cranes. *Journal of the American Veterinary Medical Association* 177: 845–848.
- CHAKRAVARTY, M., AND A. B. KAR. 1943. Observations on two coccidia, *Eimeria trionyxae* n. sp., and *Eimeria triangularis* n. sp. from the intestine of the turtle *Trionyx gangeticus*. Cuv. *Journal of the Royal Asiatic Society of Bengal, Science* 9: 49–54.
- DAS GUPTA, M. 1938. On a new coccidium *Eimeria koormae* n. sp. from the intestine of Indian tortoise, *Lissemys punctata* Smith. *Archiv für Protistenkunde* 90: 410–413.
- DUSZYNSKI, D. W., S. J. UPTON, AND L. COUCH. 2000. Coccidia (*Eimeria* and *Isospora*) of chlonia. <http://biology.unm.edu/biology/coccidia/chlonia.html>. Accessed April 2006.
- GARDINER, C. H., R. FAYER, AND J. P. DUBEY. 1988. An atlas of protozoan parasites in animal tissues. US Department of Agriculture Agriculture Handbook 651, 83 pp.
- GORDON, A. N., W. R. KELLY, AND R. J. LESTER. 1993. Epizootic mortality of free-living green turtles, *Chelonia mydas*, due to coccidiosis. *Journal of Wildlife Diseases* 29: 490–494.
- HELKE, K. L., AND S. L. POYNTON. 2005. *Myxidium mackiei* (Myxosporea) in Indo-gangetic flapshelled turtles *Lissemys punctata andersonii*: Parasite-host interaction and ultrastructure. *Diseases of Aquatic Organisms* 63: 215–230.
- KAR, A. B. 1944. Two new coccidia from pond turtles, *Lissemys punctata* (Bonnaterre). *Indian Veterinary Journal* 20: 231–234.
- KEYMER, I. F. 1978. Diseases of chelonians: (2) Necropsy survey of terrapins and turtles. *The Veterinary Record* 103: 577–582.
- LAINSON, R. 2003. Some coccidial parasites of the lizard *Amphisbaena alba* (Reptilia: Amphisbaenia: Amphisbaenidae). *Memorias do Instituto Oswaldo Cruz* 98: 927–936.
- , AND J. J. SHAW. 1971. *Sarcocystis gracilis* n.sp. from the Brazilian tortoise *Kinosternon scorpioides*. *Journal of Protozoology* 18: 365–372.

- LAVERAN, A., AND F. MESNIL. 1902. Sur quelque protozoaires parasites d'une tortue d'Asie (*Damonia reevesii*). Comptes Rendus des Séances de l'Académie des Sciences, Serie 3 134: 609–614.
- LEIBOVITZ, L., G. REBELL, AND G. C. BOUCHER. 1978. *Caryospora cheloniae* sp. n.: A coccidial pathogen of mariculture-reared green sea turtles (*Chelonia mydas mydas*). Journal of Wildlife Diseases 14: 269–275.
- LEVINE, N. D. 1982. The genus *Atoxoplasma* (Protozoa: Apicomplexa). Journal of Parasitology 68: 719–724.
- . 1988. The protozoan phylum Apicomplexa, Vol. I. CRC Press, Boca Raton, Florida, pp. 203.
- LOM, J., AND J. R. ARTHUR. 1989. A guideline for the preparation of species descriptions in Myxosporidia. Journal of Fish Diseases 12: 151–156.
- , AND I. DYKOVÁ. 1992. Protozoan parasites of fishes. Elsevier, Amsterdam, The Netherlands, 315 pp.
- LONG, P. L. 1970. Development (schizogony) of *Eimeria tenella* in the liver of chickens treated with corticosteroid. Nature 225: 290–291.
- MCCALLISTER, C. T., J. N. STUART, AND S. J. UPTON. 1995. Coccidia (Apicomplexa: Eimeriidae) from the big bend slider, *Trachemys gaigeae* (Testudines: Emydidae), in New Mexico. Journal of Parasitology 81: 804–805.
- MCCULLY, R. M., P. A. BASSON, V. DE VOS, AND A. J. DE VOS. 1970. Uterine coccidiosis of the impala caused by *Eimeria neitzi* spec. nov. The Onderstepoort Journal of Veterinary Research 37: 45–58.
- MOLNAR, K. 1996. Remarks on the morphology, site of infection and validity of some coccidian species from fish. Acta Veterinaria Hungarica 44: 295–307.
- NOVILLA, M. N., J. W. CARPENTER, T. K. JEFFERS, AND S. L. WHITE. 1989. Pulmonary lesions in disseminated visceral coccidiosis of sandhill and whooping cranes. Journal of Wildlife Diseases 25: 527–533.
- OVERSTREET, R. M. 1981. Species of *Eimeria* in non-epithelial sites. Journal of Protozoology 28: 258–260.
- PAPERNA, I., AND J. H. LANDSBERG. 1989. Description and taxonomic discussion of eimerian coccidia from African and Levantine geckoes. South African Journal of Zoology 24: 345–355.
- PARKER, B. B., AND D. W. DUSZYNSKI. 1986. Coccidiosis of sandhill cranes (*Grus canadensis*) wintering in New Mexico. Journal of Wildlife Diseases 22: 25–35.
- PERKINS, F. O., J. R. BARTA, R. E. CLOPTON, M. A. PEIRCE, AND S. J. UPTON. 2000. Phylum Apicomplexa Levine, 1970. In An illustrated guide to the protozoa, Vol. 1, J. J. Lee, G. F. Leedale and P. Bradbury (eds.). Society of Protozoologists, Lawrence, Kansas, pp. 190–369.
- SHELTON, G. C., L. D. KINTNER, AND D. O. MACKINTOSH. 1968. A coccidia-like organism associated with subcutaneous granulomata in a dog. Journal of the American Veterinary Medical Association 152: 263–267.
- SIMOND, P. L. 1901. Note sur une coccidie nouvelle, *Coccidium legeri*, parasite de *Cryptopus granosus* (*Emyda granosa*). Comptes Rendus des Séances de la Societe de Biologie et des ses Filiales 53: 485–486.
- STONE, W. B., AND R. D. MANWELL. 1969. Toxoplasmosis in cold-blooded hosts. Journal of Protozoology 16: 99–102.
- UPTON, S. J., AND C. J. OPPERT. 1991. Description of the oocysts of *Eimeria arnyi* n. sp. (Apicomplexa: Eimeriidae) from the eastern ringneck snake *Diadophis punctatus arnyi* (Serpentes: Colubridae). Systematic Parasitology 20: 195–197.

Received for publication 21 September 2004.