
Larvae of *Elaphostrongylus cervi* in a Population of Free-living Red Deer in Italy

Authors: Federico Morandi, Roberta Galuppi, Sandro Nicoloso, Cinzia Benazzi, Maria Paola Tampieri, et. al.

Source: Journal of Wildlife Diseases, 42(4) : 870-872

Published By: Wildlife Disease Association

URL: <https://doi.org/10.7589/0090-3558-42.4.870>

BioOne Complete (complete.BioOne.org) is a full-text database of 200 subscribed access titles in the biological, ecological, and environmental sciences published by societies, associations, museums, institutions, and presses.

Your use of this PDF, the BioOne Complete website, and all posted and associated content indicates your acceptance of BioOne's Terms of Use, available at www.bioone.org/terms-of-use.

Usage of BioOne Complete content is strictly limited to personal, educational, and non-commercial use. Commercial inquiries or rights and permissions requests should be directed to the individual publisher as copyright holder.

Larvae of *Elaphostrongylus cervi* in a Population of Free-living Red Deer in Italy

Federico Morandi,^{1,3} Roberta Galuppi,¹ Sandro Nicoloso,² Cinzia Benazzi,¹ Maria Paola Tampieri,¹ and Paolo Simoni¹ ¹Dipartimento di Sanità Pubblica Veterinaria e Patologia Animale, Università degli Studi di Bologna, Via Tolara di Sopra 50-40064 Ozzano Emilia, Bologna, Italy; ²D.R.E.Am. Italia, via dei Guazzi, 31, 52013 Poppi, Arezzo, Italy; ³Corresponding author (email: fmorandi@vet.unibo.it)

ABSTRACT: Hunter-killed red deer ($n=68$; *Cervus elaphus*) harvested from the Italian provinces of Bologna (Emilia Romagna) and Pistoia (Tuscany) (44°00'N 11°00'E) from October 2001 to January 2002 were examined for protostrongylid larvae. Twenty-eight animals (41%) had protostrongylid larvae in feces, lungs, and inguinal and iliac lymph nodes. Of these 28 animals, 20 were adults (71%), four were yearlings (14%), and four were calves (14%). Shape, length, width, and the location to the nematodes were consistent with *Elaphostrongylus cervi*, which has not been previously reported in Italy.

Key words: *Cervus elaphus*, *Elaphostrongylus cervi*, Italy, red deer, Tuscan-Emilian Apennines.

Elaphostrongylus cervi can cause nervous and muscular disorders in red deer (*Cervus elaphus*), and *E. cervi* has been recorded in domestic and wild cervids in Europe and Asia (English et al., 1985; Anderson, 2000; Lankester, 2001), Australia, Canada (Presidente, 1986; Gajadhar et al., 1994), and New Zealand (Mason and McAllum, 1976). Adult worms were found beneath the epimysium and in the intermuscular connective tissue of the shoulders, chest, back and upper limbs; mature parasites and third and fourth stage larvae were present in the subdural and subarachnoid spaces of the central nervous system (Lankester, 2001). This is the first report of *E. cervi* infection in free-living red deer in Italy.

The study was carried out on 68 free-living hunter-killed red deer from Tuscan-Emilian Apennines located in the provinces of Bologna (Emilia-Romagna) and Pistoia (Tuscany) (44°00'N, 11°00'E) at 80 to 1,300 m above sea level. Examined deer were harvested during the 2001 October to 2002 January hunting season

and included 34 males and 34 females; they were examined under the direction of the Interregional Technical Committee of the regions Tuscany and Emilia Romagna. Deer were divided into three age classes: calf (7 mo to <1 year old), yearling (1 to <2 years old), and adult (> 2 years old).

Red deer were extirpated from this area by the end of the 18th century and have recently been re-established in this area. In 1958 and 1965, two groups of four and three animals, respectively, were released. These originated from the State Forest of Tarvisio (46°30'N, 13°35'E) that was colonized by migrant deer from adjacent Austria (Premuda, 1975; Mazzarone and Mattioli, 1996). Since the 1980s, additional animals have escaped from enclosures on the area; these deer originated from Scotland (Nicoloso, pers. comm.). The current deer population in the area is estimated to be 2,500 (Mattioli and Nicoloso, 2003).

Samples of lung and lymph nodes were collected from all animals and were paraffin-embedded, sectioned at 5 μ m, and stained with hematoxylin and eosin (H&E). Tracheal lavages, fecal pellets (from the rectum), and tissues from muscle and the central nervous system were collected from 10 animals. Fecal pellets were examined by Baermann technique (Ministry of Agriculture, Food, and Fisheries, 1986). Lavage fluids were placed in plastic bottles and sediment was examined by light microscopy. Tissue samples were examined for the presence of adult *E. cervi*.

Grossly, the lungs of all animals had petechiae and lobular ecchymoses. In one adult female, the lung surface had two grayish palpable nodules (0.5 and 2 cm in

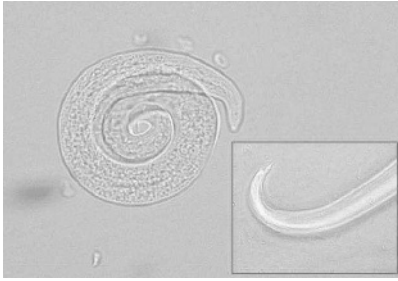


FIGURE 1. Larvae of *E. cervi*. The inset shows the typical dorsal spinula on the tail. 40 \times .

diameter). Adult nematodes were not found in airways. Histologically, alveoli or entire lobules were filled with erythrocytes and eggs and first stage nematode larvae in 28 animals (20 adults, four yearlings, and four calves). The eggs and larvae were located in the interstitial tissue of the alveolar septa surrounded by a mild granulomatous reaction of large mononuclear cells with a few eosinophils and circumscribed by a thin fibroblastic layer. The two grayish nodules observed macroscopically in the lungs of the adult female contained some eggs and degenerated larvae immersed in caseous necrosis and surrounded by granulomatous reaction with a large number of eosinophils. Larvae were also present in inguinal lymph nodes in two of the animals, whereas in most subjects lymph nodes were diffusely infiltrated with eosinophils in the absence of any parasitic structures. The localized hemorrhages in the lungs were acute, most likely agonal following gunshot.

Nematode larvae (L1) were detected in eight of 10 tracheal lavage samples and in seven of 10 fecal samples. Larvae were 390–430 μm long, and 18–20 μm wide, with an evident dorsal process at the tail end (Fig. 1). Adult and larval nematodes were not detected in the arachnoid of the spinal cord, or in the muscles. These results are consistent with results from other European studies (Kutzer and Prosl, 1975; English et al., 1985; Eriksen et al., 1989). In our study, eggs and larval infections were found in 41% of animals;

prevalence was highest in adults (71%) as compared to yearlings (14%) and calves (14%).

The location of eggs and larvae in blood vessels and interstitial lung tissue, inguinal lymph nodes, and feces; the absence of adult nematodes in the airways; the size of the larvae; and the presence of the dorsal process of the tail are characteristic of *Elaphostrongylus* (Nematoda, Protostrongylidae) infection. The identification of *Elaphostrongylus cervi* was based on the dimensions of the larvae and the length and width of the dorsal-spined L1 larvae; findings were consistent with Rezác (1990) (390–459 and 16–23 μm , respectively) and Lankester (2001) (392–445 and 17–22 μm).

The genus *Elaphostrongylus* includes three species: *E. cervi*, *E. alces*, and *E. rangiferi* that affect wild ruminants (Stuve and Skorpung, 1987; Handeland et al., 2000; Lankester, 2001). *Elaphostrongylus rangiferi* naturally affects reindeer/caribou (*Rangifer tarandus*) and moose (*Alces alces*), but not red deer. *Elaphostrongylus alces* affects only reindeer and moose (Lankester, 2001). *Elaphostrongylus rangiferi* is present in Europe only in Scandinavia and Russia above 62°N latitude (Roneus and Nordkvist, 1962), and it does not affect red deer (Lankester, 2001). The specificity of *E. rangiferi* and *E. alces* for hosts that are not present in Italy strongly reinforces the identity of the nematode as *E. cervi*.

Attempts have been made to distinguish the single-strand conformation polymorphism (SSPC) profiles of *E. cervi* from those *E. rangiferi* using molecular techniques but these have proven unsuccessful because of a lack of interspecific sequence differences in this region of the ITS-1 (Huby-Chilton et al., 2006). Adult worms were not available from this study for species identification but this is not unexpected. The absence of adult worms in young deer examined in this study could be attributable to the prepatent period lasting 3 to 4 mo. In addition, the inability

to recover adult nematodes from adult deer is dependent on the thorough examination of muscle, which can prove difficult when examining animals harvested by hunters (Lankester, 2001).

This is the first report of *E. cervi* in free-ranging red deer in Italy. The presence of *E. cervi* in the deer from the study region is not surprising given that the original stock came from Austria and Scotland, where infection with this parasite is common (Kutzer and Prosl, 1975; English et al., 1985; Hollands, 1985).

We wish to thank Joseph R. Geraci, Research Professor, Department of Pathology, Comparative Medicine Program, University of Maryland School of Medicine and Steen Larsen, Consultant, Denmark for their important contribution. We wish also to thank the Coordination and Technical Committee of the ACATE (Areale del Cervo dell'Appennino Tosco-Emiliano), in particular the ATC (Ambito Territoriale di Caccia) of Pistoia (PT16) and Bologna (BO4).

LITERATURE CITED

- ANDERSON, R. C. 2000. The Superfamily Metastrongyloidea. In Nematode parasites of vertebrates. Their development and transmission, R. C. Anderson (ed.), 2nd edition. CABI Publishing, New York, New York, pp. 129–147.
- ENGLISH, A. W., C. F. WATT, AND W. CORRIGALL. 1985. Larvae of *Elaphostrongylus cervi* in the deer of Scotland. *Veterinary Record* 116: 254–256.
- ERIKSEN, L., J. MONRAD, AND M. STEEN. 1989. *Elaphostrongylus cervi* in Danish wild red deer (*Cervus elaphus*). *Veterinary Record* 124: 124.
- GAJADHAR, A. A., S. V. TESSARO, AND W. D. G. YATES. 1994. Diagnosis of *Elaphostrongylus cervi* in New Zealand red deer (*Cervus elaphus*) quarantined in Canada, and experimental determination of a new extended prepatent period. *Canadian Veterinary Journal* 35: 433–437.
- HANDELAND, K., L. M. GIBBONS, AND A. SKORPING. 2000. Aspects of the life cycle and pathogenesis of *Elaphostrongylus cervi* of red deer (*Cervus elaphus*). *Journal of Parasitology* 86: 1061–1066.
- HOLLANDS, R. D. 1985. *Elaphostrongylus cervi cervi* in the nervous central system of red deer (*Cervus elaphus*) in Scotland. *Veterinary Record* 116: 584–585.
- HUBY-CHILTON, F., N. B. CHILTON, M. W. LANKESTER, AND A. A. GAJADHAR. 2006. Single-strand conformation polymorphism (SSCP) analysis as a new diagnostic tool to distinguish dorsal-spined larvae of the Elaphostrongylinae (Nematoda: Protostrongylidae) from cervids. *Veterinary Parasitology* 135: 153–162.
- KUTZER, V. E., AND H. PROSL. 1975. Zur kenntnis von *Elaphostrongylus cervi* Cameron, 1931. I. Morphologie und diagnose. (For the knowledge of *Elaphostrongylus cervi*. Cameron 1931. I. Morphology and diagnosis). *Wiener Tierärztlicher Monatschrift* 62: 258–266.
- LANKESTER, M. W. 2001. Extrapulmonary lungworms of cervids. In *Parasitic disease of wild mammals*, W. M. Samuel, M. J. Pybus and A. A. Kocan (eds.), 2nd edition. Manson Publishing/the Veterinary Press, London, United Kingdom, pp. 252–268.
- MASON, P. C., AND H. J. F. McALLUM. 1976. *Dictyocaulus viviparus* and *Elaphostrongylus cervi* in wapiti. *New Zealand Veterinary Journal* 24: 23.
- MATTIOLI, S., AND S. NICOLOSO. 2003. La gestione del cervo in Italia: l'esperienza dell'Appennino Tosco-Emiliano. *Habitat* 130: 54–57.
- MAZZARONE, V., AND S. MATTIOLI. 1996. Indagine sulla popolazione di cervo dell'Acquerino: relazione finale 1993–1995. Regione Toscana, Firenze, Italy, pp. 1–133.
- MINISTRY OF AGRICULTURE, FOOD, AND FISHERIES. 1986. Manual of veterinary parasitological laboratory techniques. Reference book n°418, Her Majesty's Stationery Office, London, United Kingdom, pp. 17–19.
- PREMUDA, G. 1975. Origine e consistenza attuale del patrimonio faunistico della montagna pistoiese. *Diana* 11: 28–31.
- PRESIDENTE, P. J. A. 1986. First record of the tissue worm in Australia. *Federal Deerbreeder* 5: 13–17.
- REZÁČ, P. 1990. Differential diagnosis of 1st-stage larvae of the nematodes *Varestrongylus cervi* and *Elaphostrongylus cervi*. *Veterinarstvo* 40: 311–313.
- RONEUS, O., AND M. NORDKVIST. 1962. Cerebrospinal and muscular nematodiasis (*Elaphostrongylus rangiferi*) in Swedish reindeer. *Acta Veterinaria Scandinavica* 3: 201–225.
- STUVE, G., AND A. SKORPING. 1987. Experimental *Elaphostrongylus cervi* infection in moose (*Alces alces*). *Acta Veterinaria Scandinavica* 28: 165–171.

Received for publication 26 August 2005.