

Phaeohyphomycosis in a Free-Living Eastern Box Turtle (*Terrapene carolina carolina*)

Authors: Joyner, Priscilla H., Shreve, Allison A., Spahr, John, Fountain, Andrea L., and Sleeman, Jonathan M.

Source: Journal of Wildlife Diseases, 42(4) : 883-888

Published By: Wildlife Disease Association

URL: <https://doi.org/10.7589/0090-3558-42.4.883>

BioOne Complete (complete.BioOne.org) is a full-text database of 200 subscribed and open-access titles in the biological, ecological, and environmental sciences published by nonprofit societies, associations, museums, institutions, and presses.

Your use of this PDF, the BioOne Complete website, and all posted and associated content indicates your acceptance of BioOne's Terms of Use, available at www.bioone.org/terms-of-use.

Usage of BioOne Complete content is strictly limited to personal, educational, and non - commercial use. Commercial inquiries or rights and permissions requests should be directed to the individual publisher as copyright holder.

BioOne sees sustainable scholarly publishing as an inherently collaborative enterprise connecting authors, nonprofit publishers, academic institutions, research libraries, and research funders in the common goal of maximizing access to critical research.

Phaeohyphomycosis in a Free-Living Eastern Box Turtle (*Terrapene carolina carolina*)

Priscilla H. Joyner,^{1,6} Allison A. Shreve,^{1,4} John Spahr,² Andrea L. Fountain,³ and Jonathan M. Sleeman^{1,5}

¹ The Wildlife Center of Virginia, PO Box 1557, Waynesboro, Virginia 22980, USA; ² Blue Ridge Pathologists, Fishersville, Virginia 22939, USA; ³ Department of Microbiology, Augusta Medical Center, Fishersville, Virginia 22939, USA; ⁴ Current address: VCA Tampa Bay Animal Clinic, 8501 La Due Lane, Tampa, Florida 33614, USA; ⁵ Current address: Virginia Department of Game and Inland Fisheries, 4010 West Broad Street, Richmond, Virginia 23230, USA; ⁶ Corresponding author (email: phjoyner@seadevil.net)

ABSTRACT: A free-ranging eastern box turtle (*Terrapene carolina carolina*) was referred to the Wildlife Center of Virginia with a three-month history of marked swelling of the right hind limb initially diagnosed as chromomycosis by histopathology. Hematology revealed severe anemia (9%), leukocytosis ($12.8 \text{ cells} \times 10^3/\mu\text{l}$), heterophilia ($6.14 \text{ cells} \times 10^3/\mu\text{l}$), and monocytosis ($0.51 \text{ cells} \times 10^3/\mu\text{l}$). Gross necropsy revealed a firm, encapsulated $3 \times 1 \text{ cm}$ subcutaneous mass filled with dark brown-black, friable necrotic material of the distal right hind limb. Microscopically, the mass was characterized by a granulomatous inflammatory process with numerous multinucleated histiocytic giant cells. Fungal elements were present within necrotic centers and associated with multinucleated cells. Special stains revealed numerous phaeoid hyphae and yeast; *Exophiala jeanselmei* was isolated by routine mycologic culture. Phaeohyphomycosis was diagnosed based on the histologic appearance of the fungal elements within the mass and culture results. There was no histopathological evidence of systemic infection. This is the first report of phaeohyphomycosis caused by fungi of the genus *Exophiala* in free-living reptiles.

Key words: Eastern box turtle, *Exophiala jeanselmei*, mycosis, phaeohyphomycosis, *Terrapene carolina carolina*.

Limited information is available regarding fungal disease in free-ranging reptiles with very few reports (McAllister et al., 1993; Jacobson and Cheatwood, 2000; Rose et al., 2001; Cheatwood et al., 2003). Furthermore, there are fewer reports in the literature describing infection due to phaeohyphomycotic agents, a group of dematiaceous (pigmented) fungal organisms, in reptiles (Weitzman et al., 1985; Jacobson and Cheatwood, 2000). These fungi are ubiquitous in soil and decaying matter and are opportunistic pathogens of vertebrates usually intro-

duced by traumatic inoculation. Although infection is most frequently reported in immunocompetent humans, in animals it may be associated with a compromised or suppressed immune system (Lobetti, 1996). This paper describes a case of phaeohyphomycosis in an eastern box turtle (*Terrapene carolina carolina*) and to our knowledge is the first report of clinical infection caused by the genus *Exophiala* in a free-living reptile.

An adult male eastern box turtle was referred to the Wildlife Center of Virginia (WCV) in December 2003. Initially, the turtle was presented to a wildlife rehabilitation facility in Fairfax County Virginia by a private citizen. Three months prior to referral, the animal was treated for marked swelling of the right hind limb. A mass involving the right proximal tibia was removed at the referring facility and diagnosed as chromomycosis by histopathology. Treatment included supportive care, a series of antimicrobial treatments, and a 1-mo course of 1 mg itraconazole administered orally once daily. On presentation to WCV, the turtle weighed 0.45 kg and was well hydrated and in good body condition. Swelling with localized edema was visible surrounding and distal to the right stifle, and a circumferential mass was palpable on the right proximal tibia. The lateral two digits were missing from the right hind foot. No additional abnormalities were noted on physical examination.

Two-tenths milliliters of blood was collected from the subcarapacial sinus into a heparinized 1-ml syringe using a 25-gauge needle. Hematocrit was determined

by microhematocrit centrifugation, and plasma protein levels were approximated using a refractometer. Within 10 min of obtaining the blood sample, a manual white blood cell count was performed using the eosinophil Unopette® 5877 system (Becton Dickinson and Company, Franklin Lakes, New Jersey, USA) and a hemocytometer. The total leukocyte count was determined, and the white blood cell differential was calculated by the indirect method (Campbell, 1988). Results were compared with physiological reference ranges for the common box turtle (*Terrapene carolina*) and presented as mean \pm SD (International Species Inventory System, 2002). The hematocrit was decreased at 9% (mean = $22.2 \pm 6.6\%$), and the hemogram revealed a leukocytosis ($12.80 \text{ cells} \times 10^3/\mu\text{l}$; mean = $7.05 \pm 4.61 \times 10^3/\mu\text{l}$) with heterophilia ($6.14 \text{ cells} \times 10^3/\mu\text{l}$; mean = $2.47 \pm 2.05 \times 10^3/\mu\text{l}$) and monocytosis ($0.51 \text{ cells} \times 10^3/\mu\text{l}$; mean = $0.12 \pm 0.07 \text{ cells} \times 10^3/\mu\text{l}$). Lateral and caudo-cranial radiographs revealed marked soft tissue swelling of the entire right hind limb, particularly the caudal and plantar aspects. The third and fourth digits of the right hind limb were absent. No other abnormalities were noted on radiographic examination. The box turtle was euthanized with intravenous pentobarbital because of the severity and extent of the soft tissue involvement and guarded prognosis for return to function and subsequent survival in the wild.

At necropsy, the right hind limb was swollen with a palpably firm subcutaneous mass surrounding the right proximal tibia. The third and fourth digits were absent from the right hind limb. Subcutaneously, a 3 cm \times 1 cm encapsulated mass extended distally along the caudal aspect of the right tibia. A subcutaneous adhesion was associated with the mass on the caudolateral aspect of the right midtibia where a remnant of suture material was present. The capsule was filled with dark brown-black, friable necrotic material (Fig. 1). The liver was diffusely pale, and a black

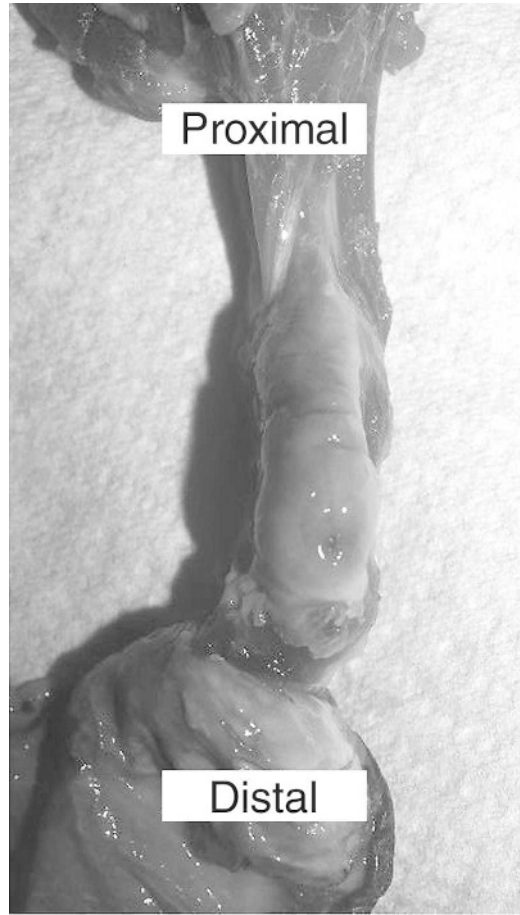

FIGURE 1. Necropsy specimen of the right hind limb of an eastern box turtle (*Terrapene carolina*). The skin is reflected distally to expose a subcutaneous mass. Note the small opening and pigmentation in the caudodistal portion of the capsule, as well as edema.

branching line was visible on the surface of the right lobe. The lungs had diffuse multifocal patches of dark red discoloration on the surface. No other gross abnormalities were noted.

Histopathologic examination of the subcutaneous soft tissue mass revealed a granulomatous inflammatory process including lymphoid cells, eosinophils, and histiocytes (Fig. 2). Numerous multinucleated histiocytic giant cells, often arranged in ringed groups around necrotic debris, were present. Numerous phaeoid (brown) fungal elements consisting of hyphae and

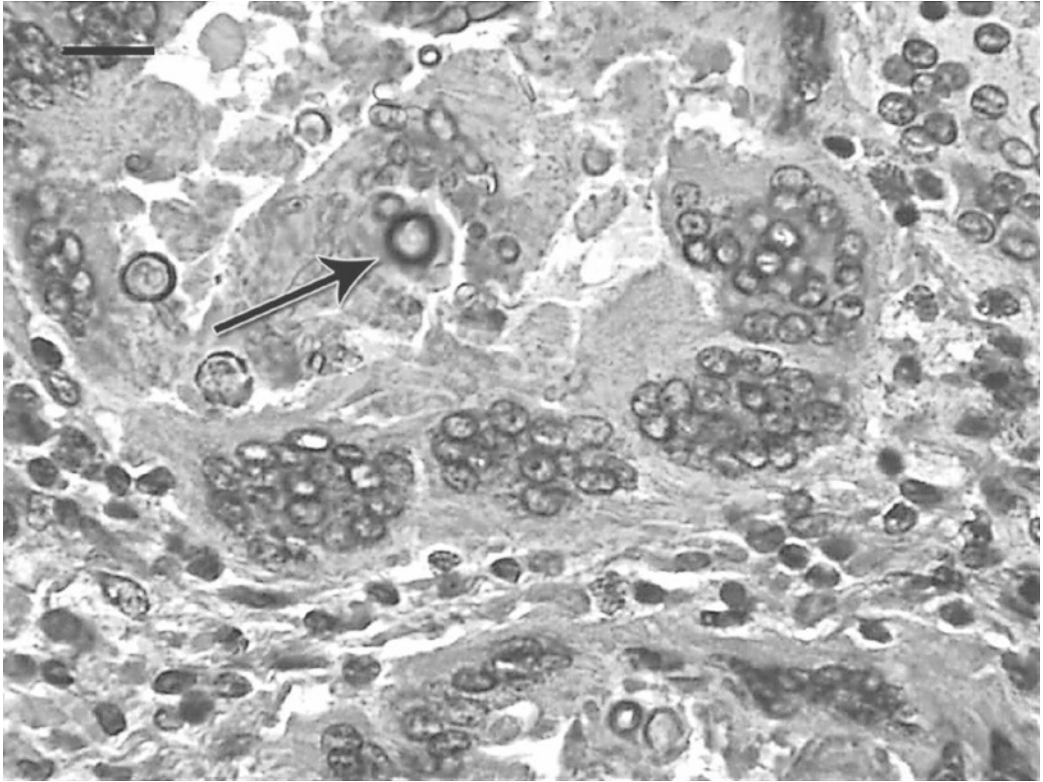


FIGURE 2. Photomicrograph of the subcutaneous lesion on the right hind limb of an eastern box turtle (*Terrapene carolina carolina*). Note the granuloma with peripheral multinucleated histiocytic giant cells and a necrotic center with brown pigmented fungal hyphae and conidia (arrow). H&E. Bar=10 μ m.

yeastlike cells were seen within the necrotic centers and associated with multinucleated cells. Gomori methenamine silver stains revealed chains of ovoid yeastlike bodies (conidia) as well as short rectangular hyphae with occasional right-angle branching. The coelomic viscera were unremarkable, except for the liver, which had pale and clear hepatocytes. There was no microscopic evidence of systemic fungal infection in any of the other tissues examined including lung, heart, esophagus, stomach, spleen, pancreas, liver, kidney, testes, intestine, cloaca, and right hind limb integument. A histopathologic diagnosis of chromomycosis of the subcutaneous tissue was made.

A sterile swab of the pigmented lesion was obtained at necropsy and submitted for fungal culture at the Augusta Medical Center, Fishersville, Virginia, USA. The

specimen was cultured on Brain Heart Infusion Agar with 10% sheep blood, gentamicin, and chloramphenicol, Inhibitory Mold Agar with gentamicin, Mycosel™ Agar, and Sabouraud Dextrose Agar (BBL™ Prepared Plated Media, BD Diagnostic Systems, Sparks, Maryland, USA) and incubated at 30 C. After 48 hr, several small, white colonies were observed on the Sabouraud plate and were identified as *Candida* (*Torulopsis*) *glabrata* using the API20C yeast identification system (bioMérieux, 595 Anglum Road, Hazelwood, Missouri, USA). After 7 days, numerous colonies (small, black, and shiny with black reverse [colony color on back of petri dish]) were seen on all media. Colonies changed to dark gray, velvety colonies after an additional 7-day incubation period. A slide culture was performed using Cornmeal Agar (BBL™ Prepared Plated

Media) incubated at 30 C and was examined microscopically after sufficient growth was observed on the coverslip. Microscopic examination revealed septate hyphae with slender, tubular annellides, occasionally branched with tapered tips, supporting clusters of small, oval conidia 2–3 μm in length. Based on growth rate and macroscopic and microscopic appearance, the organism was identified as *Exophiala jeanselmei* (Larone, 1995).

Chromomycosis is a general term for a group of clinicopathologic syndromes caused by fungal agents classified as chromoblastomycoses and phaeohyphomycoses (de Hoog et al., 2000a). The distinction lies in the fungal form present in the tissues: dermal muriform cells or sclerotic bodies in chromoblastomycosis versus hyphal fungal forms in phaeohyphomycosis (de Hoog et al., 2000a). Infection can be further classified based on location including superficial, cutaneous, subcutaneous, and deep mycoses. Colonization is often associated with traumatic inoculation (Wagner, 2000) and/or immunocompromised hosts (Lobetti, 1996). Deep mycoses may occur secondary to inhalation, ingestion, or dissemination via blood and lymphatic systems (de Hoog et al., 2000b). Infection can be diagnosed via cytology or histology, but the causative agent must be isolated by culture (de Hoog et al., 2000a).

Chromomycosis has been described in domestic mammals, birds, reptiles, amphibians, fish, and crustaceans (Bube et al., 1992; Aiello, 1998; Reavill and Schmidt, 2004). Although mycotic infections are relatively common in captive reptiles (Schumacher, 2003), reports of phaeohyphomycosis are scarce in the reptile literature. A microscopic description of *Scolecobasidium*, a phaeohyphomycotic agent of fish, has been reported in an eastern box turtle (Weitzman et al., 1985). Chromomycosis has been reported in a mangrove snake (*Boiga dendrophila*); however, cultures were unsuccessful, and it was not possible to identify the organism (Jacobson, 1984).

Various antifungal drugs have been used in the treatment of phaeohyphomycoses with questionable efficacy (Wagner, 2000). Excision or debulking is recommended before chemotherapy begins and is potentially curative (de Hoog et al., 2000a; Meletiadiis et al., 2000; Wagner, 2000). Surgical debulking of the lesion was not performed in this case because of the extent of local tissue invasion and the possibility of disseminated disease due to chronic infection.

Exophiala jeanselmei is a saprophytic dematiaceous fungus most commonly found in decaying wood and soil that is enriched with organic waste as well as polluted water and sewage (de Hoog et al., 2000a; Nucci et al., 2002). It is considered an opportunistic pathogen, but phaeohyphomycosis caused by *Exophiala* species has been reported in both immunosuppressed and immunocompetent human patients (Wagner, 2000). Fungal disease caused by *Exophiala* has been reported in humans, domestic animals (Lobetti, 1996; Helms and McLeod, 2000), wild turkeys (*Meleagris gallopavo*) (Davidson et al., 1989), fruit-eating bats (*Eidolon helvum*) (Muotoe-Okafor and Gugnani, 1993), and Atlantic salmon (*Salmo salar* L.) (Otis et al., 1985). Although it was not possible in this case to confirm the presence of *Exophiala* in tissue by immunohistochemistry (IHC) or polymerase chain reaction (PCR), the histologic sections clearly showed a phaeoid fungus in the appropriate inflammatory reaction, implicating this as the infectious agent. The cultural isolation of *E. jeanselmei* validates the histopathology, especially the finding of yeastlike cells, which are often seen in young colonies of this genus (de Hoog et al., 2000b). Histopathology with corroborating microbiology is a time-honored standard for defining a specific infectious etiology. As fungal elements in affected tissues were phaeoid and not consistent with the morphology of *C. glabrata*, we suspect *Candida* was a contaminant, and its isolation was considered incidental.

This represents the first substantiated report of *Exophiala*-associated phaeohyphomycosis in a free-living reptile.

The origin of infection is unknown. Phaeohyphomycotic infections are generally caused by traumatic implantation into the skin. When the soft tissue mass was dissected, there was a small opening in the caudodistal portion of the subcutaneous capsule suggestive of a possible site of inoculation. Although the integument showed no obvious evidence of trauma, the absent digits of the right hind limb indicated possible previous traumatic inoculation. In addition, infection has been associated with a local or systemic immunosuppression. Lymphopenia has been reported as a common factor in previous cases of phaeohyphomycosis in dogs (Lobetti, 1996); however, lymphopenia was not present in this case. Other means of assessing immune function were not explored; therefore, we were unable to determine definitively whether this infection was the result of direct inoculation, immunosuppression, or both.

We thank the staff at the Wildlife Center of Virginia and Caroline Seitz for referral of this case.

LITERATURE CITED

- AIELLO, S. E. (ed.). 1998. The Merck veterinary manual. 8th Edition. Merck & Co., Whitehouse Station, New Jersey.
- BUBE, A., E. BURKHARDT, AND R. WEIB. 1992. Spontaneous chromomycosis in the marine toad (*Bufo marinus*). *Journal of Comparative Pathology* 106: 73–77.
- CAMPBELL, T. W. 1988. Avian hematology and cytology. Iowa State University Press, Ames, Iowa, 101 pp.
- CHEATWOOD, J. L., E. R. JACOBSON, P. G. MAY, T. M. FARREL, B. L. HOMER, D. A. SAMUELSON, AND J. W. KIMBROUGH. 2003. An outbreak of fungal dermatitis and stomatitis in a free-ranging population of pigmy rattlesnakes (*Sistrurus miliarius barbouri*) in Florida. *Journal of Wildlife Diseases* 39: 329–337.
- DAVIDSON, W. R., E. B. SHOTTS, J. TESKA, AND D. W. MORELAND. 1989. Feather damage due to mycotic infections in wild turkeys. *Journal of Wildlife Diseases* 25: 534–539.
- DE HOOG, G. S., F. QUEIROZ-TELLES, G. HAASE, G. FERNANDEZ-ZEPPEFELDT, D. A. ANGELIS, A. H. G. G. VAN DEN ENDE, T. MATOS, H. PELTROCHE-LACSAHUANGA, A. A. PIZZIRANI-KLEINER, J. RAINER, N. RICHARD-YEGRES, V. VICENTE, AND F. YEGRES. 2000a. Black fungi: Clinical and pathogenic approaches. *Medical Mycology* 38: 243–250.
- , ———, J. GUARRO, J. GENE, AND M. J. FIGUERAS. 2000b. Atlas of clinical fungi. 2nd Edition. Centraalbureau voor Schimmelfcultures, Utrecht, The Netherlands, 1126 pp.
- HELMES, S. R., AND C. G. MCLEOD. 2000. Systemic *Exophiala jeanselmei* infection in a cat. *Journal of the American Veterinary Medical Association* 217: 1858–1861.
- INTERNATIONAL SPECIES INVENTORY SYSTEM. 2002. Reference ranges for physiological values in captive wildlife. International species inventory system, 2002 Edition, Apple Valley, Minnesota.
- JACOBSON, E. R. 1984. Chromomycosis and fibrosarcoma in a mangrove snake. *Journal of the American Veterinary Medical Association* 185: 1428–1430.
- , AND J. L. CHEATWOOD. 2000. Mycotic diseases of reptiles. *Seminars in Avian and Exotic Pet Medicine* 9: 94–101.
- LARONE, D. H. 1995. Medically important fungi: A guide to identification. 3rd Edition. ASM Press, Washington, D.C. 214 pp.
- LOBETTI, R. G. 1996. Leukogram and serum globulin values in two dogs with systemic *Xylohypha bantiana* infection. *Journal of the South African Veterinary Association* 67: 91–92.
- MCCALLISTER, C. T., S. R. GOLDBERG, H. J. HOLSHUH, AND S. E. TRAUTH. 1993. Disseminated mycotic dermatitis in a wild-caught timber rattlesnake, *Crotalus horridus* (Serpentes: Viperidae), from Arkansas. *Texas Journal of Science* 45: 279–281.
- MELETIADIS, J., J. F. G. M. MEIS, G. S. DE HOOG, AND P. E. VERWEIJ. 2000. In vitro susceptibilities of 11 clinical isolates of *Exophiala* species to six antifungal drugs. *Mycoses* 43: 309–312.
- MUOTOE-OKAFOR, F. A., AND H. C. GUGNANI. 1993. Isolation of *Lecythrphora mutabilis* and *Wangiella dermatitidis* from the fruit-eating bat, *Eidolon helvum*. *Mycopathologia* 122: 95–100.
- NUCCI, M., T. AKITI, G. BARREIROS, F. SILVEIRA, S. REVANKAR, B. L. WICKES, D. A. SUTTON, AND T. F. PATTERSON. 2002. Nosocomial outbreak of *Exophiala jeanselmei* fungemia associated with contamination of hospital water. *Clinical Infectious Diseases* 34: 1475–1480.
- OROS, J., C. DELGADO, L. FERNANDEZ, AND H. E. JENSEN. 2004. Pulmonary hyalohyphomycosis caused by *Fusarium* spp in a Kemp's ridley sea turtle (*Lepidochelys kempi*): An immunohistochemical study. *New Zealand Veterinary Journal* 52: 150–152.
- OTIS, E. J., R. E. WOLKE, AND V. S. BLAZER. 1985. Infection of *Exophiala salmonis* in Atlantic

- salmon (*Salmo salar* L.). Journal of Wildlife Diseases 21: 61–64.
- REAVILL, D. R., AND R. E. SCHMIDT. 2004. Reptile mycotic infections from the literature and 55 cases. In Proceedings of the Association of Reptilian and Amphibian Veterinarians, Joint Conference May 6–11, Naples, Florida, pp. 62–71.
- ROSE, F. L., J. KOKE, R. KOEHN, AND D. SMITH. 2001. Identification of the etiological agent for necrotizing scute disease in the Texas tortoise. Journal of Wildlife Diseases 37: 223–228.
- SCHUMACHER, J. 2003. Fungal diseases of reptiles. The Veterinary Clinics of North America, Exotic Animal Practice 6: 327–335.
- WAGNER, K. F. 2000. Agents of chromomycosis. In Mandell, Douglas, and Bennett's principles and practice of infectious diseases, G. L. Mandell, J. E. Bennett and R. Dolin (eds.). Harcourt Health Sciences, Philadelphia, Pennsylvania, pp. 2699–2702.
- WEITZMAN, I., S. A. ROSENTHAL, AND J. L. SHUPACK. 1985. A comparison between *Dactylaria gallopava* and *Scolecobasidium humicola*: First report of an infection in a tortoise caused by *S. humicola*. Sabouraudia 23: 287–293.

Received for publication 31 March 2005.