

DETECTION OF DICHELOBACTER NODOSUS IN WILD UNGULATES (CAPRA IBEX IBEX AND OVIS ARIES MUSIMON) AND DOMESTIC SHEEP SUFFERING FROM FOOT ROT USING A TWO-STEP POLYMERASE CHAIN REACTION

Authors: Belloy, Luc, Giacometti, Marco, Boujon, Patrick, and Waldvogel, Andreas

Source: Journal of Wildlife Diseases, 43(1) : 82-88

Published By: Wildlife Disease Association

URL: <https://doi.org/10.7589/0090-3558-43.1.82>

BioOne Complete (complete.BioOne.org) is a full-text database of 200 subscribed and open-access titles in the biological, ecological, and environmental sciences published by nonprofit societies, associations, museums, institutions, and presses.

Your use of this PDF, the BioOne Complete website, and all posted and associated content indicates your acceptance of BioOne's Terms of Use, available at www.bioone.org/terms-of-use.

Usage of BioOne Complete content is strictly limited to personal, educational, and non - commercial use. Commercial inquiries or rights and permissions requests should be directed to the individual publisher as copyright holder.

BioOne sees sustainable scholarly publishing as an inherently collaborative enterprise connecting authors, nonprofit publishers, academic institutions, research libraries, and research funders in the common goal of maximizing access to critical research.

DETECTION OF *DICHELOBACTER NODOSUS* IN WILD UNGULATES (*CAPRA IBEX IBEX* AND *OVIS ARIES MUSIMON*) AND DOMESTIC SHEEP SUFFERING FROM FOOT ROT USING A TWO-STEP POLYMERASE CHAIN REACTION

Luc Belloy,¹ Marco Giacometti,² Patrick Boujon,^{1,3} and Andreas Waldvogel¹

¹ Institut Galli-Valerio, Veterinary Diagnostic Laboratory of the Canton Vaud, CH-1014 Lausanne, Switzerland

² Wildvet Projects, CH-7605 Stampa, Switzerland

³ Corresponding author: (e-mail: patrick.boujon@vd.ch)

ABSTRACT: Severe keratinous hoof afflictions have been recorded in ibex (*Capra ibex ibex*) since 1995 and more recently in mouflon (*Ovis aries musimon*) in Switzerland. Based on clinical observations and comparison with diseases known to affect domestic ungulates, it was hypothesized these wild ungulates were affected by foot rot associated with infection with *Dichelobacter nodosus*. *Dichelobacter nodosus* has been shown to be the essential pathogen for initiation and establishment of foot rot, a highly contagious foot disease of sheep and goats. Because these bacteria could not be cultivated from affected ibex, we developed a nested polymerase chain reaction that allowed detection of *D. nodosus* without culture. Using this assay, we were able to diagnose *D. nodosus* infections of ibex, mouflon, and domestic sheep in natural outbreaks. From these results we conclude that *D. nodosus* plays an etiological role in foot rot not only in domestic but also in wild Caprinae.

Key words: *Capra ibex ibex*, *Dichelobacter nodosus*, foot rot, mouflon, *Ovis aries musimon*, PCR, wild ungulates.

INTRODUCTION

Foot rot in domestic sheep and goats is a highly contagious disease that results from a mixed bacterial infection of the claw, in which the obligate parasite *Dichelobacter nodosus* is essential for the initiation and establishment of the infection (Hindmarsh and Fraser, 1985; Stewart et al., 1986; Egerton, 2000). In domestic ungulates, particularly in sheep, foot rot is a frequent and economically important disease. Although it is not fatal itself it may lead to separation of the keratinous hoof from the underlying epidermal tissue in the worst case, resulting in severe lameness and inability to feed (Egerton et al., 1969).

Dichelobacter nodosus has been identified in European mouflon (*Ovis a. musimon*) suffering from pododermatitis in Germany (Nattermann et al., 1990). Foot rot was experimentally reproduced in domestic sheep using *D. nodosus* strains isolated from mouflon (Nattermann et al., 1993) in order to prove the possibility of transmission between different host spe-

cies. This lack of strict host specificity of *D. nodosus* was also confirmed by demonstrating natural transmission between sheep and goats (Ghimire et al., 1999). In alpine countries, such as France, Austria and Switzerland, clinical observations of epidemic pododermatitis were reported in several free-ranging Alpine ibex (*Capra ibex ibex*) populations (Glawishnig et al., 1998; Delétraz, 2002). Swiss studies suggested that an exchange between sheep and ibex was possible, but this hypothesis still needed to be confirmed (Janett, 1993).

Isolation of *D. nodosus* from affected Alpine ibex feet was been tried but was unsuccessful (Glawishnig et al., 1998; Delétraz, 2002). Culture of the slow-growing anaerobic agent is difficult. In addition, a long interval between sampling and bacteriological examination, often inevitable with ibex from remote mountain areas, increases the possibility of overgrowth by contaminating bacteria and thus further reduces the chance of isolating *D. nodosus*. Molecular methods for the specific identification of *D. nodosus* have

been developed (La Fontaine et al., 1993), but have never been used in wild Caprinae species. We therefore tested a single-step polymerase chain reaction (PCR) in Alpine ibex and European mouflon affected by pododermatitis and developed a nested PCR to increase test sensitivity in clinical samples. Using this approach, we were able to demonstrate the presence of *D. nodosus* in foot lesions of domestic sheep and wild ungulates from the Swiss Alps.

MATERIALS AND METHODS

Ibex suffering from lameness were shot by state gamekeepers in different regions of Switzerland. Feet with suspicious lesions were examined grossly. Bacteria from 19 out of 25 ibex were sampled in the field using cotton swabs. Three swabs were used per foot, allowing surface sampling from three distinct sites: interdigital skin, bulb, and wall. Swabs were placed in transport medium (culture-Swab transport system, Difco Laboratories, Detroit, Michigan, USA) and submitted by courier for examination. In addition, feet from eight of 25 ibex were sent to the Institut Gallivallerio in Lausanne (Table 1). Swabs and feet arrived in the laboratory within 48 hr of sampling and were analyzed immediately or stored at -20°C . Furthermore, two Mouflon with clinical signs of foot rot were shot and their feet sent to our laboratory. Sampling in the field was not performed in these cases (Table 1). Finally, feet of four sheep, two without and two with clinical foot rot, were used as controls. Podal horn was taken from the two affected sheep in the field. From the two unaffected sheep, feet were collected at an abattoir for laboratory diagnosis after clinical examination by a veterinarian. Feet of wild animals were not labeled as anterior or posterior, or left or right upon receipt. However, morphology allowed distinguishing anterior from posterior but not always left from right feet. Samples were excised at the three anatomical sites mentioned above with the exception of the feet from sheep with foot rot, where only horn of the bulb was collected.

Trypticase arginine serine (TAS) medium was prepared using 1.5% (w/v) trypticase peptone (Becton-Dickinson, Cockeysville, Maryland, USA), 0.5% (w/v) beef extract (Oxoid, Lab-Lemco, Praheim, Switzerland), 0.5% (w/v) proteose peptone (Difco), 0.2% (w/v) yeast extract, 0.5% L-arginine HCl (Fluka, Buchs, Switzerland), 0.15% DL-serine

(Sigma, Buchs, Switzerland), and 2% (w/v) Bacto agar (Difco). The final pH was adjusted to 8.0 by addition of NaOH before autoclaving (Skerman, 1975). Plates were incubated under anaerobic conditions for at least 12 hr at 37°C before inoculation. In addition, bacterial culture was done under anaerobic conditions at 37°C for 4 days on these TAS plates as previously described (Skerman, 1975). Strain *D. nodosus* ATCC 27521 grown under the same conditions was used as positive control.

DNA was extracted from cotton swabs in microcentrifuge tubes containing 500 μl of lysis buffer (100 mM Tris-HCl, pH 8.5, 0.05% Tween 20, 0.24 mg/ml proteinase K) and mixed thoroughly for 1 min at room temperature. The cotton swabs were then removed, and the microcentrifuge tubes incubated for 60 min at 60°C followed by an incubation of 15 min at 97°C (Giacometti et al., 1999). DNA was extracted from excised samples by putting approximately 0.2 g of horn or skin in 400 μl of sterile 0.85% NaCl solution and crushing with a sterile mortar and pestle. Two hundred microliters of this suspension were added to 500 μl of lysis buffer and processed as described above.

All PCR reactions were performed in 0.2-ml thin-walled tubes in a DNA thermal cycler (GeneAmp 9600, Perkin Elmer Cetus Norwalk, Connecticut, USA). The following sequences were used for PCR amplification of the 16S rRNA gene: primer 16SUNI-R 5' AGAGTTTGATCATGGCTCAG 3' (Kuhnert et al., 1996, 2002) and primer 16S-L(Dn) 5' AGAGTTTGATTMTGGCTCAG 3' based on the sequence of the primer 27F (Lane, 1991) for the *D. nodosus* 16S rRNA gene sequence (accession number M35016). Three microliters of lysate were added to a 47- μl reaction mix with a final concentration of 4 mM MgCl_2 , 170 μM of each deoxyribonucleotide triphosphate, 200 ng of primers 16SUNI-R and 16S-L(Dn), 5 μl of $10\times$ PCR buffer (100 mM Tris-HCl, pH 8.3, 500 mM KCl) and 1 unit of *Taq* DNA polymerase (Roche Diagnostics, Plenzberg, Germany). An initial denaturation at 95°C for 3 min was followed by 40 amplifications (95°C , 30 sec; 48°C , 30 sec; 72°C , 70 sec) and a final extension of 5 min at 72°C . The size of the resulting amplicon was 1,400 bp.

For nested PCR, 1 μl of product from the initial PCR amplification was added to 49 μl of amplification mix. The primers tested and described by La Fontaine et al. (1993) were used: 5' CGGGGTTATGTAGCTTGC 3' and 5' TCGGTACCGAGTATTTCTACCCAA-CACCT 3'. Conditions were identical to those used for the first amplification except that the

TABLE 1. Data from affected ungulates and samples obtained for analyses.

Animal species	Identification number	Date of isolation	Sex	Age (yr)	Origin ^a	Sample
Ibex	19-18.10.95	October 1995	♂		Château d'Oex VD	Feet
Ibex	24-24.10.95	October 1995	♂	8.5	Château d'Oex VD	Feet
Ibex	25-24.10.95	October 1995	♂	10.5	Château d'Oex VD	Feet
Ibex	26-24.10.95	October 1995	♂	9.5	Château d'Oex VD	Feet
Ibex	27-24.10.95	October 1995	♂	6.5	Château d'Oex VD	Feet
Ibex	11-02.11.95	November 1995	♂	12.5	Ormont-Dessous VD	Swabs
Ibex	12-02.11.95	November 1995	♂		L'Etivaz VD	Swabs
Ibex	20-28.11.95	November 1995	♂	7.5	Ormont-Dessus VD	Feet
Ibex	21-28.11.95	November 1995	♂	7.5	Ormont-Dessus VD	Swabs
Ibex	08-30.07.96	July 1996	♂	11	Montagne de l'Au VS	Swabs
Ibex	01-20.08.96	August 1996	♂	12	Säntis AI	Swabs
Ibex	05-03-09-96	September 1996	♂	6.5	Diableret VD	Swabs
Ibex	06-03.09.96	September 1996	♂	4.5	Diableret VD	Swabs
Ibex	07-03.09.96	September 1996	♂	6.5	Diableret VD	Swabs
Ibex	02-04.09.96	September 1996	♂	7	Alpstein-Säntis AI	Swabs
Ibex	19-06.09.96	September 1996	♂	11	Alpstein-Säntis AI	Swabs
Ibex	14-13.09.96	September 1996	♂	9	Alpstein-Säntis AI	Swabs
Ibex	06-05.10.96	October 1996	♂	10	Alpstein-Säntis AI	Swabs
Ibex	01-18.10.96	October 1996	♂	14	Montagne de l'Au VS	Swabs
Ibex	02-18.10.96	October 1996	♂	10	Montagne de l'Au VS	Swabs
Ibex	11-09.07.97	July 1997				Swabs
Ibex	06-27.08.97	August 1997	♂	10	Gemmi VS	Swabs + Feet
Ibex	02-25.10.97	October 1997	♂	12.5	Châtillon VD	Swabs
Ibex	19-04.11.97	November 1997	♂	8.5	Hinterrhein GR	Swabs
Ibex	03-28.04.98	April 1998	♂	9	Bockistock NW	Swabs + Feet
Mouflon	2030113-007	January 2003	♀		Champéry VS	Feet
Mouflon	2030113-008	January 2003			Champéry VS	Feet
Sheep	1	April 2004	♀		VD	Feet
Sheep	2	April 2004	♀		VD	Feet
Sheep	2041209-157	December 2004	♀		VD	Horn from feet
Sheep	2041209-158	December 2004	♀		VD	Horn from feet

^a Vaud (VD), Valais (VS), Appenzell (AI), Grisons (GR), Nidwall (NW).

MgCl₂ concentration was lowered to 2.5 mM, bovine serum albumin was added at a final concentration of 0.8 µg/µl, and the annealing temperature was increased from 48 C to 50 C (La Fontaine et al., 1993). This second PCR reaction amplified a 16S rRNA gene fragment of 783 bp within the first 1,400-bp amplicon. Amplification products were analyzed by agarose gel electrophoresis and stained with SYBr Green I (Molecular Probes, Leiden, Netherlands). Positive (lysate from ATCC 27521 culture) and negative (DNA-free mixture) controls were included in each PCR.

To confirm the specificity of the nested PCR for *D. nodosus*, all amplicons from samples of both wild animal species (mouflon, ibex) and sheep were sequenced. They were purified using a commercial kit (MinElute PCR purification kit, Qiagen, Hombrechtikon, Switzerland) and purified DNA was cloned into pBluescript SK⁻ vector (Stratagene, La

Jolla, California, USA) using the *EcoRV* restriction enzyme site (Sanbrook and Russell, 2001). Sequencing was done by a private company (Synergene-Biotech GmbH, Schlieren, Switzerland). All sequences were aligned to published bacterial sequences using the blastn program (Altschul et al., 1997; <http://www.ncbi.nlm.nih.gov/BLAST>).

RESULTS

Twenty-five male ibex (Table 1) from 4.5 yr to 14 yr of age (average age of 9.27 yr, median age of 9.5 yr) and two mouflon suffering from lameness were analyzed (Fig. 1). All animals were male with the exception of mouflon 2030113-007. The following lesions were observed in all feet (Fig. 2): interdigital exudative

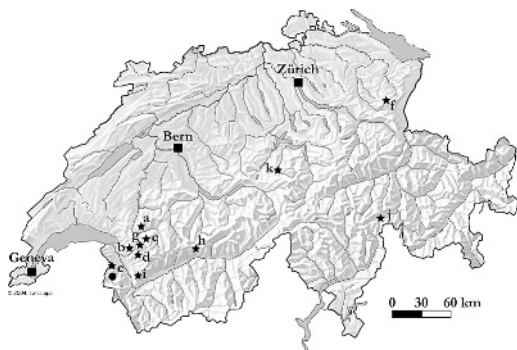


FIGURE 1. Map of Switzerland with origins of wild ungulates suffering from foot rot. Black squares represent major cities of Switzerland (Geneva, Bern, Zürich). The black dot indicates where affected mouflon were detected (Champéry VS, January 2003) and black stars where affected ibex were detected: (a) Château d'Oex VD, October 1995; (b) Ormont-Dessous VD, November 1995; (c) l'Etivaz VD, November 1995; (d) Ormont-Dessus VD, November 1995; (e) Montagne de l'Au VS, July and October 1996; (f) Säntis AI, August, September, and October 1996; (g) Diablerets VD, September 1996; (h) Gemmi VS, August 1997; (i) Châtillon VD, October 1997; (j) Hinterrhein GR, November 1997; (k) Bockistock NW, April 1998).

dermatitis; friable and irregular sole with focal or multifocal sole ulcers; overgrowth of the abaxial horn wall covering the sole and generating a space filled with mud and feces; bulb with oozing hemorrhage; lysis of the white line; hypertrophy of the tip of the claw; and foul odor.

Dichelobacter nodosus could only be cultured from one sample (ibex 19-18.10.95). No culture assay was done from samples of the two mouflon from Champéry or from ovine samples.

Single-step PCR as described by La Fontaine (1993) did not yield positive results. Nested PCR, however, allowed demonstrating the presence of *D. nodosus* DNA in the majority of samples tested (Table 2). Eleven out of 15 anterior feet and four out of 10 posterior ibex feet contained DNA of this agent. In mouflon, *D. nodosus* was detected by nested PCR in the lysate of all four feet of animal 2030113-007 and the lysate of the one anterior foot of animal 2030113-008 (Ta-

ble 2). Sheep 2041209-157 and 2041209-158, with gross lesions suggesting foot rot, yielded a positive result (Table 2). Each wild animal tested, mouflon and ibex, was infected by *D. nodosus* in at least one foot.

All sequences from DNA amplicons were analyzed using the blastn program (Altschul et al., 1997). The highest score was obtained for *D. nodosus* 16S rRNA gene except for the amplicon obtained from sheep 1. Blastn sequence comparison for this amplicon revealed identity to an uncultivable bacteria.

DISCUSSION

Ibex and mouflon suffering from a disease resembling foot rot in sheep were observed in several areas of the Alps (Glawishnig et al., 1998; Delétraz, 2002) but the etiology had not been confirmed either by culture or by molecular methods. Using a nested PCR we were able to demonstrate the presence of *D. nodosus* DNA in affected feet. This strongly suggests that ibex and mouflon were infected by the bacteria that cause foot rot in sheep.

Dichelobacter nodosus was reported as the essential pathogen for initiation and establishment of ovine foot rot (Beveridge, 1941; Egerton et al., 1969) and domestic sheep represent the main reservoir of infection (Hindmarsh and Fraser, 1985). Close contact between sheep and ibex were already reported in the Alps (Janovsky et al., 2001; Giacometti et al., 2002; Belloy et al., 2003) and foot rot was reported to be an endemic disease of sheep in Switzerland (Janett, 1993).

In sheep, virulent, intermediate, and benign clinical forms of the disease have been described (Stewart, 1989; Wani and Samanta, 2006). Feet lesions of ibex and mouflon examined in our laboratory were comparable to those found in sheep affected with highly virulent *D. nodosus*. However, Swiss gamekeepers are not allowed to shoot ibex and mouflon unless they are suffering from severe disease.

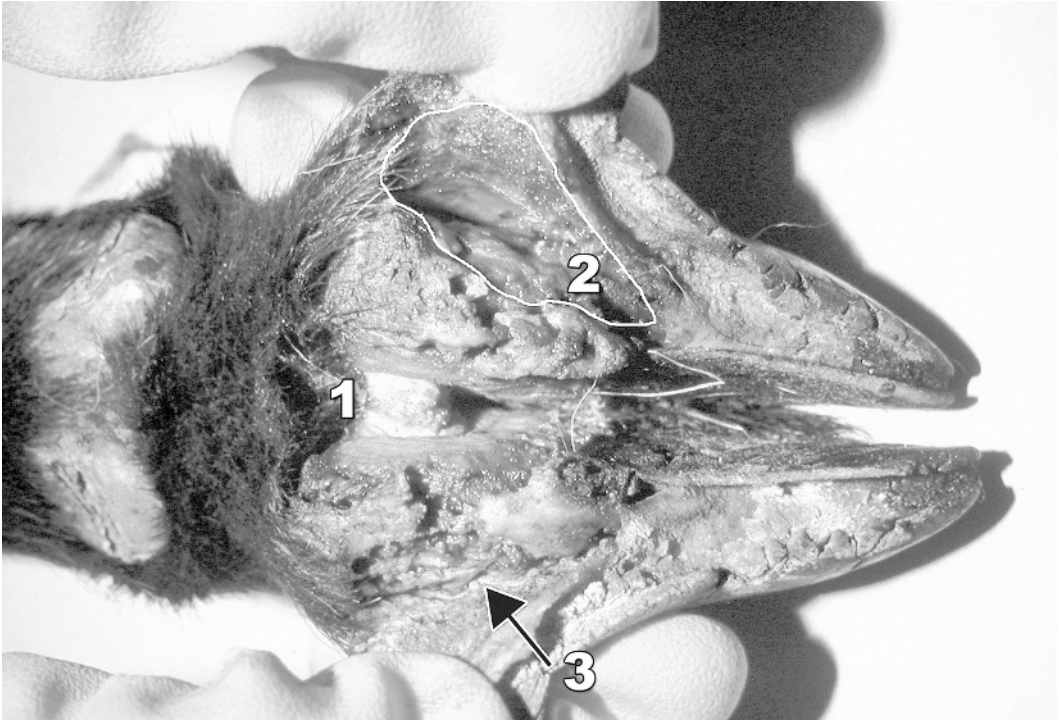

FIGURE 2. Anterior foot of a male ibex with interdigital exudative dermatitis (1), sole ulcer (2) and detachment of the horn of the wall (white line, 3). The sole ulcer was covered by an overgrowth of horn of the bearing border (removed to reveal the ulcer).

Therefore, it was not possible to study benign or intermediate forms of infection or feet from healthy wild animals, which could serve as negative controls. However, the pathological lesions observed in addition to our PCR results are compatible with the hypothesis that *D. nodosus* causes foot rot in free-ranging ibex and mouflon.

In our study, all ibex affected by foot rot were old males (average and median age of 9.27 yr and 9.5 yr, respectively). These animals have a reclusive behavior, except during reproduction. They were observed more frequently on grass-covered slopes facing north and at middle altitudes than were females with their young (Boujon, pers. obs.). Old males, therefore, are often on wet soil of summer pastures shared with domestic sheep and thus more likely to be exposed to these bacteria.

Direct PCR as described by La Fontaine et al. (1993) did not allow detection of *D. nodosus* in ibex and mouflon. Similar

observations were made by Moore et al. (2005) for the detection of *D. nodosus* from clinical samples from sheep. PCR inhibitors in hoof horn, soil particles in the samples, or suboptimal sampling conditions could explain this lack of positive results. To increase sensitivity, we added a second round of PCR amplification using primers within the amplicon of the direct PCR. This allowed detection of *D. nodosus* from lysed foot samples without DNA extraction or culture of bacteria.

Dichelobacter nodosus DNA could be amplified in all but one of the affected anterior feet from wild and domestic ungulates. The great majority of hind feet tested also yielded positive results. One sheep foot without lesions had a positive amplification result. Sequencing revealed that this was a false positive result, probably because of primer cross-reaction with DNA from an uncultivable bacteria. This illustrates the importance of testing PCR

TABLE 2. *Dichelobacter nodosus*-positive nested polymerase chain reaction (PCR) results from foot samples.

Animal	Feet ^a					
	Anterior			Posterior		
	I.S. ^b	Bulb	Wall	I.S.	Bulb	Wall
Mouflon						
2030113-007	1/2	2/2	2/2	0/2	2/2	1/2
2030113-008	1/1	0/1	0/1	n.d. ^c	n.d.	n.d.
Ibex						
19-18.10.95	1/2	1/2	1/2	n.d.	n.d.	n.d.
24-24.10.95	2/2	1/2	1/2	0/2	0/2	0/2
25-24.10.95	2/2	2/2	1/2	0/2	0/2	1/2
26-24.10.95	2/2	1/2	1/2	0/2	0/2	0/2
27-24.10.95	0/2	2/2	1/2	1/2	2/2	1/2
20-28.11.95	2/2	2/2	2/2	1/2	0/2	1/2
06-27.08.97 ^d	1/1	1/1	1/1	n.d.	n.d.	n.d.
03-28.04.98	1/2	1/2	1/2	n.d.	n.d.	n.d.
Sheep						
1	0/2	0/2	0/2	0/2	0/2	1/2 ^e
2	0/2	0/2	0/2	n.d.	n.d.	n.d.
2041209-157	n.d.	2/2	n.d.	n.d.	+	n.d.
2041209-158	n.d.	1/1	n.d.	n.d.	+	n.d.

^a Results are presented as number of feet yielding positive PCR results to the number of feet tested.

^b I.S. = interdigital skin.

^c n.d. = not done.

^d Cotton swabs and feet from the same animal were available.

^e Nested PCR gave an amplicon but sequencing revealed identity to an uncultivable bacterium.

results for plausibility and following up unusual results by sequencing.

No amplifiable DNA could be extracted from cotton swabs used for sampling ibex feet in the field, even when skin and horn samples from the same animal, but taken in the laboratory, yielded positive results. Using cotton swabs in the field allowed sampling from the surface but did not penetrate deep enough into skin and horn to reach sites where anaerobic conditions favor growth of *D. nodosus*. Evidently, the bacterial load of the surface was not massive enough to permit detection of *D. nodosus*. Moore et al. (2005) used sterile wooden applicator sticks to sample interdigital skin, underrunning sole and wall lesions in sheep, and kept samples at 4 C in medium prior to culture. Therefore, our

negative results may be because of inadequate protocols for sampling. In addition, Thorley (1976) observed that a high percentage of agar (4%) may be needed for primary isolation of *D. nodosus* from sheep; thus, the use of 2% agar in our laboratory may not have been optimal.

In conclusion, using a molecular tool that allows detection of *D. nodosus* in the horn of wild and domestic ungulates suffering from foot rot, we were able to corroborate the hypothesis that pododermatitis in ibex may result from an infection with *D. nodosus* and that this disease, foot rot, may also occur in wild animals.

ACKNOWLEDGMENTS

The authors thank Patricia Gabioud for excellent technical support and acknowledge the support of Albert Fritsche, Appenzell. Special thanks to the state gamekeepers of Appenzell, Grisons, St-Gall, Vaud, and Valais for their dedication and for collecting data and samples in the field. The authors also acknowledge Reto Fivian (Sanitary Service for Small Ruminants, Switzerland) and the sheep owners who provided samples from foot rot-affected and healthy animals. This study was funded by the Galli-Valerio Foundation and the Canton Vaud.

LITERATURE CITED

- ALTSCHUL, S. F., T. L. MADDEN, A. A. SCHAFER, J. ZHANG, Z. ZHANG, W. MILLER, AND D. J. LIPMAN. 1997. Gapped BLAST and PSI-BLAST: A new generation of protein database search programs. *Nucleic Acids Research* 25: 3389–3402.
- BELLOY, L., M. JANOVSKY, E. M. VILEI, P. PILO, M. GIACOMETTI, AND J. FREY. 2003. Molecular epidemiology of *Mycoplasma conjunctivae* in Caprinae: Transmission across species in natural outbreaks. *Applied and Environmental Microbiology* 69: 1913–1919.
- BEVERIDGE, W. I.-B. 1941. Foot-rot in sheep: A transmissible disease due to infection with *Fusiformis nodosus* (n. sp.). Bulletin 140. Council for Scientific and Industrial Research, Melbourne, Australia, pp. 1–40.
- DELETRAZ, C. 2002. Le piétin chez les ongulés sauvages: Étude clinique et épidémiologique chez le Bouquetin des Alpes. DVM Thesis, Ecole Nationale Vétérinaire de Lyon, Lyon, France, 87 pp.
- ECERTON, J. R. 2000. Foot-rot and other foot conditions. In *Diseases of sheep*, 3rd Edition,

- W. B. Martin and I. D. Aitken (eds.). Blackwell Scientific Publications, Oxford, UK, pp. 243–249.
- , D. S. ROBERTS, AND I. M. PARSONSON. 1969. The etiology and pathogenesis of ovine footrot. I. A histological study of the bacteria invasion. *Journal of Comparative Pathology* 79: 207–216.
- GHIMIRE, S. C., J. R. EGERTON, AND O. P. DHUNGYEL. 1999. Transmission of virulent footrot between sheep and goats. *Australian Veterinary Journal* 77: 450–453.
- GLAWISCHNIG, W., K. SCHÖPF, AND D. KHASCHABI. 1998. Zum Auftreten von Moderhinke in einer Tiroler Steinwildkolonie. In *Proceedings of the sixth Tagung der Deutschen Veterinär-Medizinischen Gesellschaft. Sektion Schaf- und Ziegenkrankheiten*, Giessen, Germany, pp. 151–153.
- GIACOMETTI, M., J. NICOLET, K. E. JOHANSSON, T. NAGLIC, M. P. DEGIORGIS, AND J. FREY. 1999. Detection and identification of *Mycoplasma conjunctivae* in infectious keratoconjunctivitis by PCR based on the 16S rRNA gene. *Journal of Veterinary Medicine, Series B* 46: 173–180.
- , M. JANOVSKY, H. JENNY, J. NICOLET, L. BELLOY, E. GOLDSCHMIDT-CLERMONT, AND J. FREY. 2002. *Mycoplasma conjunctivae* infection is not maintained in alpine chamois in eastern Switzerland. *Journal of Wildlife Diseases* 38: 297–304.
- HINDMARSH, F., AND J. FRASER. 1985. Serogroups of *Bacteroides nodosus* isolated from ovine footrot in Britain. *Veterinary Record* 116: 187–188.
- JANETT, F. 1993. Bekämpfung der Moderhinke auf Herdenbasis. DVM Thesis, University of Zurich, Zurich, Switzerland, 74 pp.
- JANOVSKY, M., J. FREY, J. NICOLET, L. BELLOY, E. GOLDSCHMIDT-CLERMONT, AND M. GIACOMETTI. 2001. *Mycoplasma conjunctivae* infection is self-maintained in the Swiss domestic sheep population. *Veterinary Microbiology* 83: 11–22.
- KUHNERT, P., S. E. CAPAUL, J. NICOLET, AND J. FREY. 1996. Phylogenetic positions of *Clostridium chauvoei* and *Clostridium septicum* based on 16S rRNA gene sequences. *International Journal of Systematic Bacteriology* 46: 1174–1176.
- , J. FREY, N. P. LANG, AND L. MAYFIELD. 2002. Phylogenetic analysis of *Prevotella nigrescens*, *Prevotella intermedia* and *Porphyromonas gingivalis* clinical strains reveals a clear species clustering. *International Journal of Systematic and Evolutionary Microbiology* 52 (Pt 4): 1391–1395.
- LA FONTAINE, S., J. R. EGERTON, AND J. I. ROOD. 1993. Detection of *Dichelobacter nodosus* using species-specific oligonucleotides as PCR primers. *Veterinary Microbiology* 35: 101–117.
- LANE, D. J. 1991. 16S/23S rRNA sequencing. In *Nucleic acid techniques in bacterial systematics*, E. Stackebrandt and M. Goodfellow (eds.). John Wiley & Sons, New York, New York, pp. 115–175.
- MOORE, L. J., G. J. WASSINK, L. E. GREEN, AND R. GROGONO-THOMAS. 2005. The detection and characterisation of *Dichelobacter nodosus* from cases of ovine footrot in England and Wales. *Veterinary Microbiology* 108: 57–67.
- NATTERMANN VON, H., R. BARWISCH, AND L. BRIEDERMANN. 1990. Die Bacteroides-nodosus-Infektion beim Mufflon (*Ovis ammon musimon*). *Monatshefte für Veterinär-Medizin* 45: 878–882.
- , ———, AND ———. 1993. Experimentelle Reproduktion bei Merinofleischschafen unter Verwendung von *Bacteroides-nodosus*-Isolaten vom Mufflon (*Ovis ammon musimon*). *Monatshefte für Veterinär-Medizin* 28: 651–655.
- SAMBROOK, J., AND RUSSELL, D. W. 2001. *Molecular cloning*. Cold Spring Harbor, New York.
- SKERMAN, T. M. 1975. Determination of some in vitro growth requirement of *Bacteroides nodosus*. *Journal of General Microbiology* 87: 107–119.
- STEWART, D. J. 1989. Footrot of sheep. In *Footrot and foot abscess of ruminants*, J. R. Egerton, W. K. Yong and G. G. Riffkin (eds.). CRC Press, Boca Raton, Florida, pp. 5–45.
- STEWART, D. J., J. E. PETERSON, J. A. VAUGHAN, B. L. CLARK, D. L. EMERY, J. B. CALDWELL, AND A. A. KORTT. 1986. Clinical and laboratory diagnosis of benign, intermediate and virulent strains of *Bacteroides nodosus*. In *Footrot in ruminants*, D. J. Stewart, J. E. Peterson, N. M. McKern and D. L. Emery (eds.). *Proceedings of the Workshop*, Melbourne, Victoria, Australia 1985. CSIRO Division of Animal Health and Australian Wool Corporation, Glebe, New South Wales, Australia, pp. 81–91.
- THORLEY, C. M. 1976. A simplified method for the isolation of *Bacteroides nodosus* from ovine footrot and studies on its colony morphology and serology. *Journal of Applied Bacteriology* 40: 301–309.
- WANI, S. A., AND I. SAMANTA. 2006. Current understanding of the aetiology and laboratory diagnosis of footrot. *The Veterinary Journal* 171: 421–428.

Received for publication 2 March 2006.