

Intestinal Acanthocephaladiosis in Olrog's Gulls (*Larus atlanticus*): *Profilicollis chasmagnathi* as Possible Cause of Death

Authors: La Sala, Luciano F., and Martorelli, Sergio R.

Source: Journal of Wildlife Diseases, 43(2) : 269-273

Published By: Wildlife Disease Association

URL: <https://doi.org/10.7589/0090-3558-43.2.269>

BioOne Complete (complete.BioOne.org) is a full-text database of 200 subscribed and open-access titles in the biological, ecological, and environmental sciences published by nonprofit societies, associations, museums, institutions, and presses.

Your use of this PDF, the BioOne Complete website, and all posted and associated content indicates your acceptance of BioOne's Terms of Use, available at www.bioone.org/terms-of-use.

Usage of BioOne Complete content is strictly limited to personal, educational, and non - commercial use. Commercial inquiries or rights and permissions requests should be directed to the individual publisher as copyright holder.

BioOne sees sustainable scholarly publishing as an inherently collaborative enterprise connecting authors, nonprofit publishers, academic institutions, research libraries, and research funders in the common goal of maximizing access to critical research.

Intestinal Acanthocephaladiosis in Olrog's Gulls (*Larus atlanticus*): *Profilicollis chasmagnathi* as Possible Cause of Death

Luciano F. La Sala^{1,2} and Sergio R. Martorelli¹ ¹ Centro de Estudios Parasitológicos y Vectores (CONICET–UNLP), Calle 2 Nro. 584 CEPAVE (1900) La Plata, Argentina; ² Corresponding author (email: luciano_la_sala@yahoo.com)

ABSTRACT: In 2003 and 2005, mortality events were observed among hatch-year Olrog's gulls (*Larus atlanticus*) in a breeding colony in the Bahía Blanca estuary, Argentina. Freshly dead chicks were collected for parasitologic and parasite-associated pathologic studies. *Profilicollis chasmagnathi* was found at various intensities in all of the birds examined ($n=28$). On gross and histopathologic examinations, severe lesions ranging from intestinal obstruction to complete perforation were present in small and large intestines of the birds. Larval forms of *P. chasmagnathi* were being found in prey items of *L. atlanticus* in the study area, which suggests that diet may play a central role in the epidemiology of disease and mortality events in this species.

Key words: Acanthocephalid, acanthocephaladiosis, intestine, *Larus atlanticus*, Olrog's gull, pathology, *Profilicollis chasmagnathi*, wild birds.

Olrog's gull (*Larus atlanticus*) is a vulnerable species endemic to the Atlantic coast of Argentina (BirdLife International, 2004). With a small range and population (ca. 5,000 breeding pairs), it occurs in tidal wetlands along the Atlantic coast from SE Uruguay to the Chubut province in Argentina (Yorio et al., 2005). Few breeding sites have been reported, and all known colonies occur in Argentina (Yorio et al., 2005). The Bahía Blanca estuary is considered the most important breeding site, harboring more than 80% of the breeding population in the largest colony known for the species (Isla del Puerto, 38°48'S, 62°15'W) (Delhey et al., 2001a).

Despite a paucity of studies regarding the impact of helminths on seabird populations, it is suggested the impact may be very high. Galaktionov and Bustnes (1996) and Persson (1974) proposed that the pathogenic effects of helminths on individual seabirds might be manifested at a population level

through a reduction in their populations. Many underlying processes, including food resource shortage, environmental contaminants, inclement weather, infectious diseases, sibling competition, and internal parasitism (Forrester et al., 1997; Daoust et al., 1998) may interact synergistically and lead to some degree of compromise, rendering a host more susceptible to the effects of parasitism. Among some of the possible outcomes of parasitism are starvation followed by mortality (Norman et al., 1992), impaired condition and emaciation (Work et al., 2004), lowered reproductive success (Hanssen et al., 2003), and costs from activation of immune responses (Møller et al., 2003). Therefore, it is often difficult to identify proximate and ultimate causes of parasite infections and to evaluate their true impact in wild bird populations.

Acanthocephalans, in particular, have long been implicated in recurrent mortality events in seabirds such as the common eider (*Somateria mollissima*; Camphuysen et al., 2002) and mute swan (*Cygnus olor*; Sanford, 1978). More recently, Hollmén et al. (1999) showed that eider ducklings experimentally infected with the acanthocephalan *Polymorphus minutus* grew more slowly and had lower concentrations of different serum proteins than control birds, and they concluded that the infection may have contributed to the low survival rates of *S. mollissima* ducklings.

Past mortality has not been reported for *L. atlanticus*, and almost no parasitologic data has been published in the scientific literature. This is the first report of *Profilicollis chasmagnathi* in Olrog's gulls. We also provide baseline parasitologic and pathologic findings from the first mortality

events reported for the species and put forward hypotheses about proximate cause of mortality and potential sources of infection in the study population.

On 8 December 2003 and 13 November 2005, mortality occurred among hatch-year Olog's gulls in the Isla del Puerto breeding colony. In 2003, more than 600 prefledged chick carcasses estimated as >20 days of age were counted in 1 day. In 2005, more than 1,000 dead or moribund prefledged young, estimated as 2–20 days of age, were observed after a 3-day heavy rainstorm (48.5 mm) accompanied by a moderate drop in temperature. In both years, only freshly dead birds ($n = 6$ in 2003; $n = 22$ in 2005) were systematically examined through standard necropsy examinations. In general, all birds were emaciated with severe atrophy of the pectoral muscles; absence of pericardial, subcutaneous, and coelomic fat stores; and a distended gall bladder. The entire gastrointestinal tract was fixed in 10% formalin for parasitologic and histopathologic examinations. In the laboratory, each tract was examined grossly for the presence of parasites and lesions. Parasites specimens were stored in 70% glycerinated ethanol and later diaphanized in lactophenol solution or mounted on polyvinyl alcohol-lactophenol medium for morphologic studies. According to morphologic and morphometric characteristics of the proboscis (Amin, 1992), parasites were identified as *P. chasmagnathi* (Holcman-Spector et al., 1977). Helminth voucher specimens have been deposited at the Museo de La Plata Helminth Collection, Argentina (accession no. 5641).

Because of the low recovery rate of fresh carcasses in 2003, our results concentrate mainly on findings made in the 2005 event. Prevalence of *P. chasmagnathi* infection was 100% in both years (2003: 95% confidence interval [CI] 0.55–1.00; 2005: 95% CI 0.82–1.00), and it was found in the jejunum, ileum, ceca, rectum, and coelomic cavity. Mean intensity of infection was 49 ($n=6$; range 15–73) and

65 ($n=22$; range 6–234) acanthocephalans per host in 2003 and 2005, respectively. In 2005, the highest intensities occurred in the jejunum (68% of the cases; $n=15$), followed by the ileum (27% of the cases; $n=6$). The distribution of parasites between jejunum and ileum was equal in one case. Twenty-two (100%) birds had *P. chasmagnathi* in the jejunum, 20 (91%) birds had *P. chasmagnathi* in the ileum, eight (36%) birds had *P. chasmagnathi* in the ceca, six (27%) birds had *P. chasmagnathi* in the coelomic cavity, and five (23%) birds had *P. chasmagnathi* in the rectum. Only unattached larval forms of *P. chasmagnathi* (range 1–3) were found in the proventriculus and ventriculus of three chicks. In 2005, the variance-to-mean ratio was 58.65, which shows that acanthocephalans are highly aggregated among prefledglings.

The heads of most *P. chasmagnathi* were often enlarged. They were embedded in the intestinal wall and were visible from the serosal side as raised, hardened nodules about 1.5–2 mm in diameter (Fig. 1A). Intestinal wall adhesions, constrictions, and thickening were common gross findings in sections with highest parasite burdens (Fig. 1A). Multiple intestinal wall perforations were found in all 28 birds (100%); parasite intestinal obstruction also was observed (Figs. 1B, 2). The heads of acanthocephalans that had perforated the intestinal wall were observed hanging in the coelomic cavity (Fig. 2). Some acanthocephalans had entered the peritoneal cavity and were either loose or attached to the mesentery or intestinal serosal surface. Host response to the free coelomic parasites was associated with grossly visible nodules, adhesions, and scarring at points of parasite attachment.

For histopathology, the fixed intestinal tissue and attached parasites were dehydrated in ethanol, embedded in paraffin, sectioned at 5 μ m, stained with hematoxylin and eosin, and examined microscopically. Full penetration (without perforation) of the parasite proboscis was

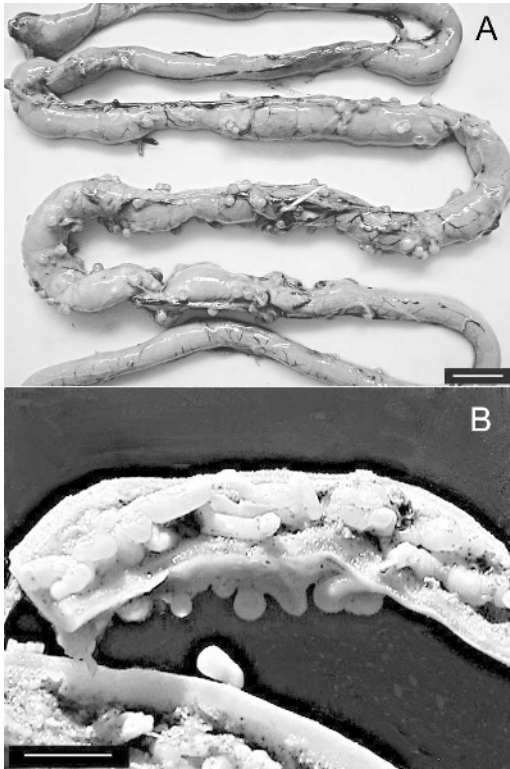


FIGURE 1. A. Small intestine of Olrog's gull chick with typical acanthocephalan lesions perforating the intestinal wall. Bar=10 mm. B. Intestinal obstruction caused by tightly packed acanthocephalans. Bar=8 mm.

associated with a thin cap of intact intestinal serosa as the only remaining barrier between the intestinal lumen, the transmural parasite, and the coelom. The

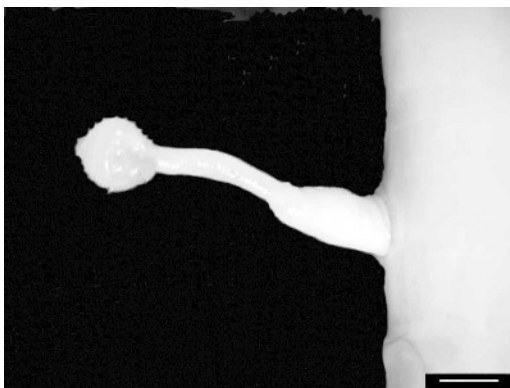

FIGURE 2. External view of small intestine perforated by a single acanthocephalan. Bar=800 μ m.

proboscis was often surrounded by mixed inflammatory infiltrates mainly represented by degenerate heterophils (Fig. 3A, B, C), which displaced outwardly adjacent host tissues (Fig. 3B).

Olrog's gull adults are feeding specialists during their breeding season. They prey mainly on the grapsid crabs *Chasmagnathus granulata* and *Cyrtograpsus angulatus* found in nearby intertidal areas (Delhey et al., 2001b), which they feed to their young. These crab species are intermediate hosts of larval forms (cystacanths) of *P. chasmagnathi* on the coast of Argentina (Martorelli, 1989), and they occur at very high densities in the Bahía Blanca estuary. In an ongoing related study, the prevalence of cystacanths of *P. chasmagnathi* was 25.5% in *C. angulatus* ($n=200$; 95% CI 25.1–25.9) and 8.9% in *Ch. granulata* ($n=113$; 95% CI 8.4–9.4). These findings, and the specialized food requirements of the adults during the chick-rearing period, support our hypothesis of an increased adult-to-chick parasite transmission through feeding.

Although this work concentrates on acanthocephalan infections, the chicks also were heavily parasitized with at least three other types of helminthes (Cestoda, Nematoda, and Digenea). Due to the observational nature of our study, the small sample size, and a lack of screening for other diseases and control for potential biases, we do not know whether mortality was due to the effects of *P. chasmagnathi* alone or to the cumulative effects of *P. chasmagnathi* with these other parasites or other underlying factors such as age, sex, nutritional plane, hatching asynchrony, sibling competition, crowding, unsuitable habitat, and environmental contaminants. Nonetheless, it seems that the inclement weather played an important role in the 2005 mortality event.

Considering the extent of the lesions observed, the high prevalence/intensities of infection, and the presence of cystacanths in the main prey items of *L. atlanticus*, we suggest that *P. chasmagnathi*

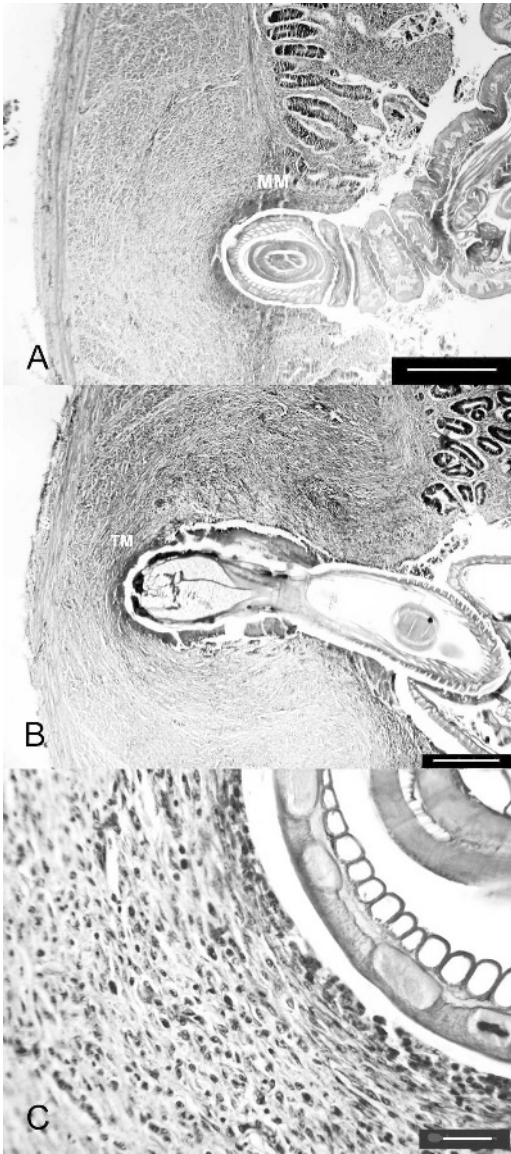


FIGURE 3. Photomicrographs of small intestine from an Olrog's gull; intestinal lumen on right of figure and coelomic cavity on left. H&E stain. A. *P. chasmagnathi* has penetrated the intestinal mucosa to the level of the muscularis mucosa (MM). Bar=300 μ m. B. *P. chasmagnathi* has penetrated to the external sheath of the tunica muscularis (TM). Outward displacement of the external sheath of the tunica muscularis and serosa (S) is apparent. Bar=300 μ m. C. Higher magnification microphotograph illustrating parasite penetration area surrounded by abundant multinucleate inflammatory cells. Bar=24 μ m.

and its intermediate hosts play a central role in the epizootiology of acanthocephalan infection, disease, and mortality of Olrog's gull chicks during their rearing period in the Bahía Blanca estuary.

We thank P. Petracci, J. Cereghetti, and C. Perez for invaluable field assistance and E. Topa for helping with histology procedures. We also thank volunteers G. Aguerre, C. Pamparana, and park ranger M. Zotello for unwavering support. This study was made possible by generous funding from the Wildlife Health Fund of the Field Veterinary Program (Wildlife Conservation Society).

LITERATURE CITED

- AMIN, M. O. 1992. Review of the genus *Polymorphus* Lühe, 1911 (Acanthocephala: Polymorphidae), with the synonymization of *Hexaglandula* Petrochenko, 1950, and *Subcorynosoma* Hoklova, 1967, and a key to the species. *Qatar University Science Journal* 12: 115–123.
- BIRDLIFE INTERNATIONAL. 2004. Threatened birds of the world 2004. BirdLife International, Cambridge, UK.
- CAMPHUYSEN, C. J., C. M. BERREVOETSC, H. J. W. M. CREMERSD, A. DEKINGA, R. DEKKER, B. J. ENS, T. M. VAN DER HAVE, R. K. H. KATS, T. KUIKEN, M. F. LEOPOLD, J. VAN DER MEER, AND T. PIERSMA. 2002. Mass mortality of common eiders (*Somateria mollissima*) in the Dutch Wadden Sea, winter 1999/2000: Starvation in a commercially exploited wetland of international importance. *Biological Conservation* 106: 303–317.
- DAOUST, P. Y., G. CONBOY, S. MCBURNEY, AND N. BURGESS. 1998. Interactive mortality factors in common loons from maritime Canada. *Journal of Wildlife Diseases* 34: 524–531.
- DELHEY, J. K. V., M. CARRETE, AND M. MARTÍNEZ. 2001a. Diet and feeding behaviour of Olrog's gull *Larus atlanticus* in Bahía Blanca, Argentina. *Ardea* 89: 319–329.
- , P. F. PETRACCI, AND C. GRASSINI. 2001b. Hallazgo de una nueva colonia de la Gaviota de Olrog en la ría de Bahía Blanca. *Hornero* 16: 39–42.
- FORRESTER, D. J., W. R. DAVIDSON, R. E. LANGE, R. K. STROUD, L. L. ALEXANDER, J. CH. FRANSON, S. D. HASELTINE, R. C. LITTELL, AND S. A. NESBITT. 1997. Winter mortality of common loons in Florida coastal waters. *Journal of Wildlife Diseases* 34: 833–847.
- GALAKTIONOV, K. V., AND J. O. BUSTNES. 1996. Diversity and prevalence of seabird parasites in

- intertidal zones of the European North coast. NINA-NIKU Project Report 4: 1–27.
- HANSSEN, S. A., I. FOLSTAD, K. E. ERIKSTAD, AND A. OKSANEN. 2003. Costs of parasites in common eiders: Effects of antiparasite treatment. *Oikos* 100: 105–111.
- HOLCMAN-SPECTOR, B., F. MAÑÉ-GARZÓN, AND E. DEI-CAS. 1977. Ciclo evolutivo y descripción de *Falsifilicollis chasmagnathi* (Acanthocephala). *Rev. Biol. Uruguay* 5: 78–91.
- HOLLMÉN, T., J. K. LEHTONEN, S. SANKARI, T. SOVERI, AND M. HARIO. 1999. An experimental study on the effects of polymorphiasis in common eider ducklings. *Journal of Wildlife Diseases* 35: 466–473.
- MARTORELLI, S. R. 1989. El rol de *Cyrtograpsus angulatus* (Crustacea: Brachiura) en los ciclos de vida de *Microphalus szidati* (Digenea: Microphallidae) y *Falsifilicollis chasmagnathi* (Acanthocephala, Fillicollidae). Algunos aspectos de su ecología parasitaria. *Memórias do Instituto Oswaldo Cruz* 84: 567–574.
- MØLLER, A. P., J. ERRITZØE, AND N. SAINO. 2003. Seasonal changes in immune response and parasite impact on hosts. *American Naturalist* 161: 657–671.
- NORMAN, F. I., P. B. GUESCLIN, AND P. DANN. 1992. The 1986 “wreck” of little penguins *Eudyptula minor* in western Victoria. *Emu* 91: 369–376.
- PERSSON, L. 1974. Endoparasitism causing heavy mortality in Eider ducks in Sweden. Xith International Congress of Game Biologists, National Swedish Environmental Protection Board, Stockholm, Sweden, pp. 255–256.
- SANFORD, S. E. 1978. Mortality in Mute Swans in southern Ontario associated with infestation with the thorny-headed worm, *Polymorphus boschadis*. *Canadian Veterinary Journal* 19: 234–236.
- WORK, T. M., C. U. METEYER, AND R. A. COLE. 2004. Mortality in Laysan Ducks (*Anas laysanensis*) by emaciation complicated by *Echinuria uncinata* on Laysan Island, Hawaii, 1993. *Journal of Wildlife Diseases* 40: 110–114.
- YORIO, P., M. BERTELOTTI, AND P. GARCIA BORBOROGLU. 2005. Estado poblacional y de conservación de gaviotas que se reproducen en el litoral marítimo Argentino. *Hornero* 20: 53–74.

Received for publication 26 January 2006.