

AN OUTBREAK OF TYPE C BOTULISM IN HERRING GULLS (LARUS ARGENTATUS) IN SOUTHEASTERN SWEDEN

Authors: Neimanis, A., Gavier-Widén, D., Leighton, F., Bollinger, T., Rocke, T., et al.

Source: Journal of Wildlife Diseases, 43(3) : 327-336

Published By: Wildlife Disease Association

URL: <https://doi.org/10.7589/0090-3558-43.3.327>

BioOne Complete (complete.BioOne.org) is a full-text database of 200 subscribed and open-access titles in the biological, ecological, and environmental sciences published by nonprofit societies, associations, museums, institutions, and presses.

Your use of this PDF, the BioOne Complete website, and all posted and associated content indicates your acceptance of BioOne's Terms of Use, available at www.bioone.org/terms-of-use.

Usage of BioOne Complete content is strictly limited to personal, educational, and non - commercial use. Commercial inquiries or rights and permissions requests should be directed to the individual publisher as copyright holder.

BioOne sees sustainable scholarly publishing as an inherently collaborative enterprise connecting authors, nonprofit publishers, academic institutions, research libraries, and research funders in the common goal of maximizing access to critical research.

AN OUTBREAK OF TYPE C BOTULISM IN HERRING GULLS (*LARUS ARGENTATUS*) IN SOUTHEASTERN SWEDEN

A. Neimanis,^{1,5} D. Gavier-Widén,² F. Leighton,^{1,3} T. Bollinger,^{1,3} T. Rocke,⁴ and T. Mörner²

¹ Canadian Cooperative Wildlife Health Centre, Department of Veterinary Pathology, Western College of Veterinary Medicine, 52 Campus Dr., University of Saskatchewan, Saskatoon, SK, Canada S7N 5B4

² Department of Wildlife, Fish and Environment, National Veterinary Institute, SE-751 89 Uppsala, Sweden

³ Department of Veterinary Pathology, Western College of Veterinary Medicine, 52 Campus Dr., University of Saskatchewan, Saskatoon, SK, Canada S7N 5B4

⁴ United States Geological Survey, National Wildlife Health Center, 6006 Schroeder Rd., Madison, Wisconsin 53711–6223, USA

⁵ Corresponding author (email: aleksija.neimanis@usask.ca)

ABSTRACT: From 2000 to 2004, over 10,000 seabirds, primarily Herring Gulls (*Larus argentatus*), died from an undetermined cause in the Blekinge archipelago in southeastern Sweden. In June 2004, 24 affected Herring Gulls were examined clinically, killed humanely, and 23 were examined by necropsy. Seven and 10 unaffected Herring Gulls collected from a local landfill site and from Iceland, respectively, served as controls. All affected birds showed similar neurologic signs, ranging from mild incoordination and weakness to severe flaccid paralysis of legs and wings, but generally were alert and responsive. All affected gulls were in normal nutritional condition, but were dehydrated and had empty stomachs. No gross or microscopic lesions, and no bacterial or viral pathogens were identified. Type C botulinum toxin was detected in the sera of 11 of 16 (69%) affected gulls by mouse inoculation. Type C botulism was the proximate cause of disease in 2004. Sera from 31% of birds tested from outbreaks in 2000 to 2003 also had detectable type C botulinum toxin by mouse inoculation. No large-scale botulism outbreak has been documented previously in this area. The source of toxin, initiating conditions, and thus, the ultimate cause of this outbreak are not known. This epidemic might signal environmental change in the Baltic Sea.

Key words: Avian, Baltic sea, bird, botulism, Herring Gull, *Larus argentatus*, paralysis, Sweden.

INTRODUCTION

In the summer of 2000, unusually large numbers of seabirds were found sick or dead in the Blekinge archipelago in the Baltic Sea off of the southeast coast of Sweden (Mörner et al., 2005) (Fig. 1). Mortality events recurred annually from 2001 to 2004 to varying degrees, and also occurred in other locations in the Baltic Sea and inland waters. Over 10,000 seabirds were affected during this period in Blekinge (Mörner et al., 2005). Sick birds displayed neurologic signs of weakness and paralysis. Although a number of different species were involved in the outbreaks, most of the affected birds were Herring Gulls (*Larus argentatus*) (Mörner et al., 2005).

Carcasses from 10 different species of affected birds were collected from 2000 to 2003 and examined at the Department of Wildlife, Fish and Environment, National

Veterinary Institute, Uppsala, Sweden, but no definitive cause of the outbreak was determined (Mörner et al., 2005). In 2004, a detailed, qualitative investigation that targeted live, clinically abnormal Herring Gulls was conducted. The objective was to determine the cause of morbidity and mortality in these gulls. Here we describe the clinical signs, pathologic findings, and diagnostic test results from these affected birds, and compare findings with local and off-site control samples. We also include a retrospective analysis of samples available from previous outbreaks.

MATERIALS AND METHODS

Study site

Clinically abnormal Herring Gulls were collected from the Blekinge archipelago, Sweden at locations ranging from 55°58'N, 14°26'E to 56°08'N, 15°15'E (Fig. 1). The archipelago consists of numerous, small rocky islands that are rarely more than 800 m across

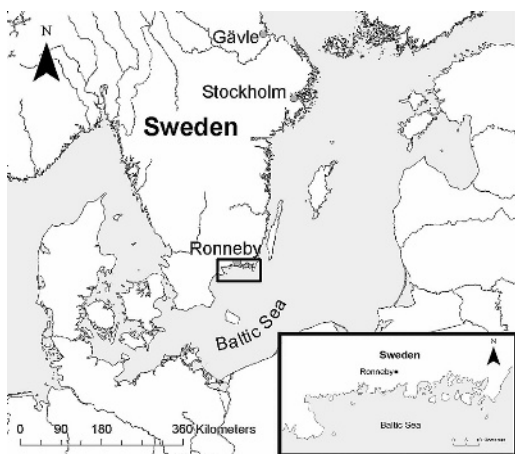


FIGURE 1. A map of southern Sweden depicting the Blekinge archipelago. Insert: Blekinge archipelago (Modified map projection from ArcMap version 9.1 in ArcGIS 9© 1999–2005, Environmental Systems Research Institute, Inc.)

in the largest dimension, and is located in the Baltic Sea where surface salinity averages 7‰ to 7.5‰ (Kullenberg, 1981). Most islands are covered in low-lying grasses and bushes, with occasional deciduous trees. Many of these islands are protected from human activity for nesting seabirds. Herring Gulls and other seabirds, including other gull species, ducks, geese, terns, and shorebirds breed in the archipelago every summer and many of these birds overwinter here (Mullarney et al., 1999).

Gull collections

A summary of specimens, sample sizes, examinations, and tests is presented in Table 1. Twenty-four clinically abnormal Herring Gulls were collected from the Blekinge archipelago from 7 to 16 June 2004. Gulls were collected from islands ($n=22$) or the adjacent mainland ($n=2$), and often more than one affected bird was collected from each island. Following observation (described below), birds were captured manually, placed in individual boxes, and transported to the mainland for euthanasia and necropsy. Birds were held in these boxes for up to 10 hr from the time of capture and were killed by decapitation. Blood was collected from the jugular vein following euthanasia.

Blood was collected from additional Herring Gulls euthanized from the Blekinge archipelago on 22 June ($n=4$), 5 July ($n=1$), and 6 July ($n=8$) 2004. Nine of these samples were collected within the coordinates provided above, and four were collected on islands east

of Ronneby to longitude E15°41'. Blood from a single affected Great Black-backed Gull (*Larus marinus*) was collected in the same manner on 6 July 2004 from an island within the study site.

For unaffected controls, seven Herring Gulls were shot at the Ronneby landfill site (56°11'N, 15°19'E), approximately 7 km from the eastern edge of the study area; blood was collected from five of these birds. Ten additional normal Herring Gulls were trapped as part of unrelated study in Iceland (64°4'N, 21°58'W) on 14 July 2004 using net traps. Live birds were transported by air to Sweden and were held in individual boxes for a maximum of 48 hr from the time of trapping to euthanasia. Birds were killed by cervical dislocation and blood was collected prior to euthanasia. Control birds were examined by necropsy and sampled in the same manner as birds collected from Blekinge.

Based on plumage (Mullarney et al., 1999), birds collected at Blekinge during 2004 consisted of 20 adults and four were 2–3-yr-old birds. The control birds collected at Ronneby Island consisted of five adults and two 2–3-yr-old birds; all 10 birds collected in Iceland were adults.

Clinical observations

Before capture, affected gulls were observed in situ, recorded on videotape, and examined clinically.

Clinical and anatomic pathology

Blood was collected into sterile tubes with and without EDTA anticoagulant (Becton-Dickinson Vacutainer Systems Europe, Plymouth, UK). Blood smears were made immediately with freshly drawn blood. Samples without anticoagulant were centrifuged and serum was frozen at -20°C . Hematology and biochemistry analyses were performed by the Division of Diagnostic Imaging and Clinical Pathology, Department of Biomedical Sciences and Veterinary Public Health, Faculty of Veterinary Medicine and Animal Science, Swedish University of Agricultural Sciences, Uppsala (Table 1).

Complete necropsies were performed on 23 of the 24 affected gulls and on all 17 control birds; tissues were collected in 10% neutral buffered formalin (Table 1). Formalin-fixed tissues from 20 affected birds and all control birds were processed routinely for histologic examination. Briefly, tissues were dehydrated in graded alcohol, cleared in xylene, and embedded in paraffin. Sections (5 μm) were stained using Mayer's hematoxylin and eosin

TABLE 1. A summary of specimen samples sizes for tests carried out on gulls in Sweden, 2000–04.

Source	Year	Sample	n	Behaviour observed	Hema- tology ^a	Biochem- istry ^b	Necropsy	Histology ^c	Bacterial culture	AIV and APMV-1 serology ^d	Virus isolation	Botulism: mouse inoculation	Botulism: ELISA
<i>Affected</i>													
Blekinge	2004	Bird	24	24	17	16	23	20	20	5	6	13 ^e	18
Blekinge	2004	Serum	14	–	–	–	–	–	–	–	–	3	14
Blekinge	2000–2003	Serum	41	–	–	–	–	–	–	–	–	16	31
Gävle	2002	Serum	1	–	–	–	–	–	–	–	–	1	0
<i>Control</i>													
Ronneby	2004	Bird	7	7	5	4	7	7	5	–	–	–	5
Iceland	2004	Bird	10	10	4	–	10	10	–	–	–	–	3

^a Included hemoglobin concentration, hematocrit, and total and differential leukocyte counts (automated hematology analyzer Cell-Dyn, Abbott Laboratories, Chicago, Illinois, USA, in the resistant-RBC-mode using VET 2.3 software).

^b Included urea, creatinine, calcium, magnesium, phosphorus, sodium, potassium, chloride, copper, zinc, iron, protein, and total bilirubin concentrations, and creatinine kinase, aspartate aminotransferase, alanine aminotransferase, alkaline phosphatase, gamma glutamyltransferase, and glutamate dehydrogenase activities (Konelab 30 autoanalyzer, Thermo Electron Oy, Vantaa, Finland, using the manufacturer's reagents).

^c Brain, spinal cord, peripheral nerves, skeletal muscle (pectoral, wing, and leg muscles), lung, heart, kidney, spleen, liver, adrenal gland, gonads, esophagus, proventriculus, ventriculus, duodenum, jejunum, ileum, cecum, colon, cloaca, pancreas, thyroid gland, trachea, bone marrow, and the bursa of Fabricius and thymus, when available.

^d AIV = Avian influenza virus; APMV-1 = Avian Paramyxovirus-1.

^e Eight samples were tested in Sweden, five were tested in Canada, and two samples were tested in both laboratories. All other mouse inoculation tests were performed in Canada.

(Luna, 1968). Additional sections were stained with Perl's method for iron and Bennhold's method for amyloid (Congo Red) to investigate observed histologic abnormalities (Luna, 1968). Investigation of parasitism was confined to gross and microscopic examination of tissues.

Bacteriology and virology

Fresh liver samples from 20 affected and five unaffected local control Herring Gulls were inoculated onto blood agar plates containing 5% horse blood and onto eosin methylene blue agar plates at the Wildlife Division, National Veterinary Institute, Uppsala, Sweden. Plates were incubated at 37°C in aerobic conditions and inspected after 24 hr and 48 hr for growth. Plates were held at ambient temperature (approximately 20°C) for five additional days and inspected for growth at the end of seven days.

Sera from five severely affected birds were tested for antibodies to avian influenza virus and avian paramyxovirus-1 (APMV-1) at the Virology Laboratory, National Veterinary Institute, Uppsala, Sweden, using agar gel immunodiffusion tests and blocking ELISA tests, respectively. For avian influenza, an H9N2 reagent supplied by an OIE reference Laboratory for Avian Influenza (Istituto Zooprofilattico Sperimentale Delle Venezie, Venice, Italy) was used as antigen and methods followed those of the OIE (2004). The blocking ELISA for APMV-1 was performed using commercially available test kits (SvanovirTM, Svanova Biotech AB, Uppsala, Sweden). Virus isolation was attempted from pooled tissues (spleen, liver, kidney, lung, and brain) from six moderately to severely affected gulls. Tissue homogenates were inoculated into embryonated chicken eggs and passaged three times at the Virology Laboratory.

Mouse inoculation

Sera from six affected birds and pooled sera from two additional affected birds were tested for botulinum toxins C and E at the Bacteriology Laboratory, National Veterinary Institute, Uppsala, Sweden in July 2004. Where possible, testing was performed on individuals that also were tested for viruses and bacteria. Young adult Swiss white mice weighing approximately 20 g were used. For each test, two mice were injected intraperitoneally (IP) with 0.5 ml of gull serum and observed for up to four days for signs of botulism (Wobeser, 1997a). Mice were immediately euthanized if signs of botulism developed. Sera that caused clinical signs in the mice, and for which there

was adequate volume, were diluted 1:5 and 1:10, and 0.5 ml of each concentration was injected IP into two additional mice. For mouse protection assays, two mice were injected IP with antitoxin to type C botulinum toxin (developed by the Bacteriology Laboratory, National Veterinary Institute, Uppsala, Sweden) and two mice were injected IP with antitoxin to type E botulinum toxin (BAB-TUSE, National Institute for Biological Standards and Controls, Hertfordshire, UK). Thirty minutes later, each mouse was injected IP with 0.5 ml of undiluted gull serum and observed for up to four days.

Sera from all remaining affected gulls that were examined from 2004, for which adequate serum volumes were available ($n=5$), were tested for type C botulinum toxin at the Western College of Veterinary Medicine (WCVN), University of Saskatchewan, Saskatoon, Saskatchewan, Canada. Sera from three additional affected birds collected from 22 June 2004 to 6 July 2004 (Table 1) and from two affected gulls which tested negative for toxin during tests in Sweden also were tested at WCVN. For each test, two young Swiss white mice (approximately 30 g) were used. One was injected IP with 0.1 ml antitoxin to type C botulinum toxin (developed by the National Wildlife Health Center, Madison, Wisconsin, USA). Thirty minutes later, both mice were injected IP with 1 ml of undiluted gull serum. Observations and test interpretation followed methods described above. In Sweden and Canada, mice that were found dead or that were euthanized after showing signs of botulism were examined by necropsy to rule out peritonitis or septicemia.

To determine if botulism contributed to the seabird mortality observed in previous years, 16 serum samples collected in previous outbreaks in Blekinge from 2000 to 2003 and one serum sample from an outbreak reported in Gävle, northern Sweden (60°36'N, 19°57'E) in 2002 were inoculated into mice at WCVN as described above. These sera were obtained from 15 Herring Gulls and two Great Black-backed Gulls (*Larus marinus*) with clinical signs identical to those of affected gulls in 2004.

Enzyme-linked immunosorbent assay (ELISA)

Seventy-one serum samples were tested for type C toxin by ELISA at the National Wildlife Health Center, Madison, Wisconsin. These included 31 affected Herring Gulls and one Great Black-backed Gull from 2004, five unaffected gulls from Blekinge and three unaffected Herring Gulls from Iceland from



FIGURE 2. A Herring Gull (*Larus argentatus*) from Blekinge, Sweden with clinical signs of botulism. The wings are dropped at the shoulder and have fallen away from the body. The bird is alert.

2004, and 27 affected Herring Gulls and four affected Great Black-backed Gulls from the Blekinge archipelago collected from 2000 to 2003 (Table 1). A capture ELISA method was followed as outlined in Rocke et al. (1998).

Data analysis

Hematology results for affected gulls, unaffected gulls from Sweden, and unaffected gulls from Iceland were compared with the Kruskal-Wallis test (Zar, 1984). Post-hoc comparison of means using Wilcoxon Rank Sum tests was performed for parameters that were significantly different (Zolman, 1993). Biochemical parameters for affected versus unaffected gulls also were compared using the Wilcoxon Rank Sum test. The proportion of gulls infected with each parasite species was compared between affected and unaffected gulls from Sweden using Fisher's exact test. Analyses were performed at an alpha level of 0.05 using Statistix 7 for Windows© 2000 (Analytical Software, Tallahassee, Florida, USA).

RESULTS

Clinical signs

Affected birds displayed a range of progressively developing neurologic signs, with limb paresis to complete paralysis being the most consistent finding. Initially, gulls showed delayed or uncoordinated flight compared to normal conspecifics when approached. Two such individuals were observed in the field, but escaped



FIGURE 3. A Herring Gull (*Larus argentatus*) from Blekinge, Sweden with clinical signs of botulism. The bird was unable to stand fully upright and stood and walked on its tarsometarsi.

capture. Mildly affected individuals were incapable of flight, but could stand and run and were mildly ataxic. Moderately affected birds were found in sternal recumbency with the wings dropped at the shoulder and fallen away from the body (Fig. 2). Intermittently, these birds stood and walked a few steps. Often, birds could not stand up completely and rested, and even walked, on their tarsometatarsi (Fig. 3). More severely affected gulls could not walk, and dragged themselves forward using their wings and beak. Moribund birds displayed open-mouthed, slow, labored breathing, occasional bobbing or ventroflexion of the head, and rarely, intermittent nystagmus. Their eyes often were partially closed, and rarely, the nictitating membranes were prolapsed or rapid constriction and dilation of the pupils was observed. With the exception of moribund individuals which were dull and poorly responsive, all birds were alert, responsive, aggressive, and had mobile heads. Wing and leg tone and beak strength decreased with increasing severity of clinical signs. Frequently, there was staining of the vent feathers with urates and bright green feces. None of the unaffected birds from the Blekinge landfill site and Iceland showed any of these clinical signs.

Clinical and anatomic pathology

Affected birds had significantly higher hemoglobin (158 ± 12.2 vs. 126.5 ± 11.5 g/l),

hematocrit (0.62 ± 0.04 vs. 0.43 ± 0.01), urea (6.43 ± 4.95 vs. 1.55 ± 0.34 mmol/l), sodium (160.06 ± 7.32 vs. 149.50 ± 4.12 mmol/l), and total bilirubin values (15.57 ± 34.63 vs. 3.43 ± 1.20 μ mol/l) than local control birds (mean \pm standard deviation; $P < 0.01$ for all comparisons). The affected gulls and the control birds from Iceland had significantly higher total leukocyte counts (9.79 ± 5.81 and $7.08 \pm 2.57 \times 10^9/l$, respectively) than did the local control birds ($2.13 \pm 1.96 \times 10^9/l$; $P = 0.04$). Mean values of all other hematologic and biochemical parameters for affected gulls were not significantly different from controls.

At post-mortem examination, affected gulls had dry, tacky subcutaneous tissues. The proventriculus and ventriculus were bile-stained and empty, the gall bladder was full, and the cloaca was distended with urates and feces. All affected and control birds were in fair to good nutritional condition based on the presence of moderate to abundant fat stores. Local control birds had full gastrointestinal tracts, but tracts in control birds from Iceland were empty. Occasional, incidental lesions were found in individual birds from all three groups (e.g., scattered granulomas, mild air sacculitis, and shot pellets).

Histologically, amyloid (Congo Red stain) was seen in vessel walls of the spleen and occasional other organs in 29% to 35% of birds from all three groups. Affected gulls often had abundant hemosiderin (Perl's stain) in Kupffer cells, and two affected birds had moderate, multifocal distension of renal tubules with urates and the tubular epithelium was attenuated. Five out of 10 (50%) control gulls from Iceland had mild to severe, subacute skeletal muscle necrosis in wing and leg muscles. Mild, acute skeletal myocyte degeneration in limb and pectoral muscles was seen in 3/20 (15%) of affected gulls and mild to moderate, subacute muscle necrosis in limbs was seen in 2/20 (10%) of affected gulls. With the exception of mild to moderate pathologic changes associated

with parasitism, no other significant lesions were seen in any of the tissues examined.

Numerous nematodes, trematodes, cestodes, and coccidia were seen in all groups of birds during microscopic examination, but for some parasites, the proportion of infected gulls appeared to differ between groups. Affected gulls more frequently had detectable schistosome infection by light microscopy (17/20 or 85%) than local unaffected gulls (3/7 or 43%; $P = 0.049$). No control birds from Iceland had detectable infection with schistosomes. Although there was a tendency for a higher proportion of unaffected local gulls to have esophageal *Capillaria* sp. in tissue sections than affected gulls (5/7 or 71% vs. 6/20 or 30%), this difference was not statistically significant ($P = 0.084$).

Bacteriology and virology

No pathogenic bacteria were cultured. No antibodies to avian influenza virus or APMV-1 were detected and no viruses were isolated from pooled tissue samples.

Botulism testing

Type C botulinum toxin was detected by mouse inoculation in 11 of 16 (69%) and 5 of 16 (31%) serum samples collected from clinically affected gulls in the Blekinge archipelago in 2004 and 2000–03, respectively. This included one of the Great Black-backed Gulls collected in 2001. The single sample tested from Gävle had no detectable toxin. Of the three positive serum samples for which a dilution series was performed, only the pooled sample produced signs typical for botulism in mice at a dilution of 1:5, none of the serum sample induced detectable signs in mice at a 1:10 dilution. One serum sample tested in both Sweden and Canada caused clinical signs in a mouse injected with 1.0 ml, but not in a mouse injected with 0.5 ml. None of the eight samples from 2004 tested in Sweden contained type E botulinum toxin. No evidence of septicemia or peritonitis was seen in mice that

died or were euthanized during botulism testing.

Nonspecific reactions were observed in 10 affected gulls and all five of the controls that were collected at Ronneby; these results probably resulted from bacterial contamination of serum and were considered inconclusive. Type C toxin was detected by ELISA in nine of 23 (39%) and six of 30 (20%) samples from affected birds collected in 2004 and from 2000–03, respectively. Sera from control birds from Iceland and from affected Great Black-backed Gulls tested negative for Type C toxin by ELISA.

DISCUSSION

The clinical signs, lack of consistent and significant morphologic lesions, negative bacteriologic and virologic test results, and positive results for botulism type C all support a diagnosis of avian botulism type C in Herring Gulls examined in 2004. Botulism occurs following the ingestion of various types of preformed botulinum toxin produced by the bacterium *Clostridium botulinum* (Quinn et al., 1999). These neurotoxins cause flaccid paralysis by interfering with acetylcholine release at the neuromuscular junction (Simpson, 1986). Birds are susceptible to intoxication by botulinum toxin type C and type E (Rosen, 1971). Botulism type C most often affects birds of the Order *Anseriformes*, but it also has been documented to cause morbidity and mortality in gulls, shorebirds, herons, cormorants, and possibly in fish (Jensen and Price, 1987; Rocke et al., 2004).

In this outbreak, other possible etiologies such as avian cholera, viral infections (avian influenza virus, avian paramyxovirus-1, West Nile virus and other viral encephalitides), and avian vacuolar myelinopathy were eliminated based on pathologic, bacterial, and viral assessments. West Nile virus, Usutu virus, or other related virus were not detected by polymerase chain reaction in samples from

birds collected from 2000 to 2003 (Mörner et al., 2005). Algal blooms were not reported during the 2004 study period, and tests of water in previous outbreaks did not detect toxic algae (Mörner et al., 2005). Trace mineral imbalances or heavy metal intoxication were not detected in carcasses collected from outbreaks in 2000 to 2003 (Mörner et al., 2005).

Clinical signs in affected Herring Gulls in this outbreak were consistent with those described in botulism outbreaks in Herring Gulls in Scotland (MacDonald and Standring, 1978) and Ireland (Quinn and Crinion, 1984). General flaccid paralysis is described for all affected avian species (Rosen, 1971). In gulls (this study) and other species (Borland et al., 1977), wing muscles appear to be affected first. Drooping wings were observed in all affected gulls examined in this investigation. In addition, affected gulls in this study frequently were observed standing and walking on their tarsometatarsi. Despite progressive flaccid paralysis, gulls remained alert and aggressive until they were moribund; this is also typical of type C botulism in gulls (MacDonald and Standring, 1978; Quinn and Crinion, 1984).

Pathologic findings were minimal and reflected debilitation, stress, and handling. Clinically affected gulls were dehydrated, as was evidenced by necropsy findings and blood parameters (Thrall et al., 2004). Paresis and paralysis likely precluded these animals from eating and drinking. The leukogram and vascular amyloidosis are nonspecific indicators of stress (Hoffman and Leighton, 1985). The higher total leukocyte counts in affected gulls and unaffected birds from Iceland are consistent with stress from intoxication and/or capture and transport. The subacute muscle necrosis of limbs in gulls from Iceland suggests capture myopathy during trapping and transport. Similarly, the acute muscle damage in limbs and pectoral muscles of a few affected gulls could be related to repeated attempts to ambulate,

prolonged sternal recumbency, capture, and transport.

In this study, type C botulinum toxin was detected by mouse inoculation in 69% of affected gull sera collected in 2004. This level of sensitivity of toxin detection is typical of other outbreaks of avian botulism. For example, Rocke et al. (1998) reported that mouse inoculation detected toxin in 79% of clinical avian botulism cases, and in a botulism outbreak in Ireland, toxin was detected in 64% of affected gulls (Quinn and Crinion, 1984).

Mouse inoculation currently is the most sensitive test available for the diagnosis of botulism, and is highly specific, but it is not sensitive to low levels of toxin (Thomas, 1991) that often are present in clinically affected birds (Wobeser, 1997a). Birds affected by botulism generally have less than 20 mouse lethal doses per ml of serum, and in many cases, they have none (Smith, 1987). Botulinum toxin binds irreversibly to receptors on the nerve at the neuromuscular junction (Rossetto and Montecucco, 2003). False negative results in mouse inoculations can occur if the majority of ingested toxin is bound at the neuromuscular junction, rather than circulating in blood (Swerczek, 1980).

As has been described in other cases (Smith, 1987), the concentration of toxin in the serum of birds sampled in this study was low. Only one sample for which a dilution series was performed had a high enough toxin concentration to induce clinical signs in mice at a dilution of 1:5 and no samples induced signs in mice at a 1:10 dilution. One serum sample caused clinical signs in a mouse injected with 1.0 ml of serum, but not in a mouse injected with 0.5 ml.

It is most likely that epidemics in 2000 to 2003 also were caused by type C botulism, because Type C botulinum toxin was detected in sera from some of these affected gulls and clinical signs in these birds were identical to those observed in 2004 (Mörner et al., 2005). The possible lower prevalence of detectable toxin in

samples from 2000 to 2003 might reflect loss of toxin activity during storage. Hubalek and Halouzka (1988) reported that only 6% of the toxicity of type C botulinum toxin persisted after 5 yr in storage at -20°C .

In this study, mouse inoculation was used sparingly out of ethical considerations, and testing efforts were augmented through ELISA testing. Type C toxin was detected by ELISA, but in a lower proportion of birds. Samples tested by ELISA experienced additional cycles of freezing and thawing, bacterial overgrowth, and prolonged storage. These factors are known to decrease sample quality (Hubalek and Halouzka, 1988; Mei et al., 2001), and in some cases, samples used for ELISA were of inadequate volume (Rocke et al., 1998). Mouse inoculations performed at the NWHC to confirm ELISA results detected toxin in an additional three birds from 2004 and two birds from 2000–03 (data not shown).

The birds examined in this investigation suffered from type C botulism. The ecology and ultimate cause of this outbreak, however, are not known. An outbreak of this magnitude over such a large geographic scale has not been documented in the Baltic Sea region and does not fit the most-studied scenario of type C botulism in which waterfowl are the primary species affected in outbreaks perpetuated by a carcass-maggot cycle. However, this outbreak does bear striking similarities to outbreaks described in Britain and Ireland in the 1970s and 1980s (Lloyd et al., 1976; Quinn and Crinion, 1984). In these outbreaks, numerous avian species along a large stretch of coastline were affected by botulism type C. In various locations in Scotland, Wales, England (Lloyd et al., 1976), and in Ireland (Quinn and Crinion, 1984), the vast majority of affected birds also were Herring Gulls. The source of the toxin in these outbreaks never was elucidated.

In the Swedish outbreak, gulls might have become intoxicated simply by scav-

enging toxin-laden carcasses. Increased numbers of vertebrate carcasses, for any reason, can increase the probability of a botulism outbreak, provided that carcasses contain *C. botulinum* spores at the time of death (Wobeser, 1997b). Alternately, invertebrate or vertebrate vectors could have facilitated toxin transfer to the gulls. Further investigation into the diet of Herring Gulls in the Blekinge archipelago is critical to the determination of the toxin source in this outbreak.

It is unclear what factors precipitated the large-scale epidemic in Blekinge in 2000 and in each subsequent year to 2004. The Baltic ecosystem has deteriorated over the past half-century (Jansson and Dahlberg, 1999). Large areas of anoxia dominate the sea bottom, species of fish populations have changed (Jansson and Dahlberg, 1999), and mean temperature and precipitation in southern Sweden recently have increased (Lindström and Alexandersson, 2004). If conditions in the Baltic Sea have favored increased proliferation of *C. botulinum*, seabirds might be coming into increasing contact with spores and/or toxin through the marine food web. Habitat partitioning could explain why gulls collected at a nearby landfill site in Blekinge were unaffected. Differences in environmentally acquired parasites such as schistosomes (Horak et al., 2002) provide further support for the differential use of environments by affected and unaffected birds.

The Baltic ecosystem historically has had low species diversity and is thus particularly sensitive to environmental disturbances (Jansson and Dahlberg, 1999). One of the consistent signs of stressed ecosystems is changing patterns of disease (Rapport and Whitford, 1999). Epidemic botulism in Herring Gulls and other seabirds could be a signal of a broader environmental perturbation in the Baltic. Investigation into the source of toxin and initiating conditions of these outbreaks is needed to explore the potential roles of environmental change and to identify possible intervention strategies.

ACKNOWLEDGMENTS

We are indebted to Le Carlsson, Ronneby, Sweden for his dedication, knowledge, and field support during the investigation of this outbreak. R. Mattsson and others in the Department of Wildlife, Fish and Environment, National Veterinary Institute, Uppsala, Sweden, provided technical and field support. S. Smith, National Wildlife Health Center, Madison, WI, USA tested sera for botulism type C using ELISA. C. Waldner, WCVN, Saskatoon, SK, Canada provided statistical advice. This manuscript was improved by comments from M. Cattet and A. Allen, WCVN, Saskatoon, SK, Canada. All work in Sweden was carried out under animal care and welfare permits held by T. Mörner and the Department of Wildlife, Fish and Environment, National Veterinary Institute, Uppsala, Sweden. Botulism testing in Canada was performed under an animal care permit issued to T. Bollinger. Financial support was provided by the Department of Wildlife, Fish and Environment, National Veterinary Institute, Uppsala, Sweden, the Western College of Veterinary Medicine Interprovincial Graduate Student Fund and the Canadian Co-operative Wildlife Health Centre.

LITERATURE CITED

- BORLAND, E. D., C. J. MORYSON, AND G. R. SMITH. 1977. Avian botulism and the high prevalence of *Clostridium botulinum* in the Norfolk Broads. *Veterinary Record* 100: 106–109.
- HOFFMAN, A. M., AND F. A. LEIGHTON. 1985. Hemograms and microscopic lesions of Herring Gulls during captivity. *Journal of the American Veterinary Medical Association* 187: 1125–1128.
- HORAK, P., L. KOLAROVA, AND C. M. ADEMA. 2002. Biology of the schistosome genus *Trichobilharzia*. *Advances in Parasitology* 52: 155–234.
- HUBALEK, Z., AND J. HALOUZKA. 1988. Thermal sensitivity of *Clostridium botulinum* type C toxin. *Epidemiology and Infection* 101: 321–325.
- JANSSON, B. O., AND K. DAHLBERG. 1999. The environmental status of the Baltic Sea in the 1940s, today, and in the future. *Ambio* 28: 312–317.
- JENSEN, W. I., AND J. I. PRICE. 1987. The global importance of type C botulism in wild birds. *In* Avian botulism. An international perspective, M. W. Eklund and V. R. Dowell, Jr. (eds.). Charles C Thomas Publisher, Springfield, Illinois, pp. 33–54.
- KULLENBERG, G. G. 1981. Physical oceanography. *In* The Baltic Sea, A. Voipio (ed.). Elsevier Scientific Publishing Company, New York, New York, pp. 135–181.
- LINDSTRÖM, G., AND H. ALEXANDERSSON. 2004. Recent

- mild and wet years in relation to long observation records and future climate change in Sweden. *Ambio* 33: 183–186.
- LLOYD, C. S., G. J. THOMAS, J. W. MACDONALD, E. D. BORLAND, K. T. STANDRING, AND J. L. SMART. 1976. Wild bird mortality caused by botulism in Britain, 1975. *Biological Conservation* 10: 119–129.
- LUNA, L. G. (ED.). 1968. Manual of histologic staining methods of the Armed Forces Institute of Pathology, 3rd edition. The Blakiston Division, McGraw-Hill Inc., Toronto, Ontario, Canada, pp. 258.
- MACDONALD, J. W., AND K. T. STANDRING. 1978. An outbreak of botulism in gulls on the Firth of Forth, Scotland. *Biological Conservation* 14: 149–155.
- MEI, J. V., J. R. ALEXANDER, B. W. ADAM, AND W. H. HANNON. 2001. Use of filter paper for the collection and analysis of human whole blood specimens. *Journal of Nutrition* 131: 1631S–1636S.
- MÖRNER, T., H. UHLHORN, E. ÅGREN, K. BERNODT, R. MATTSSON, C. BRÖJER, K. NILSSON, D. GAVIER-WIDÉN, D. S. JANSSON, D. A. CHRISTENSSON, L. PETERSSON, AND A. NEIMANIS. 2005. Onormalt hög dödlighet bland trutar och annan sjöfågel i Sverige (Mass mortality in waterfowl in Sweden). *Svensk Veterinärtidning* (Swedish Veterinary Journal) 8–9: 11–18.
- MULLARNEY, K., L. SVENSSON, D. ZETTERSTRÖM, AND P. J. GRANT. 1999. Fågelguiden. Europas och Medelhavsområdets fåglar i fält. Albert Bonniers Förlag, Stockholm, Sweden, pp. 400.
- OIE. 2004. *Manual of Diagnostic Tests and Vaccines for Terrestrial Animals 2004*. www.oie.int/eng/normes/mmanual/A_00037.htm. Accessed December 2005.
- QUINN, P. J., AND R. A. P. CRINION. 1984. A two year study of botulism in gulls in the vicinity of Dublin Bay. *Irish Veterinary Journal* 38: 214–219.
- , M. E. CARTER, B. K. MARKEY, AND G. R. CARTER. 1999. *Clinical Veterinary Microbiology*. Mosby, Toronto, Ontario, Canada, pp. 648.
- RAPPORT, D. J., AND W. G. WHITFORD. 1999. How ecosystems respond to stress. *Bioscience* 49: 193–203.
- ROCKE, T. E., S. R. SMITH, AND S. W. NASHOLD. 1998. Preliminary evaluation of a simple in vitro test for the diagnosis of type C botulism in wild birds. *Journal of Wildlife Diseases* 34: 744–751.
- , P. NOL, C. PELIZZA, AND K. K. STURM. 2004. Type C botulism in pelicans and other fish-eating birds at the Salton Sea. *Studies in Avian Biology* 27: 136–140.
- ROSEN, M. N. 1971. Botulism. In *Infectious and parasitic diseases of wild birds*, J. W. Davis, R. C. Anderson, L. Karstad, and D. O. Trainer (eds.). Iowa State University Press, Ames, Iowa, pp. 100–117.
- ROSSETTO, O., AND C. MONTECUCCO. 2003. How botulinum toxins work. In *Hand book of botulinum toxin treatment*, 2nd edition, P. Moore and M. Naumann (eds.). Blackwell Science Ltd., Malden, Massachusetts, pp. 9–27.
- SIMPSON, L. L. 1986. Molecular pharmacology of botulinum toxin and tetanus toxin. *Annual Review Pharmacology and Toxicology* 26: 427–453.
- SMITH, G. R. 1987. Botulism in water birds and its relation to comparative medicine. In *Avian botulism. An international perspective*, M. W. Eklund and V. R. Dowell Jr. (eds.). Charles C. Thomas Publisher, Springfield, Illinois, pp. 73–86.
- SWERCZEK, T. W. 1980. Toxicoinfectious botulism in foals and adult horses. *Journal of the American Veterinary Medical Association* 176: 217–220.
- THOMAS, R. J. 1991. Detection of *Clostridium botulinum* types C and D toxin by ELISA. *Australian Veterinary Journal* 68: 111–113.
- THRALL, M. A., D. C. BAKER, T. W. CAMPBELL, D. DENICOLA, M. J. FETTMAN, E. D. LASSEN, A. REBAR, AND G. WEISER. 2004. Clinical chemistry of birds. In *Veterinary hematology and clinical chemistry*. Lippincott Williams & Wilkins, Baltimore, Maryland, pp. 479–492.
- WOBESER, G. 1997a. Botulism. In *Diseases of wild waterfowl*. Plenum Press, New York, New York, pp. 149–161.
- . 1997b. Avian botulism—Another perspective. *Journal of Wildlife Diseases* 33: 181–186.
- ZAR, J. H. 1984. *Biostatistical analysis*, 2nd edition. Prentice-Hall, Englewood Cliffs, New Jersey, pp. 718.
- ZOLMAN, J. F. 1993. *Biostatistics. Experimental design and statistical inference*. Oxford University Press, New York, New York, 368 pp.

Received for publication 6 April 2006.