

Demodicosis in a Mule Deer (*Odocoileus hemionus hemionus*) from Saskatchewan, Canada

Authors: Gentes, Marie-Line, Proctor, Heather, and Wobeser, Gary

Source: Journal of Wildlife Diseases, 43(4) : 758-761

Published By: Wildlife Disease Association

URL: <https://doi.org/10.7589/0090-3558-43.4.758>

BioOne Complete (complete.BioOne.org) is a full-text database of 200 subscribed and open-access titles in the biological, ecological, and environmental sciences published by nonprofit societies, associations, museums, institutions, and presses.

Your use of this PDF, the BioOne Complete website, and all posted and associated content indicates your acceptance of BioOne's Terms of Use, available at www.bioone.org/terms-of-use.

Usage of BioOne Complete content is strictly limited to personal, educational, and non - commercial use. Commercial inquiries or rights and permissions requests should be directed to the individual publisher as copyright holder.

BioOne sees sustainable scholarly publishing as an inherently collaborative enterprise connecting authors, nonprofit publishers, academic institutions, research libraries, and research funders in the common goal of maximizing access to critical research.

Demodicosis in a Mule Deer (*Odocoileus hemionus hemionus*) from Saskatchewan, Canada

Marie-Line Gentes,¹ Heather Proctor,² and Gary Wobeser^{1,3} ¹Canadian Cooperative Wildlife Health Centre, Department of Veterinary Pathology, Western College of Veterinary Medicine, University of Saskatchewan, 52 Campus Drive, Saskatoon, Saskatchewan, S7N 5B4 Canada; ²Department of Biological Sciences, University of Alberta, CW 405 Biological Sciences Centre, Edmonton, Alberta, T6G 2E9 Canada; ³Corresponding author (email: gary.wobeser@usask.ca)

ABSTRACT: Infestation of deer with *Demodex* spp. mites has been described in white-tailed deer (*Odocoileus virginianus*) and in Columbian black-tailed deer (*Odocoileus hemionus columbianus*) in North America, as well as in four species of deer in Europe. We describe *Demodex* sp. infestation in an adult female mule deer (*Odocoileus hemionus hemionus*) with skin lesions found dead near Saskatoon, Saskatchewan, Canada. This is believed to be the first report of demodicosis in mule deer.

Key words: Alopecia, demodectic mange, *Demodex*, demodicosis, ectoparasites, mule deer, *Odocoileus hemionus hemionus*, ring-worm.

Mites of the genus *Demodex* (Acarina: Demodicidae) are commensal inhabitants of the hair follicles and sebaceous glands of humans and most species of domestic animals (Yager and Scott, 1993). Less is known about the occurrence of these ectoparasites in wildlife. There are anecdotal descriptions of *Demodex* spp. in cervids from Europe, including red deer (*Cervus elaphus*), sika deer (*Cervus nippon*), roe deer (*Capreolus capreolus*), and Sambar deer (*Rusa unicolor*) (reviewed by Bukva, 1987). In North America, demodectid mites were first documented in 1971 on a white-tailed deer (*Odocoileus virginianus*) from Oklahoma (Carpenter et al., 1972). Recently, demodectid mites were found on Columbian black-tailed deer (*Odocoileus hemionus columbianus*) during investigation of a hair-loss syndrome in this species, a condition associated with chewing louse (*Damalinia* spp.) infestation, and during which, animals suffer from extensive alopecia, become progressively weaker, and occasionally die (Bildfell et al., 2004). To the authors' knowledge, demodicosis has not been reported

previously in mule deer (*Odocoileus hemionus hemionus*).

On 21 March 2006, a female mule deer was submitted for necropsy to the Canadian Cooperative Wildlife Health Centre, Western College of Veterinary Medicine, University of Saskatchewan, Saskatoon, Saskatchewan, Canada. The animal had been found dead near a hay stack approximately 20 km northeast (52°14'N, 106°32'W) of Saskatoon. There was extensive bilateral alopecia of the periorbital region, lateral surfaces of the head, the flanks, hind limbs, and rump. In all of those areas, except the rump, the skin was dark grey, moist, and slightly lichenified. Sparse short hairs remained on the flanks. On the rump, the skin was dry and covered with flaky white scales. The deer was in poor nutritional condition with no subcutaneous or visceral fat. Based on tooth replacement and wear, the animal's age was estimated to be between 1.5 yr and 2 yr. No remarkable changes were seen in any tissues other than the skin. Because dermatomycosis (*Trichophyton verrucosum* infection) is relatively common in mule deer in Saskatchewan and causes similar skin lesions (Wobeser et al., 1983), samples of hair plucked from the margins of alopecic areas were prepared as wet mounts with lactophenol cotton blue stain (Lynch et al., 1969). No ectothrix or endothrix fungal spores were seen. Portions of normal and affected skin from five locations (periorbital region, lateral surfaces of the head, flanks, hind limbs, and rump; approximately a dozen 2 cm×3 cm sections in total) as well as sections of major organs were fixed in 10% neutral buffered formalin. Before any

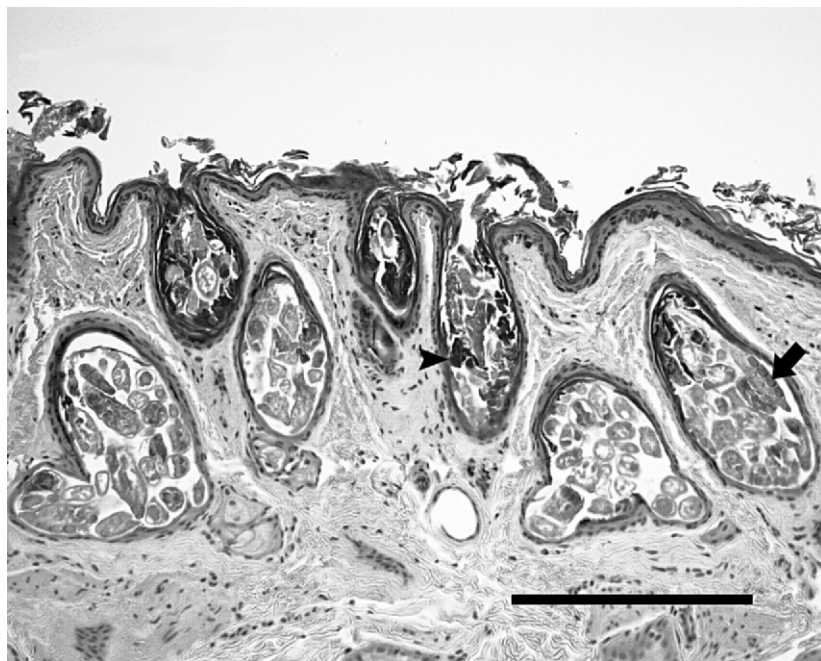


FIGURE 1. Histologic section of the skin of a mule deer infested with *Demodex* sp. Hair follicles and some sebaceous glands are dilated and filled with large numbers of mites. Mites are cigar-shaped (arrow), and follicles contain excess keratin (arrow head). No inflammation is associated with the presence of mites. Scale length: 250 μ m.

further diagnostic testing, portions of fixed obex, palatine tonsil, and retropharyngeal lymph node were decontaminated and processed for immunohistochemical detection of prion proteins of chronic wasting disease (CWD) (Prairie Diagnostic Services, 2005). When the animal was known to be test negative for CWD, other fixed tissues were embedded in paraffin, sectioned at 5 μ m, and stained with hematoxylin and eosin for histologic examination. Sections of brain, liver, spleen, lung, kidney, heart, and intestine, as well as sections of skin (total of 10 skin sections from five different sampling locations), were examined with a light microscope.

All affected areas of skin were similar microscopically. Hair follicles and some sebaceous glands were dilated and filled with large numbers of cigar-shaped mites (Fig. 1). Most follicles were devoid of hair shafts and usually contained excess keratin. No inflammation was associated with the presence of mites. No microscopic

lesions were identified in the visceral organs, other than atrophy of hepatocytes, which was consistent with the animal's emaciated state.

Mites were obtained from small portions of skin preserved in 10% buffered formalin. The tissue was washed in tap water, macerated overnight in a saturated solution of potassium hydroxide, agitated, and the fluid poured through an 80- μ m mesh sieve. Material retained on the sieve was washed, resuspended in 80% ethanol, and examined under a stereomicroscope at up to 100 \times . Mites were picked out using a flattened minuten pin and mounted in polyvinyl alcohol lacto-phenol (PVA; 6371A, BioQuip Products Inc., Gardena, California, USA). Slides were cured at 40 C for 3 days and examined using a Leica DMLB compound microscope with differential-interference contrast at 400 \times and 1,000 \times (oil-immersion).

The mites were readily identified as *Demodex* sp. (Fig. 2). Unfortunately, all

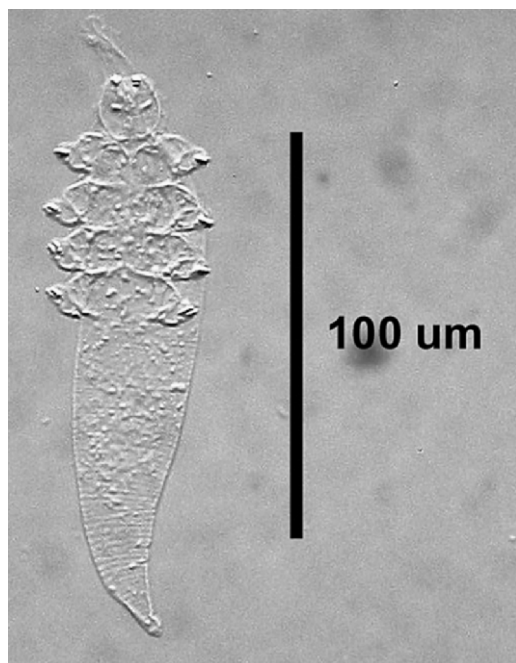


FIGURE 2. Ventral view of a *Demodex* sp. mite extracted from the skin of a mule deer.

mounted specimens ($n=6$) were nymphal and lacked species-specific characters. Although further attempts were made to recover adult mites from the macerated tissue, the sample had deteriorated, and no other mites could be detected. Additional skin samples were not available for examination. Therefore, we cannot at this time identify the mites beyond the genus *Demodex*. However, the overall appearance of the mites was similar to that of *Demodex odocoilei* from white-tailed deer in the United States (Desch and Nutting, 1974), and their size (140–150 μm in total length) was within the range of nymphal size for this species (130–168 μm). The nymphs examined were much smaller (140–150 μm in total length) than the nymphs of *Demodex kutzeri* (mean length >250 μm) found on red deer and sika deer from Europe, which were described by Bukva (1987). Body length of nymphs from another species of *Demodex* affecting red deer, *Demodex acutipēs*, were not available in the literature; however, the

morphology of the illustrated adults is very different from that of our nymphs, having a very short opisthosoma relative to the prosoma (Bukva and Preisler 1988).

Although this mule deer doe was infested with large numbers of *Demodex* spp. that colonized most hair follicles in areas of alopecia, there was no detectable inflammatory response in the affected skin. This finding is similar to that of Desch and Nutting (1974), who documented *Demodex* infestation without inflammation in white-tailed deer. Conversely, Carpenter et al. (1972) described associated folliculitis and dermatitis in white-tailed deer, and Kutzer and Grünberg (1972) reported grossly visible nodular dermatitis in a red deer. Bildfell et al. (2004) reported perifolliculitis in two heavily infested black-tailed deer but no reaction in two other individuals with lighter infestations.

Small numbers of *Demodex* mites are not usually detrimental to the host. However, when excessive proliferation of the parasite occurs, lesions of demodectic mange are produced (Jubb et al., 1993). In cattle and dogs, generalized demodicosis is occasionally seen. If secondary pyoderma and furunculosis are present and the condition is left untreated, lesions can progress into a potentially life-threatening disease. It is generally believed that factors such as poor nutrition, immunosuppression, concomitant disease, or heredity are needed for demodicosis to become generalized (Gross et al., 2005). Lesions of generalized demodectic mange, such as generalized folliculitis, furunculosis, lymphadenopathy, and secondary pyoderma, were not present in this doe. It appeared that the animal died because of severe emaciation. An additional energy requirement for thermoregulation, because of heat loss associated with the extensive alopecia, may have impaired the animal's ability to survive the cold temperatures of winter and spring. Because the prevalence and intensity of infestation with demodecid mites in wild deer are

largely unknown, it would be useful to systematically examine skin samples from cervids that are submitted for postmortem examination, especially if they have some degree of alopecia.

LITERATURE CITED

- BILDFELL, R. J., J. W. MERTINS, J. A. MORTENSON, AND D. F. COTTAM. 2004. Hair-loss syndrome in black-tailed deer of the Pacific Northwest. *Journal of Wildlife Diseases* 40: 670–681.
- BUKVA, V. 1987. *Demodex kutzeri* sp. n. (Acari: Demodicidae), an identical parasite of two species of deer, *Cervus elaphus* and *C. nippon pseudaxis*. *Folia Parasitologica (Praha)* 34: 173–181.
- , AND J. PREISLER. 1988. Observations on the morphology of the hair follicle mites (Acari: Demodicidae) from *Cervus elaphus* L., 1758 including description of *Demodex acutipes* sp. n. *Folia Parasitol (Praha)* 35: 67–75.
- CARPENTER, J. W., J. C. FREENY, AND C. S. PATTON. 1972. Occurrence of *Demodex* Owen 1843 on a white-tailed deer from Oklahoma. *Journal of Wildlife Diseases* 8: 112–114.
- DESCH, C. E., AND W. B. NUTTING. 1974. *Demodex odocoilei* sp. nov. from the white-tailed deer, *Odocoileus virginianus*. *Canadian Journal of Zoology* 52: 785–789.
- GROSS, T. L., P. J. IHRKE, E. J. WALDER, AND V. K. AFFOLTER. 2005. *Skin diseases of the dog and cat: Clinical and histopathologic diagnosis*. Blackwell Science Ltd, Oxford, UK, 932 pp.
- KUTZER, E., AND W. GRÜNBERG. 1972. Demodikose beim Rothirsch (*Cervus elaphus*). *Zeitschrift für Parasitenkunde* 40: 9–17.
- LYNCH, M. J., S. S. RAPHAEL, L. D. MELLOR, P. D. SPARE, AND M. J. H. INWOOD. 1969. *Medical laboratory technology and clinical pathology*, 2nd Edition. W. B. Saunders Co., Philadelphia, Pennsylvania, 1359 pp.
- PRAIRIE DIAGNOSTIC SERVICES. 2005. Standard operating procedures immuno 101. Immunohistochemical detection of prion proteins in chronic wasting disease of deer and elk using the Ventana automated immunostainer. Prairies Diagnostic Services, Saskatoon, Saskatchewan, Canada.
- WOBESER, G., S. A. MITCHAM, J. R. SAUNDERS, AND H. M. HUNT. 1983. Dermatomycosis (ringworm) in mule deer (*Odocoileus hemionus*). *Canadian Veterinary Journal* 24: 316–317.
- YAGER, J. A., AND D. W. SCOTT. 1993. The Skin and Appendages. In *Pathology of domestic animals*, K. V. F. Jubb, P. C. Kennedy and N. Palmer (eds.). Academic Press Inc, San Diego, California, pp. 686–690.

Received for publication 18 August 2006.