

Cephalopagus Conjoined Twins in a Leopard Cat (Prionailurus bengalensis)

Authors: Kompanje, Erwin J. O., and Hermans, John J.

Source: Journal of Wildlife Diseases, 44(1) : 177-180

Published By: Wildlife Disease Association

URL: <https://doi.org/10.7589/0090-3558-44.1.177>

BioOne Complete (complete.BioOne.org) is a full-text database of 200 subscribed and open-access titles in the biological, ecological, and environmental sciences published by nonprofit societies, associations, museums, institutions, and presses.

Your use of this PDF, the BioOne Complete website, and all posted and associated content indicates your acceptance of BioOne's Terms of Use, available at www.bioone.org/terms-of-use.

Usage of BioOne Complete content is strictly limited to personal, educational, and non - commercial use. Commercial inquiries or rights and permissions requests should be directed to the individual publisher as copyright holder.

BioOne sees sustainable scholarly publishing as an inherently collaborative enterprise connecting authors, nonprofit publishers, academic institutions, research libraries, and research funders in the common goal of maximizing access to critical research.

Cephalopagus Conjoined Twins in a Leopard Cat (*Prionailurus bengalensis*)

Erwin J. O. Kompanje,^{1,2,3} and John J. Hermans² ¹ Natural History Museum Rotterdam, PO Box 23452, 3001 KL Rotterdam, The Netherlands; ² Erasmus MC University Medical Center Rotterdam, Department of Radiology, PO Box 2040, 3000 CA Rotterdam, The Netherlands; ³ Corresponding author (email: e.j.o.kompanje@erasmusmc.nl)

ABSTRACT: Case reports of conjoined twins (“Siamese twins”) in wild mammals are scarce. Most published reports of conjoined twins in mammals concern cases in man and domestic mammals. This article describes a case of cephalopagus conjoined twins in a leopard cat (*Prionailurus bengalensis*) collected on the island of Sumatra, Indonesia, in the period 1873–76. A review of known cases of conjoined twinning in wild mammals is given.

Key words: Cephalopagus, conjoined twins, leopard cat, *Prionailurus bengalensis*.

Conjoined twins (“Siamese twins”) are well known in man, in domestic and laboratory mammals, domestic and wild birds, and in wild and captive-bred reptiles, amphibians, and fishes, but are very rarely described in wild mammals. The precise incidence is unknown, most likely due to high prenatal and antenatal mortality. Almost all known cases of conjoined twins in wild mammals concern unborn embryos and fetuses found during dissection of the pregnant dead females. The aim of this article is to describe and illustrate an additional case of conjoined twins in a wild mammal species.

Female conjoined twin fetuses of a leopard cat (*Prionailurus bengalensis*) (Fig. 1) were collected at Atjeh on the island of Sumatra, Indonesia (0°00'N, 102°00'E) in the period 1873–1876. The specimen was preserved in 70% alcohol and sent to the National Museum of Natural History, Leiden, the Netherlands where it was stored in the collection (collection number RMNH 1485). In 1998, it was donated to the Natural History Museum Rotterdam (collection number 9990-00002574). Nothing is known about the circumstances under which the specimen, documented

as cephalopagus conjoined twins, was collected.

In summer 2003, a CT scan of the skeleton (Fig. 2) was made that showed a fused skull, two complete vertebral columns, and other skeletal parts. The skull looked normal, but the two foramen magnum pointed to fusion of two skulls.

Conjoined twins always are conjoined in one of eight sites (Spencer, 2000a, 2000b, 2003) and are named after the site of union: Thoracopagus (united ventrally at the chest); Omphalopagus (united ventrally at the abdomen); Cephalopagus (united ventrally at head and chest); Ischiopagus (united ventrally at the pelvis); Parapagus (united laterally [dicephalus; one body, two heads or diprosopus; one body, two faces]); Craniopagus (united at the heads); Pygopagus (united caudally); and Rachipagus (united dorsally at the spine). Spencer (2000a, 2000b, 2003) provides convincing evidence that symmetrical conjoined twins are the result of secondary fusion of two originally separate monovular embryonic discs, and are not the result of incomplete fission producing a partially separated zygote. The etiology of conjoined twins remains enigmatic.

In the classic symmetric case of cephalopagus, the large conjoined head has two identical faces (also named Janus or Janiceps, after the two-faced Roman god, or Octopus, for the eight limbs) looking out over the two pair of shoulders. Cephalopagus conjoined twins are fused ventrally from the upper top of the head down to the umbilicus, thus sharing head, neck, thorax, thoracic organs, and upper abdomen. Vertebral columns, lower abdo-

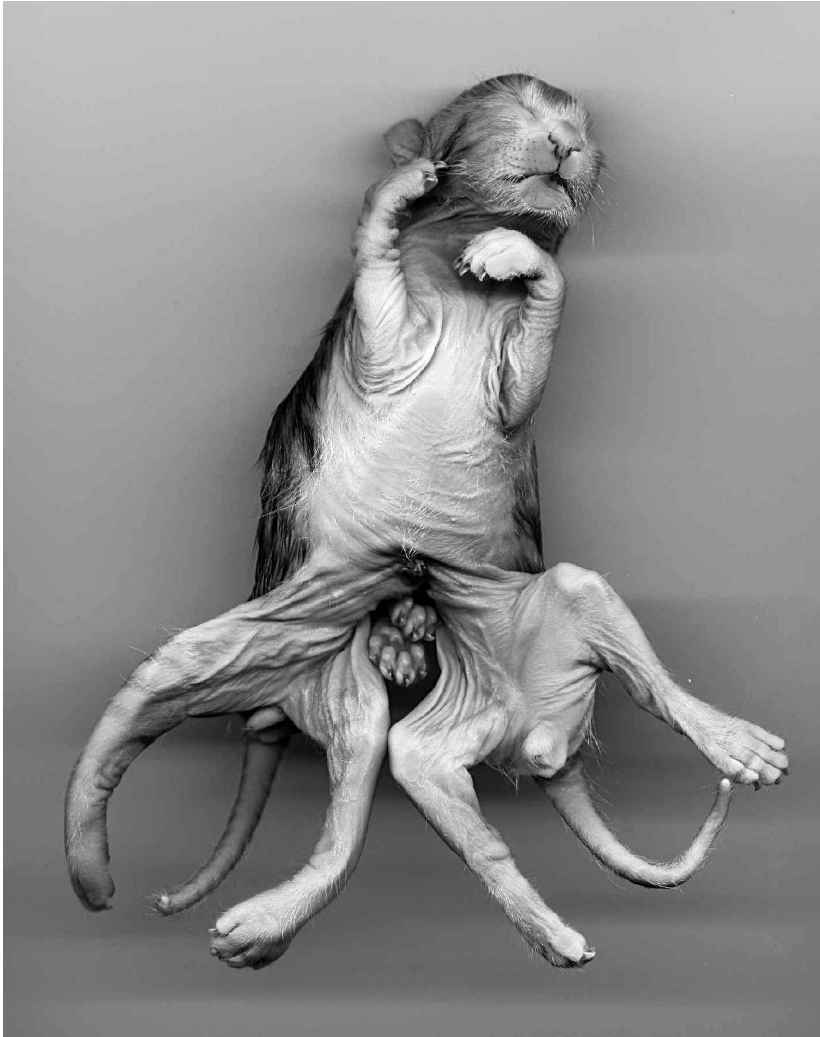


FIGURE 1. *Prionailurus bengalensis*, cephalopagus conjoined twins (NMR 9990-00002574).

men, genitalia, and all the limbs are usually separate.

The variable degree of laterality in fusion at the rostral aspect of the embryonic disc in a cephalopagus results in a graded series of cases (Spencer, 2003). These variations are: 1) symmetric ventral union, resulting in two complete faces (the classic cephalopagus); 2) moderate asymmetry of union, with diminished posterior face and brain, variable mouth, eyes, nose, and ears present; 3) severe asymmetry with complete absence of the posterior face (as is the described leopard cat); 4) extreme asymmetry, resulting in anen-

cephaly of the conjoined brain, either with one face or two laterally united faces on the same side, but with ventral union of the body down to the umbilicus; 5) maximal asymmetry, resulting in prosopothoracopagus with separate brains, but with ventral union of the trunks (Spencer, 2003).

These leopard cat conjoined twins had severe asymmetry in union, with complete absence of one face. In moderate asymmetric cephalopagus, otic remains are common, but in these leopard cat conjoined twins no trace of this was visible. The twins had, as usual in cephalopagus,

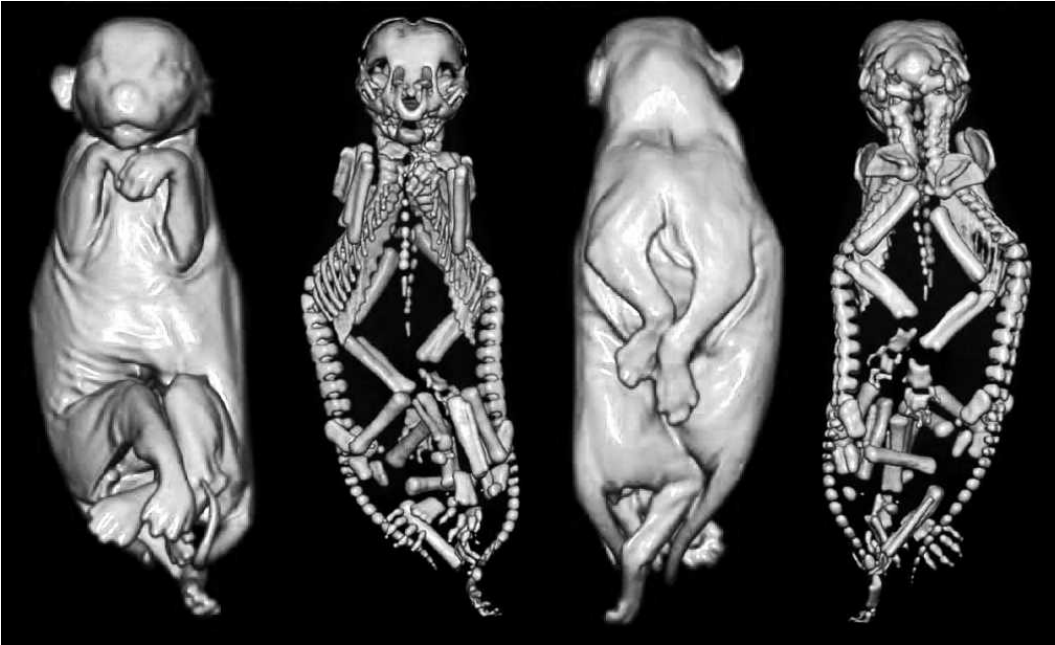


FIGURE 2. *Prionailurus bengalensis* cephalopagus conjoined twins (NMR 9990-00002574). Images from CT scanning. Posterior and anterior view.

two entirely separate vertebral columns up to the two foramen magnums in the fused skulls. The conjoined thorax had two shared sternums, each of the twins contributing a set of ribs on each side of each

sternum. All eight limbs were normally developed.

Cephalopagus conjoined twins probably result from fusion of the oropharyngeal membranes at the most rostral aspect of

TABLE 1. Published cases of conjoined twins in wild mammals.

Reference	Species	Taxonomy	Age
Reisel, 1671	<i>Lepus europaeus</i>	Cephalopagus	Newborn
Jung, 1671	<i>Lepus europaeus</i>	Cephalopagus	Newborn
Seger, 1671	<i>Lepus europaeus</i>	Cephalopagus	Newborn
Mentzel, 1686	<i>Alces alces</i>	Cephalopagus	Fetus
Winslow, 1734	<i>Cervus elephas</i>	Parapagus diprosopus	Newborn
Neugebauer, 1851	<i>Lepus europaeus</i>	Cephalopagus	Newborn
Benesch, 1957	<i>Lepus europaeus</i>	Cephalopagus	Newborn
Fay, 1960	<i>Odocoileus virginianus borealis</i>	Parapagus dicephalus	Fetus
Daniel and Kershaw, 1964	<i>Cervus elephas</i>	Parapagus dicephalus	Fetus
Kawamura, 1969	<i>Balaenoptera borealis</i>	Thoracopagus	Fetus
Kawamura and Kashita, 1971	<i>Stenella coeruleoalba</i>	Cephalopagus	Fetus
Kamiya et al., 1981	<i>Stenella coeruleoalba</i>	Parapagus dicephalus	Fetus
Zinchenko and Ivashin, 1987	<i>Balaenoptera acutorostrata</i>	Thoracopagus	Fetus
Faust, 1999	<i>Lepus europaeus</i>	Cephalopagus	Newborn
Kompanje, 2001, 2005b	<i>Tursiops truncatus</i>	Parapagus dicephalus	Newborn
Faust, 2001	<i>Cervus elephas</i>	Parapagus dicephalus	Fetus
Cesarini et al., 2002, 2004	<i>Tursiops truncatus</i>	Parapagus diprosopus	Newborn
Kompanje, 2005a	<i>Rattus rattus</i>	Omphalopagus parasiticus	Adult
Kompanje, 2005a	<i>Erinaceus europaeus</i>	Pygopagus parasiticus	Subadult

two early embryonic discs that share a single yolk sac. The primordial of heart and septum transversum are adjacent to the edges of these discs, resulting in involvement of union also.

Conjoined twins in wild terrestrial mammals have been very rarely reported. We could find only 19 cases in the scientific literature between 1671 and 2006 (Table 1). Spontaneous occurrence of conjoined twins in laboratory animals is uncommon; Szabo (1989) reported one rat conjoined twin on 10,000 and one rabbit conjoined twin in 4,000 offspring during 20 years.

LITERATURE CITED

- BENESCH, F. 1957. Lehrbuch der tierärztlichen Geburtshilfe und gynäkologie. Urban und Schwarzenberg, München, 813 pp.
- CESARINI, C., I. CLÉMENCEAU, M. A. BUTTAFOCO, F. DHEMAIN, O. VAN CANNEYT, W. DABIN, V. RIDOUX, AND T. JAUNIAUX. 2002. Exceptional record of a double-headed monster of bottlenose dolphin (*Tursiops truncatus*) in the Mediterranean Sea. In European Cetacean Society, 16th annual Conference, April 7–11, conference guide and abstracts, pp. 55–56.
- , F. DHEMAIN, T. JAUNIAUX, O. VAN CANNEYT, AND V. RIDOUX. 2004. Double faced monster in the bottlenosed dolphin (*Tursiops truncatus*) found in the Mediterranean Sea. Veterinary Record 154: 306–308.
- DANIEL, M. J., AND M. KERSHAW. 1964. Recent congenital anomalies in red deer in New Zealand. Journal of Mammalogy 45: 480–483.
- FAUST, I. 1999. Zoologische Einblattdrücke und Flugschriften vor 1800. Band II: Vögel, Säugetiere. Stuttgart, Hiersemann, Germany.
- . 2001. Zoologische Einblattdrücke und Flugschriften vor 1800. Band III: Paarhufer. Stuttgart, Hiersemann, Germany.
- FAY, L. D. 1960. A two-headed white-tailed deer fetus. Journal of Mammalogy 41: 411–412.
- JUNG, G. S. 1671. Monstrum leporinum: Miscellanea curiosa sive ephemeridum medico-physicarum germanicarum naturae curiosorum. Annus Secundus: 301–302.
- KAMIYA, T., N. MIYAZAKI, AND S. SHIRAGA. 1981. First case of dicephaly in Odontoceti. Scientific Reports Whales Research Institute 33: 127–129.
- KAWAMURA, A., AND K. KASHITA. 1971. A rare double monster of dolphin *Stenella caeruleoalba*. Scientific Reports Whales Research Institute 23: 139–140.
- KAWAMURA, S. 1969. Siamese twins in the sei whale *Balaenoptera borealis* Lesson. Nature 221: 490–491.
- KOMPANJE, E. J. O. 2001. Review of strandings and catches of *Tursiops truncatus* (Mammalia: Cetacea, Odontoceti) in the Netherlands between 1754 and 2000. Deinsea 8: 169–224.
- . 2005a. Two cases of asymmetrical conjoined twins in wild mammals from the Netherlands. Deinsea 11: 139–145.
- . 2005b. A case of symmetrical conjoined twins in a bottlenose dolphin *Tursiops truncatus* (Mammalia, Cetacea). Deinsea 11: 147–150.
- MENTZEL, C. 1686. Alces monstroso partu & gratitudine in hominis: Miscellanea curiosa sive ephemeridum medico-physicarum germanicarum naturae curiosorum. Decuriae II. Annus Quintus: 6–8.
- NEUGEBAUER, L. 1851. Duplicität des grössten Theils des Körpers beobachtet bei einem jungen Hasen (*Lepus timidus*). Nova-acta Leopoldino 24: 17–48.
- REISEL, S. 1671. Lepus monstrosus: Miscellanea curiosa sive ephemeridum medico-physicarum germanicarum naturae curiosorum. Annus Secundus: 301.
- SEGER, G. 1671. Vitulus biceps: Miscellanea curiosa sive ephemeridum medico-physicarum germanicarum naturae curiosorum. Annus Secundus: 168.
- SPENCER, R. 2000a. Theoretical and analytical embryology of conjoined twins: Part I: Embryogenesis. Clinical Anatomy 13: 36–53.
- . 2000b. Theoretical and analytical embryology of conjoined twins: Part II: Adjustments to union. Clinical Anatomy 13: 97–120.
- . 2003. Conjoined twins: Developmental malformations and clinical implications. John Hopkins University Press, Baltimore, Maryland, 476 pp.
- SZABO, K. T. 1989. Congenital malformations in laboratory and farm animals. Academic Press, San Diego, California, 313 pp.
- WINSLOW, M. 1734. Remarques sur les monstres: Seconde partie: Examen anatomique du faon à deux têtes, envoyé par ordre du roi, don't l'extérieur a été décrit dans la première partie de mes remarques sur les monstres. Suite de Memoires de Mathematique et de Physique, Tires des Registres de l'Academie Royale des Sciences. Pierre Mortier, Amsterdam: 624–644.
- ZINCHENKO, V. L., AND M. V. IVASHIN. 1987. Siamese twins of minke whales of the southern hemisphere. Scientific Reports of Whales Research Institute 38: 165–169.

Received for publication 13 April 2007.