

DISTRIBUTION OF MYCOBACTERIUM AVIUM SUBSPECIES PARATUBERCULOSIS IN THE LOWER FLORIDA KEYS

Authors: Pedersen, Kerri, Manning, Elizabeth J. B., and Corn, Joseph L.

Source: Journal of Wildlife Diseases, 44(3) : 578-584

Published By: Wildlife Disease Association

URL: <https://doi.org/10.7589/0090-3558-44.3.578>

BioOne Complete (complete.BioOne.org) is a full-text database of 200 subscribed and open-access titles in the biological, ecological, and environmental sciences published by nonprofit societies, associations, museums, institutions, and presses.

Your use of this PDF, the BioOne Complete website, and all posted and associated content indicates your acceptance of BioOne's Terms of Use, available at www.bioone.org/terms-of-use.

Usage of BioOne Complete content is strictly limited to personal, educational, and non - commercial use. Commercial inquiries or rights and permissions requests should be directed to the individual publisher as copyright holder.

BioOne sees sustainable scholarly publishing as an inherently collaborative enterprise connecting authors, nonprofit publishers, academic institutions, research libraries, and research funders in the common goal of maximizing access to critical research.

DISTRIBUTION OF *MYCOBACTERIUM AVIUM* SUBSPECIES *PARATUBERCULOSIS* IN THE LOWER FLORIDA KEYS

Kerri Pedersen,^{1,3,4} Elizabeth J. B. Manning,² and Joseph L. Corn¹

¹ Southeastern Cooperative Wildlife Disease Study, Department of Population Health, College of Veterinary Medicine, University of Georgia, Athens, Georgia 30602, USA

² John's Information Center, School of Veterinary Medicine, University of Wisconsin, Madison, Wisconsin 53706, USA

³ Current address: United States Department of Agriculture, Animal and Plant Health Inspection Service, Wildlife Services, Wildlife Disease and Emergency Response Program, 4101 LaPorte Ave., Fort Collins, Colorado 80521, USA

⁴ Corresponding author (email: kerri.pedersen@aphis.usda.gov)

ABSTRACT: Johne's disease, a fatal and contagious gastrointestinal infection caused by *Mycobacterium avium* subsp. *paratuberculosis* (*Map*), was first diagnosed in an endangered Florida Key deer (*Odocoileus virginianus clavium*) in 1996 and later in six additional Key deer deaths from 1998 to 2004. We investigated the geographic distribution of *Map* in the Lower Florida Keys from February 2005 through May 2006 via collection of blood and fecal pellets from 51 live-captured deer, collection of 550 fecal samples from the ground, and by necropsies of 90 carcasses. Tissue and fecal samples also were submitted from 30 raccoons (*Procyon lotor*), three feral cats (*Felis catus*), an opossum (*Didelphis virginiana*), and a Lower Keys marsh rabbit (*Sylvilagus palustris hefneri*). *Mycobacterium avium* subsp. *paratuberculosis* was identified in 23 Key deer fecal samples collected from the ground, tissue samples from two clinically ill Key deer, and from the mesenteric lymph node of a raccoon. The results of this study indicate that *Map* persists in the Key deer population and environment at a low prevalence, but its distribution currently is limited to a relatively small geographic area within the range of Key deer.

Key words: Florida Keys, Johne's disease, Key deer, *Mycobacterium avium* subsp. *paratuberculosis*, *Odocoileus virginianus clavium*, paratuberculosis, *Procyon lotor*, raccoon.

INTRODUCTION

Mycobacterium avium subsp. *paratuberculosis* (*Map*) is a hardy and slow-growing microorganism that causes Johne's disease, a significant economic and health problem for domestic ruminants. Signs of this eventually fatal disease occur many months after infection and include emaciation and diarrhea in some species (Williams, 2001). Infection also has been documented in a wide range of wildlife species, including white-tailed deer (*Odocoileus virginianus*; Chiodini and Van Kruiningen, 1983), tule elk (*Cervus elaphus nannodes*; Jessup et al., 1981), big horn sheep (*Ovis canadensis*; Williams, 1983), wild rabbits (*Oryctolagus cuniculus*; Greig et al., 1999), fox (*Vulpes vulpes*), stoat (*Mustela erminea*; Beard et al., 2001), Key deer (*Odocoileus virginianus clavium*; Quist et al., 2002), raccoons (*Procyon lotor*), opossum (*Didelphis virginiana*), armadillos (*Dasypus novemcinctus*; Corn et al., 2005), and feral cats (*Felis catus*; Palmer et al., 2005).

Johne's disease was first identified in an endangered free-ranging Florida Key deer in 1996 at a private residence on Big Pine Key; a second case was confirmed 2 yr later at the same location (Quist et al., 2002). Based on a subsequent survey of repository serum and fecal samples and live capture, the prevalence of *Map* infection was thought to be low in the Key deer population. However, from 2003 to 2004 five additional deer were diagnosed with Johne's disease at the same residence and neighboring islands. These reports plus new findings in Johne's disease research indicating that nonruminant wildlife are also susceptible to infection on heavily contaminated premises (Beard et al., 2001; Corn et al., 2005) raised the possibility that the infection prevalence had increased or was more extensive than previously thought. Additional concerns included illegal feeding of Key deer and the National Key Deer Refuge policy for translocation of deer to keys previously within the historic range of this species. The purpose of this survey

was to determine the geographic distribution of *Map* in the Key deer population.

MATERIALS AND METHODS

Study area

The Florida Keys are a series of islands that extend from the southern tip of the Florida peninsula. Key deer occupy several islands along this chain known as the Lower Keys from Little Pine Key to Sugarloaf Key (Hardin et al., 1984). However, approximately 75% of the population is limited to Big Pine and No Name Keys (24°44'N, 81°20'W) where fresh water is available (Lopez, 2001).

Capture methods

Key deer were live-trapped at various locations on Big Pine Key. Locations were selected based on the propensity of Key deer to congregate in the area and the feasibility of setting up a net. A drop net was used to capture the deer according to methods described by Lopez et al. (1998). Once caught in the net, deer were physically restrained while blood and fecal samples were collected. Sex, age, location, and global positioning system coordinates were recorded, and each animal was either marked with tattoo ink or tattooed before release to prevent repeat sampling.

Collection of samples

Samples were collected intermittently from February 2005 through May 2006. Key deer killed by vehicles or other causes were stored in a freezer by National Key Deer Refuge personnel before each survey period, and they were then necropsied as time permitted during the sampling period. Deer killed during the sampling period were necropsied within a few hours of discovery. Fecal pellets and tissue samples including liver, ileum, and mesenteric lymph node were collected from each deer depending on the condition of the animal when found. Blood was collected from freshly killed deer by cardiac puncture; serum was obtained within a few hours of collection and stored in a freezer at -18 C until shipped. Tissue and fecal samples were placed in individual whirl-paks (Fischer Scientific, Suwanee, Georgia, USA). Additional sections of each of the tissues were fixed in 10% buffered formalin, and they were stored for histopathologic evaluation of tissues testing positive for *Map*. Fecal pellets were collected from the ground at various locations on Big Pine, No Name, Howe, Water, Little Pine, Cudjoe, and Big Torch Keys, and on Munson Island, Little

Palm Island, and an unnamed offshore island. Fecal pellets were collected opportunistically in areas where Key deer were known to congregate or where they were observed frequently. The same location was not sampled more than once per week. Only fecal pellets that were fresh as determined by the collector were submitted. Samples were refrigerated for less than or equal to 72 hr and shipped on ice packs to the Johne's Information Center at the University of Wisconsin (Madison, Wisconsin, USA).

During June and July, raccoons and feral cats were captured on Munson Island and the southern end of Big Pine Key using Tomahawk live-traps. Animals were immobilized with Telazol[®] (Fort Dodge, Overland Park, Kansas), and then they were euthanized by intracardiac injection of sodium pentobarbital. Necropsies were conducted immediately, and fecal and tissue samples including liver, ileum, and mesenteric lymph node were collected from each animal.

Laboratory methods

Culture, isolate identification, and serology were conducted by the Johne's Information Center (Madison, Wisconsin, USA). Isolation of mycobacteria was performed using the radiometric method of detection (Collins et al., 1990). Briefly, 3 g of fecal material was processed with a decontamination solution overnight. Then, 10 ml of the supernatant was filtered, and the filter was placed in BACTEC incubation bottles (Bectin Dickerson, Sparks, Maryland) and monitored weekly for ¹⁴C release. Aliquots were taken for acid-fast staining from samples signaling positive. Acid-fast organisms isolated from the samples were identified as *Map* by an IS900 DNA probe and mycobactin-dependent growth patterns. Sera were tested for antibody to *Map* by a version of an enzyme-linked immunosorbent assay using a protein G antibody conjugate (IDEXX, Portland, Maine, USA; Tryland et al., 2004). Histopathology was conducted at the Southeastern Cooperative Wildlife Disease Study (Athens, Georgia, USA). Tissues from culture-positive animals were embedded in paraffin, and they were sectioned at 3 to 4 µm. Individual sections were stained with hematoxylin and eosin for routine examination and with Ziehl-Neelsen acid-fast stain to search for acid-fast bacteria.

RESULTS

Mycobacterium avium subsp. *paratuberculosis* was isolated from 24 Key deer

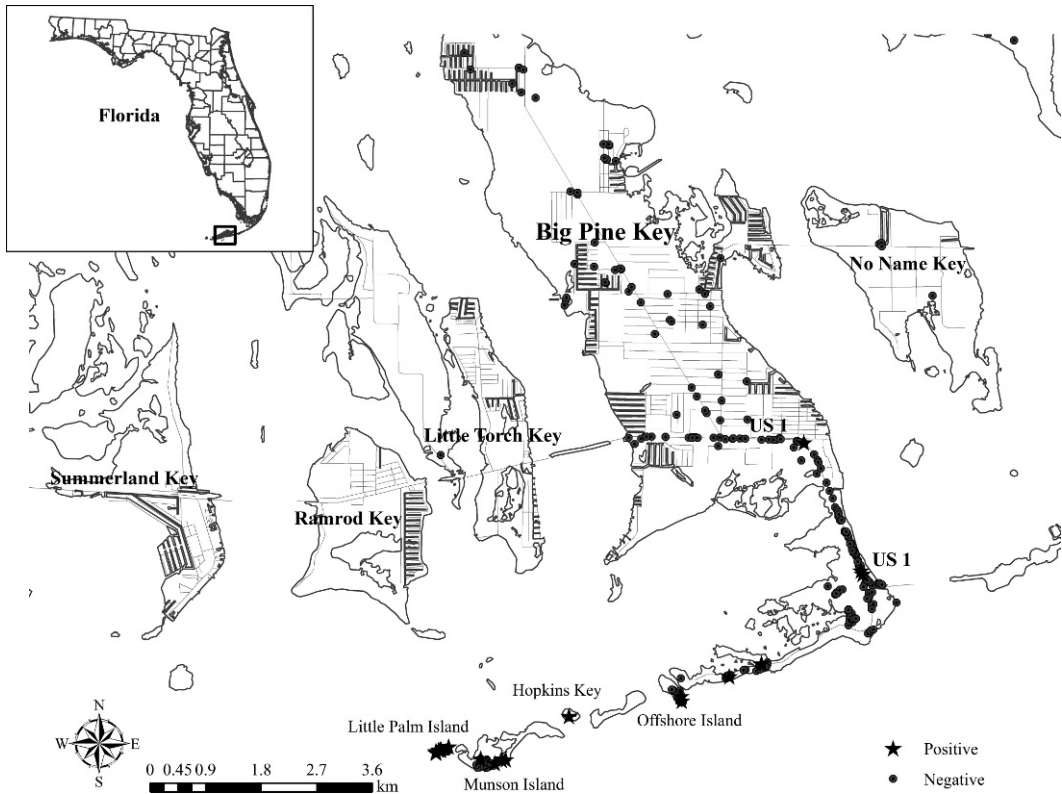


FIGURE 1. Sites where samples have been collected and submitted for *Mycobacterium avium* subsp. *paratuberculosis* testing since 1996. Points do not reflect relative number of samples.

fecal samples submitted for culture. The 24 culture-positive fecal samples represent (4%) of the 669 collected: 536 were taken from the ground, 84 from carcasses, and 49 from live-captured deer. Twenty-three of the culture-positive fecal samples were collected from the ground: seven of 73 (10%) on Munson Island, 11 of 90 (12%) on Little Palm Island, two of 33 (6%) on an offshore island, and three of 304 (1%) on Big Pine Key (Fig 1). Two of the positive samples on Big Pine Key were collected on the south side of highway US 1, and one sample was from a private residence on Long Beach Road (Fig 1). The only other positive fecal isolate was obtained from a fecal sample collected directly from a clinically ill deer. Samples collected from the other nine keys were negative for *Map*.

In total, 262 Key deer tissue samples

collected from 90 deer were submitted for culture and histopathology. *Mycobacterium avium* subsp. *paratuberculosis* was isolated from the feces, ileum, mesenteric lymph node, and liver of an adult female Key deer found on Little Palm Island; this animal was also antibody positive, weak, and emaciated. Lesions including severe granulomatous inflammation with intracellular acid-fast organisms were consistent with Johne's disease. In addition, an emaciated and weak adult female Key deer was found on Little Palm Island in May 2006. Tissue culture and histopathology of the ileocecal and mesenteric lymph nodes plus the ileum confirmed infection with *Map*.

Two of 97 serum samples tested positive for antibodies to *Map*. One sample was collected from a deer found dead on Little Palm Island; corresponding fecal and

TABLE 1. Samples submitted for Johne's disease testing by location and species.

Location	Species	No. of <i>Mycobacterium avium</i> subsp. <i>paratuberculosis</i> -positive isolates by sample type		
		Feces	Tissue	Serum
Big Pine Key	Key deer	3/424	0/226	1/91
	Marsh rabbit	0/1	0/3	
	Raccoon	0/27	0/78	
	Feral cat	0/3	0/9	
	Opossum	0/1	0/3	
No Name Key	Key deer	0/15	0/3	0/2
Munson Island	Key deer	7/75	0/9	0/1
	Raccoon	0/5	1/12	
Little Palm Island	Key deer	12/91	6/9	1/2
	Raccoon	0/1		
Howe Key	Key deer	0/12		
Cudjoe Key	Key deer	0/3	0/3	
Sugarloaf Key	Key deer	0/1	0/3	
Ramrod Key	Key deer	0/1	0/3	
Middle Torch	Key deer	0/1	0/3	0/1
Water Key	Marsh rabbit	0/3		
Offshore Island	Key deer	2/33		
Little Pine Key	Key deer	0/12		
	Raccoon	0/6		
Big Torch Key	Silver rice rat	0/2		
	Key deer	0/1	0/3	
Total		12/718	7/367	2/97

tissue samples tested positive. The other sample was from an adult buck found dead on Big Pine Key but corresponding fecal and tissue samples all tested negative.

Tissue and fecal samples were submitted from 30 raccoons, 3 feral cats, an opossum and a Lower Keys marsh rabbit that had been killed by a vehicle (Table 1). All tissues were culture negative except the mesenteric lymph node of one raccoon captured on Munson Island. No other tissues from this animal were culture positive and histopathology revealed mild inflammation but no acid-fast bacteria typically observed with *Map* infection. Fecal pellets from three rabbits, two silver rice rats (*Oryzomys argentatus*), and nine raccoons were collected from the ground but also tested negative (Table 1).

DISCUSSION

Recovery of *Map* from multiple samples confirms the presence and persistence of

the microorganism in the Lower Florida Keys. Based on the location of the culture-positive samples, the geographic distribution of *Map* in the Keys currently seems to be limited to Big Pine Key, Munson, and Little Palm Islands. All previous cases of Johne's disease reported since 1996 also occurred in this area (Quist et al., 2002). We did not discover evidence of Johne's disease in deer sampled north of US 1, but two fecal samples collected from the ground along US 1 were culture positive. Because the actual number of deer represented by the fecal samples collected in this survey is unknown, no infection prevalence can be calculated based on these data. It is also impossible to determine the number of deer represented by the positive fecal samples, but it is likely that multiple deer were infected because the positive samples were collected on multiple islands (Fig 1).

Key deer comprise most if not all of the ruminants present in the Lower Keys. Although we do not know how or when

Map was introduced into the Key deer population, it seems that *Map* is being maintained in this population. Furthermore, during collection of fecal pellets on Little Palm Island, a Key deer was observed swimming from Little Palm to another island, suggesting that the potential for spread of the infection on a larger scale exists and that it may not remain limited to the area south of US 1. Supplemental feeding, as occurs on Big Pine Key, Munson, and Little Palm islands, encourages congregation of Key deer, which increases animal density, environmental contamination, and the likelihood of transmission of various infectious diseases (Williams, 2001; Nettles et al., 2002). High population density and poor habitat quality as exist in the southern part of Big Pine Key (Harveson et al., 2004) increase the probability of exposure and subsequent infection with *Map*. The urbanization of the Key deer as described by Folk and Klimstra (1991) encourages free-ranging deer to congregate, which may perpetuate *Map* in the environment.

Based on the limited number of samples tested, evidence of infection in nonruminant species was scant; a single isolate from the mesenteric lymph node of a raccoon captured on Munson Island was culture positive. Isolation of *Map* in the tissue indicated that the raccoon had been infected, but neither lesions nor evidence of shedding at the time of capture was found. The raccoon may have become infected through exposure to the contaminated environment (75 [9%] Key deer fecal samples collected on Munson Island [41 ha] were *Map* positive) or by scavenging an infected deer.

The contribution, if any, of nonruminant wildlife to inter- or intraspecies dissemination of *Map* is not yet understood. Previous studies have reported infection in raccoons (Corn et al., 2005) as well as other nonruminant species that inhabit dairy farms with infected livestock, including feral cats (Palmer et al.,

2005), rabbits (Raizman et al., 2005), birds (Corn et al., 2005), and coyotes (Anderson et al., 2007). Many of these studies describe clinically and histopathologically normal animals from which the isolation of *Map* from tissue seems to have been an incidental finding. It is possible that some nonruminant species are not affected by *Map* infection or that these animals may have been tested during the early stages of infection before lesion development. In Scotland, *Map* seems to be established in rabbits due to high *Map* excretion rate and the grazing habits of rabbits along with horizontal, vertical and pseudovectorial transmission (Judge et al., 2006). A more recent study detected an unusually high infection rate (81 animals; 38%) in raccoons and other scavenging animals in Wisconsin (Anderson et al., 2007); this rate was based on the results of three different *Map* polymerase chain reaction assays.

Key deer mortality caused by *Map* infection is relatively low in comparison to vehicle-related mortality (2002–2004; 72%). However, due to the endangered status of the Key deer and the unknown factors affecting the perpetuation and dispersal of the microorganism in the Lower Florida Keys, it is imperative to minimize the risk of infection. Actions that may reduce risk include 1) increased education of tourists and residents about the consequences of supplemental feeding (Lopez et al., 2003), 2) increased enforcement of laws prohibiting illegal feeding of deer (Miller et al., 2003), and 3) continued monitoring of the Key deer population to determine whether the disease continues to be maintained and whether dissemination to areas north of US 1 occurs. Further studies on the role of environmental contamination in the maintenance and transmission of *Map* and studies on the effects of cessation of supplemental feeding of Key deer on dispersal are recommended.

ACKNOWLEDGMENTS

We give special thanks to I. D. Parker and D. E. Watts for helping to capture and sample all live-trapped deer. Thanks are also due to National Key Deer staff for assistance with field studies, the Johne's Information Center personnel for thorough and careful diagnostic testing of the samples, and to M. K. Keel of SCWDS for histopathology. Funding for this project was provided through Challenge Cost-Share Agreement 401815G084 between the US Fish and Wildlife Service and the University of Georgia Research Foundation, Inc. Additional funds were provided through sponsorship from the fish and wildlife agencies of Alabama, Arkansas, Florida, Georgia, Kansas, Kentucky, Louisiana, Maryland, Mississippi, Missouri, North Carolina, Puerto Rico, South Carolina, Tennessee, Virginia, and West Virginia; through the Federal Aid to Wildlife Restoration Act (50 Stat. 917) and Grant Agreement 06ERAG0005, Biological Resources Division, US Geological Survey, US Department of the Interior; and through Cooperative Agreements 0596130032CA and 0696130032CA, Veterinary Services, Animal and Plant Health Inspection Service, US Department of Agriculture.

LITERATURE CITED

- ANDERSON, J. L., J. K. MEECE, J. J. KOZICZKOWSKI, D. L. CLARK, JR., R. P. RADCLIFF, C. A. NOLDEN, M. D. SAMUEL, AND J. L. E. ELLINGSON. 2007. *Mycobacterium avium* subsp. *paratuberculosis* in scavenging mammals in Wisconsin. *Journal of Wildlife Diseases* 43: 302–208.
- BEARD, P. M., M. J. DANIELS, D. HENDERSON, A. PIRIE, K. RUDGE, D. BUXTON, S. RHIND, A. GREIG, M. R. HUTCHINGS, I. MCKENDRICK, K. STEVENSON, AND J. M. SHARP. 2001. Paratuberculosis infection of nonruminant wildlife in Scotland. *Journal of Clinical Microbiology* 39: 1517–1521.
- CHIODINI, R. J., AND H. J. VAN KRUININGEN. 1983. Eastern white-tailed deer as a reservoir of ruminant paratuberculosis. *Journal of American Veterinary Medical Association* 182: 168–169.
- COLLINS, M. T., K. B. KENEFICK, D. C. SOCKETT, R. S. LAMBRECHT, J. MCDONALD, AND J. B. JORGENSEN. 1990. Enhanced radiometric detection of *Mycobacterium paratuberculosis* by using filter-concentrated bovine fecal specimens. *Journal of Clinical Microbiology* 28: 2514–2519.
- CORN, J. L., E. J. B. MANNING, S. SREEVATSAN, AND J. R. FISCHER. 2005. Isolation of *Mycobacterium avium* subspecies *paratuberculosis* from free-ranging birds and mammals on livestock premises. *Applied and Environmental Microbiology* 71: 6963–6967.
- FOLK, M. J., AND W. D. KLIMSTRA. 1991. Urbanization and domestication of the Key deer (*Odocoileus virginianus clavium*). *Florida Field Naturalist* 19: 1–9.
- GREIG, A., K. STEVENSON, D. HENDERSON, V. PEREZ, V. HUGHES, I. PAVLIK, E. HINES 2ND, I. MCKENDRICK, AND J. M. SHARP. 1999. Epidemiological study of paratuberculosis in wild rabbits in Scotland. *Journal of Clinical Microbiology* 37: 1746–1751.
- HARDIN, J. W., W. D. KLIMSTRA, AND N. J. SILVY. 1984. Florida Keys. In *White-tailed deer: Ecology and management*, L. K. Halls (ed.), Stackpole Books, Harrisburg, Pennsylvania, pp. 381–390.
- HARVESON, P. M., R. R. LOPEZ, N. J. SILVY, AND P. A. FRANK. 2004. Source-sink dynamics of Florida Key deer on Big Pine Key, Florida. *Journal of Wildlife Management* 68: 909–915.
- JESSUP, D. A., B. ABBAS, D. BEHYMER, AND P. GOGAN. 1981. Paratuberculosis in tule elk in California. *Journal of the American Veterinary Medical Association* 179: 1252–1254.
- JUDGE, J., I. KYRIAZAKIS, A. GREIG, R. S. DAVIDSON, AND M. R. HUTCHINGS. 2006. Routes of intra-species transmission of *Mycobacterium avium* subsp. *paratuberculosis* in rabbits (*Oryctolagus cuniculus*): A field study. *Applied and Environmental Microbiology* 72: 398–403.
- LOPEZ, R. R. 2001. Population ecology of Florida Key deer. PhD Dissertation. Texas A&M University, College Station, Texas, 203 pp.
- , N. J. SILVY, J. D. SEBESTA, S. D. HIGGS, AND M. W. SALAZAR. 1998. A portable drop net for capturing urban deer. *Proceedings of the Southeastern Association of Fish and Wildlife* 52: 206–209.
- , ———, P. A. FRANK, AND B. L. PIERCE. 2003. Effects of supplemental feeding on Key deer behavior in urban areas. *Florida Scientist* 66: 267–272.
- MILLER, R., J. B. KANEENE, S. D. FITZGERALD, AND S. M. SCHMITT. 2003. Evaluation of the influence of supplemental feeding of white-tailed deer (*Odocoileus virginianus*) on the prevalence of bovine tuberculosis in the Michigan wild deer population. *Journal of Wildlife Diseases* 39: 84–95.
- NETTLES, V. F., C. F. QUIST, R. R. LOPEZ, T. J. WILMERS, P. FRANK, W. ROBERTS, S. CHITWOOD, AND W. R. DAVIDSON. 2002. Morbidity and mortality factors in Key deer (*Odocoileus virginianus clavium*). *Journal of Wildlife Diseases* 38: 685–692.
- PALMER, M. V., W. C. STOFFREGEN, J. G. CARPENTER, AND J. R. STABEL. 2005. Isolation of *Mycobacterium avium* subsp. *paratuberculosis* (Map) from feral cats on a dairy farm with Map-infected cattle. *Journal of Wildlife Diseases* 41: 629–635.
- QUIST, C. F., V. F. NETTLES, E. J. B. MANNING, D. G. HALL, J. K. GAYDOS, T. J. WILMERS, AND R. R.

- LOPEZ. 2002. Paratuberculosis in Key deer (*Odocoileus virginianus clavium*). *Journal of Wildlife Diseases* 38: 729–737.
- RAIZMAN, E. A., S. J. WELLS, P. A. JORDAN, G. D. DELGIUDICE, AND R. R. BEY. 2005. *Mycobacterium avium* subsp. *paratuberculosis* from free-ranging deer and rabbits surrounding Minnesota dairy herds. *Canadian Journal of Veterinary Research* 69: 32–38.
- TRYLAND, M., I. OLSEN, T. VIKOREN, K. HANDELAND, J. M. ARNEMO, J. THARALDSEN, B. DJONNE, T. D. JOSEFSEN, AND L. J. REITAN. 2004. Serologic survey for antibodies against *Mycobacterium avium* subsp. *paratuberculosis* in free-ranging cervids from Norway. *Journal of Wildlife Diseases* 40: 32–41.
- WILLIAMS, E. S. 1983. Experimental infection of some North American wild ruminants and domestic sheep with *Mycobacterium paratuberculosis*: Clinical and bacteriological findings. *Journal of Wildlife Diseases* 19: 185–191.
- . 2001. Paratuberculosis and other mycobacterial diseases. In *Infectious diseases of wild mammals*. 3rd Edition. E. S. Williams and I. K. Baker (eds.). Iowa State University Press, Ames, Iowa, pp. 361–371.

Received for publication 1 August 2007.