



Intracranial Abscessation as a Natural Mortality Factor for Adult Male White-Tailed Deer (*Odocoileus Virginianus*) in Kent County, Maryland, USA

Authors: Karns, Gabriel R., Lancia, Richard A., DePerno, Christopher S., Conner, Mark C., and Stoskopf, Michael K.

Source: Journal of Wildlife Diseases, 45(1) : 196-200

Published By: Wildlife Disease Association

URL: <https://doi.org/10.7589/0090-3558-45.1.196>

BioOne Complete (complete.BioOne.org) is a full-text database of 200 subscribed and open-access titles in the biological, ecological, and environmental sciences published by nonprofit societies, associations, museums, institutions, and presses.

Your use of this PDF, the BioOne Complete website, and all posted and associated content indicates your acceptance of BioOne's Terms of Use, available at www.bioone.org/terms-of-use.

Usage of BioOne Complete content is strictly limited to personal, educational, and non - commercial use. Commercial inquiries or rights and permissions requests should be directed to the individual publisher as copyright holder.

BioOne sees sustainable scholarly publishing as an inherently collaborative enterprise connecting authors, nonprofit publishers, academic institutions, research libraries, and research funders in the common goal of maximizing access to critical research.

Intracranial Abscessation as a Natural Mortality Factor for Adult Male White-Tailed Deer (*Odocoileus virginianus*) in Kent County, Maryland, USA

Gabriel R. Karns,^{1,4} Richard A. Lancia,¹ Christopher S. DePerno,¹ Mark C. Conner,² and Michael K. Stoskopf³ ¹ Fisheries and Wildlife Sciences Program, Department of Forestry and Environmental Resources, North Carolina State University, Raleigh, North Carolina 27695, USA; ² DuPont Crop Protection, Chesapeake Farms, Chestertown, Maryland 21620, USA; ³ Department of Clinical Sciences and Environmental Medicine Consortium, North Carolina State University, Raleigh, North Carolina 27606, USA; ⁴ Corresponding author (email: grkarns@ncsu.edu)

ABSTRACT: Intracranial abscessation is a cause of natural mortality among free-ranging white-tailed deer (*Odocoileus virginianus*) across portions of the United States and Canada. Intracranial abscesses caused by *Arcanobacterium pyogenes* disproportionately affect adult male white-tailed deer. From 2003–08, we evaluated the occurrence of intracranial abscessation among adult (≥ 2.5 yr) radiocollared male white-tailed deer ($n=33$) at a large private property in Kent County, Maryland, USA. We documented mortality and necropsied 26 (79%) of the 33 deer. In 2007, we collected swabs from the antler bases and nasopharyngeal membranes of living male white-tailed deer in Maryland, USA ($n=9$), and Texas, USA ($n=10$), and from freshly rubbed ($n=7$) and unrubbed ($n=7$) trees in Maryland, USA. Swabs were cultured for the presence or absence of *A. pyogenes*. In Maryland, USA, nine (35%) of the 26 necropsied radiocollared male deer had intracranial abscesses. Five (56%) of nine Maryland, USA, males, and none (0%) of 10 Texas, USA, males cultured positive for *A. pyogenes*. No rubbed or unrubbed trees at the Maryland site cultured positive for *A. pyogenes*. The rate of intracranial abscess among adult male white-tailed deer at the Maryland, USA, site (35%) exceeds reported rates for other regions of the United States (9%).

Key words: *Arcanobacterium pyogenes*, intracranial abscessation, Maryland, *Odocoileus virginianus*, Texas, white-tailed deer.

Intracranial abscessation is a documented source of natural mortality in white-tailed deer (*Odocoileus virginianus*) across portions of the United States and Canada (Baumann et al., 2001). Occurring primarily between October and April, cases of intracranial abscess are thought to be

directly related to breeding activities (i.e., antler sparring, rubbing behavior, or antler casting) and disproportionately affect male white-tailed deer (Davidson et al., 1990). *Arcanobacterium pyogenes* (formerly *Actinomyces*) or other bacteria enter via subcutaneous cuts, abrasions, or injured pedicles, and penetration of the cranium is thought to occur primarily through the suture between the parietal and frontal bones (Davidson et al., 1990). Associated symptoms of abscesses include incoordination, fearlessness, weakness, blindness, emaciation, and potentially, death (Davidson et al., 1990).

Beginning in mid-October, male white-tailed deer vigorously rub tree saplings with their antlers and foreheads (Atkeson and Marchinton, 1982). Antler rubbing polishes the antlers, creates scent posts, and functions in breeding behavior (Kile and Marchinton, 1977). It is possible that *A. pyogenes* may be transmitted between males using common trees for antler rubbing; however research is lacking. Intracranial abscessation can afflict deer regardless of sex or age (Davidson et al., 1990; Nettles et al., 2002; Chirino-Trejo et al., 2003). In a survey of deer mortality reports from the Southeastern Cooperative Wildlife Disease Study and other state (Colorado, Florida, Idaho, Michigan, Mississippi, Missouri, New Jersey, New York, Oklahoma, Texas, Washington, Wisconsin, and Wyoming, USA) and provincial (Alberta, Ontario, and Saskatchewan, Can-

ada) agencies, intracranial abscessation accounted for 2.2% of sex-nonspecific deer natural mortality, 4.9% of male natural mortality, and 9.3% of adult (≥ 2.5 yr) male natural mortality (Baumann et al., 2001). Intracranial abscessation is considered extremely rare in Texas, USA, and southern portions of Oklahoma, USA, and it is believed the region's arid climate might discourage survival of the infective organisms (Baumann et al., 2001).

Our objectives were to determine the rate of intracranial abscess as a source of natural mortality among adult (≥ 2.5 yr) male white-tailed deer; evaluate the prevalence of *A. pyogenes* in the bacterial flora of adult male white-tailed deer in arid (south Texas, USA) and more verdant (Maryland, USA) habitats; and examine the possible role of antler rub trees in the transmission of *A. pyogenes* between male deer.

Our Maryland, USA, site was a 1,300-ha wildlife management and agricultural research demonstration area in Kent County, Maryland, USA (39°10'N, 76°10'W) located on the eastern shore of Chesapeake Bay, 10 km southwest of Chestertown. The site was privately owned, and 50% of the study area was forested with nonalluvial swamps consisting primarily of oaks (*Quercus* spp.), sweetgum (*Liquidambar styraciflua*), black gum (*Nyssa sylvatica*), and red maple (*Acer rubrum*). Greenbriar (*Smilax* spp.), sweet pepperbush (*Clethra alnifolia*), and highbush blueberry (*Vaccinium corymbosum*) dominated the understory. Cash crops, field corn (*Zea mays*), and soybeans (*Glycine max*) composed 20% of the study area. Fallow fields composed 13% of the farm (orchard grass [*Dactylis glomerata*], clover [*Trifolium* spp.], sorghum [*Sorghum* spp.], and rye [*Lolium multiflorum*]). The remaining 17% was composed of nonforested wildlife cover and constructed waterfowl impoundments (Shaw, 2005). Recently, deer density was estimated at 1 deer/3 ha (Shaw, 2005).

Our Texas, USA, site centered on two pastures within a 103,691-ha commercial cattle operation located in the eastern Rio Grande Plains region, 4 km east of Kingsville in Kleberg County, Texas, USA (27°31'N, 97°55'W). There were no high fences and the mixed-shrub rangeland was dominated by mesquite (*Prosopis glandulosa*) and huisache (*Acacia farnesiana*; McCoy et al., 2005). The pastures were stocked with domestic cattle at an average rate of 1 animal unit/10 ha, and deer density was estimated at 1 deer/17 ha (McCoy et al., 2005).

From 2003–08, at our Maryland, USA, site, we monitored 33 adult (≥ 2.5 yr) male white-tailed deer with Global Positioning System (GPS) radiocollars (Tomberlin, 2007). The radiocollars were equipped with mortality sensors that activated within 8 hr of death, and deer were retrieved 12 to 48 hr postmortem. Field necropsies were performed onsite. Brain cases were opened to determine presence of intracranial abscess. Using a CO₂-powered dart projector with 2.4 ml tiletamine HCl and zolazepam HCl (Telazol®; 200 mg/ml; Fort Dodge Animal Health, Fort Dodge, Iowa, USA) and 0.6 ml xylazine (Cervizine® 300; 450 mg/ml; Wildlife Laboratories, Inc., Fort Collins, Colorado, USA) drug combination, nine deer were captured to fit with radiocollars from 20 June 2007 to 30 July 2007. From these deer, nasopharyngeal membranes and antler bases were independently swabbed until thoroughly covered with epithelial residue using Remel Bacti-Swab transport swabs (Remel Products, Lenexa, Kansas, USA). Deer were examined for injuries, large tick loads, abrasions, or cuts. At the Texas, USA, site, nasopharyngeal and antler base swabs were taken from 10 adult (≥ 2.5 yr) male white-tailed deer captured by helicopter net-gunning during a GPS-collar study on 30 October 2007. Deer sampled from both study areas were estimated to be approximately the same age based on morphologic characteristics. Tree rub samples were collected on 23 October

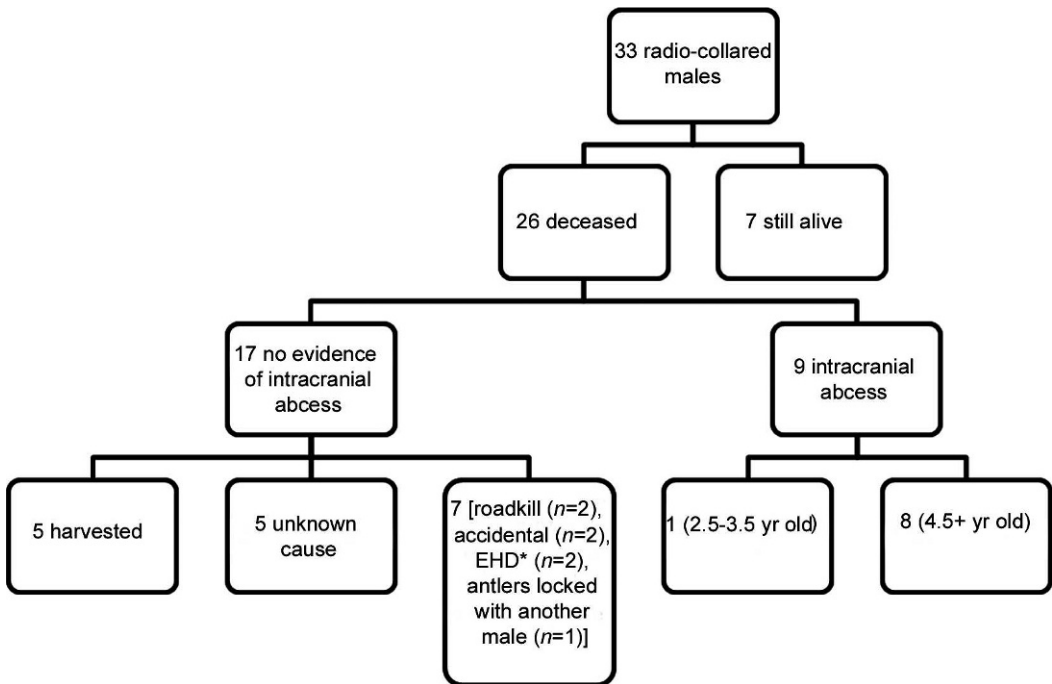


FIGURE 1. The fate of 33 adult male radiocollared white-tailed deer captured at Chesapeake Farms, Maryland, USA, 2003–2007. *EHD=epizootic hemorrhagic disease.

2007 from seven freshly rubbed (approximately ≤ 24 hr) trees at the Maryland, USA, site. The collection date was centered within the period of the white-tailed deer breeding season when antler rubbing and scraping peaked (Kile and Marchinton, 1977). We selected the most freshly rubbed tree that we could locate, irrespective of tree species, in a 1-hr-long search within seven unique land covers that are representative of the study area and more widely distributed across the overall landscape. Tree species was recorded, and the closest unrubbed tree of the same species was swabbed and cultured as a control. Antler, nasopharyngeal, and tree swabs were refrigerated for up to 24 hr before delivery to the Centreville Animal Health Diagnostic Lab (Centreville, Maryland, USA), where samples were plated on blood agar. A gram stain and catalase test was conducted for each sample. All aerobic gram-negative and gram-positive bacteria were identified to genus and speciated on the basis of

morphology, staining characteristics, and biochemical use using standard ASM techniques (Lennette et al., 1985; Holt et al., 1994). All procedures for research followed the guidelines for the Institutional Animal Care and Use Committee at North Carolina State University (05-024-0).

Of the 33 Maryland, USA, radiocollared deer, we documented mortality for 26 (79%) of the individuals (Fig. 1). Cause of death was not determined for five (19%) of the necropsied deer. Nine (35%) of the 26 known-fate deer had intracranial abscesses (Fig. 1). Each affected male had exudate visible by external examination of at least one antler pedicle or orbit and had one or more abscesses inside the cranial cavity (Fig. 2). Eight (89%) of the nine deer with intracranial abscesses were older-age class (≥ 4.5 yr) males, representing more than half (62%) of the older age-class males in our sample (Fig. 1). Cultures from the nasopharyngeal and antler-base samples of 56% ($n=5$) of the

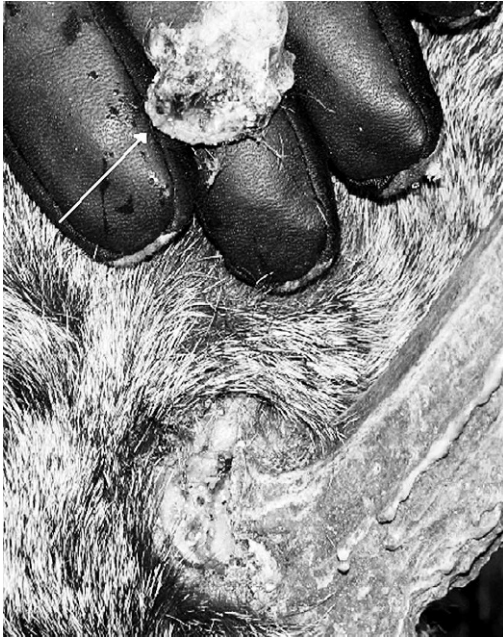

FIGURE 2. Exudate on the antler pedicle of 4.5-yr-old male white-tailed deer at Chesapeake Farms, Maryland, USA, 2006. Note the skull fragment that split away from the antler pedicle. Photo courtesy of M. Conner.

Maryland, USA, deer were positive for *A. pyogenes*. Other bacteria identified included *Staphylococcus* ($n=6$), *Bacillus* ($n=4$), *Klebsiella* ($n=1$), and *Pseudomonas* ($n=1$; Davidson et al., 1990; Baumann et al., 2001). Eighty percent ($n=4$) of the *A. pyogenes* results came from the nasopharyngeal samples. None of the Texas, USA, deer cultured positive for *A. pyogenes*. Other bacteria identified from Texas, USA, samples included *Staphylococcus* ($n=8$) and *Bacillus* ($n=9$). The failure to culture *A. pyogenes* from nasopharyngeal or antler base swabs suggests that presence of this organism associated with intracranial abscessation may be limited at our Texas, USA, site. It is possible the arid climate may discourage growth of *A. pyogenes*; however, our study design does not specifically address this question.

Arcanobacterium pyogenes or other bacteria were not detected from the freshly rubbed or unrubbed trees in

Maryland, USA. Species sampled included loblolly pine (*Pinus taeda*; $n=2$), black gum ($n=4$), sweet gum ($n=2$), white oak (*Quercus alba*; $n=2$), black cherry (*Prunus serotina*; $n=2$), and black locust (*Robinia pseudoacacia*; $n=2$). Failure to culture bacteria from the trees suggests that our culture methods were not optimized for bacterial cultures of tree bark. If a rubbed tree was contaminated with *A. pyogenes*, it is also possible the tree's nonspecific immune defenses, including pathogen-resistant proteins, would kill or retard the growth of *A. pyogenes* (Jones and Dangl, 2006).

During this study, *A. pyogenes* was common in the nasopharyngeal mucosa of male deer, and we believe that direct contact between competing males could conceivably be a more significant mode of bacterial transmission than using common trees for antler rubbing. Further, during breeding behavior (antler sparring) and social grooming, there is the possibility of transfer of contaminated mucus between individuals (Forand and Marchinton, 1989). The intracranial abscess prevalence for radiocollared males in Maryland, USA, is conservative because we did not examine five unknown mortalities for the presence of diffuse suppurative meningoencephalitis (Fig. 1) and because of the limitations of the field necropsy techniques used (Davidson et al., 1990). Histologic evaluation of brain and meninges might have identified additional cases (Davidson et al., 1990). Because of management for increased male age structure as part of a quality deer management [QDM] paradigm at the Maryland, USA, site, intrasexual competition may be elevated during the breeding season, which would be expected to predispose individuals to disproportionately more injuries than would occur in less-intensively managed populations. High deer density at the Maryland, USA, site also could be a factor increasing stress and injuries during breeding season, thus propagating the occurrence of intracranial abscessation. If

intracranial abscesses are additive to natural and harvest mortality in QDM-managed populations, it could be a significant impediment to successful QDM and should be considered by managers, wildlife agencies, and hunters on the Delmarva Peninsula, USA.

We thank DuPont Agricultural Enterprise and the Fisheries and Wildlife Sciences Program and Department of Forestry and Environmental Resources at North Carolina State University for funding this research project. Thanks to L. Muller at University of Tennessee-Knoxville for providing darting equipment. Also, we thank J. Lewis at Texas A&M University-Kingsville and M. Hellickson of King Ranch for facilitating access and cooperation throughout the study and S. Hutchens and K. Golden for reviewing drafts of this manuscript. Additional thanks to the Centreville Animal Health Diagnostic Laboratory for analyses of bacteriologic samples.

LITERATURE CITED

- ATKESON, T. D., AND R. L. MARCHINTON. 1982. Forehead glands in white-tailed deer. *Journal of Mammalogy* 63: 613–617.
- BAUMANN, C. D., W. R. DAVIDSON, D. E. ROSCOE, AND K. BEHELER-AMASS. 2001. Intracranial abscessation in white-tailed deer of North America. *Journal of Wildlife Diseases* 37: 661–670.
- CHIRINO-TREJO, M., M. R. WOODBURY, AND F. HUANG. 2003. Antibiotic sensitivity and biochemical characterization of *Fusobacterium* spp. and *Arcanobacterium pyogenes* isolated from farmed white-tailed deer (*Odocoileus virginianus*) with necrobacillosis. *Journal of Zoo and Wildlife Medicine* 34: 262–268.
- DAVIDSON, W. R., V. F. NETTLES, L. E. HAYES, E. W. HOWERTH, AND C. E. COUVILLION. 1990. Epidemiologic features of an intracranial abscessation/suppurative meningoencephalitis complex in white-tailed deer. *Journal of Wildlife Diseases* 26: 460–467.
- FORAND, K. J., AND R. L. MARCHINTON. 1989. Patterns of social grooming in adult white-tailed deer. *American Midland Naturalist* 122: 357–364.
- HOLT, J. G., N. R. KRIEG, P. H. A. SNEATH, J. T. STALEY, AND S. T. WILLIAMS. 1994. *Bergey's Manual of Determinative Bacteriology*, 9th Edition. Williams and Wilkins, Baltimore, Maryland, pp. 787.
- JONES, D. G., AND J. L. DANGL. 2006. The plant immune system. *Nature* 444: 323–329.
- KILE, T. L., AND R. L. MARCHINTON. 1977. White-tailed deer rubs and scrapes: spatial, temporal and physical characteristics and social role. *American Midland Naturalist* 97: 257–266.
- LENNETTE, E. H., A. BALOWS, W. J. HAUSLER, AND H. J. SHADOMY. 1985. *Manual of clinical microbiology*, 4th Edition. American Society for Microbiology, Washington, D.C., 1,149 pp.
- MCCOY, J. E., D. G. HEWITT, AND F. C. BRYANT. 2005. Dispersal by yearling male white-tailed deer and implications for management. *Journal of Wildlife Management* 69: 366–376.
- NETTLES, V. F., C. F. QUIST, R. R. LOPEZ, T. J. WILMERS, P. FRANK, W. ROBERTS, S. CHITWOOD, AND W. R. DAVIDSON. 2002. Morbidity and mortality factors in Key deer (*Odocoileus virginianus clavium*). *Journal of Wildlife Diseases* 38: 685–692.
- SHAW, J. C. 2005. Implications of quality deer management on population demographics, social pressures, dispersal ecology, and the genetic mating system of white-tailed deer at Chesapeake Farms, Maryland. PhD Dissertation. North Carolina State University, Raleigh, North Carolina, 111 pp.
- TOMBERLIN, J. W. 2007. Movement, activity, and habitat use of adult male white-tailed deer at Chesapeake Farms, Maryland. MS Thesis. North Carolina State University, Raleigh, North Carolina, 104 pp.

Received for publication 29 April 2008.