

## **Poxvirus Infection in an American Red Squirrel (*Tamiasciurus hudsonicus*) from Northwestern Canada**

Authors: Himsworth, Chelsea G., Musil, Kristyna M., Bryan, Lorraine,  
and Hill, Janet E.

Source: Journal of Wildlife Diseases, 45(4) : 1143-1149

Published By: Wildlife Disease Association

URL: <https://doi.org/10.7589/0090-3558-45.4.1143>

---

BioOne Complete ([complete.BioOne.org](https://complete.BioOne.org)) is a full-text database of 200 subscribed and open-access titles in the biological, ecological, and environmental sciences published by nonprofit societies, associations, museums, institutions, and presses.

Your use of this PDF, the BioOne Complete website, and all posted and associated content indicates your acceptance of BioOne's Terms of Use, available at [www.bioone.org/terms-of-use](https://www.bioone.org/terms-of-use).

Usage of BioOne Complete content is strictly limited to personal, educational, and non - commercial use. Commercial inquiries or rights and permissions requests should be directed to the individual publisher as copyright holder.

---

BioOne sees sustainable scholarly publishing as an inherently collaborative enterprise connecting authors, nonprofit publishers, academic institutions, research libraries, and research funders in the common goal of maximizing access to critical research.

## Poxvirus Infection in an American Red Squirrel (*Tamiasciurus hudsonicus*) from Northwestern Canada

Chelsea G. Himsworth,<sup>1,4</sup> Kristyna M. Musil,<sup>2</sup> Lorraine Bryan,<sup>3</sup> and Janet E. Hill<sup>2</sup> <sup>1</sup>Department of Veterinary Pathology and <sup>2</sup>Veterinary Microbiology, Western College of Veterinary Medicine, University of Saskatchewan, 52 Campus Drive, Saskatoon, Saskatchewan S7N 5B4, Canada; <sup>3</sup>Canadian Cooperative Wildlife Health Center, University of Saskatchewan, Saskatoon, Saskatchewan S7N 5B4, Canada; <sup>4</sup>Corresponding author (email: chelsea.himsworth@usask.ca)

**ABSTRACT:** There are two recognized poxviruses that are associated with disease in tree squirrels: squirrel fibroma virus (SQFV), *Leporipoxvirus*, which affects eastern grey squirrels (*Sciurus carolinensis*) in eastern North America, and squirrelpox virus (SQPV), a member of a newly identified poxvirus genus, which affects European red squirrels (*Sciurus vulgaris*) in the United Kingdom. In August 2008, a cutaneous poxvirus-associated disease was identified in a North American red squirrel (*Tamiasciurus hudsonicus*) from the Yukon Territory, Canada. The gross and microscopic appearance of the skin lesions was more consistent with SQPV than SQFV, and electron microscopy revealed poxvirions only within epithelial cells. Polymerase chain reaction (PCR) was used to identify poxvirus core protein encoding DNA in skin samples, and phylogenetic analysis showed that the inferred amino acid sequence was distinct from all other poxvirus species for which the core protein gene has been sequenced, including those of the genus *Leporipoxvirus*. Although the core protein sequence of SQPV was not available, comparison of the constructed phylogenetic tree to other published trees, based on major outer envelope proteins, revealed that the identified sequence occupies a position similar to SQPV in terms of its relationship to other poxviruses. However, PCR primers designed to amplify gene sequences encoding the SQPV major envelope protein and RNA polymerase did not amplify any sequences from infected tissues. These findings suggest that the virus present in this squirrel is a novel poxvirus of North American red squirrels. To our knowledge, this is the first case of poxvirus infection in Canadian squirrels outside of Ontario.

**Key words:** American red squirrel, Canada, squirrel fibroma virus, squirrelpox, *Tamiasciurus hudsonicus*.

There are two recognized diseases of squirrels of the genus *Sciurus* caused by

poxviruses. Squirrel fibroma virus (SQFV), *Leporipoxvirus*, is believed to be endemic in many populations of eastern grey squirrels (*Sciurus carolinensis*) within their natural range in eastern North America (Robinson and Kerr, 2001; Terrell et al., 2002). Squirrel fibroma virus usually causes sporadic disease, and, although occasional epizootics occur, it is not thought to have a significant impact on grey squirrel populations (Robinson and Kerr, 2001; Terrell et al., 2002). In contrast, squirrelpox virus (SQPV), the sole member of a newly identified and currently unnamed genus within the poxvirus family (Thomas et al., 2003; McInnes et al., 2006), causes a fatal disease in European red squirrels (*Sciurus vulgaris*) and is believed to be contributing to the decline of this species in the United Kingdom (Carroll et al., 2008). Squirrelpox is thought to have been introduced into the UK in the late 19th century with the introduction of the eastern grey squirrel, which appears to be the natural reservoir for the virus (McInnes et al., 2006; Carroll et al., 2008). Both SQFV and SQPV cause epidermal changes characteristic for poxviruses, including epithelial hyperplasia and hyperkeratosis, hydropic degeneration of keratinocytes, and the formation of intracytoplasmic inclusions (Simon and Bullard, 1973; Sainsbury and Ward, 1996; Ginn et al., 2007). Unlike SQPV, SQFV causes proliferation of dermal fibroblasts and the formation of intracytoplasmic viral inclusions within those cells (Hirth et al., 1969;

O'Connor et al., 1980; Terrell et al., 2002). Squirrelpox virus can also be distinguished from SQFV by the exudative nature of the cutaneous lesions, making SQPV infection similar to that of parapoxviruses in its histologic appearance (Hirth et al., 1969; Sainsbury and Gurnell, 1995; Sainsbury and Ward, 1996). Grossly, SQPV is associated with cutaneous ulceration and formation of hemorrhagic crusts (Sainsbury and Gurnell, 1995), whereas SQFV causes the development of distinct nodules (Terrell et al., 2002; O'Connor et al., 1980; King et al., 1972). We describe a case of poxvirus-associated disease in a North American red squirrel (*Tamiasciurus hudsonicus*) from Yukon Territory, Canada. To our knowledge there are no published accounts of poxvirus-associated disease in Canadian squirrels outside of Ontario.

In August 2008, a lethargic, juvenile, male red squirrel with a stumbling gait was found in a residential area of Whitehorse, Yukon Territory, Canada (60°43'N, 135°4'W). The property owner was concerned about the squirrel's rough peltage and "deformed" feet. The squirrel was collected, euthanized humanely, and submitted to the Canadian Cooperative Wildlife Health Center, Saskatoon, Saskatchewan, Canada for further examination.

On gross examination, there were numerous, multifocal to coalescing, tan to dark-brown, friable crusts throughout the pelt (Fig. 1). These crusts were particularly abundant overlying the pinnae, which were noticeably thickened. Multiple digits were missing, and those that remained were dark and appeared necrotic. The tail was absent; however, the reason for this was unclear. The squirrel had no visible subcutaneous or visceral fat, however, the intestine was filled with seeds and there were formed feces in the colon.

Samples from multiple organs, including skin, taken at necropsy were fixed in 10% neutral buffered formalin, routinely processed, and embedded in paraffin. Sections (5 µm) were stained with hematoxylin and eosin for microscopic exami-

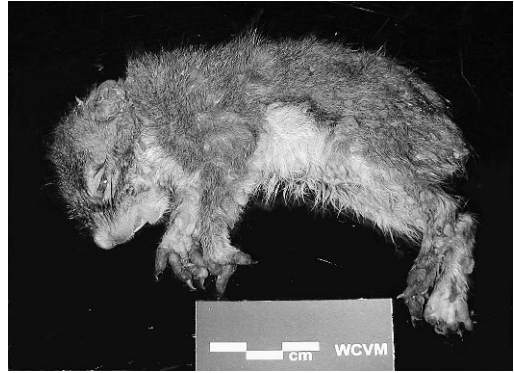

FIGURE 1. A juvenile North American red squirrel from Yukon Territory with numerous raised crusts throughout the pelt, marked thickening of the skin covering the pinnae, and necrosis or loss of multiple digits.

nation. Microscopically, throughout the skin, there were multifocal areas of epidermal hyperplasia characterized by moderate acanthosis, with downgrowth of rete pegs, as well as marked, compact, ortho- and parakeratotic hyperkeratosis (Fig. 2). Numerous keratinocytes in the upper stratum spinosum and stratum granulosum were undergoing ballooning degeneration, and occasional cells contained eosinophilic, intracytoplasmic inclusions (Fig. 3). There was an irregularly distributed dermal inflammatory infiltrate consisting of neutrophils, lymphocytes, and plasma cells, and, in some areas, there was marked neutrophilic exocytosis. Overlying the affected areas was a thick hemorrhagic crust containing keratin and neutrophils. There were no other significant lesions.

Formalin-fixed skin was processed for electron microscopy and sections were stained with uranyl acetate and lead citrate. Numerous, approximately 300-nm-long, viral particles morphologically consistent with poxvirus were identified in the cytoplasm of intact and exfoliated keratinocytes (Fig. 4). Virus was not observed in dermal fibroblasts.

Polymerase chain reaction (PCR) was performed on previously frozen samples



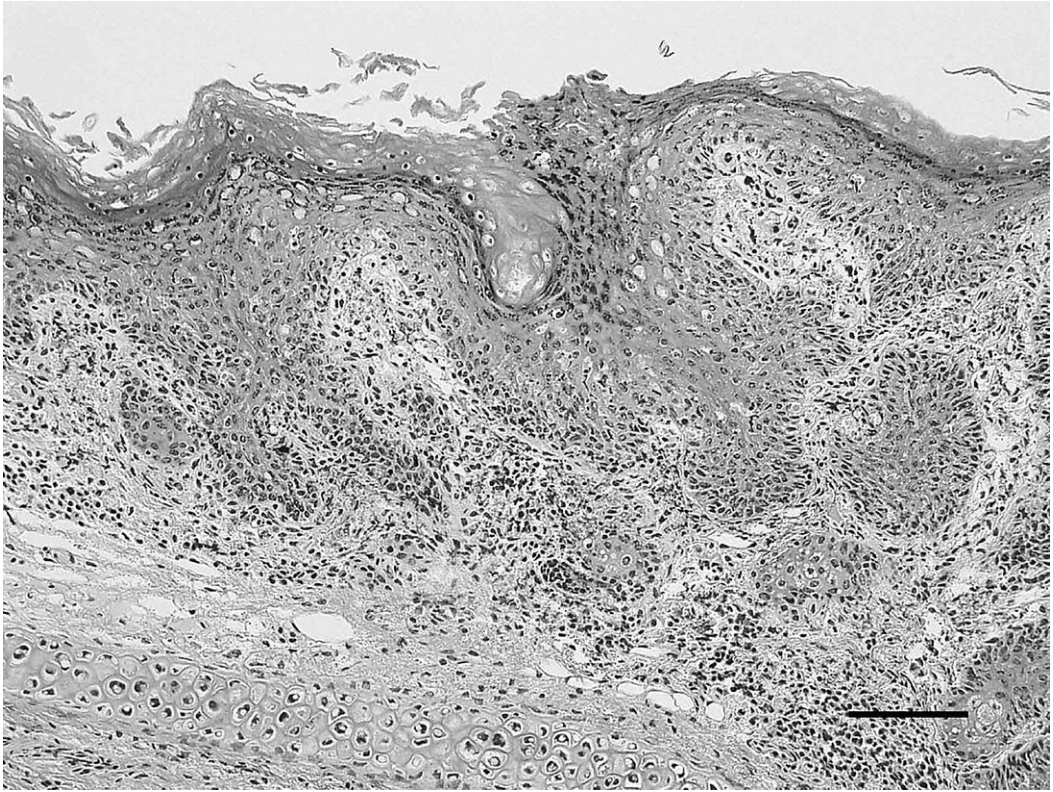


FIGURE 2. Skin from the pinna of a juvenile red squirrel: Moderate epidermal hyperplasia and hyperkeratosis with ballooning degeneration of keratinocytes and dermal inflammation. H&E stain. Bar=100  $\mu$ m.

from affected areas of the pelt and ear pinna in an attempt to identify the causative virus. Two genes were targeted for PCR. Based on the Genbank deposit of Bangari et al. (Accession No. EU732593, squirrel fibroma virus, DNA polymerase gene, unpublished) primers JH0079 5'-TAT TAT TCG CCA CGA ATA CAC A-3' and JH0080 5'-ATA ATC TAG ACG TAG CCG TAG A-3' were used in an attempt to amplify a 389-base-pair (bp) fragment of the DNA polymerase gene of SQFV. Primers (JH0081 5'-GCT CCA TCT CGA CCA TCA AG-3' and JH0082 5'-GTT GTA GAT GTC GGG CCA GT-3') were designed based on the Genbank deposit of Thomas et al. (Accession No. AY312569, squirrel poxvirus, envelope protein gene, ortholog of the vaccinia virus [VACV] major outer envelope protein) in order to

amplify a 368-bp region of the SQPV major envelope protein gene.

The Qiagen DNeasy tissue and blood kit was used for total DNA extraction from samples of pelt and ear (sample size for extraction was approximately 20 mg). Polymerase chain reaction was conducted on both tissue DNA extracts (ear and pelt). Extracted DNA (2  $\mu$ l) was used as template in PCR (50  $\mu$ l total volume) containing 1 $\times$  reaction buffer (10 mm KCl, 10 mm  $[\text{NH}_4]_2\text{SO}_4$ , 20 mm Tris HCl [pH 8.75], 0.1% Triton X-100, 0.1 mg/ml BSA), 0.5 U Taq DNA polymerase (UBI Life Sciences, Saskatoon, Saskatchewan, Canada), 2.5 mm  $\text{MgSO}_4$ , and 20 pmol each of forward and reverse primers. Polymerase chain reactions were incubated at 95 C for 3 min followed by 40 cycles of 30 sec at 95 C, 30 sec at the annealing temperature,

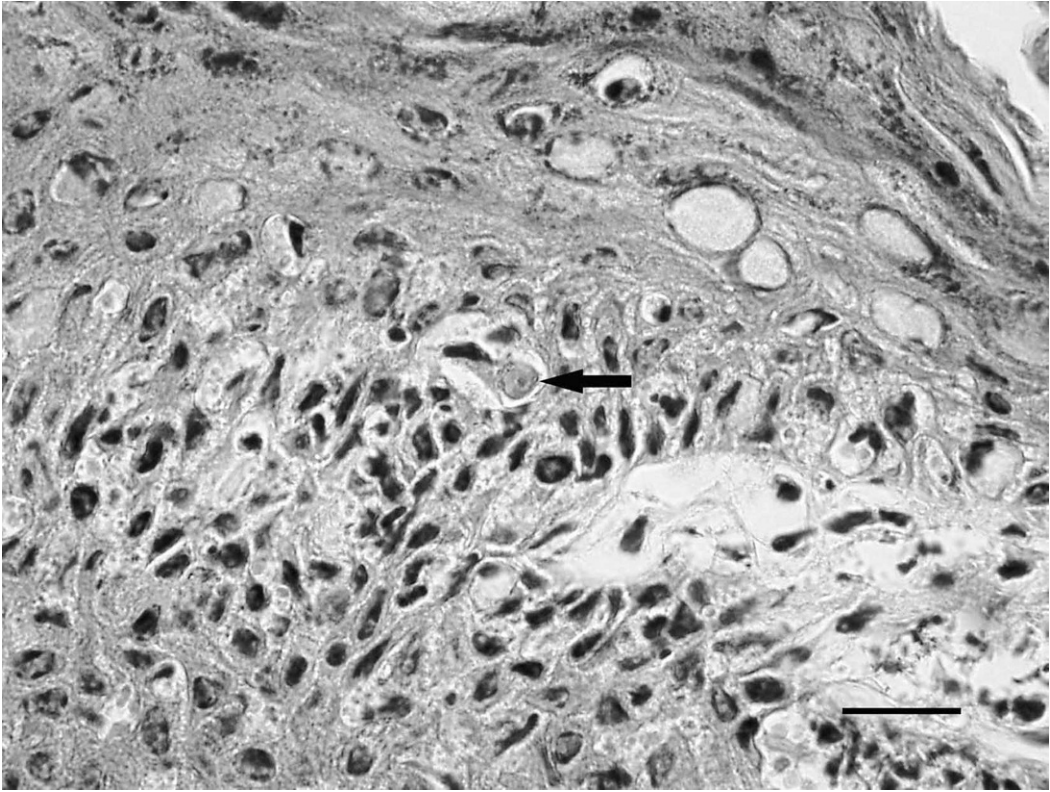


FIGURE 3. Skin from the pinna of a juvenile red squirrel: Intracytoplasmic viral inclusion (arrow) within a keratinocyte. H&E stain. Bar=20  $\mu$ m.

and 30 sec at 72 C. A gradient of annealing temperatures from 50 C to 57 C was used for both primer sets in replicate reactions. Products of PCR were examined on 1.5% agarose gels stained with ethidium bromide. A single PCR product of approximately 500 bp was detected in the reactions done with JH0079/JH0080 (SQFV DNA polymerase), but no products were obtained under any of the conditions used with JH0081/JH0082 (SQPV envelope protein gene).

The JH0079/JH0080 PCR products amplified from pelt and ear samples were purified and sequenced with the use of the amplification primers. An identical DNA sequence of 511 bp was obtained from both samples (Genbank Accession No. FJ839690). A comparison of the amplified sequence to Genbank with BLASTn indicated that the sequence

derived from the squirrel tissue was weakly similar (~65% nucleotide sequence identity) to core protein genes from a variety of poxviruses including parapox, leporipox, and orthopox viruses. A BLASTx search (where the translated nucleotide sequence is compared to the protein sequence database) indicated that the putative amino acid translation of the squirrel-derived PCR product is 64% similar or 84% identical to virion core protein P4b from Orf virus (Parapox; Genbank Accession No. NP\_957856). The translated sequence is 56% similar and 76% identical to the orthologous sequence from rabbit fibroma virus (core protein gp092L; Genbank Accession No. NP\_051981). There are no sequence data available for the SQPV core protein ortholog.

The possible nucleotide sequence that could encode poxvirus P4b proteins



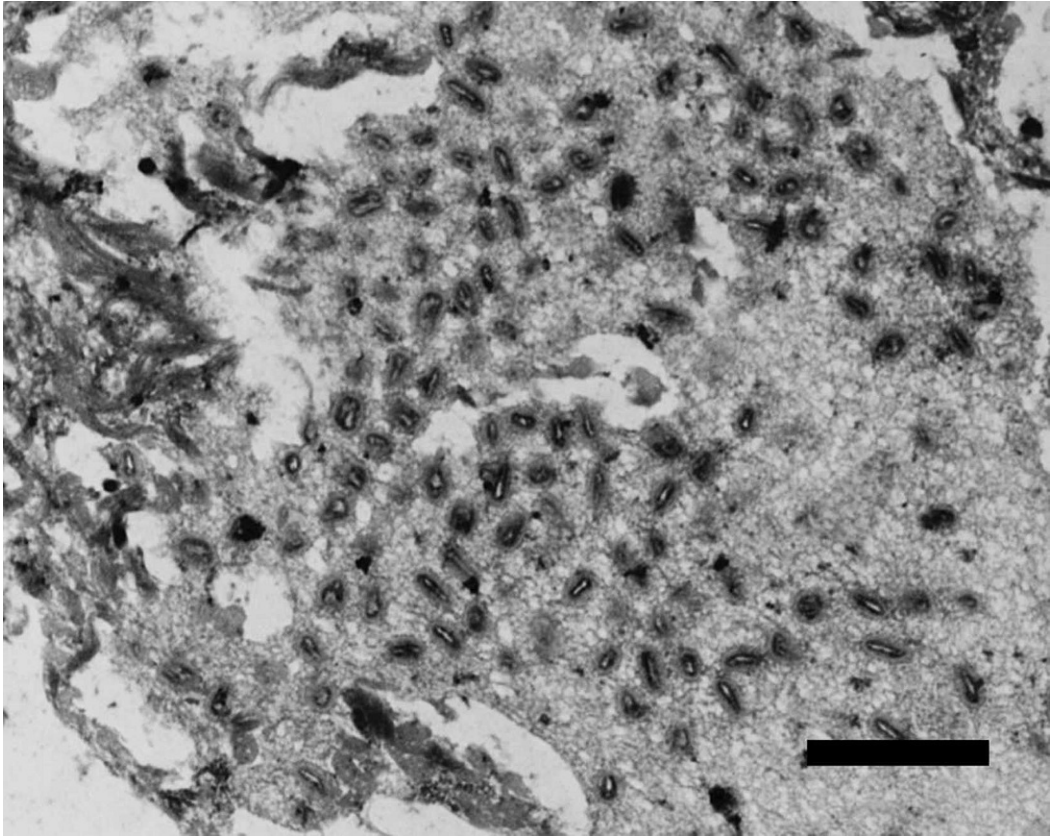


FIGURE 4. Skin from the pinna of juvenile red squirrel: Numerous poxvirus particles are present within an exfoliated keratinocyte. Transmission electron micrograph uranyl acetate and lead citrate. Bar=1  $\mu$ m.

showed significant sequence similarity to the amplification primers JH0079/JH0080 (data not shown), which could explain our serendipitous amplification of core protein gene sequence with the use of primers designed to amplify the DNA polymerase gene of SQPV.

A phylogenetic tree (Fig. 5) was created based on an alignment of 111 amino acids of translated sequence from the JH0079/JH0080 amplicon and core proteins of *Chordopoxviridae*. This tree shows that the squirrel-derived sequence is clearly distinct from all other poxvirus species. However, when the topology of this tree is compared to published trees (based on orthologs of the VACV major outer envelope protein and the poxvirus RNA polymerase 30-kDa subunit; Thomas et al., 2003) it is apparent that the squirrel-

derived sequence occupies a position similar to SQPV in relation to other poxviruses. This suggested the possibility that the sequence isolated was, in fact, from SQPV.

To investigate this possibility, we designed two additional PCR primer sets targeting the RNA polymerase gene of SQPV, which has also been used for phylogenetic analysis of poxviruses. Primers JH0089 (5'-TCG TGA ACA CGA AGA CCA AC-3') and JH0090 (5'-GTT GTA CTC CAC GCC CTT TC-3'), JH0091 (5'-GTC CGA GAA TAA TGC CGT GT-3') and JH0092 (5'-CCG TCC TCG GAC TCG TAC T-3') were designed to amplify 239 or 690 bp of the SQPV RPO30-like protein gene (Genbank Accession No. AY310357). No fragments of the appropriate size were amplified from

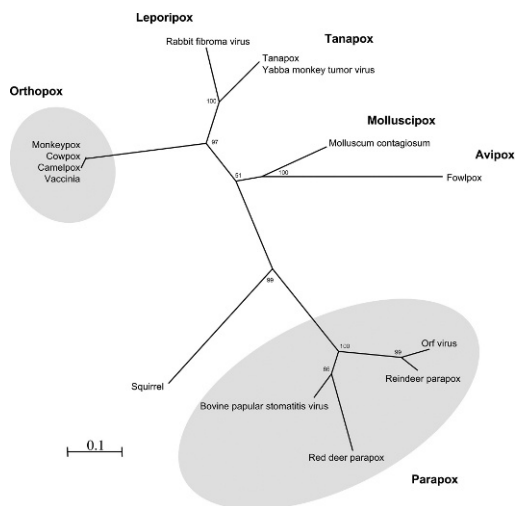


FIGURE 5. A phylogenetic tree based on an alignment of 111 amino acids of translated sequence from the JH0079/JH0080 amplicon and core proteins of *Chordopoxviridae*, including vaccinia (AAQ93219), cowpox (CAD90671), camelpox (NP\_570510), monkeypox (NP\_536541), rabbit fibroma virus (NP\_051981), Yaba monkey tumor virus (NP\_938349), tanapox (YP\_001497089), molluscum contagiosum (NP\_044057), fowlpox (NP\_039130), red deer parapox (AAS45191), reindeer parapox (AAS45179), orf virus (NP\_957856) and (NP\_957988) bovine papular stomatitis virus. The tree is a consensus of 100 neighbor-joined trees and bootstrap values are indicated at the nodes.

the infected squirrel tissue under any of the reaction conditions employed.

After our initial attempts to identify the virus, we obtained a DNA extract from a SQPV-positive red squirrel from the UK. The anticipated fragments were amplified from this SQPV-positive sample with the use of primers specific for SQPV envelope protein gene (JH0081/JH0082) and RPO30-like protein gene (JH0089/JH0090). Primers JH0112 (5'-TCC ACT TCG AAG ATC ACT GCT-3') and JH0113 (5'-GAG TCC CGT AAT CCG GAG AT-3') were designed to amplify specifically a 359-bp region of the Canadian squirrel virus P4b-like sequence. No amplification from the SQPV-positive sample was observed with this primer pair. We were also unable to amplify any fragments from the SQPV-positive sample with primers targeting the SQFV DNA

polymerase gene (JH0079/JH0080), even with extremely permissive amplification conditions (annealing temperature of 42 C).

Although the identity of the poxvirus detected in this squirrel remains unknown, the observed gross and microscopic pathology is most similar to that reported in cases of SQPV infection (Hirth et al., 1969; Sainsbury and Gurnell, 1995; Sainsbury and Ward, 1996). Results of PCR and initial phylogenetic analysis also indicate that the virus is more closely related to SQPV than SQFV. However, our inability to amplify SQPV-specific DNA sequences from this squirrel, despite the fact that these sequences were amplified from a SQPV-positive control sample, suggests that the virus detected in this case is a novel poxvirus. This suggestion is supported by the fact that it is unclear how a North American red squirrel in Yukon Territory might become exposed to SQPV. The eastern grey squirrel is thought to be the reservoir SQPV in the UK (McInnes et al., 2006), and although antibodies against the virus have been detected in eastern grey squirrels in the USA, the virus has not been associated with disease in North America (McInnes et al., 2006). Additionally, the natural range of the eastern grey squirrel within Canada does not extend to Yukon Territory (Koprowski, 1994); therefore, direct contact between this squirrel and eastern grey squirrel is unlikely.

Given the overlap between the ranges of the eastern grey squirrel and North American red squirrel (Koprowski, 1994; Steele, 1998), it is possible that SQPV was transmitted between these species at an earlier time, and has subsequently been circulating unnoticed in red squirrel populations in Northern Canada. However, there is some indication that there may be several different poxviruses capable of infecting North American tree squirrel species, as is evidenced by the identification of an unusual poxvirus in two western grey squirrels (*Sciurus griseus*; Regnery, 1975), a species that is, for the most part, geographically separated from eastern

grey squirrels (Carraway and Verts, 1994; Koprowski, 1994). Given the sparse human habitation of Yukon Territory, and the inconspicuous nature of tree squirrel species, it is not inconceivable that a previously unrecognized poxvirus could be present in red squirrels in that area. Alternatively, given the severity of disease in this squirrel and the fact that it is, thus far, the only reported case, the possibility of a wildlife reservoir for this virus, other than the red squirrel, should be considered.

In conclusion, we describe the first account of poxvirus-associated disease in Canadian squirrels outside of Ontario. Although initial molecular analysis suggests that the etiologic agent may be novel poxvirus, only further surveillance of North American red squirrels and molecular characterization of the causal virus will reveal the true identity, distribution, and significance of this disease.

The authors would like to thank Colin J. McInnes, Head of Virology, Moredun Research Institute, Edinburgh, UK, for contributing a sample of SQPV DNA.

#### LITERATURE CITED

- CARRAWAY, L. N., AND B. J. VERTS. 1994. *Sciurus griseus*. Mammalian Species 474: 1–7.
- CARROLL, B., P. RUSSELL, J. GURNELL, P. NETTLETON, AND A. W. SAINSBURY. 2008. Epidemics of squirrelpox virus disease in red squirrels (*Sciurus vulgaris*): Temporal and serological findings. *Epidemiology and Infection* 137: 257–265.
- GINN, P. E., J. E. K. L. MANSELL, AND P. M. RAKICH. 2007. Skin and appendages. In Jubb, Kennedy, and Palmer's pathology of domestic animals. 5th Edition, G. E. Maxie (ed.). Elsevier, Edinburgh, UK, pp. 553–781.
- HIRTH, R. S., D. S. WYAND, A. D. OSBORNE, AND C. N. BURKE. 1969. Epidermal changes caused by squirrel poxvirus. *Journal of the American Veterinary Medical Association* 155: 1120–1125.
- KING, J. M., A. WOOLF, AND J. N. SHIVELY. 1972. Naturally occurring squirrel fibroma with involvement of internal organs. *Journal of Wildlife Diseases* 8: 321–324.
- KOPROWSKI, J. L. 1994. *Sciurus carolinensis*. Mammalian Species 480: 1–9.
- MCINNES, C. J., A. R. WOOD, K. THOMAS, A. W. SAINSBURY, J. GURNELL, F. J. DEIN, AND P. F. NETTLETON. 2006. Genomic characterization of a novel poxvirus contributing to the decline of the red squirrel (*Sciurus vulgaris*) in the UK. *Journal of General Virology* 87: 2115–2125.
- O'CONNOR, D. J., R. W. DITERS, AND S. W. NIELSEN. 1980. Poxvirus and multiple tumors in an eastern gray squirrel. *Journal of the American Veterinary Medical Association* 177: 792–795.
- REGNERY, R. L. 1975. Preliminary studies on an unusual poxvirus of the western grey squirrel (*Sciurus griseus griseus*) of North America. *Intervirology* 5: 364–366.
- ROBINSON, A. J., AND P. J. KERR. 2001. Poxvirus infections. In *Infectious diseases of wild mammals*. 3rd Edition, E. S. Williams and I. K. Barker (eds.). Blackwell Publishing, Ames, Iowa, pp. 179–201.
- SAINSBURY, A. W., AND J. GURNELL. 1995. An investigation into the health and welfare of red squirrels, *Sciurus vulgaris*, involved in reintroduction studies. *Veterinary Record* 137: 367–370.
- SAINSBURY, T., AND L. WARD. 1996. Parapoxvirus infection in red squirrels. *Veterinary Record* 138: 400.
- SIMON, J., AND R. K. BULLARD. 1973. Transmissible fibroma of grey squirrels (a case report). *Veterinary Medicine Small Animal Clinics* 68: 1282–1283.
- STEELE, M. A. 1998. *Tamiasciurus hudsonicus*. Mammalian Species 586: 1–9.
- TERRELL, S. P., D. J. FORRESTER, H. MEDEKER, AND T. W. REGAN. 2002. An epizootic of fibromatosis in gray squirrels (*Sciurus carolinensis*) in Florida. *Journal of Wildlife Diseases* 38: 305–312.
- THOMAS, K., D. M. TOMPKINS, A. W. SAINSBURY, A. R. WOOD, R. DALZIEL, P. F. NETTLETON, AND C. J. MCINNES. 2003. A novel poxvirus lethal to red squirrels (*Sciurus vulgaris*). *Journal of General Virology* 84: 3337–3341.

*Received for publication 26 January 2009.*