

GENITAL HERPESVIRUS IN BOTTLENOSE DOLPHINS (TURSIOPS TRUNCATUS): CULTIVATION, EPIDEMIOLOGY, AND ASSOCIATED PATHOLOGY

Authors: van Elk, Cornelis E., van de Bildt, Marco W. G., de Jong, Antonius A. W., Osterhaus, Albert D. M. E., and Kuiken, Thijs

Source: Journal of Wildlife Diseases, 45(4) : 895-906

Published By: Wildlife Disease Association

URL: <https://doi.org/10.7589/0090-3558-45.4.895>

BioOne Complete (complete.BioOne.org) is a full-text database of 200 subscribed and open-access titles in the biological, ecological, and environmental sciences published by nonprofit societies, associations, museums, institutions, and presses.

Your use of this PDF, the BioOne Complete website, and all posted and associated content indicates your acceptance of BioOne's Terms of Use, available at www.bioone.org/terms-of-use.

Usage of BioOne Complete content is strictly limited to personal, educational, and non - commercial use. Commercial inquiries or rights and permissions requests should be directed to the individual publisher as copyright holder.

BioOne sees sustainable scholarly publishing as an inherently collaborative enterprise connecting authors, nonprofit publishers, academic institutions, research libraries, and research funders in the common goal of maximizing access to critical research.

GENITAL HERPESVIRUS IN BOTTLENOSE DOLPHINS (*Tursiops truncatus*): CULTIVATION, EPIDEMIOLOGY, AND ASSOCIATED PATHOLOGY

Cornelis E. van Elk,¹ Marco W. G. van de Bildt,² Antonius A. W. de Jong,²
Albert D. M. E. Osterhaus,² and Thijs Kuiken^{2,3}

¹ Dolfinarium Harderwijk, Strandboulevard Oost 1, Harderwijk, 3841 AB, Netherlands

² Erasmus Medical Centre, Dr. Molewaterplein 50, Rotterdam, 3000 CA, Netherlands

³ Corresponding author (email: t.kuiken@erasmusmc.nl)

ABSTRACT: We studied the pathology, epidemiology, and clinical significance of genital herpesvirus infection in a zoo collection of bottlenose dolphins (*Tursiops truncatus*). Samples from the genital mucosa of male ($n=21$) and female ($n=15$) dolphins were tested by nested polymerase chain reaction (PCR) targeting the DNA polymerase of herpesvirus. Herpesvirus infection was significantly associated with the occurrence of mucosal plaques on penis ($n=3$) or vulva ($n=4$). Biopsies from a penile plaque showed epithelial hyperplasia by histology, contained herpesvirus-like particles by electron microscopy, and tested positive for herpesvirus by PCR. Herpesvirus was successfully cultivated from penile plaque samples and identified as a member of the *Gammaherpesvirinae* by DNA sequencing and phylogenetic analysis. We used the newly cultivated bottlenose dolphin herpesvirus (TTHV) to develop a direct enzyme-linked immunosorbent assay for anti-TTHV antibodies in banked sera of these dolphins. The percentage of positive samples was higher in adults (20/21, 95%) than in juveniles (7/15, 47%). Seroconversion occurred around the age of onset of sexual behavior. Although herpesvirus infection has been associated with abortion, perinatal mortality, and urogenital neoplasia in other species, we found no evidence of herpesvirus infection by PCR in tissues from six cases of abortion and perinatal mortality, and no diagnoses of urogenital tumors in 24 bottlenose dolphins from this zoo collection that died since 1990. Together, we here report the first successful cultivation from bottlenose dolphins of a herpesvirus that probably causes benign genital plaques, is endemic in this group of dolphins, and is likely transmitted by sexual contact.

Key words: Bottlenose dolphins, cultivation, enzyme-linked immunosorbent assay, genital mucosa, herpesvirus, pathology, polymerase chain reaction, *Tursiops truncatus*.

INTRODUCTION

Herpesviruses are widely disseminated in nature. Upon examination, most animal species yield at least one and frequently several distinct herpesviruses. Herpesviruses are well adapted to their natural hosts, and infections in immunocompetent individuals are rarely fatal (Pellet and Roizman, 2007). Cetacean species have been found to be infected with herpesvirus by various methods. Associated lesions vary in location and severity. By phylogenetic analysis of the partial DNA polymerase coding sequence detected by polymerase chain reaction (PCR), these viruses belong to the alpha and gamma families of herpesviruses. Herpesvirus has never been cultivated from cetaceans. Skin lesions in beluga whales (*Delphinapterus leucas*; Martineau et al., 1988; Barr

et al., 1989) and bottlenose dolphins (*Tursiops truncatus*; Manire et al., 2006) contained herpesvirus-like particles observed by electron microscopy. In addition, skin and oral lesions from bottlenose dolphins contained herpesviral DNA by PCR that was classified as belonging to an alphaherpesvirus (Smolarek Benson et al., 2006). Encephalitis in a harbor porpoise (*Phocoena phocoena*) was caused by herpesvirus infection as demonstrated by immunohistochemistry and electron microscopy (Kennedy et al., 1992). A disseminated herpesvirus infection was observed in two bottlenose dolphins with necrotizing lesions and eosinophilic intranuclear inclusion bodies in multiple organs. Lesions contained herpesvirus-like particles by electron microscopy and herpesvirus DNA by PCR belonging to the family of alphaherpesviruses (Blan-

chard et al., 2001). Genital lesions associated with herpesvirus infection have been found in three cetacean species. A penis lesion in a Blainville's beaked whale (*Mesoplodon densirostris*) had basophilic intranuclear inclusion bodies and contained herpesviral DNA by PCR that was classified as belonging to a gammaherpesvirus (Saliki et al., 2006). Genital lesions from five bottlenose dolphins and one Risso's dolphin (*Grampus griseus*) contained herpesvirus DNA by PCR that were classified as belonging to gamma-herpesviruses (Smolarek Benson et al., 2006).

Besides benign proliferative lesions in the genital mucosa, genital herpesvirus infection is a known cause of severe clinical disease. Genital herpesvirus infections can occur in the gravid uterus and the neonate upon birth, and they may be dangerous because neither fetus nor neonate is immunocompetent (Avgil and Ornoy, 2006). Herpesvirus infection has been described as a cause of abortion, stillbirth, and neonatal disease in cattle, pigs, dogs, horses, and humans (Avgil and Ornoy, 2006; Foster, 2007; Schlafer and Miller, 2007). In California sea lions (*Zalophus californianus*), genital herpesvirus infection also has been implicated in the development of urogenital tumors, which are a significant cause of morbidity and mortality in this species (King et al., 2002).

Our goals in this study were first, to determine the etiology of lesions observed in the genital mucosa of bottlenose dolphins in a zoo collection; second, to investigate the epidemiology of the detected herpesvirus infection; and, third, to investigate whether infection with this herpesvirus could be linked to perinatal mortality or urogenital neoplasia.

MATERIALS AND METHODS

Bottlenose dolphins

The zoo collection of bottlenose dolphins under investigation consisted of 36 individuals.

Based on sexual maturity at 10 yr of age (Robeck et al., 2008), there were 15 females (11 adults and four juveniles) and 21 males (10 adults and 11 juveniles) (Table 1). This group consisted of wild-caught dolphins from the Gulf of Mexico ($n=7$), the waters around Cuba ($n=1$), and the Atlantic coast of Florida ($n=1$), as well as captive-bred dolphins ($n=27$). The dolphins were held in two marine mammal parks, one park in the Netherlands and the other park in France. The marine mammal park in the Netherlands consisted of two basins with volumes of 4 and 12 million liters and that in France of one basin with a volume of 4 million liters. These were filled with either fresh water supplemented with sodium chloride or with artificial seawater. Water was sand filtered and either chlorinated or disinfected using ultraviolet light. The dolphins were fed on different species of thawed frozen fish and squid, supplemented with vitamin B and E. All dolphins were under close daily supervision during training by experienced staff, and they were inspected at least once per week by a registered veterinarian. Throughout the history of both parks, dolphins had been exchanged between the two parks and with other facilities for breeding purposes. At the time of this investigation, October 2007–October 2008, all dolphins from both parks were kept together in the Netherlands.

Samples of genital mucosa

From 34 dolphins, samples were collected in duplicate from the genital slit (which is present in both females and males) by use of a cotton swab. One cotton swab was placed in a vial with 1 ml of virus transport medium (Hanks' balanced salt solution [Hanks' minimal essential medium, HMEM] containing 10% glycerol, 200 international units/ml penicillin, 200 µg/ml streptomycin, 100 U/ml polymyxin B sulphate, and 250 µg/ml gentamicin) for virus culture and stored at room temperature until processing. The other cotton swab was placed in a vial with 0.5 ml of lysis buffer (High Pure Viral Nucleic Acid Kit, Roche Diagnostics GmbH, Mannheim, Germany) for PCR and stored at room temperature until processing. Two males with visible lesions in the penis mucosa (5 and 34) were sampled in duplicate by scraping a plastic bacteriology loop across the lesion. The plastic loops were shaken in vials containing either HMEM for virus culture or lysis buffer for PCR. One male (19) developed a penile lesion during the study period and was sampled on three occasions: first, by use of cotton swabs;

TABLE 1. Detection of herpesvirus infection and associated plaques in genital mucosa of bottlenose dolphins by polymerase chain reaction (PCR) and macroscopic inspection, as well as serologic evidence of herpesvirus infection based on enzyme-linked immunosorbent assay (ELISA) in oldest and most recent available samples from serum bank.

Dolphin				Genital mucosa ^d		Herpes ELISA				
						Age at sampling (yr)		Titer ^e		Seroconversion
Age category and gender ^a	No.	Origin ^b	Yr of birth ^c	Herpes PCR	Gross lesion	First sample	Second sample	First sample	Second sample	Between ages
Adult female	1	WC	1962 (est.)	N	N	33	46	>160	>160	13–14
	8	WC	1967 (est.)	P	P	27	41	>160	>160	
	31	WC	1973 (est.)	N	N		35		>160	
	16	WC	1977 (est.)	P	P	25	31	>160	>160	
	3	WC	1982 (est.)	N	N	12	26	>160	>160	
	2	WC	1983 (est.)	P	P	13	25	N	>160	
	15	CB	1987	N	N	11	21	>160	>160	
	13	CB	1989	N	N	8	19	>160	>160	
	10	CB	1992	N	N	6	16	>160	>160	
	9	CB	1992	N	N	10	16	>160	>160	
Juv. female	35	CB	1996	P	N		12		N	4–5
	36	CB	1999	P	P		9		N	
	21	CB	2001	N	N	3	7	N	>160	
	29	CB	2003	N	N	4	5	N	N	
	27	CB	2005	N	N	1	3	N	N	
Adult male	6	WC	1963 (est.)	N	N	31	45	>160	>160	6–9
	5	WC	1974 (est.)	P	P	20	34	>160	>160	
	12	WC	1983 (est.)	N	N	15	25	>160	>160	
	34	WC	1988 (est.)	P	P	19	20	>160	>160	
	11	CB	1981	N	N	17	27	>160	>160	
	14	CB	1984	N	ne	6	24	40	>160	
	4	CB	1984	N	N	9	24	80	>160	
	7	CB	1989	N	N	6	19	N	>160	
	17	CB	1998	N	ne	4	10	>160	>160	
	18	CB	1998	N	N	9	10	>160	>160	
Juv. male	32	CB	1999	N	N		9		N	3–4
	19	CB	2001	P ^f	P ^g	1	7	N	N	
	20	CB	2001	N	ne	3	7	N	>160	
	22	CB	2001	P	ne	1	7	N	>160	
	23	CB	2002	N	N	2	6	>160	>160	2–3
	24	CB	2004	N	ne	2	4	N	>160	
	30	CB	2004	N	N		4		N	
	33	CB	2004	N	N		4		N	
	25	CB	2005	N	ne	1	3	N	>160	
	26	CB	2005	N	ne	1	3	>160	>160	
	28	CB	2005	N	ne		3		N	

^a Juv. = Juvenile.

^b WC = wild-caught; CB = captive-born.

^c Est. = estimated.

^d P = positive; N = negative; ne = not examined.

^e Value is dilution at which sample signal still more than twice control signal; N = sample signal less than twice control signal.

^f Negative in March 2008, but positive in October 2008, after penile plaque had developed.

^g No gross lesion visible before 8 September 2008 but visible on 25 September 2008.

second (after the penile lesion was detected), by use of plastic loops; and third, by use of disposable pulmonary biopsy forceps oval cup, outer diameter 1.8 mm (ConMed Endoscopy Technologies Inc., Billerica, Massachusetts, USA). On the third occasion, three tissue samples were taken at the edge of the lesion, two samples for histology, and one sample for PCR.

Serum samples

Serum samples from each of the 36 dolphins had been collected as part of routine health evaluation. After collection of blood in a serum separation tube and clotting, the tubes were centrifuged at $20,000 \times G$ for 5 min, and obtained serum was archived at -20°C .

Organ samples

Organ samples from four cases of perinatal mortality and two abortions were stored frozen at -70°C until processing for herpesvirus PCR. These six cases were two aborted fetuses (3 and 6 mo old), two stillborn calves, one calf with a bilateral microphthalmia, and one calf that failed to thrive. Organs sampled were brain, lung, spleen (except from the 3-mo-old aborted fetus), liver (except from one stillborn calf), and placenta (except from the nonthriving calf). The 6-mo-old aborted fetus was severely damaged before it could be retrieved from the basin; thus, alternative samples were collected: placenta, heart, stomach, and adrenal gland.

Inspection of genital mucosa

The genital mucosa was inspected for the presence of lesions. In males, this was done during voluntary or spontaneous penis extrusion. In females, which all voluntarily presented the genital slit, the genital mucosa was exposed by spreading the genital slit by hand and shining a light onto the mucosa.

The frequency at which the genital mucosa was inspected during the study period varied per dolphin. In males, dolphins 12, 5, 6, 11, 7, 4, and 18, which were trained to extrude the penis voluntarily for semen collection, were inspected at least four times a month during the whole study period; dolphins 23 and 19 were inspected four times during September 2008; dolphin 34 was inspected twice during the study period; dolphins 32, 30, and 33 were inspected minimally once during spontaneous penis extrusion; and dolphins 14, 17, 20, 22, 24, 25, 26, and 28 were not examined. In females, the genital mucosa of each dolphin was inspected once during the study period.

Virus culture

Within 48 hr of sampling, 60 μl of virus transport medium that held the cotton swab of the genital mucosa (dolphins 16, 26, and 35) or the material scraped from a macroscopic male genital mucosal lesion (dolphins 34 and 5) was inoculated for 1 hr at 37°C on each of the following cell lines: primary harbor porpoise kidney cell cultures (PPki), primary bottlenose dolphin kidney cell cultures (TTki), Madin-Darby bovine kidney cells (MDBK), Madin-Darby canine kidney cells (MDCK), and Crandell feline kidney cells (CrFK). Cultures were washed twice with culture medium. Cultures were washed twice with Dulbecco's modified Eagle's medium supplemented with antibiotics and 10% fetal calf serum and incubated at 37°C humid atmosphere with 5% CO_2 . Cultures were checked daily for cytopathologic changes for a maximum of 10 days. At least three passages were made before cultures were considered negative. At the end of each passage, all cultures were tested for the presence of herpesviral DNA by PCR.

Electron microscopy

The fourth passage of PPki cells inoculated with a genital mucosa sample from dolphin 34 was fixed in 4% formaldehyde and 1% glutaraldehyde and postfixed in 1% osmium tetroxide. After embedding in epoxy resin, thin sections were prepared, stained with 6% saturated uranyl acetate and lead citrate, and examined with a Philips Morgagni 268D electron microscope (F.E.I., Brno, Czech Republic). Formalin-fixed, paraffin-embedded biopsies of the penile lesion of dolphin 19 were deparaffinized and processed in the same manner as the PPki samples.

Histology

Biopsy samples of the penile lesion of dolphin 19 were fixed in 10% neutral-buffered formalin, routinely processed, and embedded in paraffin. Five-micrometer-thick sections were mounted on glass slides and stained with hematoxylin and eosin (H&E).

Herpesvirus PCR and nucleotide sequencing

From the genital mucosa samples collected in lysis buffer and from the biopsies obtained from the genital lesion of dolphin 19, DNA was isolated using the High Pure Viral Nucleic Acid Kit (Roche Diagnostics, GmbH), following the protocol provided by the manufacturer. A nested herpesvirus PCR was performed as described previously (VanDevanter et al., 1996). In brief, two forward primers (HV-F1:

5'-GAYTTYGCNAGYYTNTAYCC-3' and HV-F2: 5'-TCCTGGACAAGCAGARNYSG-CNMTNAA-3') and one reverse primer (HV-R1: 5'-GTCTTGCTCACCAGNTCNACNC-CYTT-3') were used in the first PCR. An aliquot of 2 µl from the first PCR reaction was used for a nested PCR with one forward primer (HV-F3: 5'-TGTAAC TCGGTG-TAYGGNTTYACNNGNGT-3') and one reverse primer (HV-R2: 5'-CACAGAGTCC-GTRTCNCCRTANAT-3'). Products of the PCR reactions were checked by electrophoresis on a 2% agarose gel for fragments of the correct size. Automated sequencing of PCR fragments was performed on an ABI 3130XL genetic analyzer with the Big Dye Terminator Cycle Sequencing Kit (Applied Biosystems, Foster City, California, USA) using the primers F3 and F2 for the fragments of the nested PCR and primers F1, R1, and R2 if a PCR fragment from the first PCR was available. For identification of sequenced fragments, the BLAST option of the National Center for Biotechnology Information website was used (<http://www.ncbi.nlm.nih.gov/>). For phylogenetic analysis, the SEQBOOT and DNAML programs of the Phylip package were used (Felsenstein, 2004).

Papillomavirus PCR

Because papillomavirus is known to cause genital lesions in bottlenose dolphins (Rehtanz et al., 2006), a papillomavirus PCR was performed on all genital mucosa samples collected in lysis buffer using primers MY11/MY09 (Manos et al., 1989) and GP5⁺/GP6⁺ (de Roda Husman et al., 1995). This PCR had been successful in detecting DNA of two *Phocoena spinipensis* papillomaviruses, one of which is closely related to bottlenose dolphin papillomavirus 2 (Van Bresseem et al., 2007).

Herpesvirus serology

A Nonidet-P40 (NP-40) cell lysate was prepared using the fourth passage of PPki cells infected with the herpesvirus isolated from dolphin 34 (named TTHV). This cell lysate, diluted in phosphate-buffered saline (PBS), was used as antigen coating for enzyme-linked immunosorbent assay (ELISA). Antigen coating was incubated overnight at room temperature in 96-well ELISA plates. Checkerboard titrations with a serum pool from PCR-positive dolphins were performed to determine optimal dilution of the antigen coating and the conjugate. Serum samples were tested in serial 2 log dilutions on a coating with TTHV/NL/08-01-infected PPki cells and on a coating of uninfected PPki cells.

As a conjugate, horseradish peroxidase-labeled protein A was used. The ELISA buffer used for dilution of the sera and conjugate was PBS, 0.5% bovine serum albumin, 1% powdered milk, and 0.05% Tween 20. Serum and conjugate were incubated for 1 hr at 37 C. Tetramethylbenzidine was used as a substrate. Color reaction was stopped after 10 min using sulfuric acid, and absorbance was measured at 450 nm. Samples with a signal of 2 times the background or higher, at titers equal to or greater than 20, were considered positive. Of each of the 36 dolphins, the most recent and the oldest serum samples available were checked to investigate how long the infection had been present. Annual samples, as available, for six dolphins (dolphins 2, 21, 7, 20, 24, and 25) that had seroconverted in this time period, were checked to determine the age of seroconversion more precisely.

Retrospective analysis of necropsy reports

Gammaherpesvirus infection has been associated with the development of urogenital tumors in California sea lions (King et al., 2002). Therefore, available necropsy reports of animals that died since 1993 (10 female adults, two male adults, five female juveniles or neonates, and seven male juveniles or neonates) were reviewed for diagnosis of urogenital neoplasia.

Statistical analysis

We used Fisher's exact test (Zar, 1996) to examine the hypotheses that 1) a positive herpesvirus PCR was independent of presence of macroscopically visible lesions in the genital mucosa and 2) the occurrence of an antibody titer was independent of age class.

RESULTS

Inspection of genital mucosa

Macroscopic lesions were observed in the penile mucosa of three of 13 male dolphins and in the vulval mucosa of four of 15 female dolphins (Table 1). These lesions were single or multiple plaques that were pale yellow to white, with an irregular shape, a smooth surface, and raised 1–7 mm (males) or 1–4 mm (females) above the surrounding mucosa (Fig. 1). The plaques ranged in diameter from 5 mm to 50 mm in males and 5 mm to 20 mm in females. In 27 of 28 dolphins, the presence of a macroscopically visible

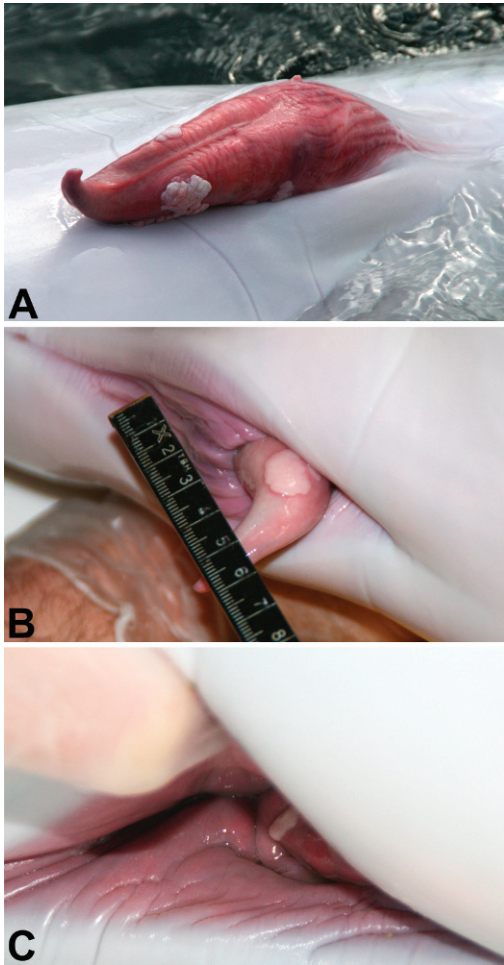


FIGURE 1. Plaques associated with herpesvirus infection in the genital mucosa of bottlenose dolphins. A. Adult male (34) with two plaques on penile mucosa. B. Juvenile male (19) in which plaque on penile mucosa occurred during study period. C. Juvenile female (36) with plaque on vulvar mucosa.

genital lesion was associated with a positive herpes PCR ($P < 0.001$, Fisher's exact test; see below).

In most of the dolphins, genital plaques were already seen at the first observation during the study period. However, in dolphin 19, a penile plaque occurred between observations on 8 and 25 September 2008 (Fig. 1).

Virus culture

On day 3 after inoculation during the first passage, patches of cytopathic effect

(CPE) were visible in PPki cell cultures of samples from dolphins 34 and 5. Over the next 4 days, this CPE became confluent. Supernatant and cells were checked by herpesvirus PCR and passaged onto fresh PPki cell cultures, resulting in CPE similar to that in the first passage. These cultures were positive for bottlenose dolphin gamma-herpesvirus by PCR and sequencing of the PCR products (see below).

No herpesvirus was detected by CPE or herpesvirus PCR in PPki cells inoculated with the three samples, from dolphins 16, 26, and 35. No herpesvirus was detected by CPE or PCR in any of the five samples by use of TTki, MDBK, MDCK, or CrFK cells.

Electron microscopy

Nuclei of PPki cells inoculated with a genital mucosa sample from dolphin 34 contained many round or hexagonal particles with a consistent diameter of approximately 100 nm (Fig. 2). Some particles had a round, electron-dense core, whereas others were empty. Size, shape, and location of these particles are consistent with herpesvirus nucleocapsids (Doane and Anderson, 1987).

Epithelial cells at the surface of the mucosal biopsy sample of the penile lesion of dolphin 19, corresponding with the hypereosinophilic layer seen by light microscopy, contained round or hexagonal unenveloped particles with a consistent diameter of approximately 100 nm and an electron-dense or electron-lucent core. In the intercellular space between adjacent epithelial cells were enveloped virus particles. Size, shape, and location of these particles are consistent with herpesvirus nucleocapsids (Doane and Anderson, 1987). The affected cells were characterized by fragmentation of the nucleus, condensation of chromatin, and vacuolization of the cytoplasm (Fig. 3).

Histology

The biopsy sample of the penile lesion contained the full thickness of the epithelium and was approximately 100 cells thick,

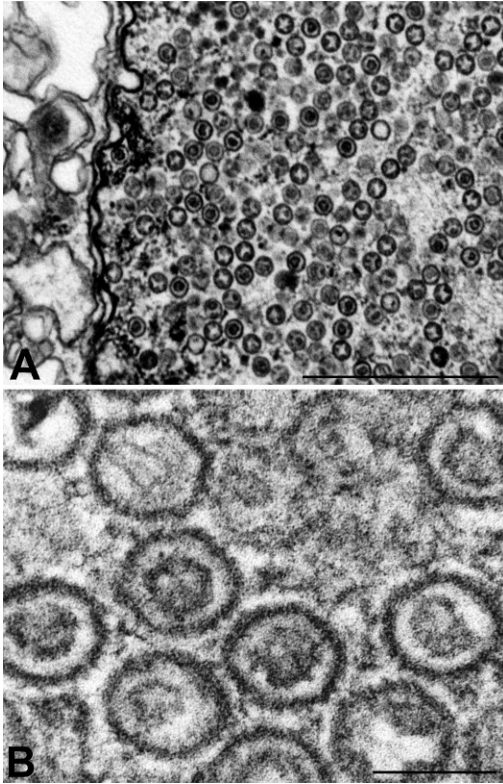


FIGURE 2. Transmission electron micrographs of primary cell culture of harbor porpoise kidney cells inoculated with penile plaque scraping from bottlenose dolphin 34. Uranyl acid and lead citrate stain. A. Many herpesvirus nucleocapsids are present in the nucleus. Bar=1,000 nm. B. Detail of A, showing round to hexagonal shape of nucleocapsids, some with electron-dense core. Bar=100 nm.

with scant subjacent connective tissue. The epithelium showed moderate hyperplasia, disorganization of the histologic architecture, and prominent papillae of the lamina propria. In general, the epithelial cells were large and polygonal, with distinct borders, abundant pale eosinophilic, finely vacuolated cytoplasm and large, centrally located, and oval nuclei with one or two prominent basophilic nucleoli. Adjacent to the basement membrane, the epithelial cells had more basophilic nuclei and a few had mitotic figures, consistent with epithelial hyperplasia. In the middle layer of the epithelium, some cells had perinuclear cytoplasmic vacuolation and nuclear condensation. At the surface of the epithelium

was a 10-cell-thick layer of cells with progressive flattening, eosinophilia of the cytoplasm, and fragmentation and condensation of the nucleus. At the transition of this hypereosinophilic cell layer and the underlying epithelium, the cell nuclei had margined chromatin and an eosinophilic core. These cores were suggestive of intranuclear inclusion bodies, but most lacked a clear halo (Figs. 4, 5).

Herpesvirus PCR and DNA sequencing

In nine of 36 dolphins, herpesvirus was detected in genital mucosa samples by PCR and subsequent sequencing of the PCR product (Table 1). Full analysis of the PCR products of four samples (dolphins 5, 16, 19, and 34) demonstrated a 356-nucleotide fragment of the polymerase gene, showing 100% identity with a bottlenose dolphin gammaherpesvirus from bottlenose dolphins stranded on the Florida Keys and 91% identity with a gammaherpesvirus from bottlenose dolphins stranded on the Atlantic side of Florida or North Carolina (Fig. 6).

All organ samples of the four cases of perinatal mortality and two abortions were negative for herpesvirus by PCR.

Papillomavirus PCR

All 36 genital mucosa samples were negative for papillomavirus by PCR.

Herpesvirus serology

By ELISA using the virus isolate TTHV/NL/08-01 as antigen, seven of 15 (47%) juvenile dolphins had specific antibodies to bottlenose dolphin gammaherpesvirus in the most recently collected sera, all with titers >160. In comparison, 20 of 21 (95%) adult dolphins had specific antibodies, also all with titers >160 (Table 1). The proportion of seropositive animals was significantly higher in adults than in juveniles ($P<0.001$, Fisher's exact test).

In the time between the dates of collection of the oldest and most recent sera, seroconversion occurred in seven

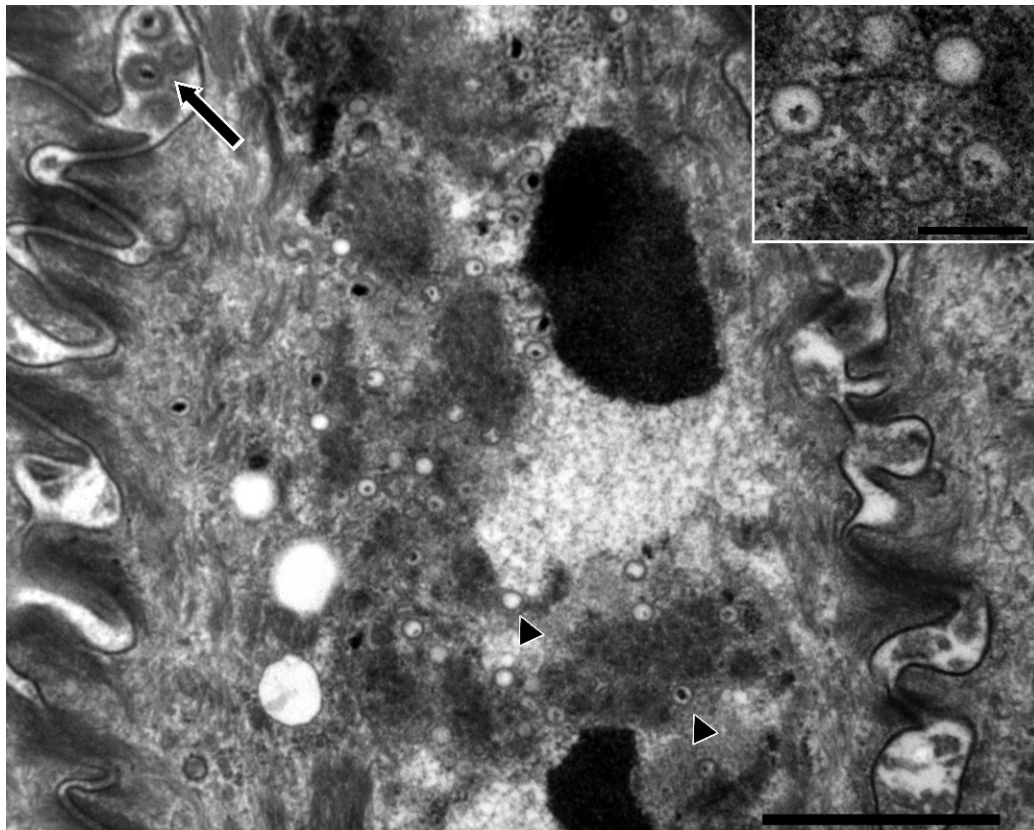


FIGURE 3. Transmission electron micrographs of superficial epithelial cells in biopsy of penis plaque from dolphin 19, showing unenveloped viral nucleocapsids (arrowheads) in the cell and enveloped nucleocapsids (arrow) in the intercellular space. Note the lack of nuclear membrane, the electron-dense clumps of condensed chromatin and the cytoplasmic vacuoles. Uranyl acetate and lead citrate. Bar=1,000 nm. Inset. Detail of unenveloped viral nucleocapsids with a diameter of approximately 100 nm. Bar=200 nm.

dolphins, six of which were juveniles. Based on analysis of annual samples the youngest female to have seroconverted was 5 yr old. The youngest male was 1 yr old. The oldest female without detectable antibodies was 13 yr old, and the oldest male was 9 yr old.

Retrospective analysis of necropsy reports for diagnosis of urogenital neoplasia

Urogenital tumors were not diagnosed in any of these necropsy reports. The only tumor diagnosed was an adrenal adenocarcinoma in a geriatric male.

DISCUSSION

We report the first successful cultivation of a herpesvirus from bottlenose dolphins

or any other cetacean species. The availability of a culture of this bottlenose dolphin herpesvirus (TTHV) opens new avenues in virus characterization, development of diagnostic methods, understanding of pathogenesis, and vaccine development for TTHV infection in bottlenose dolphins. As a first step in improving diagnosis, we developed an ELISA to detect specific antibodies in serum.

The production of infectious progeny virus by herpesviruses is accompanied by destruction of the infected cell (Pellet and Roizman, 2007). Epithelial herpesvirus infections are therefore commonly accompanied by destruction of the epithelium, necrosis, and ulceration. Hyperplasia with prominent papillae of the lamina propria

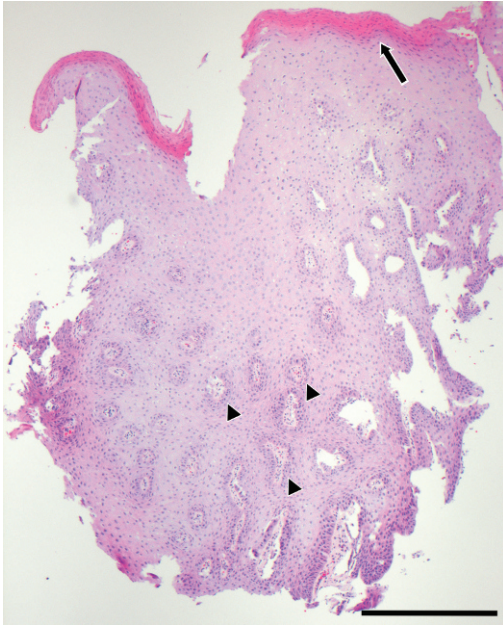


FIGURE 4. Biopsy of penis plaque from dolphin 19, showing epithelial hyperplasia. Note the disorganized histologic architecture, prominent papillae of the lamina propria (arrowheads) and the hyper eosinophilic superficial cell layer (arrow). H&E. Bar=500 μ m.

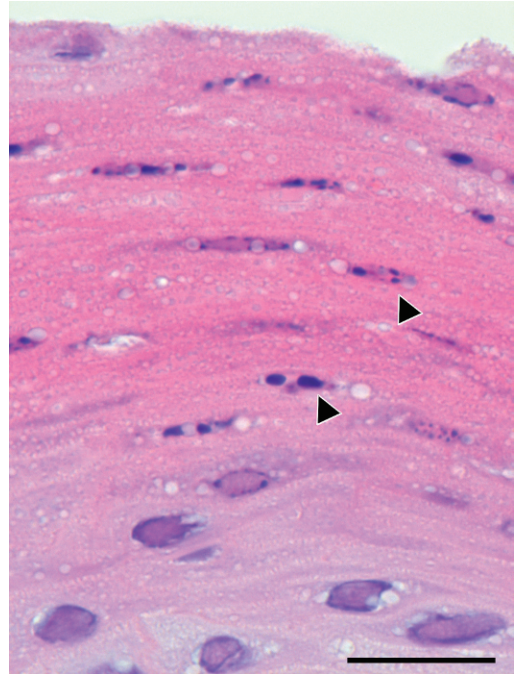


FIGURE 5. Detail of Figure 4, showing hyper eosinophilic superficial cell layer. The cells with fragmented nuclei and condensed chromatin (arrowheads) correspond with the epithelial cells in which herpesvirus-like particles were detected by electron microscopy. H&E. Bar=20 μ m.

and perinuclear vacuolation is more reminiscent of lesions caused by papillomavirus (Pamela et al., 2007). However herpesvirus has been associated with hyperplasia and papillomas in Neotropical parrots (Styles et al., 2004), cloacal papillomas in parrots (Johne et al., 2002), a papilloma-like penile lesion in a Blainville's beaked whale (*Mesoplodon densirostris*; Saliki et al., 2006), and fibropapillomatosis in marine turtles (Norton et al., 1990; Quackenbush et al., 1998). Although in parrots papillomavirus was initially suspected to be causative for the papillomas, it could not be detected in two investigations into the etiology (Johne et al., 2002; Styles et al., 2004).

Our study provides strong evidence that infection with TTHV/NL/08-01 causes genital plaques in bottlenose dolphins. First, in 27 of 28 dolphins, the result of herpesvirus PCR on genital samples correctly predicted the presence of genital

plaques. Second, one bottlenose dolphin (19) developed a genital plaque in the same period that the genital sample became positive by herpesvirus PCR, and the products of this herpesvirus PCR were identical to that of the newly isolated TTHV. Third, biopsies of the plaque of bottlenose dolphin 19 contained herpesvirus polymerase encoding DNA and herpesvirus particles in the lesion. No other viruses were noted despite extensive examination of the sample by electron microscopy. Finally, the results of our study correspond with a previous study where a closely related or identical herpesvirus was detected by PCR in localized genital lesions of bottlenose dolphins (Smolarek Benson et al., 2006).

Although papillomavirus has been associated with genital lesions in bottlenose dolphins (Rehtanz et al., 2006), we found no evidence of papillomavirus infection in

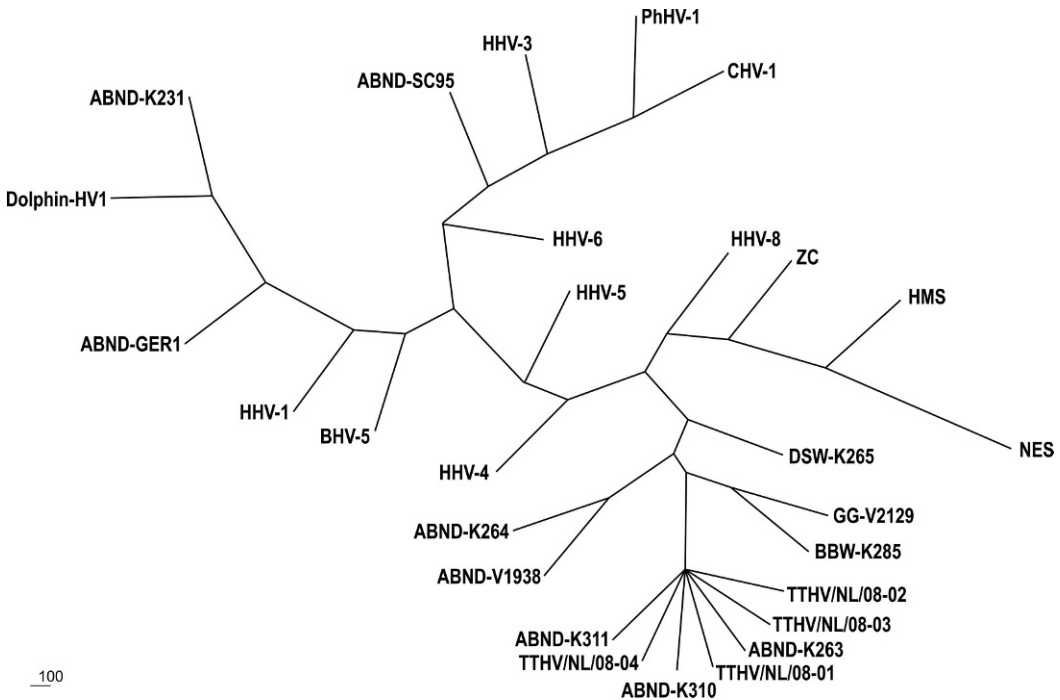


FIGURE 6. Unrooted phylogenetic tree of polymerase gene fragments for comparison of bottlenose dolphin herpesviruses from this study with bottlenose dolphin herpesviruses from previous studies, herpesviruses from other marine mammal species, and representative human and canine herpesviruses. Nucleotide sequences were subjected to bootstrapped ($n=500$) maximum likelihood analysis using the Phylip package. The consensus tree is shown. GenBank accession numbers are given in parentheses: ABND-K263, bottlenose dolphin K263, USA captive (AY952777); ABND-K310, bottlenose dolphin K310 tongue lesion, USA stranded Florida Keys (AY952779); ABND-K311, bottlenose dolphin K311, USA captive (AY949831); DSW-K265, dwarf sperm whale (*Kogia simus*) K265, USA (AY949830); ABND-V1938, bottlenose dolphin V1938, USA stranded North Carolina (DQ288667); ABND-K264, bottlenose dolphin K264, USA stranded Jacksonville Florida (AY952776); HHV-4, Human herpesvirus 4, EBV (AJ507799); BBW-K285, Blainville's beaked whale (*Mesoplodon densirostris*), USA stranded Kure Beach, North Carolina (AY949828); GG-V2129, Risso's dolphin (*Grampus griseus*), USA stranded Gulf of Mexico Florida, 2005 (DQ288666); NES, northern elephant seal (*Mirounga angustirostris*), USA (DQ183057); HMS, Hawaiian monk seal (*Monachus schauinslandi*), USA (DQ093191); ZC, California sea lion (*Zalophus californianus*), USA (AF236050); HHV-8, Human herpes virus 8 (AF148805); TTHV/NL/08-01, Bottlenose dolphin 34, Netherlands, captive (GQ258353); TTHV/NL/08-02, bottlenose dolphin 5, Netherlands, captive (GQ258354); TTHV/NL/08-03, bottlenose dolphin 16, Netherlands, captive (GQ258355); TTHV/NL/08-04, bottlenose dolphin 19, Netherlands, captive (GQ258356); CHV-1, Canine herpesvirus 1 (AY949827); PhHV-1, Phocine herpesvirus type 1, Pacific (U92269); HHV-3, Human herpesvirus 3, VZV (X04370); ABND-SC95, bottlenose dolphin, USA (AF245443); BHV-5, bovine herpesvirus 5, strain SV507/99 (AY261359); HHV-1, human herpesvirus 1, HSV-1, (AB070848); ABND-GER1, bottlenose dolphin, Germany (AY608707); DOLPHIN-HV1, bottlenose dolphin, USA, Hilton Head Island South Carolina, 1995 (AF196646); ABND-K231, bottlenose dolphin K231, USA (captive) (AY949832); HHV-5, Human herpesvirus 5, HCMV (M14709); and HHV-6, Human herpesvirus 6 (AB283024).

these genital mucosa lesions. Papillomavirus DNA was not detectable by PCR in any of the samples of the genital mucosa or in the biopsied material from the penile lesion of dolphin 19. Consensus primers were used that were successful in finding

Phocoena spinnipinis Papillomavirus type 1 that is closely related to *Tursiops truncatus* Papillomavirus type 2 (Van Bressem et al., 2007). Detailed electron microscopic examination of the biopsy sample of the penile plaque from dolphin

19 did not reveal papillomavirus-like particles. Based on these observations coinfection with papillomavirus is unlikely.

We found no evidence that TTHV in bottlenose dolphins caused disease other than genital plaques. No herpesvirus was detected in samples from six bottlenose dolphin cases of perinatal mortality and abortions, which have been associated with genital herpesvirus infection in multiple species (Foster, 2007). Of 24 necropsy reports examined, there were no records of urogenital neoplasia, which has been associated with herpesvirus infection in California sea lions (King et al., 2002). However, this conclusion is based on examination of a relatively small number of cases, and further studies are recommended to determine the pathogenic potential of this herpesvirus.

The degree of genetic similarity of TTHV from this study to previously detected herpesviruses from bottlenose dolphins seems to be related to the geographic origin of the dolphins. A herpesvirus from a bottlenose dolphin stranded on the Florida Keys (Smolarek Benson et al., 2006), which lies adjacent to the Gulf of Mexico (origin of dolphin 5 and 16), and Cuban waters (origin of dolphin 34), showed 100% identity to the herpesvirus from our study. In contrast, two herpesviruses from bottlenose dolphins stranded further north, on the Atlantic coasts of Florida and North Carolina (Smolarek Benson et al., 2006), showed only 91% identity with the herpesvirus from our study. Because herpesviruses may show a marked geographically defined genotype distribution (Pellet and Roizman, 2007), genetic differences between herpesviruses from bottlenose dolphins may provide information on the degree of separation between the populations from which they originate.

Results of serologic examination suggest that the herpesvirus is endemic in this zoo collection of dolphins and is transmitted by sexual contact. Transmission by sexual contact is suggested by the correlation between minimum age at which sera are

positive (1 yr for males, 5 yr for females [Table 1]) and onset of sexual activity. From the age of less than 1 yr, males insert their penis into the genital slit of adult females and that of males of all ages (unpublished data). In contrast, females are only penetrated when they become sexually mature, at a minimum age of 4 yr (Robeck et al., 2008). Seroconversions occurred throughout the period 1997 to 2007, and antibodies also were demonstrated in the oldest available sera from 1994, indicating the virus is endemic in this collection.

In conclusion, we report the first successful cultivation of a herpesvirus from bottlenose dolphins. This TTHV belongs to the subfamily of *Gammaherpesvirinae* and is significantly associated with genital plaques in both males and females. Seroepidemiology using a newly developed ELISA demonstrated infection is endemic in the zoo collection and apparently spreads by sexual contact. We found no evidence that TTHV is associated with perinatal mortality or urogenital neoplasia. However, more extensive studies are warranted to confirm or negate these preliminary observations.

ACKNOWLEDGMENTS

We acknowledge the training staff of Dolfinarium Harderwijk and Parc Asterix and Vivian Emmer for assistance with obtaining and processing of the samples and the inspection of the animals.

LITERATURE CITED

- AVGIL, M., AND A. ORNOY. 2006. Herpes simplex virus and Epstein-Barr virus infections in pregnancy: Consequences of neonatal or intrauterine infection. *Reproductive Toxicology* 21: 436–445.
- BARR, B., J. L. DUNN, M. D. DANIEL, AND A. BANFORD. 1989. Herpes-like viral dermatitis in a beluga whale (*Delphinapterus leucas*). *Journal of Wildlife Diseases* 25: 608–611.
- BLANCHARD, T. W., N. T. SANTIAGO, T. P. LIPSCOMB, R. L. GARBER, W. E. MCFEE, AND S. KNOWLES. 2001. Two novel alphaherpesviruses associated with fatal disseminated infections in Atlantic bottlenose dolphins. *Journal of Wildlife Diseases* 37: 297–305.
- DE RODA HUSMAN, A.-M., J. M. M. WALBOOMERS, A. J. C. VAN DEN BRULE, C. J. L. M. MEIJER, AND P. J. F. SNIJDERS. 1995. The use of general primers

- GP5 and GP6 elongated at their 39 ends with adjacent highly conserved sequences improves human papillomavirus detection by PCR. *Journal of General Virology* 76: 1057–1062.
- DOANE, F., AND N. ANDERSON. 1987. Electron microscopy in diagnostic virology: A practical guide and atlas. Cambridge University Press, Cambridge, U.K., 178 pp.
- FELSENSTEIN, J. 2004. PHYLIP (Phylogeny Inference Package), version 3.6. Department of Genome Sciences, University of Washington, Seattle, Washington.
- FOSTER, A. 2007. Female Reproductive System. *In* Pathologic basis of veterinary disease, M. McGavin and J. Zachary (eds.). Mosby Elsevier, St. Louis, Missouri, pp. 1263–1315.
- JOHNE, R., A. KONRATH, M.-E. KRAUTWALD-JUNGHANS, E. F. KALETA, H. GERLACH, AND H. MÜLLER. 2002. Herpesviral, but no papoviral sequences, are detected in cloacal papillomas of parrots. *Archives of Virology* 147: 1869–1880.
- KENNEDY, S., I. J. LINDSTEDT, M. M. MCALISKEY, S. A. MCCONNELL, AND S. J. MCCULLOUGH. 1992. Herpesviral encephalitis in a harbor porpoise (*Phocoena phocoena*). *Journal of Zoo and Wildlife Medicine* 23: 374–379.
- KING, D. P., M. C. HURE, T. GOLDSTEIN, B. M. ALDRIDGE, F. M. GULLAND, J. T. SALIKI, E. L. BUCKLES, L. J. LOWENSTINE, AND J. L. STOTT. 2002. Otarine herpesvirus-1: A novel gamma-herpesvirus associated with urogenital carcinoma in California sea lions (*Zalophus californianus*). *Veterinary Microbiology* 86: 131–137.
- MANIRE, C. A., K. A. SMOLAREK, C. H. ROMERO, M. J. KINSEL, T. M. CLAUSS, AND L. BYRD. 2006. Proliferative dermatitis associated with a novel alpha-herpesvirus in an Atlantic bottlenose dolphin (*Tursiops truncatus*). *Journal of Zoo and Wildlife Medicine* 37: 174–181.
- MANOS, M. M., Y. TING, D. K. WRIGHT, A. J. LEWIS, T. R. BROKER, AND S. M. WOLINSKY. 1989. The use of polymerase chain reaction amplification for the detection of genital human papillomaviruses. *Cancer Cells* 7: 209–214.
- MARTINEAU, D., A. LAGACE, P. BELAND, R. HIGGINS, D. ARMSTRONG, AND L. R. SHUGART. 1988. Pathology of stranded beluga whales (*Delphinapterus leucas*) from the St. Lawrence Estuary, Quebec, Canada. *Journal of Comparative Pathology* 98: 287–311.
- NORTON, T. M., E. R. JACOBSON, AND J. P. SUNDBERG. 1990. Cutaneous fibropapillomas and renal myxofibroma in a green turtle (*Chelonia mydas*). *Journal of Wildlife Diseases* 26: 265–270.
- PAMELA, E. G., J. E. K. L. MANSELL, AND P. M. RAKICH. 2007. Skin and appendages. *In* Jubb, Kennedy, and Palmers pathology of domestic animals. Vol. 3, M. Maxie (ed.). Saunders Elsevier, Edinburgh, U.K., pp. 553–783.
- PELLET, E., AND B. ROIZMAN. 2007. The family: *Herpesviridae* a brief introduction. *In* Fields Virology, D. Knipe and P. Howley (eds.). Wolters Kluwer, Philadelphia, Pennsylvania, pp. 2479–2500.
- QUACKENBUSH, S. L., T. M. WORK, G. H. BALAZS, R. N. CASEY, J. ROVNAK, A. CHAVES, L. DUTOIT, J. D. BAINES, C. R. PARRISH, P. R. BOWER, AND J. W. CASEY. 1998. Three closely related herpesviruses are associated with fibropapillomatosis in marine turtles. *Virology* 246: 392–399.
- REHTANZ, M., S. J. GHIM, A. RECTOR, M. VAN RANST, P. A. FAIR, G. D. BOSSART, AND A. B. JENSON. 2006. Isolation and characterization of the first American bottlenose dolphin papillomavirus: *Tursiops truncatus* papillomavirus type 2. *Journal of General Virology* 87: 3559–3565.
- ROBECK, T. R., S. K. C. ATKINSON, AND F. BROOK. 2008. Reproduction. *In* CRC handbook of marine mammal medicine, L. A. Dierauf and F. M. D. Gulland (eds.). CRC Press, Boca Raton, Florida, pp. 193–236.
- SALIKI, J. T., E. J. COOPER, D. S. ROTSTEIN, S. L. CASELTINE, D. A. PABST, W. A. McLELLAN, P. GOVETT, C. HARMS, K. A. SMOLAREK, AND C. H. ROMERO. 2006. A novel gammaherpesvirus associated with genital lesions in a Blainville's beaked whale (*Mesoplodon densirostris*). *Journal of Wildlife diseases* 42: 142–148.
- SCHLAFFER, D., AND R. MILLER. 2007. Female genital system. *In* Jubb, Kennedy, and Palmers Pathology of Domestic Animals. Vol. 3, M. Maxie (ed.). Saunders Elsevier, Edinburgh, U.K., pp. 429–564.
- SMOLAREK BENSON, K. A., C. A. MANIRE, R. Y. EWING, J. T. SALIKI, F. I. TOWNSEND, B. EHLERS, AND C. H. ROMERO. 2006. Identification of novel alpha- and gammaherpesviruses from cutaneous and mucosal lesions of dolphins and whales. *Journal of Virological Methods* 136: 261–266.
- STYLES, D. K., E. K. TOMASZEWSKI, L. A. JAEGER, AND D. N. PHALEN. Psittacid herpesviruses associated with mucosal papillomas in neotropical parrots. *Virology* 325: 24–35.
- VAN BRESSEM, M. F., P. CASSONNET, A. RECTOR, C. DESAINTE, K. VAN WAEREBEEK, J. ALFARO-SHIGUETO, M. VAN RANST, AND G. ORTH. 2007. Genital warts in Burmeister's porpoises: Characterization of *Phocoena spinipinnis* papillomavirus type 1 (PsPV-1) and evidence for a second, distantly related PsPV. *Journal of General Virology* 88: 1928–1933.
- VANDEVANter, D. R., P. WARRENER, L. BENNET, E. R. SCHULTZ, S. COULTER, R. L. GARBER, AND T. M. ROSE. 1996. Detection and analysis of diverse herpesviral species by consensus primer PCR. *Journal of Clinical Microbiology* 34: 1666–1671.
- ZAR, J. 1996. Biostatistical analysis. Prentice Hall, Upper Saddle River, New Jersey, 662 pp.

Received for publication 10 April 2009.