

A MICROSPORIDAN (PROTOZOA: CNIDOSPORA) IN CHANNEL CATFISH (*Ictalurus punctatus*)

Authors: HERMAN, ROGER LEE, and PUTZ, ROBERT E.

Source: Journal of Wildlife Diseases, 6(3) : 173

Published By: Wildlife Disease Association

URL: <https://doi.org/10.7589/0090-3558-6.3.173>

BioOne Complete (complete.BioOne.org) is a full-text database of 200 subscribed and open-access titles in the biological, ecological, and environmental sciences published by nonprofit societies, associations, museums, institutions, and presses.

Your use of this PDF, the BioOne Complete website, and all posted and associated content indicates your acceptance of BioOne's Terms of Use, available at www.bioone.org/terms-of-use.

Usage of BioOne Complete content is strictly limited to personal, educational, and non - commercial use. Commercial inquiries or rights and permissions requests should be directed to the individual publisher as copyright holder.

BioOne sees sustainable scholarly publishing as an inherently collaborative enterprise connecting authors, nonprofit publishers, academic institutions, research libraries, and research funders in the common goal of maximizing access to critical research.

A MICROSPORIDAN (PROTOZOA: CNIDOSPORA) IN CHANNEL CATFISH (*Ictalurus punctatus*)

During the fall of 1969, a channel catfish (*Ictalurus punctatus*) with visceral cysts was brought to the attention of Dr. C. Dawe.¹ The fish was caught from a private pond in Maryland which had been stocked from the Potomac River. Histological sections were sent to the Eastern Fish Disease Laboratory for diagnosis.

The visceral cysts were proteocephalid plerocercoids. Further study of the slides showed cysts of the myxosporidan, *Henneguya* sp., within the gill tissue, and lesions in the ventricle of the heart and intestinal sub-mucosa. These lesions were xenomas (Weissenberg, 1968. J. Protozool. 15 (1): 44-57) filled with various stages of a microsporidan (Figure 1). An accurate count of spores per sporont, which is the main criteria for generic identification of microsporidans, could not be made from these sections. At least six spores per sporont were present indicating the parasites belong to

the genus *Thelohania* (eight spores per sporont) or *Plistophora* (16 spores or more per sporont).

The nucleus as well as the cell body of the infected cells was hypertrophied. The xenomas were surrounded by a hyaline membrane which was thicker in the intestine than in the heart. Mild compression of surrounding tissue occurred in both organs. There was no indication of cellular reaction to the lesions in the heart; however, in the intestine some reaction was suggested but the decomposed state of the organ prevented conclusive interpretation. To our knowledge, this is the first report of a microsporidan from *Ictalurus punctatus*.

ROGER LEE HERMAN
ROBERT E. PUTZ

Bureau of Sport Fisheries and Wildlife
Eastern Fish Disease Laboratory
Kearneysville, West Virginia 25430

April 14, 1970

¹National Cancer Institute, Bethesda, Maryland.

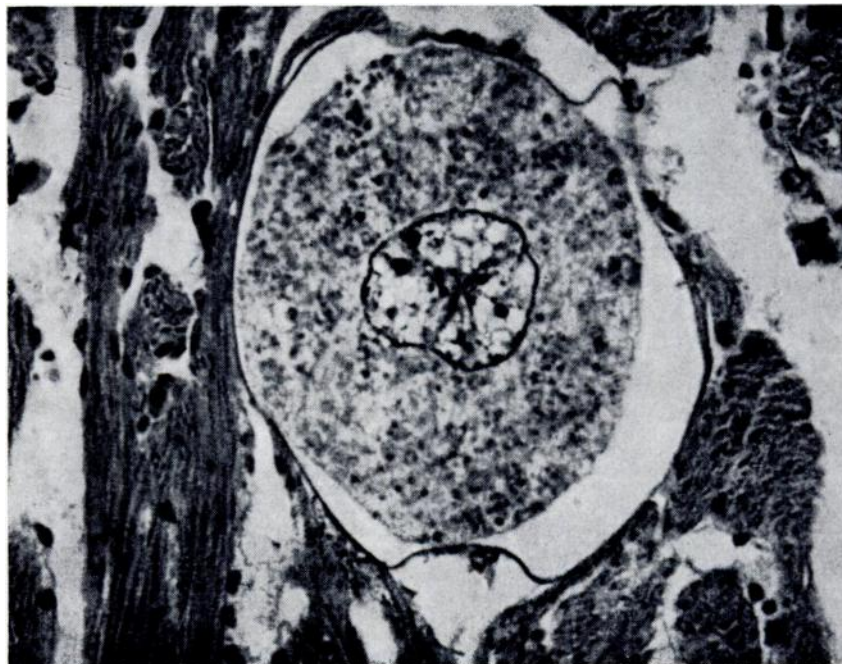


FIGURE 1. Cardiac xenoma caused by a microsporidan in channel catfish, showing hypertrophy of both nucleus and cell body. H. and E. X 150.