

## **THE OCCURRENCE OF SETARIA IN REINDEER\***

Authors: ROBERT A. DIETERICH, and JACK R. LUICK

Source: Journal of Wildlife Diseases, 7(4) : 242-245

Published By: Wildlife Disease Association

URL: <https://doi.org/10.7589/0090-3558-7.4.242>

---

BioOne Complete ([complete.BioOne.org](http://complete.BioOne.org)) is a full-text database of 200 subscribed and open-access titles in the biological, ecological, and environmental sciences published by nonprofit societies, associations, museums, institutions, and presses.

Your use of this PDF, the BioOne Complete website, and all posted and associated content indicates your acceptance of BioOne's Terms of Use, available at [www.bioone.org/terms-of-use](http://www.bioone.org/terms-of-use).

Usage of BioOne Complete content is strictly limited to personal, educational, and non-commercial use. Commercial inquiries or rights and permissions requests should be directed to the individual publisher as copyright holder.

---

BioOne sees sustainable scholarly publishing as an inherently collaborative enterprise connecting authors, nonprofit publishers, academic institutions, research libraries, and research funders in the common goal of maximizing access to critical research.

## THE OCCURRENCE OF SETARIA IN REINDEER\*

ROBERT A. DIETERICH and JACK R. LUICK

Institute of Arctic Biology, University of Alaska College, Alaska 99701

*Abstract:* *Setaria yehi* Desset, 1966, is reported from domestic reindeer (*Rangifer tarandus* Linnaeus), maintained at College and Cantwell, Alaska. Microfilariae were present in blood from reindeer harboring *S. yehi*. Gross and microscopic findings in the infected animals revealed a low-grade peritonitis. Caribou, moose, dairy cows, goats, and dogs examined in the local areas were negative for microfilariae.

### INTRODUCTION

The taxonomy, hosts, and geographic distribution of *Setaria* sp. abdominal worms in the United States and Canada have been reviewed by Becklund and Walker.<sup>1</sup> *Setaria yehi* Desset, 1966, has been reported in North America from ungulates of several species: moose, *Alces alces*; deer, *Odocoileus* spp.; caribou, *Rangifer tarandus*; and bison, *Bison bison*. It has been identified in moose in Alaska, but has not been reported in domestic reindeer, *Rangifer tarandus*, in this region. A *Setaria* sp. in reindeer in the Soviet Union was reported by Raevskaia.<sup>2</sup>

The complete life cycle of *S. yehi* is unknown but undoubtedly involves biological transmission of larvae by a blood sucking arthropod. The larvae in turn develop into adults that live free in the peritoneal cavity of the definitive host. Microfilariae from these adults find their way to the host's blood stream and can be demonstrated.

### MATERIAL AND METHODS

Animals were examined from July, 1969 to June, 1970 for the presence of microfilariae by collecting 12 ml of whole blood, allowing it to clot and stand overnight at 21 C, and then decanting off the serum. The serum was centrifuged at 1500 RPM for 3 minutes,


decanted and the sediment examined for microfilariae at 100 x magnification. Gross pathologic and histologic examinations were carried out on 10 reindeer.

The reindeer that comprise the University of Alaska's herd were originally obtained from Nome, Alaska. University of Alaska reindeer are held at two areas; one group in the interior of Alaska at College, and the other at Cantwell approximately 135 miles to the south and separated from College by the Alaska Range. Fourteen caribou near Cantwell and 2 moose, 6 Holstein cows, 2 domestic goats, 4 horses, and 2 dogs from College were also examined.

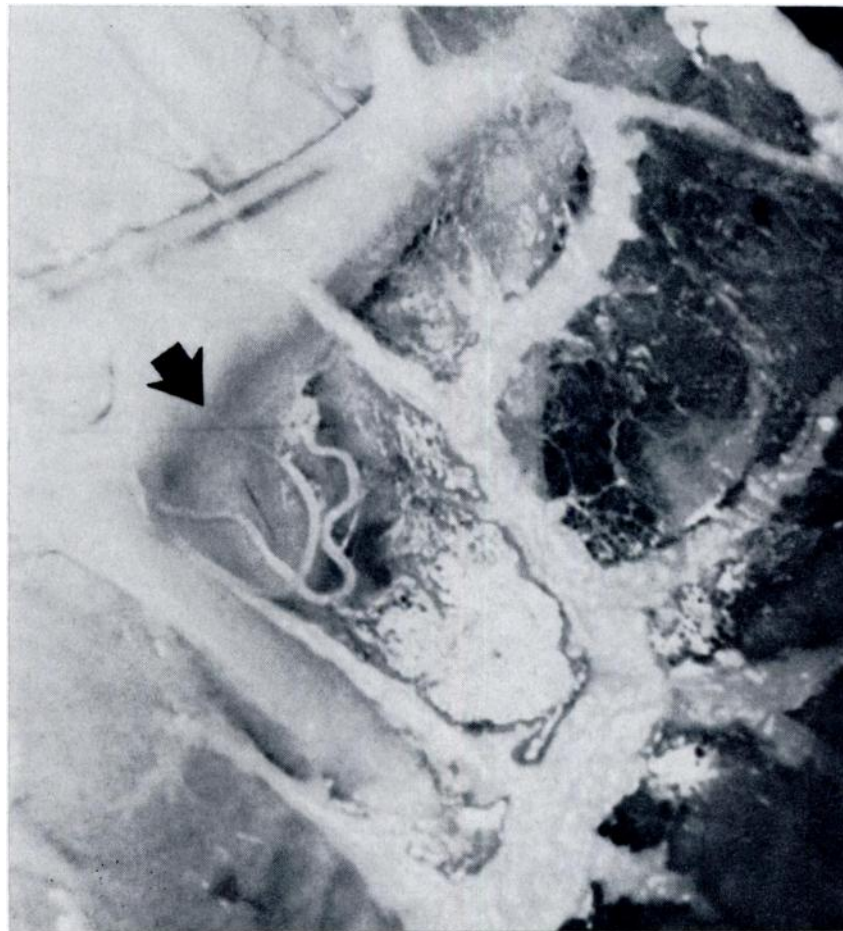### RESULTS AND DISCUSSION

Microfilariae were first observed in reindeer at the Institute of Arctic Biology, University of Alaska, during the summer of 1969, in blood smears prepared for routine evaluation (figure 1). In the winter of 1969 nematodes were found free in the peritoneal cavity of five reindeer that were euthanatized during a body composition study (figure 2). These adult parasites were identified by Becklund and Walker as *Setaria yehi* Desset, 1966 (personal communication). Specimens have been deposited in the United States National Museum Helminth Collection, Number 6623. Numerous reindeer are slaughtered annually at Nome and *S. yehi*

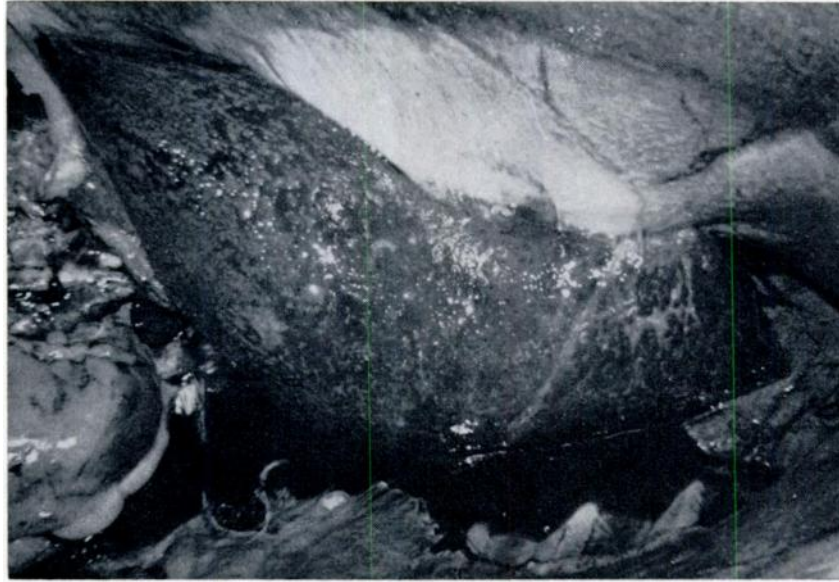
\*This study was supported by A.E.C. Grant No. AT-04-3/310.



1. Giemsa stained *Setaria microfilaria* from blood of reindeer X450.



2. Adult *Setaria in situ* near rumen of reindeer.



3. Reindeer liver with fibrinous deposits on surface.

has not been found in members of that herd (personal communication). All 15 animals at College, representing ages from 1 year to over 4 years, had microfilariae in their blood, while 10 of 13 animals at Cantwell, also 1-4 years of age were positive using the serum concentration method. Individuals tested repeatedly during winter and summer months were positive at all times with the exception of two animals that were positive in December, negative during January, February, March and April, and again positive in May.

All reindeer examined that had microfilariae in their blood (after being euthanized for body composition studies) were also found to have from 5 to 20 nematodes in the abdominal cavity and a chronic low grade peritonitis. Typical findings included: 50 to 150 ml of straw colored serous fluid in the peritoneal cavity, several areas of fibrous adhesions between the mesentery and intestines, and fibrin deposits on the surface of the liver (figure 3). Microscopic examination of the liver, abomasum, and small intes-

tine revealed chronic inflammatory processes involving the serosal surfaces. Three reindeer negative for microfilariae from the Cantwell herd were examined and found to have no nematodes in the abdominal cavity and no gross or microscopic lesions of peritonitis. Some of the reported cases of setarial infections in animals refer to cerebrospinal nematodiasis as the primary pathologic finding.<sup>3</sup> No central nervous system disorders have been seen in the University reindeer herd and gross examination of cross sections taken every 2 cm along the spinal column and brain of infected reindeer revealed no abnormalities.

Fourteen caribou that utilize the lichen ranges during the summer and winter near the Cantwell reindeer herd were found by gross examination not to harbor *Setaria* sp. Two moose that were maintained with infected reindeer within the Institute's animal pens did not have microfilariae present in blood samples examined during December, 1969. Similarly, six Holstein cows, two domestic goats, four horses, and two dogs all from

the College area had no microfilariae in their blood when examined in January, 1970.

Infections in our local herd were sub-clinical. The University reindeer herd has remained in good condition and has reproduced well even when harboring *S. yehi*.

Treatment was attempted with limited success. Diethylcarbamazine given orally

to three reindeer at a dosage of 50 mg per kg body weight per day for 21 days proved to be totally ineffectual in reducing microfilarial levels. A marked drop in numbers of microfilariae occurred in one reindeer injected intraperitoneally with 13 mg/kg of an organic phosphate [0-0 Dimethyl, 0,p- (dimethyl sulfamoyl) phenylphosphorothioate] in propylene glycol.

#### LITERATURE CITED

1. BECKLUND, W. W., and M. L. WALKER. 1969. Taxonomy, hosts, and geographic distribution of the *Setaria* (Nematoda: Filarioidea) in the United States and Canada. *J. Parasitology*. 55: 359-368.
2. INNES, J. R. 1953. Cerebrospinal nematodiasis. *Archives of Neurology and Psychiatry*. 70: 325-349.
3. RAEVSKAIA, Z. A. 1928. *Trudy gosudarstvennogo instituta eksperimental -noi veterinarii*. 5: 53-108.

*Received for publication October 27, 1970*

---