

## **SOME HISTOPATHOLOGICAL LESIONS CAUSED BY HELMINTHS IN MARINE MAMMALS 1**

Authors: MIGAKI, GEORGE, VAN DYKE, DON, and HUBBARD,  
RICHARD C.

Source: Journal of Wildlife Diseases, 7(4) : 281-289

Published By: Wildlife Disease Association

URL: <https://doi.org/10.7589/0090-3558-7.4.281>

---

BioOne Complete ([complete.BioOne.org](https://complete.BioOne.org)) is a full-text database of 200 subscribed and open-access titles in the biological, ecological, and environmental sciences published by nonprofit societies, associations, museums, institutions, and presses.

Your use of this PDF, the BioOne Complete website, and all posted and associated content indicates your acceptance of BioOne's Terms of Use, available at [www.bioone.org/terms-of-use](https://www.bioone.org/terms-of-use).

Usage of BioOne Complete content is strictly limited to personal, educational, and non - commercial use. Commercial inquiries or rights and permissions requests should be directed to the individual publisher as copyright holder.

---

BioOne sees sustainable scholarly publishing as an inherently collaborative enterprise connecting authors, nonprofit publishers, academic institutions, research libraries, and research funders in the common goal of maximizing access to critical research.

## SOME HISTOPATHOLOGICAL LESIONS CAUSED BY HELMINTHS IN MARINE MAMMALS<sup>[1]</sup>

GEORGE MIGAKI,<sup>[2]</sup> DON VAN DYKE,<sup>[3]</sup> and RICHARD C. HUBBARD<sup>[4]</sup>

**Abstract:** Microscopic lesions caused by helminths discussed in this paper are verminous pneumonia, gastric ulcers, and ulcerative enterocolitis in the California sea lion (*Zalophus californianus*); biliary fibrosis and pulmonary granulomas in the dall porpoise (*Phocoenoides dalli*); and gastric fibrosis in an Atlantic bottlenose dolphin (*Tursiops truncatus*) and a Pacific bottlenose dolphin (*Tursiops gilli*).

The purpose of this paper is to describe and illustrate the severity of the tissue damage produced by helminths in wild pinniped and cetacean animals. The recognition of such parasite-related lesions is an important consideration in evaluating the clinical behavior of the animal. The identification of the parasite will aid not only in establishing the cause of the lesions but also in the proper treatment of such affected animals.

During the past year necropsy specimens from over 40 marine mammals have been received in the Registry of Comparative Pathology (RCP) and examined histologically. The specimens, which were submitted to the RCP either as contributions or for consultation, were from wild marine mammals, some of which had been used in experiments following capture. During the course of histologic examination of the specimens we observed lesions caused by or associated with helminths, which were

considered to be relatively common pathologic changes but worthy of documentation. Specific case histories, though they would be desirable, are not available. Reviews of the literature concerning helminths in marine mammals have been reported by Johnston and Ridgway,<sup>7</sup> Delyamure,<sup>4</sup> Woodard *et al.*,<sup>13</sup> Yamaguti,<sup>14</sup> Fleischman and Squire,<sup>6</sup> Ridgway,<sup>10</sup> Keyes,<sup>5</sup> and Cockrill.<sup>2</sup>

### Verminous Pneumonia in the California Sea Lion (*Zalophus californianus*)

Reports<sup>5,6,9</sup> indicate that verminous pneumonia caused by *Parafilaroides de-corus* is a common occurrence in the California sea lion. A recent report<sup>8</sup> indicates that the opaleye fish (*Girella nigricans*) serves as an intermediate host for this nematode.

The six sea lions with verminous pneumonia in this report were found stranded along the coast of California. Clinical

[1] Supported in part by Public Health Service Grant Number RR00301-06 from the Division of Research Facilities and Resources, Department of Health, Education, and Welfare, under the auspices of Universities Associated for Research and Education in Pathology, Inc., and in part by the University of California, Berkeley, Naval Biomedical Research Laboratory, funded through Office of Naval Research Contract No. N00014-69-A-0200-1001.

[2] Comparative Pathology Branch, Armed Forces Institute of Pathology, Washington, D.C. 20305.

[3] Marine Bioscience Facility, Naval Undersea Research and Development Center, Point Mugu, California 93042.

[4] Biological Sonar Laboratory, Marine Mammal Study Center, Fremont, California 94536.

The opinions or assertions contained herein are the private views of the authors and are not to be construed as official or as reflecting the views of the Department of the Army or the Department of Defense.

This paper was presented at the International Association for Aquatic Animal Medicine Conference, April 29-30, 1971, University of Guelph, Guelph, Ontario, Canada.

signs were nonspecific and consisted of labored respirations and coughing. At necropsy, the lungs had a mottled appearance and areas of consolidation. The bronchial and tracheal lumens contained a frothy reddish material. Fibrinous strands were adherent to the pleura.

Histopathologic lesions in the lungs caused by *P. decorus* have been well documented.<sup>6,9</sup> In our sea lions the adults and larvae of *P. decorus* were found in the alveoli and bronchi, and there was considerable variation in the response of the host tissue to the parasite. In some areas there was little inflammatory response (Figs. 1A, 1B), while in other areas there was thickening of the interalveolar septa from edema. In the consolidated areas, the alveoli and bronchi were filled with polymorphonuclear leukocytes, predominantly eosinophils, with the interalveolar tissue containing histiocytes, plasma cells, eosinophils, and lymphocytes (Fig. 1C). The degeneration and death of the adult parasite may have caused hypersensitivity, as indicated by the presence of many eosinophils.<sup>9</sup>

#### Gastric Ulcers in the California Sea Lion

Gastric ulcers in marine mammals caused by the genera *Anisakis* and *Contracaecum* have been reported.<sup>6,11,12,15</sup> The parasites, though seen in gastric ulcers of our eight sea lions at necropsy, were not identified. The gross appearance of the ulcers varied, some being fresh and hemorrhagic, others in various stages of healing. The active ulcers were relatively large, were situated in various areas of the stomach, and had extended deeply into the wall. They had a crater-like appearance with thick, raised edges. Histologically, the ulcers contained entire intact parasites (Fig. 2A) and degenerated eosinophilic cuticular fragments (Fig. 2B). The ulcers in many instances extended beyond the submucosa and into the tunica muscularis. The necrotic centers of the ulcers were surrounded by a thick, fibrous tissue. The Y-shaped lateral cords of the parasites suggests that the nematode belongs to the genus *Anisakis* (Fig. 2C).

#### Ulcerative Enterocolitis Caused by Unidentified Flukes in the California Sea Lion

Flukes (Fig. 3A) were found in the mucosa of both the small and the large intestines of three sea lions. Small ulcers (Fig. 3B) with catarrhal exudate were adjacent to the flukes, and it is quite likely that these flukes are responsible for the ulcers. These small flukes, many containing eggs, were not identified as to species. In the northern fur seal (*Calloshinus tarsinus*), Keyes<sup>8</sup> found the following trematodes in the small intestine: *Pricitrema zalophi*, *Phocitrema fusiforme*, and *Cryptocotyle jejuna*.

#### Biliary Fibrosis in the dall porpoise (*Phocoenoides dalli*)

This condition was found in two dall porpoises. Epithelial cells of the large bile ducts had undergone extensive hyperplasia and many glandular structures with wide lumens had formed (Figs. 4A, 4B). The cellular infiltrates consisted of a mixture of leukocytes, predominantly lymphocytes, plasma cells, and histiocytes, with a few eosinophils. The connective tissue surrounding the bile ducts was increased in amount and was composed of mature collagenous tissue. The fluke had morphologic features similar to those described for *Campula oblonga*.<sup>14</sup> Woodward *et al.*<sup>13</sup> reported hepatic and pancreatic lesions caused by *Campula palliata* in *T. truncatus*. The triangular pigmented eggs in the uterus were an interesting finding, and they may serve as a differential feature in the identification of this genus of fluke in tissue sections (Fig. 4A, inset). In the absence of a demonstrable fluke in tissue sections, the severe focal proliferation of the biliary epithelium may be mistaken for a benign neoplastic process.

#### Pulmonary Granulomas in a Dall Porpoise

The lungs had many small nodules at the edges of the lobes. Microscopically, the lesions were large, discrete histiocytic granulomas surrounded by a wide band of collagenous tissue (Fig. 5A). The centers of some of the granulomas con-

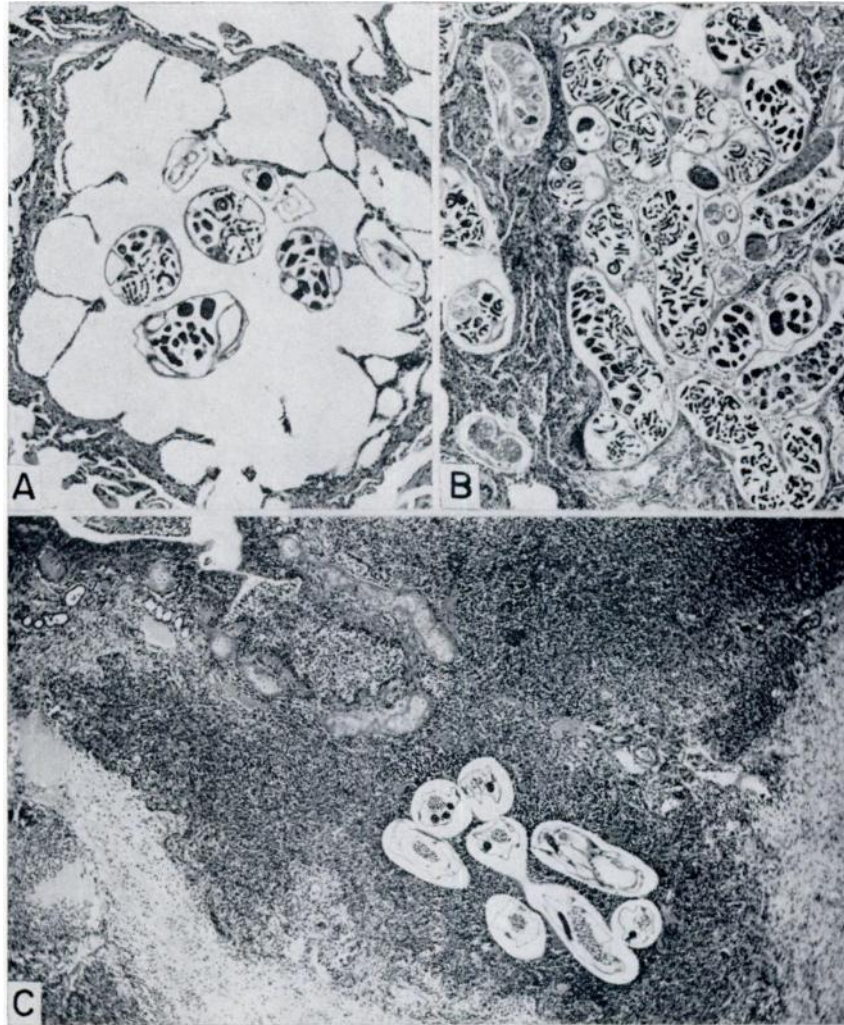


FIGURE 1. Verminous pneumonia in the California sea lion.

A. *Parafilaroides decorus*, containing many larvae in their uteri, in the alveoli. Note the slight inflammatory process. AFIP neg. 71-670, X 63. B. Numerous *P. decorus* in the alveoli, with thickening of the interalveolar septa resulting from collapse of the alveoli and leukocytic infiltrates. AFIP neg. 71-503, X 55. C. Broncho-pneumonia with the lumina of the alveoli, bronchioles, and bronchi filled with polymorphonuclear leukocytes (mostly eosinophils), lymphocytes, plasma cells, and macrophages. Edema is demonstrated in the thickened interalveolar tissue. AFIP neg. 71-661, X 45.

tained cross sections of a nematode that was identified as *Halocercus* sp. These nematodes were found in the small bronchi (Figs. 5B, 5C) and were causing a severe bronchitis with a considerable amount of mineralization and desquamation of the bronchial epithelium. Since

this animal has a poorly developed cough reflex, it has been suggested that bronchial exudate descends towards the alveoli and results in the histiocytic granulomas. In *T. truncatus*, *H. lagenorhynchi* has been reported as a common nematode in the lung.<sup>13</sup>

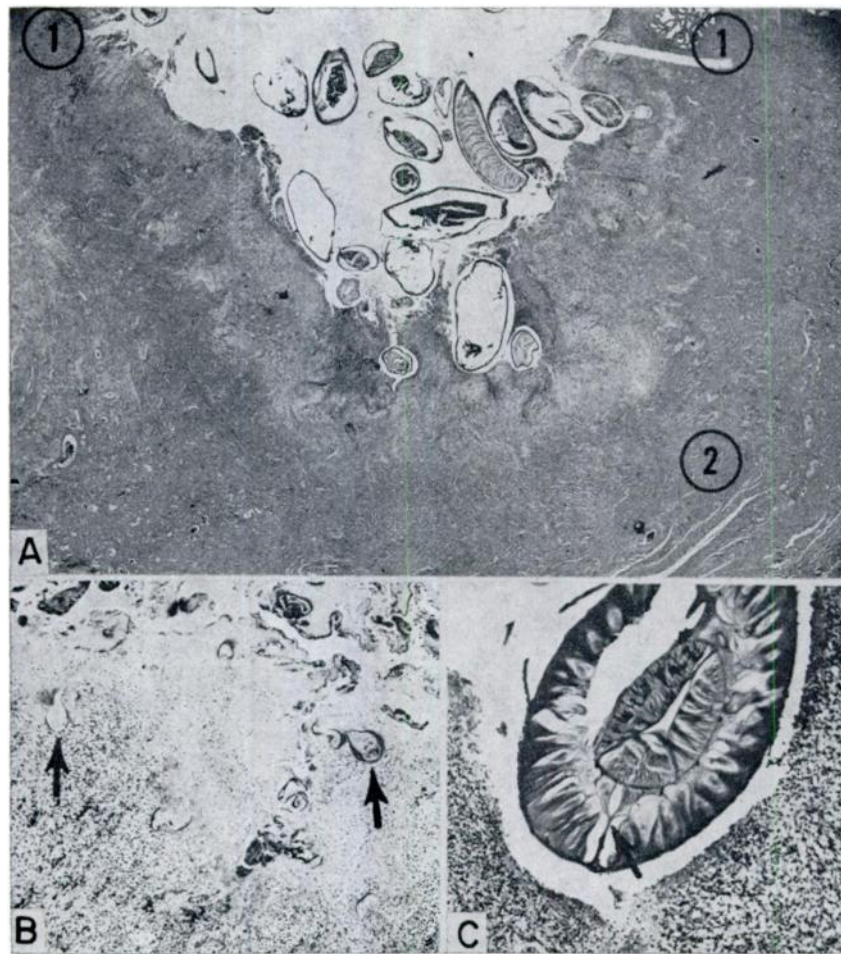


FIGURE 2. Gastric ulcers in the California sea lion. A. Numerous sections of nematodes found in an ulcer. Mucosa (1) and muscularis (2) of the stomach. AFIP neg. 71-509, X 8. B. Eosinophilic cuticular remnants of the nematode (arrows) found in the necrotic portion of the ulcer. AFIP neg. 71-2140, X 50. C. Higher magnification of a cross section of a nematode. Note the Y-shaped lateral cord (arrow), which suggests the possibility that the nematode belongs to the genus *Anisakis*. AFIP neg. 71-2157, X 75.



Another nematode, *Stenurus minor*, has been reported in subpleural granulomas in lungs of a dall porpoise.<sup>7</sup>

**Gastric Nodular Fibrosis in an Atlantic Bottlenose Dolphin (*Tursiops truncatus*) and a Pacific Bottlenose Dolphin (*Tursiops gilli*)**

The fluke causing gastric nodular fibrosis in *T. truncatus* has been reported as *Pholeter gastrophilus*.<sup>13</sup> In our specimens, such gastric lesions were observed in a *T. truncatus* and a *T. gilli*. Histologically, there were large fibrotic nodules in the

submucosa of the stomach. The cystic centers of these nodules contained adult flukes (Fig. 6A). The flukes were surrounded by a thick layer of collagenous tissue, containing small accumulations of eosinophils. The presence of cuticular spines and of yellow eggs with a single operculum (Fig. 6B) and the absence of a body cavity are criteria that are useful in the identification of a trematode in tissue sections. In the event that parasitic structures are not demonstrable, such fibrotic lesions may be mistaken for a neoplasm because of the extensive fibrosis in the gastric wall.

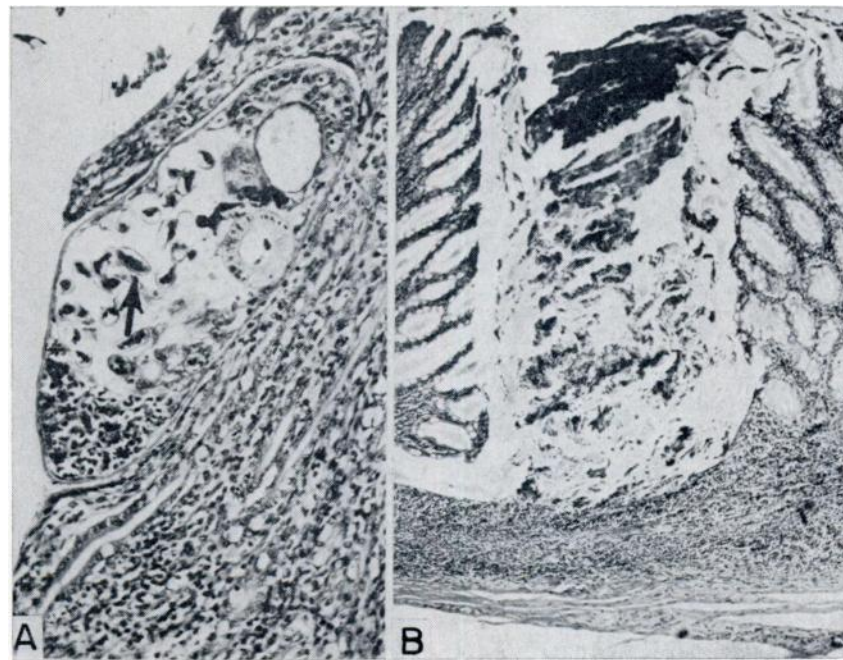


FIGURE 3. Ulcerative enterocolitis associated with flukes in the California sea lion. A. A fluke, containing eggs (arrow) located in the mucosa of the small intestine. AFIP neg. 71-662, X 175. B. Focal necrosis of the mucosa of the large intestine resulting in small ulcers. AFIP neg. 71-2153, X 56.

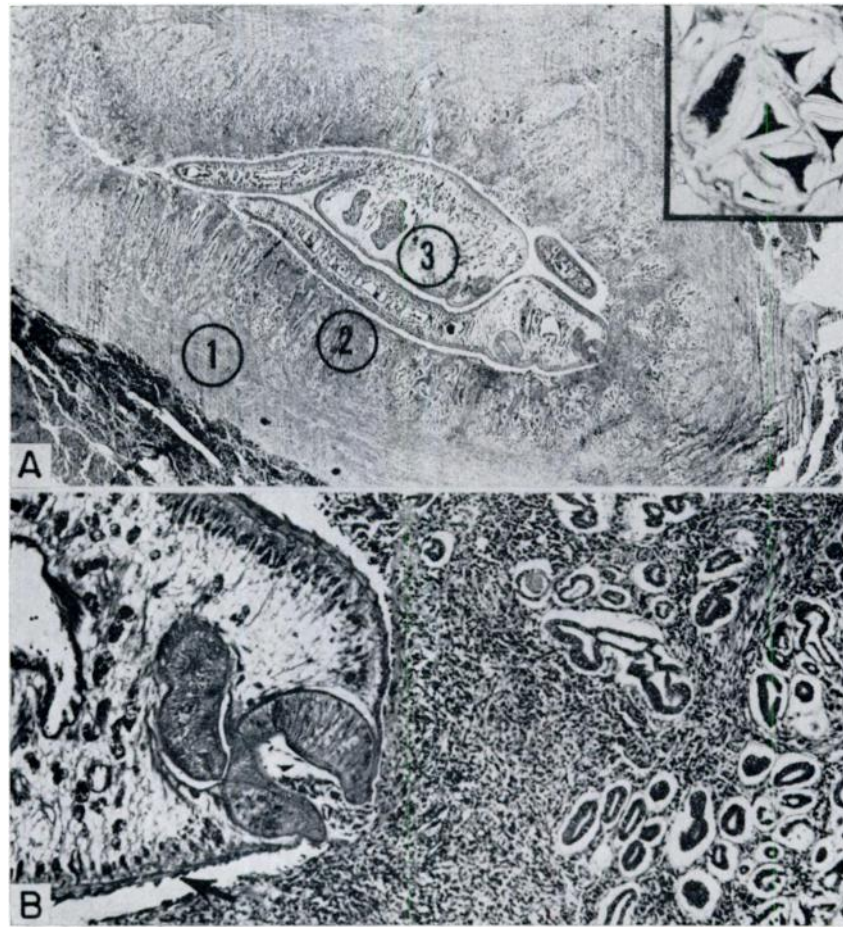


FIGURE 4. Biliary fibrosis in the dall porpoise. A. A large bile duct in the liver, with extensive fibrosis on the periphery (1) and proliferation of the epithelial cells (2) and several *Campula oblonga* (3) present in the lumen. AFIP neg. 71-498, X 10. (Inset) Higher magnification to demonstrate the triangular-shaped eggs of *C. oblonga*. AFIP neg. 71-497, X 180. B. Higher magnification of portion of A to demonstrate the cuticular spines (arrow) and oral sucker of *C. oblonga*. Note glandular hyperplasia of the biliary epithelium. AFIP neg. 71-2155, X 75.

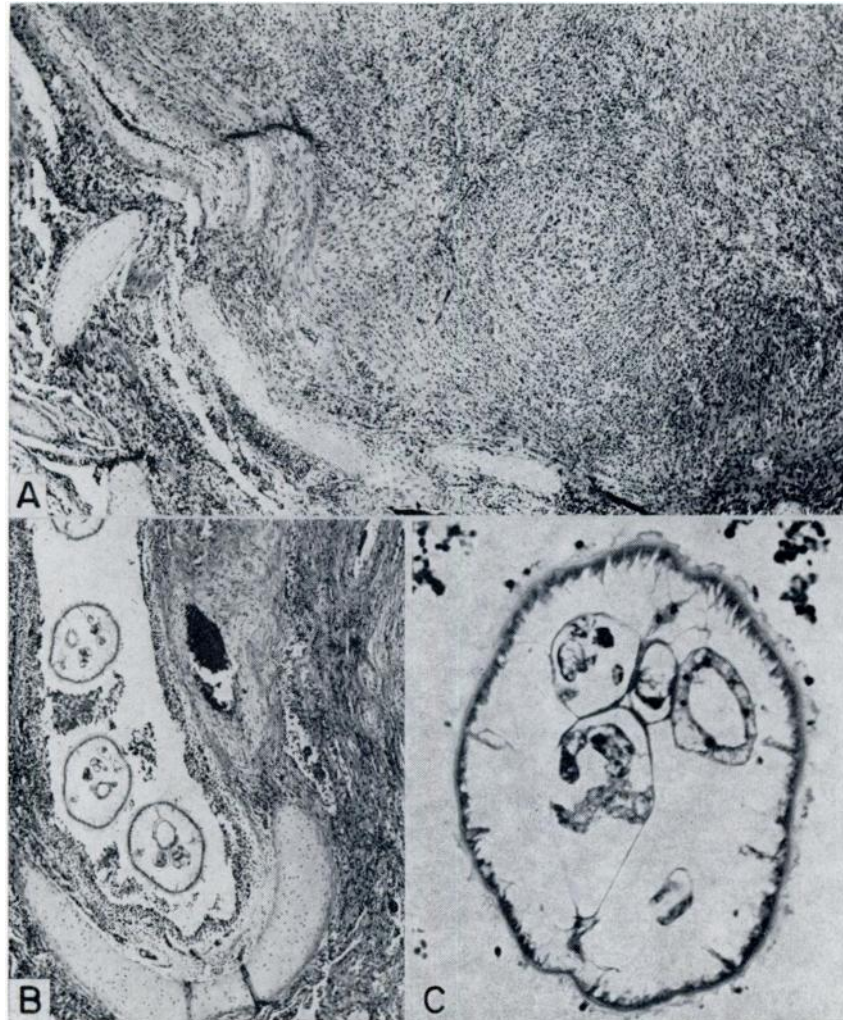


FIGURE 5. Pulmonary granulomas in a dall porpoise. A. The large, discrete granulomas are composed essentially of histiocytes. AFIP neg. 71-2144, X 56. B. Bronchus containing several sections of the nematode, *Halocercus* sp. Note desquamation of the bronchial epithelium and leukocytic infiltrate in the submucosa. AFIP neg. 71-502, X 45. C. Higher magnification of portion of same tissue as B to demonstrate the morphologic features of *Halocercus* sp. Note the cuticular ridges and spines. AFIP neg. 71-2154, X 180.



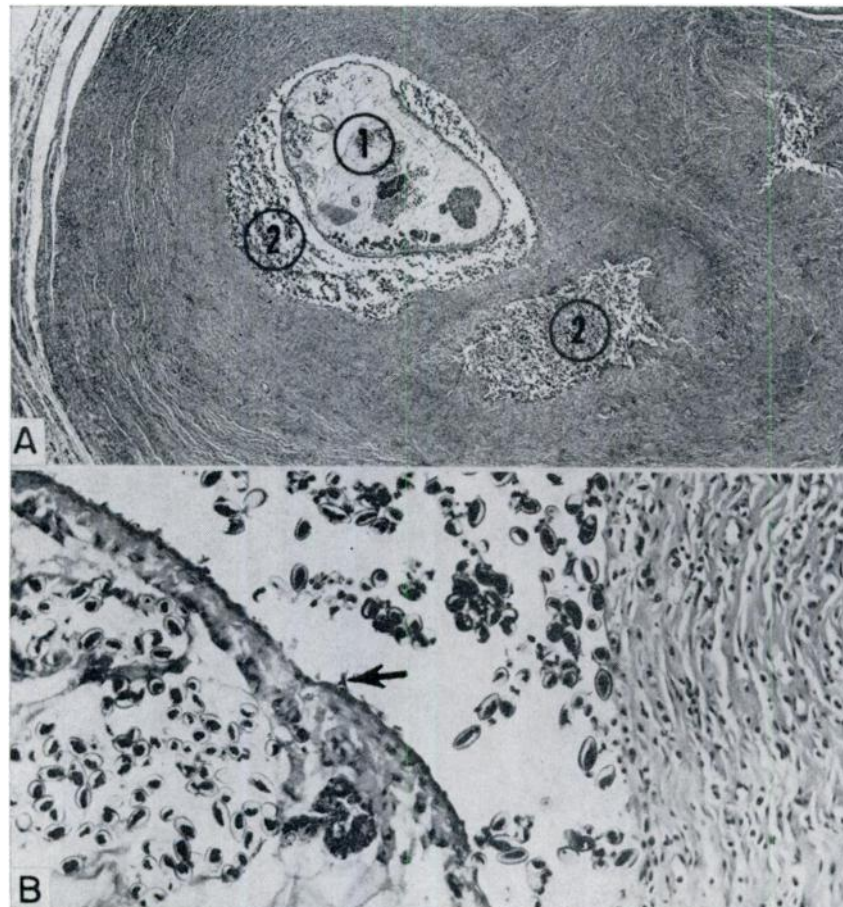


FIGURE 6. Gastric nodular fibrosis in a Pacific bottlenose dolphin. A. The fluke, **Pholeter gastrophilus** (1), and eggs (2) are located in the center of a large fibrotic nodule in the submucosa of the stomach. AFIP neg. 71-2147, X 16. B. Higher magnification of portion of A to demonstrate the collagenous connective tissue surrounding the fluke. Note the cuticular spines (arrow) and eggs. AFIP neg. 71-2148, X 180.

#### Acknowledgement

We wish to thank Mrs. M. B. Chitwood, Parasitology Laboratory, Animal Disease and Parasite Research Division, U.S. Department of Agriculture, Beltsville, Maryland, for the identification of the parasites in tissue sections.

## LITERATURE CITED

1. AREAN, V. M. 1971. Anisakiasis. In *Pathology of Protozoal and Helminthic Diseases with Clinical Correlations*. (Marcial-Rojas, R. A., ed.). Williams and Wilkins, Co., Baltimore, Md. 1010 pages.
2. COCKRILL, W. R. 1960. Pathology of the Cetacea. *Brit. Vet. J.* 116: 1-29.
3. DAILEY, M. D. 1970. The transmission of *Parafilaroides decorus* (Nematode: Metastrongyloidea) in the California sea lion (*Zalophus californianus*). *Proc. Helminthol. Soc. Wash.* 37: 215-222.
4. DELYAMURE, S. L. 1955. *Helminthofauna of Marine Mammals (Ecology Phylogeny)*. Academy of Sciences USSR. 1-522. (Translated by the Israel Program for Scientific Translations for 1968 for the U.S. Department of Interior and National Science Foundation). National Technical Information Service, U.S. Department of Commerce, Springfield, Va. 22151.
5. DOUGHERTY, E. C., and C. M. HERMAN. 1947. Few species of the genus *Parafilaroides* Dougherty, 1946 (Nematode: Metastrongyloidea), from Sea Lions, with a List of the Lungworms of the Pinnipedia. *Proc. Helminthol. Soc. Wash.* 14: 77-87.
6. FLEISCHMAN, R. W., and R. A. SQUIRE. 1970. Verminous pneumonia in the California sea lion (*Zalophus californianus*). *Pathol. Vet.* 7: 89-101.
7. JOHNSTON, D. G., and S. H. RIDWAY. 1969. Parasitism in some marine mammals. *J. Am. Vet. Med. Assoc.* 155: 1064-1072.
8. KEYES, M. C. 1965. Pathology of the northern fur seal. *J. Am. Vet. Med. Assoc.* 147: 1090-1095.
9. MORALES, G. A., and C. F. HELMBOLDT. 1971. Verminous pneumonia in the California sea lion. (*Zalophus californianus*). *J. Wildl. Dis.* 7: 22-27.
10. RIDGWAY, S. H. 1965. Medical care of marine mammals. *J. Am. Vet. Med. Assoc.* 147: 1077-1085.
11. SCHROEDER, C. R., and H. M. WEDGEFORTH. 1935. The occurrence of gastric ulcers in sea mammals of the California coast, their etiology and pathology. *J. Am. Vet. Med. Assoc.* 87: 333-342.
12. WILSON, T. M., and P. H. STOCKDALE. 1970. The harp seal, *Pagophilus groenlandicus* (Erxleben, 1777) XI. *Contracaecum* sp. infestation in a harp seal. *J. Wildl. Dis.* 6: 152-154.
13. WOODARD, J. C., S. G. ZAM, D. K. CALDWELL, and M. C. CALDWELL. 1969. Some parasitic diseases of dolphins. *Pathol. Vet.* 6: 257-272.
14. YAMAGUTI, S. 1961. *Systema Helminthum*, vols. I and III. Interscience, New York.
15. YOUNG, P. C., and D. LOWE. 1969. Larval nematodes from fish of the subfamily Anisakinae and gastro-intestinal lesions in animals. *J. Comp. Pathol.* 79: 301-313.

Received for publication May 28, 1971