



## **ELAEOPHOROSIS IN WHITE-TAILED DEER OF THE SOUTHEASTERN U.S.A.: CASE REPORT AND DISTRIBUTION\***

Authors: PRESTWOOD, ANNIE K., and RIDGEWAY, THEODORE R.

Source: Journal of Wildlife Diseases, 8(3) : 233-236

Published By: Wildlife Disease Association

URL: <https://doi.org/10.7589/0090-3558-8.3.233>

---

BioOne Complete ([complete.BioOne.org](https://complete.BioOne.org)) is a full-text database of 200 subscribed and open-access titles in the biological, ecological, and environmental sciences published by nonprofit societies, associations, museums, institutions, and presses.

Your use of this PDF, the BioOne Complete website, and all posted and associated content indicates your acceptance of BioOne's Terms of Use, available at [www.bioone.org/terms-of-use](https://www.bioone.org/terms-of-use).

Usage of BioOne Complete content is strictly limited to personal, educational, and non - commercial use. Commercial inquiries or rights and permissions requests should be directed to the individual publisher as copyright holder.

---

BioOne sees sustainable scholarly publishing as an inherently collaborative enterprise connecting authors, nonprofit publishers, academic institutions, research libraries, and research funders in the common goal of maximizing access to critical research.

## ELAEOPHOROSIS IN WHITE-TAILED DEER OF THE SOUTHEASTERN U.S.A.: CASE REPORT AND DISTRIBUTION\*

ANNIE K. PRESTWOOD and THEODORE R. RIDGEWAY<sup>†</sup>

Southeastern Cooperative Wildlife Disease Study, Department of Parasitology,  
College of Veterinary Medicine, University of Georgia, Athens 30601, U.S.A.

*Abstract:* Impaired function of the mylo-hyoideus muscles was associated with and possibly caused by arterial worm, *Elaeophora schneideri*, infection in an aged white-tailed deer (*Odocoileus virginianus*). Subsequent to this observation, *E. schneideri* was found in 12 white-tailed deer from four widely separated coastal plain counties in the states of Florida, Georgia, and South Carolina, U.S.A.

### INTRODUCTION

The arterial worm, *Elaeophora schneideri*, is widespread throughout the western United States where it infects a variety of domestic<sup>7</sup> and wild<sup>2,4,5</sup> ruminants. Deer of the genus *Odocoileus* are considered usual hosts for this helminth.<sup>3,7</sup> In other hosts, abnormalities such as filarial dermatosis (sorehead) in sheep,<sup>7</sup> and blindness and ischemic necrosis of the muzzle and ears of wapiti (*Cervus canadensis*)<sup>1-3</sup> are associated with infections of *E. schneideri*. Accounts of *E. schneideri* in animals east of the Mississippi River are lacking, although Walker and Becklund<sup>6</sup> list the deposition of *E. schneideri* from white-tailed deer of Florida in the U.S. National Museum Helminth Collection. Information is presented herein on the occurrence, distribution, and pathogenic effects of *E. schneideri* in white-tailed deer of the southeastern United States.

### CASE REPORT

On September 13, 1962, an eight-year-old female white-tailed deer from Eglin Air Force Base, Walton County, Florida was presented for clinical and pathological

study. The animal was incoordinated, severely debilitated, and demonstrated a striking absence of fear. An enlargement was present between the rami of the lower jaw. Death ensued within a few hours after admission to the clinic.

Post-mortem examination revealed an extensive accumulation of masticated food and debris in the oral cavity beneath the tongue. Lesions of viral, bacterial, mycotic, or toxic origin were not found in the central nervous system or elsewhere. Upon examination of the circulatory system, 14 nematodes were found by the junior author in the heart, thoracic aorta, and carotid arteries. These helminths were identified as *Elaeophora schneideri* Wehr and Dikmans 1935, and specimens were deposited in the USNM Helminth Collection as No. 59909.

### DISTRIBUTION AND PREVALENCE OF

#### *E. schneideri* IN THE SOUTHEAST

Since 1962, 851 deer from 13 southeastern states and St. Croix, U.S. Virgin Islands have been examined for *E. schneideri*. This parasite has been found in white-tailed deer of three of these states, viz. Florida, Georgia, and South Carolina (Figure 1).

\*This study was supported by an appropriation from the Congress of the United States. Funds were administered and research coordinated under the Federal Aid in Wildlife Restoration Act (50 Stat. 917) and through Contract No. 14-16-0008-777, Bureau of Sport Fisheries and Wildlife, U.S. Department of the Interior.

<sup>†</sup> Present Address: American Research Diversified Laboratories, Inc., Box 267, Lexington, Georgia 30648.

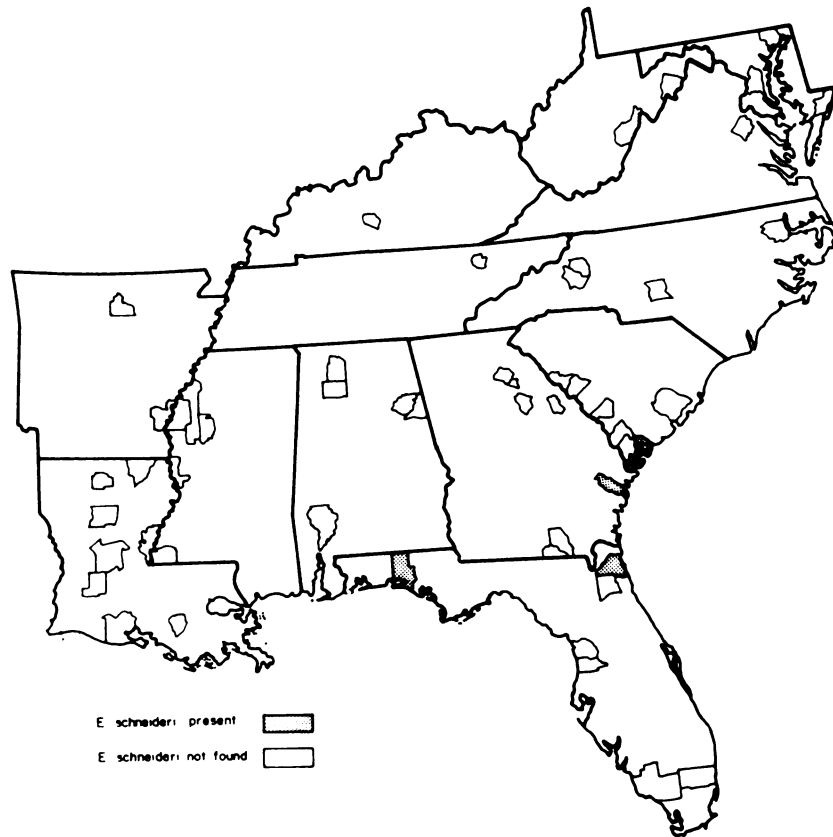


FIGURE 1. Map of Southeast showing counties from which deer were examined for *E. schneideri*.

#### Florida

Between November, 1962, and February, 1963, opportunities were presented for examining the circulatory systems of 77 white-tailed deer killed by hunters during either-sex hunts on Eglin Air Force Base. From 1 to 15 arterial worms were located in 7 of 23 females; the helminth was not found in the 54 males which were harvested. Worms were recovered from the left ventricle of the heart, right and left common carotid, right external maxillary, left and right

sublingual and lumbar arteries in these animals.

Following this initial survey, 40 deer of both sexes from Eglin Air Force Base were collected quarterly over a two-year period during 1968 and 1969. Single specimens of *E. schneideri* were found in the carotid arteries of a female collected in May, 1968, and a male collected in February, 1969. During June, 1971, five female white-tailed deer were examined in Duval County, Florida. Seven *E. schneideri* were recovered from the carotid arteries of one of these animals.

**Georgia**

During a three-year period (1968-1970) 60 male and female white-tailed deer were examined quarterly from Fort Stewart Military Reservation, Liberty County, Georgia. One *E. schneideri* was recovered from the carotid artery of a female collected in November, 1969.

**South Carolina**

During 1963, ten male and female white-tailed deer were collected in Beaufort County, South Carolina. A single *E. schneideri* was recovered from a meningeal artery of a female deer.

**DISCUSSION**

This report constitutes the first account of clinical manifestation associated with and possibly caused by *E. schneideri* infection in a deer. Partial paralysis of the mylo-hyoideus muscles, which form the floor of the mouth, had occurred, permitting an accumulation of food particles, gradual stretching of the muscles, and subsequent enlargement of the sublingual space. This loss of function may have been related to diminished blood flow

caused by *E. schneideri* in the arterial system supplying this region.

Heretofore, *E. schneideri* has been considered a parasite of ruminants infrequenting high altitude ranges, i.e. greater than 1850 meters<sup>3,4,6,7</sup> in elevation. In the Southeast, deer harboring arterial worms were found on areas classed as lower coastal plain where the elevation was no more than 45 meters above sea-level.

Horseflies of the genera *Hybomitra* and *Tabanus* have been incriminated as vectors of *E. schneideri*<sup>2-4</sup> in the Southwest. A very rich horsefly fauna occurs in the Southeast, and in the authors' experience, horseflies appear to be more prevalent in the coastal plain than in the piedmont or mountain physiographic provinces of this region.

The discontinuous distribution of this helminth and absence from most localities in the Southeast suggest that *E. schneideri* was introduced into deer of this region. The source of infection is unknown. There are no zoos or game farms within the general vicinity of each enzootic county, however buffalo (*Bison bison*) share a common range with the Duval County, Florida deer. In any event, it appears that *E. schneideri* has failed to become prevalent in southeastern deer despite an abundance of intermediate and definitive hosts.

**Acknowledgements**

The authors would like to thank Mrs. May Belle Chitwood, National Animal Parasite Laboratory, Beltsville, Maryland, and Dr. Helen E. Jordan, School of Veterinary Medicine, Oklahoma State University, Stillwater, for aid in identification of *Elaeophora schneideri*.

**LITERATURE CITED**

1. ADCOCK, J. L., and C. P. HIBLER. 1969. Vascular and neuroophthalmic pathology of elaeophorosis in elk. *Path. Vet.* 6: 185-213.
2. ———, ———, Y. Z. ABDELBAKI, and R. W. DAVIS. 1965. Elaeophorosis in elk (*Cervus canadensis*). *Bull. Wildl. Dis. Assoc.* 1: 48.
3. HIBLER, C. P., and J. L. ADCOCK. 1971. Elaeophorosis. pp. 263-278. *In* Davis, J. W., and R. C. Anderson. *Parasitic Disease of Wild Mammals*. Iowa State Univ. Press, Ames, Iowa. 364 p.
4. ———, ———, R. W. DAVIS, and Y. Z. ABDELBAKI. 1969. Elaeophorosis in deer and elk in the Gila Forest, New Mexico. *Bull. Wildl. Dis. Assoc.* 5: 27-30.

5. \_\_\_\_\_, \_\_\_\_\_, G. H. GATES, and R. WHITE. 1970. Experimental infection of domestic sheep and mule deer with *Elaeophora schneideri*, Wehr and Dikmans, 1935. J. Wildl. Dis. 6: 110-111.
6. \_\_\_\_\_, \_\_\_\_\_, \_\_\_\_\_, \_\_\_\_\_, and B. R. DONALDSON. 1971. Observations on horseflies infected with larvae of *Elaeophora schneideri*. J. Wildl. Dis. 7: 43-45.
7. KEMPER, H. E. 1957. Filarial dermatosis of sheep. J. Am. Vet. Med. Assoc. 130: 220-224.
8. WALKER, MARTHA L., and W. W. BUCKLUND. 1970. Checklist of the internal and external parasites of deer, *Odocoileus hemionus* and *O. virginianus*, in the United States and Canada. Special Publication No. 1. Index-Catalogue of Medical and Veterinary Zoology. ARS, USDA. Washington, D.C. 45 p.

*Received for publication January 24, 1972*

---