

RICKETTSIA-LIKE ORGANISMS IN THE BLOOD OF *Turdus abyssinicus* IN KENYA

Author: PEIRCE, M. A.

Source: Journal of Wildlife Diseases, 8(3) : 273-274

Published By: Wildlife Disease Association

URL: <https://doi.org/10.7589/0090-3558-8.3.273>

BioOne Complete (complete.BioOne.org) is a full-text database of 200 subscribed and open-access titles in the biological, ecological, and environmental sciences published by nonprofit societies, associations, museums, institutions, and presses.

Your use of this PDF, the BioOne Complete website, and all posted and associated content indicates your acceptance of BioOne's Terms of Use, available at www.bioone.org/terms-of-use.

Usage of BioOne Complete content is strictly limited to personal, educational, and non - commercial use. Commercial inquiries or rights and permissions requests should be directed to the individual publisher as copyright holder.

BioOne sees sustainable scholarly publishing as an inherently collaborative enterprise connecting authors, nonprofit publishers, academic institutions, research libraries, and research funders in the common goal of maximizing access to critical research.

RICKETTSIA-LIKE ORGANISMS IN THE BLOOD OF *Turdus abyssinicus* IN KENYA

M. A. PEIRCE*, East African Veterinary Research Organization, Muguga, P.O. Kabete, Kenya.

Abstract: Rickettsia-like organisms are described from erythrocytes of *Turdus abyssinicus* from the Northern Frontier District of Kenya. Similar organisms from captive *Balearica pavonina* in England have been transmitted by blood inoculation to laboratory birds.

During a survey of haematozoa in birds from the Northern Frontier District of Kenya, the presence of unusual parasites in the erythrocytes was observed in 8 out of 20 *Turdus abyssinicus* (Olive thrush) examined from Mount Marsabit, 2° 15' N., 37° 55' E., 1615m above sea level. None of the other avian species examined during the survey was observed to harbour similar organisms.

Blood smears were made from a peripheral wing vein, fixed in methyl alcohol and stained in Giesma solution for one hour at pH 7.2. The parasitaemias ranged from 10 to 68%, and rarely more than one parasite per cell was observed. Generally the parasites were situated mid-way between the host cell membrane and nucleus. At first it was thought that the parasites were piroplasms, but a more detailed examination has shown that they have no distinct nucleus and cytoplasm.

The morphology resembled anaplasmod bodies of regular and irregular outline ranging from 0.5 μ to 1.3 μ in diameter. Some of the parasites were more elongated, but did not exceed 1.5 μ in length. In some cells the parasites appeared to be dividing, often with fine cytoplasmic strands giving the appearance of a cell membrane. It was these occurrences which at first had suggested that they might be piroplasms.

The general appearance of the parasites resembled the early stages of some previously described avian parasites^{3,4,5,7}. There are similarities also with the early stages of *Aegyptianella pullorum* which Bird and Garnham¹ have suggested is

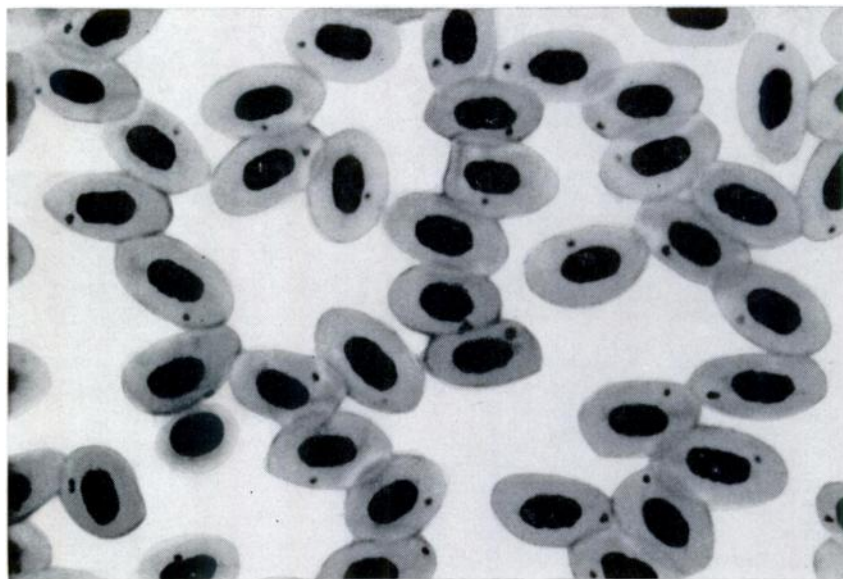
more closely related to the Rickettsia or psittacosis - lymphogranuloma-trachoma group of organisms. This group probably includes some of the "babesiods" described by other authors^{3,5,7}.

It seems likely that the parasites from *T. abyssinicus* belong to the Rickettsia group of organisms.

An observation made in 1965 is perhaps worth recording as it relates to a similar organism to that found in *T. abyssinicus*. During investigations into *Haemoproteus* sp. infections in captive *Balearica pavonina* (Crowned crane) at a zoological garden in Surrey, England (Peirce, unpublished results), blood was taken from one of the infected birds, diluted 1 in 5 with sterile saline and inoculated intravenously into laboratory reared birds (one turkey poult receiving 0.2 ml, one chicken poult 0.3 ml, one pheasant 0.5 ml and one pigeon 0.7 ml). From day 6 to day 10 following inoculation, parasites resembling those of *T. abyssinicus* were observed in the chicken, reaching a maximum parasitaemia of 15%. Parasites were observed also in the pheasant from days 6 to 8 although the level of parasitaemia was considerably lower (1 in 2000). No parasites appeared in either of the other birds. Although the general morphology resembled the parasites described from *T. abyssinicus*, some of the anaplasmod bodies were smaller, being less than 0.5 μ in diameter. Sub-clinical infections with Rickettsia-like organisms may be more common than is usually supposed.

During the Kenya survey, *T. abyssinicus* was the only avian species on which

*PRESENT ADDRESS: Department of Parasitology, Ministry of Agriculture, Fisheries and Food, Central Veterinary Laboratory, New Haw, Weybridge, Surrey, England.



Rickettsia-like organisms in the blood of *T. abyssinicus*. (x 1800).

a tick was found—a single nymph of *Ambylomma* sp. The only other tick species recorded from this host is *Ixodes walkerae*² (the host was identified as *T.*

olivaceus, a synonym of *T. abyssinicus*). It seems probable that either or both of these tick species could be the vector of the parasite recorded from *T. abyssinicus*.

Acknowledgements

I am grateful to Professor P. C. C. Garnham and Dr. J. R. Baker for examining the parasite from *T. abyssinicus* and for their advice. I am indebted also to Dr. Baker who kindly read the manuscript and offered invaluable suggestions during preparation. Mr. R. Sayer kindly produced the photomicrograph.

LITERATURE CITED

1. BIRD, R. G. and GARNHAM, P. C. C. 1967. *Aegyptianella pullorum* Carpano, 1928—Fine structure and taxonomy. *J. Protozool.* 14: Suppl. 42.
2. CLIFFORD, C. M., KOHLS, G. M. and HOOGSTRAAL, H. 1968. *Ixodes walkerae*, n.sp. from a bird in Kenya (Acarina: Ixodidae). *J. Med. Ent.* 5: 513-514.
3. HENRY, C. 1939. Présence dans les hématies de poulets d'éléments rappelant les corps de Balfour. *Bull. Soc. Path. exot.* 32: 145-149.
4. LAIRD, M. and LARI, F. A. 1957. The avian blood parasite *Babesia moshkovskii* (Schurenkova, 1938), with a record from *Corvus splendens* Vieillot in Pakistan. *Can. J. Zool.* 35: 783-795.
5. McNEIL, E. and HINSHAW, W. R. 1944. A blood parasite of the turkey. *J. Parasit.* 30: suppl. 9.
6. PEIRCE, M. A., and BACKHURST, G. C. 1970. Observations on the haematozoa found in birds from the Northern Frontier District of Kenya. *E. Afr. Wildl. J.* 8: 208-212.
7. ROUSSELOT, R. 1947. Parasites du sang de divers animaux de la région de Teheran. *Arch. Inst. Hessearek.* 5: 62-72.

Received for publication February 7, 1972