

Heterakis AND Histomonas INFECTIONS IN YOUNG PEA FOWL, COMPARED TO SUCH INFECTIONS IN PHEASANTS, CHICKENS, AND TURKEYS

Authors: LUND, EVERETT E., and CHUTE, ANNE M.

Source: Journal of Wildlife Diseases, 8(4) : 352-358

Published By: Wildlife Disease Association

URL: <https://doi.org/10.7589/0090-3558-8.4.352>

BioOne Complete (complete.BioOne.org) is a full-text database of 200 subscribed and open-access titles in the biological, ecological, and environmental sciences published by nonprofit societies, associations, museums, institutions, and presses.

Your use of this PDF, the BioOne Complete website, and all posted and associated content indicates your acceptance of BioOne's Terms of Use, available at www.bioone.org/terms-of-use.

Usage of BioOne Complete content is strictly limited to personal, educational, and non - commercial use. Commercial inquiries or rights and permissions requests should be directed to the individual publisher as copyright holder.

BioOne sees sustainable scholarly publishing as an inherently collaborative enterprise connecting authors, nonprofit publishers, academic institutions, research libraries, and research funders in the common goal of maximizing access to critical research.

Heterakis AND *Histomonas* INFECTIONS IN YOUNG PEAFOWL, COMPARED TO SUCH INFECTIONS IN PHEASANTS, CHICKENS, AND TURKEYS

EVERETT E. LUND and ANNE M. CHUTE, United States Department of Agriculture,
Agricultural Research Service, Animal Parasitology Institute*, Beltsville, Maryland 20705, U.S.A.

Abstract: Young peafowl (*Pavo cristatus*), when tested for susceptibility to histomoniasis by feeding embryonated eggs of *Heterakis gallinarum* carrying *Histomonas meleagridis*, were almost as susceptible to the disease as young Beltsville Small White turkeys. The disease developed more slowly, but, by 14 days after inoculation morbidity was 100% and 84% died. The young peafowl is so much more susceptible to histomoniasis than either chickens or pheasants that it should never be permitted to mingle with these birds, except where earthworms, the means of transmission of *Heterakis*, are absent. However, the young peafowl is unimportant in transmitting *Histomonas meleagridis* because the cecal worm rarely completes its life cycle in a young bird of this species when histomoniasis is present.

INTRODUCTION

The peafowl, *Pavo cristatus* L., 1758, was the third species of gallinaceous bird in which histomoniasis, then known as blackhead or infectious entero-hepatitis, was reported.^{20,19} Crawley and Stubbs³ described the disease in a peahen sent to the Pennsylvania Bureau of Animal Industry, and noted that the same disorder was listed as the cause of death of a peacock received at the same laboratory in 1913. Other reports of histomoniasis in peafowl in the United States include those of Dickinson⁴ from Oregon, Bump² from New York, and several reports from the New York State Veterinary College, where histomoniasis was found in 16 peafowl between 1948 and 1955.²¹ Similar reports are known from several other countries, including Spain,¹⁸ England,²² Czechoslovakia,¹ and Japan.²³ In Japan 54 peafowl died of histomoniasis at the Inokashira Zoological Park in Tokyo in 3 years, 1954-1956. The use of appropriate medication in 1956 apparently prevented further losses.

MATERIALS AND METHODS

The peachicks used for this study were purchased from a commercial grower who had been informed of the necessity for having chicks with no previous infections. Consequently, all were incubator hatched, and were brooded and maintained exclusively on wire at the game farm and later, at this laboratory. Because all hatches were small, never exceeding eight, birds from three biweekly hatches were used for this study. At inoculation, the youngest birds were 12 weeks old and the oldest were 16 weeks. At necropsy, we avoided sampling from a single age group.

Birds of three species for which responses to infections with *Histomonas meleagridis* (Smith, 1895) Tyzzer, 1920 and *Heterakis gallinarum* (Schrank, 1788) Madsen, 1949 are well known were used for comparison. Birds so used were Beltsville Small White turkeys 7 to 8 weeks old, New Hampshire chickens of comparable age, and ring-necked pheasants, *Phasianus colchicus* L., 1758, 9 to 10

*Formerly the National Animal Parasite Laboratory

weeks old. Because peafowl mature much more slowly than do the other birds, the age difference at inoculation was intentional. All birds were incubator hatched and brooded and maintained on wire. Because young birds of some species fail to gain properly when first caged individually, birds of all four species initially were placed two per cage.

The inoculum was obtained from chickens, but removed by only two generations of *H. gallinarum* from passage in both chickens and turkeys.¹⁰ It was a suspension of embryonated eggs of *H. gallinarum* of a strain known to transmit *Histomonas meleagridis* of sufficient virulence to cause mortality among young turkeys. The inoculum was pretested in young turkeys to enable us to estimate the minimum dose (number of embryonated eggs) to cause high mortality (but preferably not 100%) in our most susceptible breed. The dose selected was 80 embryonated eggs per bird, given in 1 ml of physiologic saline. Details of calibration and administration of the inoculum have been described in previous reports.^{7,9,12}

Because only 16 peafowl were available for inoculation, and 4 for uninoculated controls, the same numbers of the other

species were used. Where possible, two inoculated birds of each species were necropsied at each of eight intervals: 10, 14, 17, 21, 28, 35, 42 and 49 days following inoculation. Each experimental bird was examined for gross lesions, and fresh smears of the cecal contents and any liver lesions were examined microscopically for histomonads. All heterakids were washed from the ceca, counted, and sexed. When present, 10 worms of each sex from each bird were measured, and mature females were placed in 0.5% formalin solution to permit embryonation of eggs. The number of unembryonated and embryonated eggs were then counted so that the percentage of embryonation could be calculated, and the production of embryonated eggs produced per bird could be compared with the number given each bird initially. Entire female worms and embryonated eggs pooled from worms from comparable sources were later fed to young turkeys, to compare the ability of eggs from each source to transmit *Histomonas*.¹¹

RESULTS

The results are summarized in Tables 1 and 2, and in Figure 1.

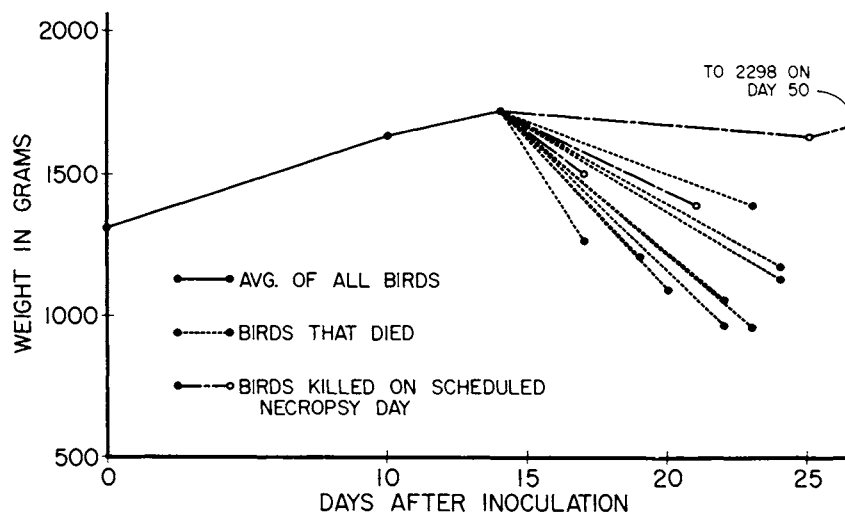


FIGURE 1. Influence of histomoniasis on weight gains of young peafowl.

TABLE 1. Responses of peafowl to *Histomonas meleagridis* infection, compared with those of young turkeys, chickens and pheasants.

	Peafowl	Turkey	Chicken	Pheasant
Incidence of infection (%):				
At 10 days	50 ¹	100	100	50
At 14 days	100	100	100	50
17-49 days	100	100	92	36
Overall	94 ¹	100	94	40
Liver lesions, incidence after 1st appearance (%):				
	92	100	0	0
Diameter of liver lesions (mm):				
At 14 days		4-5		
At 17 days	1	6-13		
Thereafter	2-7	6-11		
Mortality:				
Incidence after 1st occurrence (%)	84	100	0	0
Avg. day after inoc.	21.5	18.1		

¹Occasioned by 1 bird in which *H. meleagridis* was not detected at 10 days. Possibly it may have had too few to be detected. All other peafowl had *H. meleagridis*.

Because microscopic examinations of cecal discharges were not made during the first 10 days after inoculation, the first indications of infections with *H. meleagridis* were either abnormal appearance and behavior or the absence of normal cecal discharges, or both.

As shown in Table 1, infections with *H. meleagridis* developed more slowly in the peafowl than in either the turkeys or the chickens, but otherwise they closely resembled those in the turkeys. The ceca of both peafowl necropsied 10 days after inoculation appeared normal, but *H. meleagridis* was detected in the contents of one cecum of one bird. Thereafter, lesions developed rapidly. Both peafowl necropsied at 14 days had thick-walled ceca showing annulation^{8,10} and containing either soft cores or core fragments that had not yet consolidated. By the 14th day most of the 12 remaining peafowl appeared listless and were not eating well. Liver lesions, about 1 mm in diameter, were first detected in the two birds, one dead and one ill, examined on

the 17th day. Most of the remaining peafowl were obviously ill. As shown in Figure 1, only 1 of the 10 remaining peafowl was eating adequately. Eight of these 10 peafowl died from the 19th to the 24th day, inclusive; a 9th was moribund when killed for study on the 21st day after inoculation. Only one peafowl remained by the 28th day, so we deferred killing it as scheduled. By the 35th day, this bird was again making satisfactory gains, so we allowed it to complete the experiment. At necropsy on the 49th day, both ceca contained hard cores, and there were several adhesions of the ceca to the intestines, but there was no evidence of liver involvement. The four uninoculated peafowl had no indications of histomoniasis.

Some turkeys were obviously ill on the 8th day after inoculation. Cecal involvement with *H. meleagridis* was found in the two turkeys necropsied at 10 days, but neither had liver lesions. Thereafter, all turkeys had pronounced involvement of the liver as well as of the ceca. All

TABLE 2. Survival and development of *Heterakis gallinarum* in the young peafowl, compared with that in young turkeys, chickens and ring-necked pheasants.

	Peafowl		Turkey		Chicken		Pheasant	
10 days:								
% recovery	22.5		35.6		60.6		96.3	
Avg. length (mm)	3.1 ¹	2.7	2.8	2.5	3.1	2.8	3.4	3.1
14 days:								
% recovery	24.4		19.4		2.5		75.6	
Avg. length (mm)	3.5	3.4	3.3	2.9	2.5	2.5	4.2	3.9
17 days:								
% recovery	11.3		2.3		0		75.6	
Avg. length (mm)	4.6	3.6	3.8	3.3			5.5	4.9
21 days:								
% recovery	14.6		5.5		0		68.1	
Avg. length (mm)	5.6	4.8	4.5	4.1			8.0	6.7
28-49 days (worms old enough to be mature):								
No. of birds involved	1		0		8		7	
% worm recovery	12.5		0		3.9		67.7	
Range in length (mm)	6.5 - 7.0 - 10.0 8.5				6.2 - 5.5 - 10.2 8.3		10.0 - 8.2 - 14.0 11.1	
No. of female worms	4				16		179	
No. of females with eggs	1				5		179	
Avg. no. of eggs per female	2				189		188	
% of embryonation	0				29		27	
Total no. of embryonated eggs					274		9087	
Total no. of such eggs recovered for each given	0		0		0.4		16.2	
% of female worms with eggs transmitting <i>Histomonas</i>	0		0		40		10	
No. of embryonated eggs given per infection with <i>H. meleagridis</i>					137		133	

¹Values for females at left and males at right.

turkeys died, one on the 16th day after inoculation, four on the 17th day, two on the 18th day, four on the 19th day, and the last on the 21st day.

Some chickens voided blood with their cecal discharges by the 9th day after inoculation. Only one chicken escaped

infection with *H. meleagridis*, but all infections were transitory, involved only the ceca, and followed the typical pattern for histomoniasis in the young New Hampshire fowl.⁹

The ring-necked pheasants had their characteristic resistance to histomoniasis.¹⁴

One inoculated pheasant died early from self-inflicted injuries. Only 6 of the 15 pheasants that survived for study were ever found to harbor *H. meleagridis*, or have cecal responses indicating histomoniasis.

As shown in Table 2, *Heterakis gallinarum* did not thrive in the young peafowl. During the first 2 weeks, before the ceca were sufficiently involved with *Histomonas meleagridis* to affect worm development,¹⁰ worm recovery was about 23%. Subsequently, only about half as many heterakids remained. During the first 2 weeks, the worms were essentially normal in size,⁷ but thereafter retardation became increasingly conspicuous. The only peafowl to survive beyond the 4th week following inoculation had only one female heterakid, barely within the range of lengths for mature worms (10-14 mm). It contained eight eggs, none of which embryonated.

Heterakis gallinarum fared even worse in the young turkeys than it did in the peafowl. No turkey survived beyond the 3rd week, so no heterakids had the opportunity to mature. However, those heterakids that survived to the 21st day were so retarded that it is questionable whether they would have matured. The young turkey is a notoriously poor host for heterakids that carry a virulent strain of *Histomonas meleagridis*.^{9,13} With the strain of *Histomonas* carried by the cecal worms used for this study, *Heterakis* fared badly even in chickens. Only 5 of the 12 chickens remaining after the first 2 weeks had any heterakids. They had a total of only 22, of which 16 were females. Only five of these were mature, and collectively they contained only 274 eggs that embryonated. As 640 embryonated eggs had been given to the eight chickens that were kept 28 to 49 days, only 43% of the total embryonated eggs inoculated were recovered. The severe responses of the ceca to *Histomonas* infections had made them untenable habitats for most of the worms. The five mature female heterakids were fed to five young turkeys, one worm per bird. Only two of the poult developed histomoniasis, so at least 2 of the 274 eggs contained in the five females must have carried viable histomonads. Obviously, there could have

been more. There were not enough embryonated eggs to test the effects of giving pooled eggs.¹¹

In contrast, heterakids thrived in the pheasants throughout the 7-week study, returning 16 times as many embryonated eggs as had been given in the inoculum to the seven birds in which heterakids had the opportunity to mature. Only two of these seven pheasants are known to have harbored *H. meleagridis*. Of the 10 female heterakids fed individually to 10 test poults, two females were from each of the two pheasants that had once harbored *H. meleagridis*. Only one poult developed histomoniasis. It had been given a worm with 306 embryonated eggs. However, of 10 test poults each given 93 embryonated eggs (the average number of embryonated eggs in each of the 10 females fed intact), seven developed histomoniasis. Worms for both tests were taken in like numbers from the same pheasant sources for each test. Thus, by feeding the pooled eggs, one infection with *H. meleagridis* was produced for each 133 embryonated eggs given. Obviously, a female heterakid that carried any embryonated eggs capable of transmitting *Histomonas* must have been carrying several such eggs, in this instance. This situation is comparable, in principle, to that found many years ago¹¹ with the histomonad now known as *Parahistomonas wenrichi*.^{8,5}

DISCUSSION

Young peafowl are almost as susceptible to histomoniasis acquired by feeding embryonated eggs of *Heterakis gallinarum* from adult turkeys and young chickens as are young Beltsville Small White turkeys. The progress of the disease is slower than in young turkeys, but otherwise external and internal signs are similar. High mortality can be expected.

The young peafowl is much more susceptible to histomoniasis than are New Hampshire chickens, which, in our experience, are fairly representative of those breeds of chickens accustomed to being reared on the soil. Consequently, the practice sometimes observed in children's zoos, city parks and large gardens of

permitting peafowl and chickens to roam the same areas should be avoided. Some older peafowl seem to tolerate such associations. It has not been demonstrated experimentally whether the greater resistance to histomoniasis develops in all or most of the birds as they grow older, or whether the ones seen in such associations are merely the hardy survivors of a once numerous lot. Should the soil contain no earthworms, neither *Heterakis* nor *Histomonas* is likely to be transmitted frequently enough to be of importance.^{15,10} However, most parks, zoos, and gardens have at least some areas in which earthworms are found.

Young peafowl should not be permitted to traverse soil used by pheasants, unless earthworms are entirely absent. Because pheasants are often maintained in large flight cages, the nature of the substratum is more easily governed than in the parks at large. Such cages, if intended to confine various species of gallinaceous birds, could have deep bases of coarse gravel or

otherwise be constructed or treated to exclude earthworms.^{17,10}

The young peafowl is unimportant in contaminating the soil with infective stages of either *Heterakis gallinarum* or *Histomonas meleagridis* when both are present in the bird. In this respect, it ranks with the young turkey, and stands in marked contrast to the young chicken and young ring-necked pheasant. Indeed, in this study, the pheasant retained so many female *Heterakis* that it would have contaminated the soil with eggs capable of transmitting *Histomonas meleagridis* 8 times as frequently as the young chickens would have. Potentially, then, the ring-necked pheasant is, in this respect, the worst offender we have encountered. If this should also be true of other species of pheasants, keepers of ornamental birds including those with as different responses to *Histomonas* as peafowl and pheasants should take extreme care to protect their more susceptible birds.⁹

LITERATURE CITED

1. BELAK, M., and V. JURASEK. 1962. Histomonadova nakaza u pava. Vet. Casop. 6: 189-192.
2. BUMP, G. 1940. Bureau of Game. 29th Ann. Rep. New York State Conservation Dept. (1939): 230-270.
3. CRAWLEY, H., and E. L. STUBBS. 1922. Enterohepatitis in a peahen. J. Amer. vet. med. Assoc. 61: 443-444.
4. DICKINSON, E. M. 1930. Infectious entero-hepatitis in the peafowl. J. Amer. vet. med. Assoc. 76: 567-568.
5. HONIGBERG, B. M., and JELENA KULDOVA. 1969. Structure of a non-pathogenic histomonad from the cecum of galliform birds and revision of the trichomonad family *Monocercomonadidae* Kirby. J. Protozool. 16: 526-535.
6. LUND, E. E. 1955. The progress of histomoniasis (blackhead) in turkeys as related to the size of the infective dose. Poultry Sci. 34: 127-130.
7. ———. 1958. Growth and development of *Heterakis gallinae* in turkeys and chickens infected with *Histomonas meleagridis*. J. Parasitol. 44: 297-301.
8. ———. 1963. *Histomonas wenrichi* n. sp. (Mastigophora: Mastigamoebidae), a nonpathogenic parasite of gallinaceous birds. J. Protozool. 10: 401-404.
9. ———. 1967. Response of four breeds of chickens and one breed of turkeys to experimental *Heterakis* and *Histomonas* infections. Avian Dis. 11: 491-502.
10. ———. 1969. Histomoniasis. Adv. Vet. Sci. Comp. Med. 13: 355-390.
11. ———, and R. H. BURTNER, JR. 1957. Infectivity of *Heterakis gallinae* eggs with *Histomonas meleagridis*. Exper. Parasitol. 6: 189-193.

12. ———, and ———. 1958. Effect of four embryonation media on the embryonation and infectivity to chickens of *Histomonas*-bearing eggs of *Heterakis*. J. Parasitol. 44: 197-200.
13. ———, and ANNE M. CHUTE. 1970. Relative importance of young and mature turkeys and chickens in contaminating soil with *Histomonas*-bearing *Heterakis* eggs. Avian Dis. 14: 342-348.
14. ———, and ———. 1972. The ring-necked pheasant (*Phasianus colchicus torquatus*) as a host for *Heterakis gallinarum* and *Histomonas meleagridis*. Amer. Midl. Natur. 87: 1-7.
15. ———, E. E. WEHR, and D. J. ELLIS. 1966. Earthworm transmission of *Heterakis* and *Histomonas* to turkeys and chickens. J. Parasitol. 52: 899-902.
16. ———, ANNE M. CHUTE, and SARA L. MYERS. 1970. Performance in chickens and turkeys of chicken-adapted *Heterakis gallinarum*. J. Helminthol. 44: 97-106.
17. LYNCH, K. M. 1968. How to control blackhead in "wild" turkeys. Conserv. Catalyst 11: 19.
18. MEDINA BLANCO, M. 1949. Las protozoosis del pavo. Bol. Zootecnica, Cordoba 5: 101-113.
19. MELVIN, A. D. 1908. Twenty-third Annual Report of the Bureau of Animal Industry for the Year 1906. U.S. Dept. Agric., Govt. Printing Office, Washington, D.C.
20. MOHLER, J. R. 1905. Blackhead, or infectious entero-hepatitis in turkeys. U.S. Dept. Agric., Bur. Animal Industry, Circ. No. 5 (revised).
21. New York State Veterinary College, Reports of, 1948-1955.
22. REWELL, R. E. 1950. Report of the society's pathologist for the year 1949. Proc. Zool. Soc. London 120: 485-495.
23. TSUNODA, K., and T. TATEIWA. 1958. Studies on the control of entero-hepatitis (blackhead) in peafowl chickens. Nat. Inst. Animal Health, Tokyo, Bull. No. 35: 149-159.

Received for publication May 1, 1972