



## CEREBRAL NEMATODIASIS IN A RED SQUIRREL

Author: SCHUELER, RONALD L.

Source: Journal of Wildlife Diseases, 9(1) : 58-60

Published By: Wildlife Disease Association

URL: <https://doi.org/10.7589/0090-3558-9.1.58>

---

BioOne Complete ([complete.BioOne.org](https://complete.BioOne.org)) is a full-text database of 200 subscribed and open-access titles in the biological, ecological, and environmental sciences published by nonprofit societies, associations, museums, institutions, and presses.

Your use of this PDF, the BioOne Complete website, and all posted and associated content indicates your acceptance of BioOne's Terms of Use, available at [www.bioone.org/terms-of-use](https://www.bioone.org/terms-of-use).

Usage of BioOne Complete content is strictly limited to personal, educational, and non - commercial use. Commercial inquiries or rights and permissions requests should be directed to the individual publisher as copyright holder.

---

BioOne sees sustainable scholarly publishing as an inherently collaborative enterprise connecting authors, nonprofit publishers, academic institutions, research libraries, and research funders in the common goal of maximizing access to critical research.

## CEREBRAL NEMATODIASIS IN A RED SQUIRREL

RONALD L. SCHUELER, Department of Veterinary Science, University of Maryland, College Park, Maryland 20740, U.S.A.

**Abstract:** Necropsy of a South American red squirrel (*Sciurus granatensis*), with clinical signs of neurological disease, disclosed multifocal parasitic granulomata in the brain, lung and myocardium. Lesions were noted in the cerebral hemispheres and subcerebellar white matter. The parasite was identified as a larval ascarid. History of close contact with excreta from raccoons suggested the larvae were that of *Ascaris columnaris*, an intestinal nematode of the raccoon.

### HISTORY

On October 29, 1971, a South American red squirrel was submitted for necropsy because of unusual neurologic behavior. Rabies was suspected. The animal had been housed for about 7 months in a wooden-bottomed cage which was previously occupied by raccoons.

### NECROPSY AND HISTOLOGIC FINDINGS

Gross lesions were limited to the capsular surfaces of the kidneys and consisted of irregular patches of fibrino-purulent exudate.

Histologic examination of various tissues disclosed foci of granulomatous inflammation in the gray matter of the cerebral hemispheres, subcerebellar white matter, myocardium, and around pulmonary bronchioles. Focal gliosis, occasional neuron necrosis, hemorrhage, perivascular aggregates of lymphocytes and plasma cells, and sometimes malacia accompanied the granulomatous lesions in the brain. Cross sections of larval ascarids were found in lesions of the brain and lung (Fig. 1). The parasite was not detected in other organs.

### DISCUSSION

*Ascaris columnaris*, a common intestinal nematode of raccoons, is infective for rodents, and can produce central nervous system disturbance.<sup>3,7,8</sup> Eggs in feces become infective in about 1 month when kept at room temperature.<sup>2</sup> Sprent<sup>4</sup> showed that experimental infection of mice with *A. columnaris* produced clinical signs of central nervous system damage several months after infection, and that the migrating larvae remained viable in the brain tissue up to 6 months post-infection. Naturally occurring cerebral nematodiasis, presumably due to *A. columnaris*, has been reported in the ground squirrel (*Citellus tridecemlineatus*).<sup>1</sup> In this report, development of clinical signs of neurologic disturbance occurred 2 weeks to 9 months after capture. A similar condition due to *A. columnaris* has been reported in the groundhog (*Marmota monax*).<sup>5</sup>

To the author's knowledge, there has been one published report of cerebral nematodiasis in squirrels (*Sciurus carolinensis*).<sup>6</sup> In that study, eggs from *A. columnaris*, taken from a raccoon, were embryonated and fed to gray squirrels. Central nervous system disturbance resulted. Histopathologic examination of

Approved for publication as scientific article number A1783, contribution number 4573 of the University of Maryland, Agricultural Experiment Station, Dept. of Veterinary Science, College Park, Maryland.

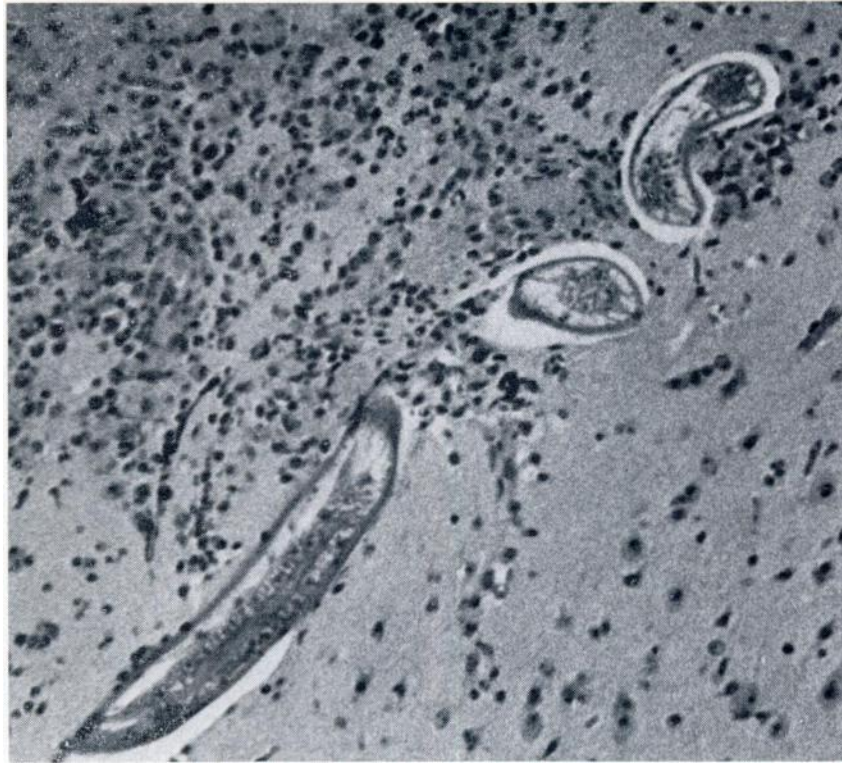


FIG. 1. Section of cerebral hemisphere. Note the larval ascarids and the focal granulomatous inflammation (x 126).

the brains from these animals, however, was not reported.

The time interval from initial exposure of the red squirrel to raccoon feces, to the onset of clinical signs (incubation period) is consistent with that reported for experimental infection of mice with *A. columnaris*. The incubation period is also similar to that reported for naturally infected ground squirrels.

Although the ascarid larvae in this case

were not specifically identified as *A. columnaris*, the history of exposure to raccoon feces, and the incubation period suggest that aberrant infection with this parasite is the most likely explanation for the lesions observed. These findings also emphasize that visceral larva migrans, with cerebral nematodiasis as the most outstanding feature, should be considered in any neurological disturbance in squirrels.

#### Acknowledgements

The author wishes to thank Dr. Vagn Flyger, Natural Resources Institute, University of Maryland, and Dr. Henry W. Setzer, Smithsonian Institution, Washington, D.C., for species identification of the squirrel. The author is also grateful to Dr. Ralph Lichtenfels, U.S.D.A., Animal Disease and Parasite Research Division, Beltsville, Maryland for assistance in identification of the parasite in sections.

## LITERATURE CITED

1. FRITZ, T. E., D. E. SMITH, and R. J. FLYNN. 1968. A central nervous system disorder in ground squirrels (*Citellus tridecimlineatus*) associated with visceral larva migrans. J. Amer. vet. med. Assoc. 153: 841-844.
2. MOZGOVOI, A. A. 1968. Ascaridata of animals and man, Part 1. In Skrjabin, K. I., ed. *Essentials of Nematodology*. II., Office of Technical Services, U.S. Dept. of Commerce, Washington, D.C. pp. 77-79.
3. OLSEN, O. W., and R. FENSTERMACHER. 1938. The raccoon, a new host of *Ascaris columnaris*. Leidy, 1856. Proc. Helminth Soc. Wash. 5: 20.
4. SPRENT, J. F. A. 1955. On the invasion of the central nervous system by nematodes. II Invasion of the nervous system in ascariasis. Parasit. 45: 31-40.
5. SWERCZEK, T. A., and C. F. HELMBOLDT. 1970. Cerebrospinal nematodiasis in groundhogs (*Marmota monax*). J. Amer. vet. med. Assoc. 157: 671-674.
6. TINER, J. D. 1949. Preliminary observations on the life history of *Ascaris columnaris*. J. Parasit. 35, 2 (Supplement): 13.
7. TINER, J. D. 1953. The migration, distribution in the brain, and growth of ascarid larvae in rodents. J. inf. Dis. 92: 105-113.
8. WALLER, E. F. 1940. Infectious gastroenteritis in raccoons (= *Procyon lotor*). J. Amer. vet. med. Assoc. 96: 266-268.

Received for publication June 30, 1972