



Ophidascaris filaria (DUJARDIN 1845) FROM THE AFRICAN ROCK PYTHON, *Python sebae*, IN THE SUDAN, WITH A NOTE ON ASSOCIATED GASTRIC LESIONS

Authors: ELBIHARI, S., and HUSSEIN, M. F.

Source: Journal of Wildlife Diseases, 9(2) : 171-173

Published By: Wildlife Disease Association

URL: <https://doi.org/10.7589/0090-3558-9.2.171>

BioOne Complete (complete.BioOne.org) is a full-text database of 200 subscribed and open-access titles in the biological, ecological, and environmental sciences published by nonprofit societies, associations, museums, institutions, and presses.

Your use of this PDF, the BioOne Complete website, and all posted and associated content indicates your acceptance of BioOne's Terms of Use, available at www.bioone.org/terms-of-use.

Usage of BioOne Complete content is strictly limited to personal, educational, and non - commercial use. Commercial inquiries or rights and permissions requests should be directed to the individual publisher as copyright holder.

BioOne sees sustainable scholarly publishing as an inherently collaborative enterprise connecting authors, nonprofit publishers, academic institutions, research libraries, and research funders in the common goal of maximizing access to critical research.

***Ophidascaris filaria* (DUJARDIN 1845) FROM THE
AFRICAN ROCK PYTHON, *Python sebae*,
IN THE SUDAN, WITH A
NOTE ON ASSOCIATED GASTRIC LESIONS**

S. ELBIHARI and M. F. HUSSEIN, Faculty of Veterinary Science,
P.O. Box 32, Khartoum North, Sudan

Abstract: A new record of *Ophidascaris filaria* from *Python sebae* constitutes the first report of the nematode from the Sudan and the fifth from the African rock python. The worms were found to have spicules much shorter than those reported in the accepted description of the species. A lesion associated with the worms comprised granulomatous and pre-neoplastic changes.

INTRODUCTION

There are only four reports of *Ophidascaris filaria* in the African rock python. New records from different localities might therefore shed light on the distribution of this nematode and also help to clarify the confusion in the systematics of the genus. Because they are not mentioned in the literature, a study of the lesions associated with the parasite was considered worthwhile.

MATERIAL AND METHODS

An African rock python was found recently dead from a head wound 80 km south of Idd ElGhanam, Darfur. After it was skinned, the stomach was opened and 18 round worms were seen free in the lumen, crowded in the posterior half of the organ. These were still alive when removed and placed in glycerine-alcohol. Further inspection of the stomach revealed a firm swelling, about 5 cm in diameter, protruding in the lumen. Six worms had their anterior ends inserted into the middle of this swelling; they were firmly attached and could be removed only with difficulty. A thin sheath, possibly of host origin, surrounded the inserted parts. The whole lesion was removed, cut into smaller portions and placed in 10 percent buffered formalin. Several paraffin sections were made and

stained with haematoxylin and eosin, Gomori's reticulin stain and periodic-acid-Schiff reagent (PAS).

FINDINGS

When removed the worms were dull yellow and showed no trace of ingested blood. Table 1 gives the measurements made on some of the specimens. Although the body length, measurements of various organs and ova were found to fall within the ranges described for *O. filaria* by Baylis,¹ and Sprent,² a remarkable exception was the lengths of the spicules, which in this study were strikingly short (1.47-1.58 mm).

Grossly, the lesion presented a smooth, rounded, non-pedunculated appearance (Fig. 1). When sectioned, numerous, intercommunicating cysts of varying sizes were seen in the submucosa. These contained intact parasites, or remnants thereof, calcified material and necrotic debris (Fig. 2). A few cysts had a central core of degenerated eosinophils. Each cyst was walled by three or four rows of cells with pale, vesiculated nuclei and faint cytoplasm, and surrounded by concentric layers of fibrous connective tissue and large numbers of eosinophils. The submucosa also showed scattered granulomas (Fig. 3) and a heavy submucosal inflammatory reaction which merged focally into areas of poorly differentiated cells,

TABLE 1. Measurements of *O. filaria* from the Sudan (ranges in mm).

	Males (5)*	:	Females (8)*
Body length	89 - 101		130 - 146
Oesophagus	3.7 - 4.8		3.9 - 4.9
Spicules			
Length	1.47 - 1.58		—
Width**	0.08 - 0.94		—
Position of vulva (% body length from anterior end)	—		14:9 - 7:5
Eggs	—		0.060 - 0.075

* Number of worms from which range was obtained.

** Measurement at greatest width.

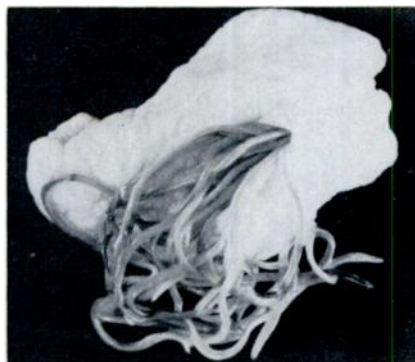

FIGURE 1. Portion of gastric lesion showing attached worms.

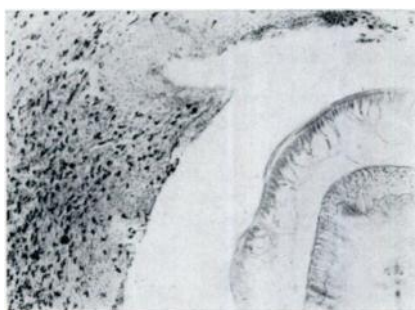

FIGURE 2. Section of stomach showing submucosal cyst containing parasite. Haematoxylin and Eosin. X 240.

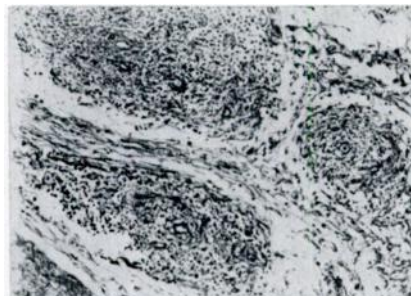


FIGURE 3. Section of stomach showing submucosal granulomas. PAS. X 240.

suggestive of pre-neoplastic change. In these areas, the cells were polyhedral or spindle-shaped, and some were binucleated. Many of them had prominent nucleoli and nuclear membranes, hyperchromatosis and occasional mitotic figures. The stroma of these areas showed mucoid degeneration and a few haemorrhagic streaks.

DISCUSSION

An important morphological finding in the present specimens of *O. filaria*, compared to those studied by other authors, is the short length of the spicules. Baylis¹ reported a spicule length of 4.0 - 4.8 mm in worms up to 110.0 mm long, while

in seven worms measuring 78.0 - 134 mm in length Sprent⁵ found that the spicules varied from 3.7 to 5.5 mm. The shortest spicules seen in *O. filaria* were reported by Robinson⁴ from Malayan *Python reticulatus*; their lengths were from 1.75 to 2.2 mm. Because of uncertainties of the taxonomy of nematodes belonging to this genus, Sprent⁵ proposed to synonymize *O. rubicunda*, *O. infundibulicola*, *O. baylisi* and *O. amucronata* with *O. filaria*. However, the same author⁵ presented fresh evidence on the basis of which he suggested splitting the Australian and Asian groups into four species; African specimens were, however, not included in this revision.

Although it is possible that further information on the morphology of African *O. filaria* obtained from future collections could justify separation of this group within the genus into strains, variants or sub-species, the reduced spicular measurements in the worms described in this report would not, as yet, justify creating a new subspecific category.

The definitive association of granulomatous and neoplastic lesions with nematodes has been reported as early as 1913

when Fibiger (cited by Poynter³) described carcinomas in the stomachs of rats infected with *Gongylonema neoplasticum*. Although in that particular example, a causal relationship was not demonstrated, another nematode, *Spirocerca lupi* was shown to produce neoplastic lesions in the cesophagus of the dog; Poynter³ reviewed the literature supporting this causal relationship.

To our knowledge, *O. filaria* has not been reported to cause any lesions in pythons and other occasional snake hosts. This is partly attributable to the paucity of material available for study, but could also be an indication of a lack of severe host reaction. However, Cooper and Nares² believe that *Ophidascaris* spp., when present in large numbers, may reduce resistance to infection in reptiles, and Telford⁷ states that these parasites may sometimes cause gastric occlusion and digestive disturbances. The granulomatous and pre-neoplastic lesions reported here may have only fortuitous relationship to the nematode. If so, the worms may have had an exacerbating effect that contributed to the development of the lesions to the stage described here.

Acknowledgement

We are grateful to Dr. I. D. Gibson of the British Museum (Natural History) for identifying the parasite.

LITERATURE CITED

1. BAYLIS, H. A. 1920. On the classification of the *Ascaridae*. II. The *Polydelphis* group with some account of other ascarids parasitic in snakes. *Parasitol.* 12: 411-426.
2. COOPER, J. E., and P. NARES. 1971. Clinical and post-mortem examination of snakes at the Nairobi Snake Park. *E. Afr. Wildl. J.* 9: 166-170.
3. POYNTER, D. 1966. Some tissue reactions to the nematode parasites of animals. *In Advances in Parasitology* 4; Ben Dawes, ed. pp. 321-383.
4. ROBINSON, V. C. 1934. On a collection of parasitic worms from Malay. I. Nematodes (*Superfamilies Ascaroidea* and *Oxyuroidea*). *Parasitol.* 26: 481-488.
5. SPRENT, J. F. A. 1969. Studies on ascaridoid nematodes in pythons: redefinition of *Ophidascaris filaria* and *Polydelphis anoura*. *Parasitol.* 59: 129-140.
6. ———. 1969. Studies on ascaridoid nematodes in pythons: speciation of *Ophidascaris* in the Oriental and Australian regions. *Parasitol.* 59: 937-959.
7. TELFORD, S. R. 1971. Parasitic diseases of reptiles. *J. Amer. Vet. Med. Assoc.* 159: 1644-1652.

Received for publication December 18, 1972