



Bilateral patellar fractures and increased cortical bone thickness associated with long-term oral alendronate treatment in a cat

Authors: Council, Nicola, Dyce, Jon, Drost, Wm Tod, de Brito Galvao, Joao Felipe, Rosol, Thomas J, et al.

Source: Journal of Feline Medicine and Surgery Open Reports, 3(2)

Published By: SAGE Publishing

URL: <https://doi.org/10.1177/2055116917727137>

BioOne Complete (complete.BioOne.org) is a full-text database of 200 subscribed and open-access titles in the biological, ecological, and environmental sciences published by nonprofit societies, associations, museums, institutions, and presses.

Your use of this PDF, the BioOne Complete website, and all posted and associated content indicates your acceptance of BioOne's Terms of Use, available at www.bioone.org/terms-of-use.

Usage of BioOne Complete content is strictly limited to personal, educational, and non - commercial use. Commercial inquiries or rights and permissions requests should be directed to the individual publisher as copyright holder.

BioOne sees sustainable scholarly publishing as an inherently collaborative enterprise connecting authors, nonprofit publishers, academic institutions, research libraries, and research funders in the common goal of maximizing access to critical research.



Bilateral patellar fractures and increased cortical bone thickness associated with long-term oral alendronate treatment in a cat

Journal of Feline Medicine and Surgery Open Reports
1–6

© The Author(s) 2017

Reprints and permissions:

sagepub.co.uk/journalsPermissions.nav

DOI: 10.1177/2055116917727137

journals.sagepub.com/home/jfmsopenreports

This paper was handled and processed by the American Editorial Office (AAFP) for publication in *JFMS Open Reports*



Nicola Council¹, Jon Dyce², Wm Tod Drost²,
Joao Felipe de Brito Galvao³, Thomas J Rosol⁴
and Dennis J Chew²

Abstract

Case summary A 14-year-old cat presented with bilateral patellar fractures and radiographically thickened tibial cortices. This cat had been treated with alendronate for 8 years prior to presentation. To remove the subjectivity of the radiographic evaluation, tibial radiographs from 35 apparently healthy geriatric cats were used for comparison. Cortical and diaphyseal thickness were measured at the proximal and distal thirds of the tibia. Our cat had increased cortical bone thickness compared to that of the control cats.

Relevance and novel information Treatment with bisphosphonates can lead to brittle bones and fractures after prolonged use in humans. This is the first description of fractures and cortical bone changes that may have been associated with prolonged bisphosphonate use in a cat. Radiographic measurements of cortical bone thickness may identify cats that are at increased risk for bone pathology secondary to prolonged alendronate use.

Accepted: 4 July 2017

Case description

A 14-year-old castrated male Maine Coon cat presented for left hindlimb lameness of 1 day's duration without known trauma. Physical examination revealed a non-weightbearing lameness on the left hindlimb, with sensitivity upon palpation of the stifle. The stifle joint was stable and there was no swelling. Following sedation, orthogonal radiographs were made of the pelvis and stifles. A complete transverse fracture of the left patella with mild proximal displacement of the base was documented. There was severe sclerosis of the patella with loss of corticomedullary demarcation (Figure 1). There was no stifle effusion or soft tissue swelling. A focal region of the cranial and caudal cortex of the left tibia were thickened and the fibula did not have a distinct medullary canal (Figure 1). The right patella was also sclerotic but had no evidence of a fracture. The cat was treated with oral buprenorphine (15 µg/kg transmucosally) for pain management, along with restricted activity, and it recovered

well. Two months following the initial lameness, the cat was re-presented for acute right hindlimb lameness. Radiographs confirmed a complete transverse fracture of the right patella, sclerosis of the right patella and a non-union fracture of the left patella (Figure 2a,b). Pain management and rest were re-instituted and the cat was doing well approximately 1 month after the second patellar fracture.

¹Hillside Animal Hospital, Scottsdale, AZ, USA

²Department of Veterinary Clinical Sciences, College of Veterinary Medicine, The Ohio State University, Columbus, OH, USA

³VCA Arboretum View Animal Hospital, Downers Grove, IL, USA

⁴Department of Veterinary Biosciences, College of Veterinary Medicine, The Ohio State University, Columbus, OH, USA

Corresponding author:

Dennis J Chew DVM, DACVIM, Professor Emeritus, 601 Vernon L Tharp St, Columbus, OH 43210 USA
Email: chew.1@osu.edu



Creative Commons Non Commercial CC BY-NC: This article is distributed under the terms of the Creative Commons

Attribution-NonCommercial 4.0 License (<http://www.creativecommons.org/licenses/by-nc/4.0/>) which permits non-commercial use, reproduction and distribution of the work without further permission provided the original work is attributed as specified on the SAGE and Open Access pages (<https://us.sagepub.com/en-us/nam/open-access-at-sage>).

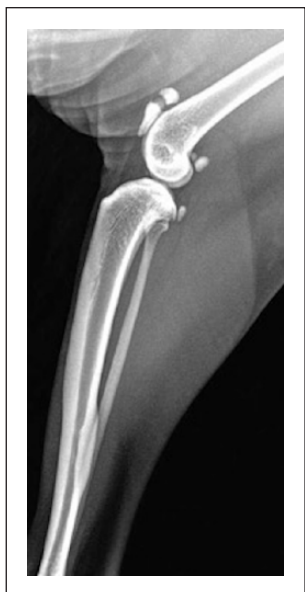

Figure 1 Medial lateral radiograph of a left stifle/tibia made at initial presentation showing a complete transverse fracture of the patella with mild proximal displacement of the proximal segment. There is severe trabecular sclerosis of the patella associated with reduced medullary canal thickness. The cranial and mid-diaphyseal cortices of the tibia are thickened. The fibula does not have a distinct medullary canal

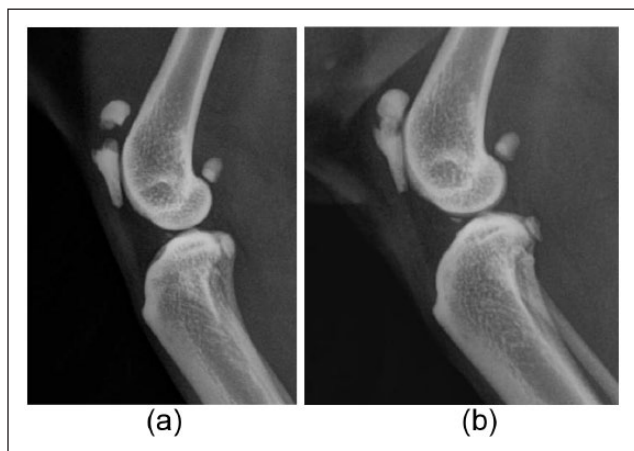


Figure 2 (a) Medial lateral radiograph of the right stifle taken 2 months after the left patellar fracture was diagnosed, showing a complete transverse fracture of the patella with mild proximal displacement of the base. There is trabecular sclerosis of the patella. (b) Medial lateral radiograph of left stifle taken 2 months after the initial radiographs (compare with Figure 1) showing a non-union fracture of the left patella

Further review of the cat's medical history revealed that this cat had received alendronate (5 mg PO once weekly) for the past 8 years. A veterinary dental specialist had initially prescribed alendronate to prevent

further development of tooth resorption, following extraction of multiple teeth affected by this condition. At 13 years of age the cat's serum creatinine was 2.1 mg/dl (reference interval [RI] 0.8–2.3 mg/dl) and blood urea nitrogen was also within the RI. A complete urinalysis revealed a urine specific gravity (USG) of 1.050 at this time. In the 8 years during which the cat was treated with alendronate, serum calcium and phosphorus were within the RIs on numerous serum biochemical panels; magnesium was not measured. Serum creatinine exceeded the RI three times during this time period but was most often in the upper-third of the RI. Paired USGs during this time frame were ≥ 1.050 .

Radiographs of this cat's tibia were compared with those from a group of geriatric cats ≥ 8 years old that presented to the orthopedic service for investigation of hindlimb lameness and had images of the whole tibia, including lateral and craniocaudal projections, allowing measurements to be taken. Thirty-five cats were identified from The Ohio State University – Veterinary Medical Center digital radiography archive from 2003–2013. Complete radiographic studies were not available for all cats. Age ranged from 8–20 years (median 12 years). Sex distribution included 20 castrated males, two intact males and 13 spayed females. The most common indications for imaging were stifle osteoarthritis and tibial fracture associated with trauma. These cats were normal based on history and physical examination, other than that related to the musculoskeletal system. Serum creatinine was measured in 27 of these cats. Serum creatinine was a median of 1.6 mg/dl (range 0.6–2.8 mg/dl) in 27 cats. Serum creatinine was within the RI in 20 cats and >2.0 in seven cats.

Measurements of the tibia were made using a digital caliper applied perpendicular to the tibial long axis at two locations in both the mediolateral and craniocaudal radiographic projections (Figure 3). One set of measurements was made proximally at the junction of the proximal and middle thirds of the tibia (distal to the tibial crest), and the second set was taken distally at the junction of the middle and distal thirds of the tibia. The width of the cranial and caudal cortex was determined on the mediolateral projection, and the width of the medial and lateral cortex on the craniocaudal projection. The external diameter of the bone was measured at both proximal and distal sites on both radiographic projections. The diameter of the medullary canal was calculated by subtraction of the cortical measurement from the total diameter measurement. To compensate for variability in tibial size between cats and allow comparison with the cat of this report, measurements were expressed as percentages of external cortical diameter (Table 1). Compared with this population of control cats, the cat of this case report had greater cortical bone

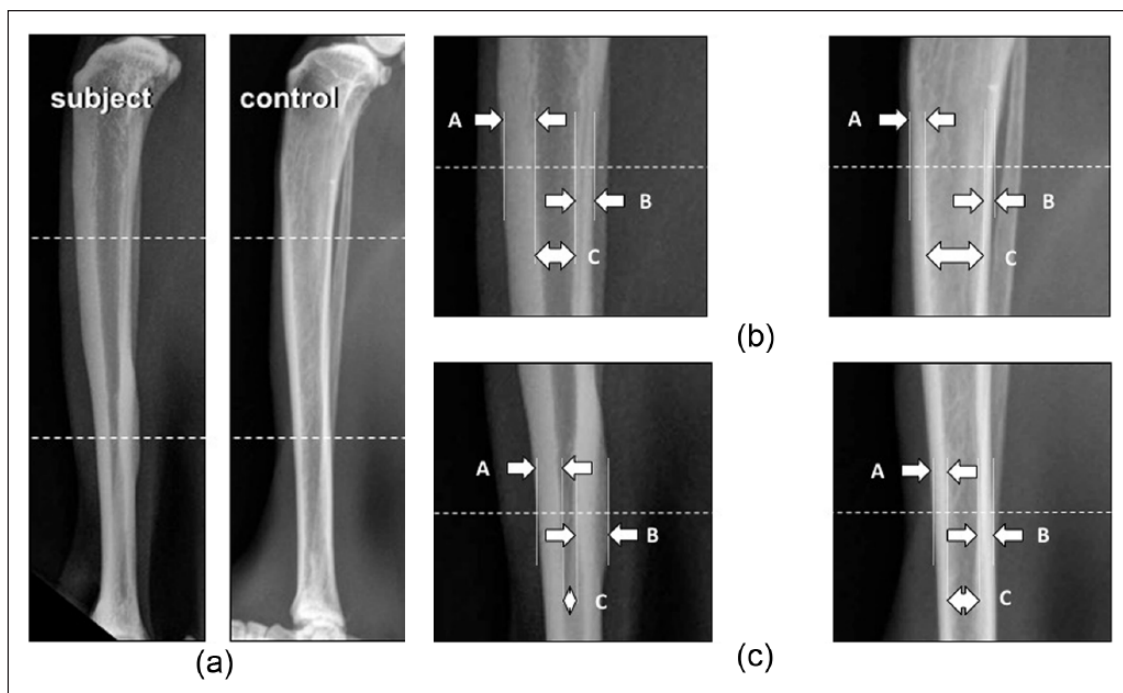


Figure 3 (a) Lateral radiographic projection of the subject and control tibia. Measurements of the tibia were taken perpendicular to the tibial long axis proximally at the junction of the proximal third and distal two-thirds of the tibia, and distally at the level of the junction of the proximal two-thirds and distal third of the tibia. (b) Proximal measurement. The width of the (A) cranial and (B) caudal cortex and the diameter of the bone were measured using a digital caliper. The diameter of the (C) medullary canal was calculated by subtraction. (c) Distal measurement. The width of the (A) cranial and (B) caudal cortex, and the diameter of the bone were measured using a digital caliper. The diameter of the (C) medullary canal was calculated by subtraction

thickness and a narrower medullary canal. Figure 4 shows the comparison of all radiographic measurements taken. Measurements of the medullary canal diameter that were most likely to differentiate controls from the subject were taken from the distal craniocaudal (median was 59% in controls vs 33.5% in subject) and lateral projections (median was 52.5% in controls vs 31.5% in subject), and from the proximal craniocaudal projection (median was 54% in controls vs 34% in subject).

Discussion

We believe that this is the first clinical report of bone fracture associated with long-term bisphosphonate treatment in the cat. This cat developed bilateral patellar fractures in association with osteosclerosis of both patellae (Figures 1 and 2a,b). Additionally, the cortices of the tibia were thickened and the medullary canal narrowed compared with a control group of geriatric cats. Reports of increased bone opacity and cortical thickness in cats are scarce. Although the cat of this case report may have had undiagnosed early chronic kidney disease (CKD), cats with CKD are more likely to have reduced bone density or osteopenia as a consequence of CKD mineral and bone disorder,

including renal secondary hyperparathyroidism, rather than increased radiographic bone opacity and increased cortical thickness.^{1,2}

There have not been any previous reports of cats receiving alendronate that developed patellar fractures, increased cortical bone thickening or osteopetrosis. Cats with either osteopetrosis or patellar fractures tend to be younger than the cat of this report.³ Stress fractures of the patella unassociated with external trauma have been described in 34 young cats (median age 2 years 5 months).³

Alendronate is a third-generation amino-bisphosphonate used not only to treat disorders that lead to excess bone resorption in humans, including osteoporosis and Paget's disease, but also has other uses such as treatment for hypercalcemia, multiple myeloma and hyperparathyroidism. Bisphosphonates inhibit osteoclastic bone resorption through decreases in the function and number of osteoclasts.⁴ Bisphosphonate treatment in cats is mainly used to decrease the concentration of circulating ionized calcium in cats with idiopathic hypercalcemia,⁵⁻⁷ and occasionally for cats with granulomatous disease or malignancy-associated hypercalcemia.⁸ Since the odontoclast appears to be similar to the osteoclast in structure and function,⁹ oral

Table 1 Radiographic measurement of the tibial cortex and medulla expressed in percentage of control cats and cat with fractured patellae

Control cases	Proximal lateral: cranial cortex (%)		Proximal lateral: cranial medullary canal (%)		Proximal lateral: caudal cortex (%)		Proximal lateral: caudal medullary canal (%)		Proximal cranial: lateral cortex (%)		Proximal cranial: lateral medullary canal (%)		Proximal cranial: caudal cortex (%)		Proximal cranial: caudal medullary canal (%)		Distal cranial: lateral cortex (%)		Distal cranial: lateral medullary canal (%)		Distal cranial: caudal cortex (%)		Distal cranial: caudal medullary canal (%)		
	Number of values	Minimum	Median	SD	Maximum	Number of values	Minimum	Median	SD	Maximum	Number of values	Minimum	Median	SD	Maximum	Number of values	Minimum	Median	SD	Maximum	Number of values	Minimum	Median	SD	Maximum
	27	11	29	5.7	38	27	9	20	4.1	27	24	12	25	3.9	30	24	10	22.5	4.6	28	24	42	52.5	7.6	78
	2	2	2	2	2	2	2	2	2	2	2	2	2	2	2	2	2	2	2	2	2	2	2	2	2
	39	39.5	0.7	40	23	23	23	0.0	23	37	35	36	1.4	37	31	31.5	0.7	33	33	33.5	0.7	34	34	2.1	34
	31	31	31	31	31	31	31	31	31	31	31	31	31	31	31	31	31	31	31	31	31	31	31	31	31
	33.5	33.5	33.5	33.5	33.5	33.5	33.5	33.5	33.5	33.5	33.5	33.5	33.5	33.5	33.5	33.5	33.5	33.5	33.5	33.5	33.5	33.5	33.5	33.5	33.5
	0.0	0.0	0.0	0.0	0.0	0.0	0.0	0.0	0.0	0.0	0.0	0.0	0.0	0.0	0.0	0.0	0.0	0.0	0.0	0.0	0.0	0.0	0.0	0.0	0.0
	23	23	23	23	23	23	23	23	23	23	23	23	23	23	23	23	23	23	23	23	23	23	23	23	23
	32	32	32	32	32	32	32	32	32	32	32	32	32	32	32	32	32	32	32	32	32	32	32	32	32
	36	36	36	36	36	36	36	36	36	36	36	36	36	36	36	36	36	36	36	36	36	36	36	36	36

alendronate treatment has been used by some veterinary dentists to prevent the progression of feline tooth resorption. Currently, bisphosphonate treatment is not a widely accepted treatment for this condition.¹⁰

The long-term effects of bisphosphonate treatment on bones of cats in veterinary clinical practice have not been reported, as bone radiographs have not been included as part of the routine diagnostic evaluation before and after treatment with bisphosphonates. A study of the effects of sodium etidronate in cats as a model for use in humans revealed increased overall bone width.¹¹ The cat of this report received 5 mg alendronate (Fosamax; Merck) orally once a week for 8 years. This dose is below the average dose of 10 mg orally once a week for cats with idiopathic hypercalcemia given for 6 months.⁵ The maximal time of alendronate treatment was 11 months in five cats,¹⁰ 6 months in 12 cats⁵ and 30 months in a single cat,⁷ periods of time far shorter than in the cat of this report. Radiographs of long bones from these cats were not taken during bisphosphonate treatment.

No obvious adverse clinical effects were noted during 6 months of treatment with oral alendronate in 12 cats with a likely diagnosis of idiopathic hypercalcemia, although hypocalcemia developed in two of these cats.⁵ No adverse clinical or biochemical effects were reported in five female cats that were treated with oral alendronate at 3.0 mg/kg once weekly for 22 weeks followed by 9 mg/kg twice weekly for 27 weeks.¹⁰ A single cat with idiopathic hypercalcemia was treated with alendronate for 30 months without reported adverse effects.⁷ Another cat with idiopathic hypercalcemia was treated for 15 months without reported clinical side effects, but episodes of hypocalcemia and hypophosphatemia were noted.¹²

Radiographic findings in this case included increased tibial bone opacity (sclerosis) and increased thickness of the bone cortex in association with no change in overall shape of the bone. This should not be confused with osteopetrosis, which is a genetic disease associated with various mutations that impair normal osteoclast function. There is both increased cortical and cancellous bone in osteopetrosis with enhanced fracture risk owing to increased bone fragility. Since this cat was geriatric and had a history of 8 years of oral alendronate treatment, it is likely that the osteosclerosis and increased cortical bone thickness was acquired secondary to bisphosphonate exposure, rather than a consequence of a genetic mutation. This acquired condition in cats is more appropriately called osteosclerosis rather than osteopetrosis.¹³⁻¹⁵

Though bisphosphonate treatment is frequently used in humans to help avert fractures in patients with osteoporosis,¹⁶ a causal relationship exists between bisphosphonate use and the development of fractures in some cases. Severely suppressed bone turnover and remodeling

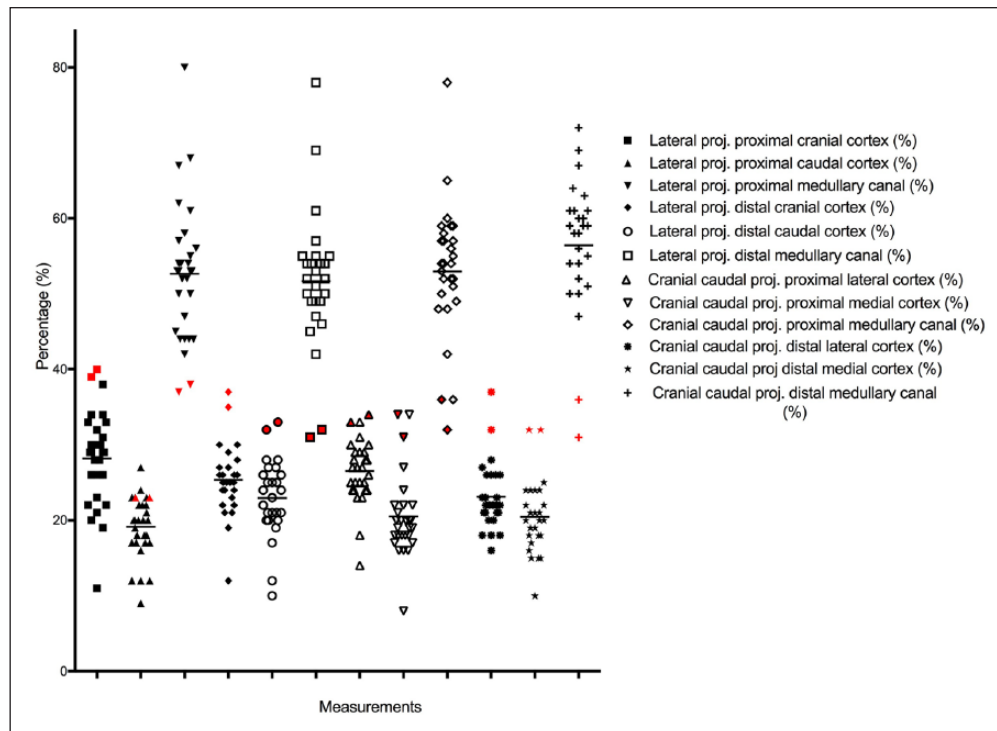


Figure 4 Measurements of the tibia were made using a digital caliper applied perpendicular to the tibial long axis at two locations in both the mediolateral and craniocaudal radiographic projections. See text for details as to how the measurements were made. Black marks are for control cats; red marks are for the cat of this report with the fractured patellae



Figure 5 Histopathology of a cross-section of the proximal tibia. Hematoxylin and eosin stain. There is increased cortical endosteal bone thickness with increased porosity and expanded vascular spaces of the increased endosteal cortical bone (*)

were proposed to be responsible for development of fractures.¹⁷⁻¹⁹ Decreased activity of osteoclasts from bisphosphonate use leads to changes in bone remodeling and abnormally dense thickened bones that can be brittle.²⁰ Long-term studies on the use of bisphosphonates in

humans have been evaluated for up to 10 years for alendronate.¹⁹ Current recommendations in human medicine are to treat with bisphosphonates for a maximal period of 5 years,²¹ depending on the patient's fracture risk due to osteoporosis. At completion of therapy, a drug holiday has been suggested, varying in length from 1-3 years, before resuming treatment with the same or a different bisphosphonate.¹⁹

Radiographs from this cat revealed marked cortical thickening of the tibia, narrowing of the intramedullary cavity of the tibia and fibula, and severe sclerosis of both patellae. Severe sclerosis in the patellae, coupled with the force of the patellar tendon, were likely the reasons for the location of the fractures in this cat. We recommend that radiographs of the long bones be evaluated in cats for which years of oral bisphosphonate therapy are planned. In order to detect early development of adverse bone effects, acquisition of baseline radiographs prior to starting chronic bisphosphonate therapy is optimal, with follow-up radiographs evaluated on an annual basis. Cats on bisphosphonate therapy should be closely monitored for weight loss, inappetence, and signs of oral discomfort (ptyalism) as potential indicators for osteonecrosis of the jaw, even though this has not yet been reported in cats. Development of persistent gastrointestinal signs (inappetence, vomiting, regurgitation) could also indicate

development of gastrointestinal ulcers or inflammation secondary to alendronate toxicity.

Following the cat's patellar fractures, alendronate treatment was discontinued permanently. Seven months after the second patellar fracture, the cat was diagnosed with large-cell lymphoma and was euthanized 7 months after this diagnosis. Histopathology of the proximal tibia revealed dramatically increased cortical endosteal bone thickness (approximately 50%). However, the increased endosteal cortical bone had increased bone porosity with expanded vascular spaces that may have originated from Haversian canals (Figure 5). This suggests that the cortical osteosclerosis may reverse upon withdrawal of bisphosphonate treatment.

Conclusions

This case report serves to increase awareness for the possible long-term adverse consequences of prolonged bisphosphonate use in cats. It may be prudent to recommend that serial measurements from long-bone radiographs be performed and compared with those obtained at baseline during long-term treatment with alendronate to detect early bone pathology. It is possible that radiographic changes in cortical and medullary dimensions may precede fracture. Bone radiography over time in cats receiving long-term bisphosphonate treatment will be necessary to determine if this is true.

Conflict of interest The authors declared no potential conflicts of interest with respect to the research, authorship, and/or publication of this article.

Funding The authors received no financial support for the research, authorship, and/or publication of this article.

References

- Segev G, Meltzer H and Shipov A. **Does secondary renal osteopathy exist in companion animals?** *Vet Clin North Am Small Anim Pract* 2016; 46: 1151–1162.
- Foster JD. **Update on mineral and bone disorders in chronic kidney disease.** *Vet Clin North Am Small Anim Pract* 2016; 46: 1131–1149.
- Langley-Hobbs SJ. **Survey of 52 fractures of the patella in 34 cats.** *Vet Rec* 2009; 164: 80–86.
- Vasikaran SD. **Bisphosphonates: an overview with special reference to alendronate.** *Ann Clin Biochem* 2001; 38: 608–623.
- Hardy BT, de Brito Galvao JF, Green TA, et al. **Treatment of ionized hypercalcemia in 12 cats (2006–2008) using PO-administered alendronate.** *J Vet Intern Med* 2015; 29: 200–206.
- Whitney JL, Barrs VR, Wilkinson MR, et al. **Use of bisphosphonates to treat severe idiopathic hypercalcaemia in a young Ragdoll cat.** *J Feline Med Surg* 2011; 13: 129–134.
- Stock E, Paepe D, Verhaert L, et al. **Idiopathic hypercalcemia in a Persian cat.** *Vlaams Diergeneeskundig Tijdschrift* 2013; 82: 11–16.
- Hostutler RA, Chew DJ, Jaeger JQ, et al. **Uses and effectiveness of pamidronate disodium for treatment of dogs and cats with hypercalcemia.** *J Vet Intern Med* 2005; 19: 29–33.
- Matsumoto Y. **Morphological and functional properties of odontoclasts on dentine resorption.** *Kokubyo Gakkai Zasshi* 1994; 61: 123–143.
- Mohn KL, Jacks TM, Schleim KD, et al. **Alendronate binds to tooth root surfaces and inhibits progression of feline tooth resorption: a pilot proof-of-concept study.** *J Vet Dent* 2009; 26: 74–81.
- Jowsey J, Holley KE and Linman JW. **Effect of sodium etidronate in adult cats.** *J Lab Clin Med* 1970; 76: 126–133.
- Whitney JL, Barrs VR, Wilkinson MR, et al. **Use of bisphosphonates to treat severe idiopathic hypercalcaemia in a young Ragdoll cat.** *J Feline Med Surg* 2011; 13: 129–134.
- Fujita M, Takaishi Y, Nagae H, et al. **Osteopetrosis-like disease in a cat with respiratory distress.** *J Vet Med Sci* 2007; 69: 687–690.
- Wright MW, Hudson JA and Hathcock JT. **Osteopetrosis in cats: clarification of a common misnomer.** *Vet Radiol Ultrasound* 2003; 44: 106.
- Hanel RM, Graham JP, Levy JK, et al. **Generalized osteosclerosis in a cat.** *Vet Radiol Ultrasound* 2004; 45: 318–324.
- Rizzoli R and Wehren L. **Alendronate treatment for osteoporosis: a review of the evidence.** *Clin Calcium* 2002; 12: 1136–1140.
- Mashiba T, Hirano T, Turner CH, et al. **Suppressed bone turnover by bisphosphonates increases microdamage accumulation and reduces some biomechanical properties in dog rib.** *J Bone Miner Res* 2000; 15: 613–620.
- Odvin CV, Zerwekh JE, Rao DS, et al. **Severely suppressed bone turnover: a potential complication of alendronate therapy.** *J Clin Endocrinol Metab* 2005; 90: 1294–1301.
- Watts NB and Diab DL. **Long-term use of bisphosphonates in osteoporosis.** *J Clin Endocrinol Metab* 2010; 95: 1555–1565.
- Whyte MP, Wenkert D, Clements KL, et al. **Bisphosphonate-induced osteopetrosis.** *N Engl J Med* 2003; 349: 457–463.
- Geusens P. **Bisphosphonates for postmenopausal osteoporosis: determining duration of treatment.** *Curr Osteoporos Rep* 2009; 7: 12–17.