



## **Probable cutaneous adverse drug reaction to piroxicam in a cat**

Authors: Young, Amanda J, Torres, Sheila M, and Koch, Sandra N

Source: Journal of Feline Medicine and Surgery Open Reports, 4(2)

Published By: SAGE Publishing

URL: <https://doi.org/10.1177/2055116918786598>

---

BioOne Complete ([complete.BioOne.org](https://complete.BioOne.org)) is a full-text database of 200 subscribed and open-access titles in the biological, ecological, and environmental sciences published by nonprofit societies, associations, museums, institutions, and presses.

Your use of this PDF, the BioOne Complete website, and all posted and associated content indicates your acceptance of BioOne's Terms of Use, available at [www.bioone.org/terms-of-use](https://www.bioone.org/terms-of-use).

Usage of BioOne Complete content is strictly limited to personal, educational, and non - commercial use. Commercial inquiries or rights and permissions requests should be directed to the individual publisher as copyright holder.

---

BioOne sees sustainable scholarly publishing as an inherently collaborative enterprise connecting authors, nonprofit publishers, academic institutions, research libraries, and research funders in the common goal of maximizing access to critical research.



# Probable cutaneous adverse drug reaction to piroxicam in a cat

Amanda J Young, Sheila M Torres and Sandra N Koch

*Journal of Feline Medicine and Surgery Open Reports*  
1–5

© The Author(s) 2018

Reprints and permissions:

sagepub.co.uk/journalsPermissions.nav

DOI: 10.1177/2055116918786598

journals.sagepub.com/home/jfmsopenreports

This paper was handled and processed

by the American Editorial Office (AAFP)

for publication in *JFMS Open Reports*



## Abstract

**Case summary** A 9-year-old male neutered Devon Rex cat presented with bilaterally symmetrical ulcerative lesions with mucopurulent exudate that developed rapidly. The lesions were apparent on the axillae, ventral abdomen and inguinal areas. The cat was systemically well. Piroxicam was being administered for palliative treatment of a previously diagnosed salivary adenocarcinoma. Histopathology revealed severe extensive epidermal ulceration with focal dyskeratotic keratinocytes in the stratum granulosum without lymphocyte satellitosis. Resolution of skin lesions was observed after discontinuing piroxicam. Similar lesions developed after previous piroxicam administration, further suggesting a possible adverse reaction to this drug. In addition, the Naranjo score indicated that piroxicam was a probable cause for the ulcerative skin lesions.

**Relevance and novel information** This is the first report of piroxicam, a non-steroidal anti-inflammatory drug, as a probable cause of ulcerative skin lesions in a cat.

**Keywords:** Drug reaction, piroxicam, non-steroidal anti-inflammatory drugs, cutaneous, skin

**Accepted:** 25 May 2018

## Introduction

Cutaneous adverse drug reactions (ADRs) in domestic animals are considered uncommon and account for 1–2% of cases presented to specialty dermatology clinics.<sup>1–3</sup> They are difficult to diagnose because the clinical signs can mimic many skin diseases and a true cause and effect relationship is often challenging to prove.<sup>4</sup> Idiosyncratic ADRs in cats have been reportedly caused by many systemic and topical drugs, but there have been no previous reports of cutaneous ADRs to non-steroidal anti-inflammatory drugs (NSAIDs).<sup>1,3,4</sup> The aim of this case report is to describe a probable cutaneous ADR to piroxicam in a cat.

## Case description

A 9-year-old male neutered Devon Rex cat presented to the University of Minnesota, College of Veterinary Medicine (UMNCVM) dermatology service, with symmetrical, ulcerative lesions localized to the axillae, inguinal areas and ventral abdomen. The lesions developed 10 days previously and had since progressed rapidly. The cat had a history of seasonal pruritus and miliary dermatitis that occurred from spring through autumn,

which was responsive to oral prednisolone and injections of cefovecin.

Ten months prior to presentation, an oral mass developed on the right side of the buccal surface of the lower lip. Six weeks later the mass was surgically excised by the referring veterinarian (rDVM) with narrow margins. The histopathologic diagnosis was salivary gland adenocarcinoma. A second surgery was performed by the rDVM 11 weeks later to remove a 5 mm new mass that appeared at the surgical site.

Three weeks after the second surgery, the cat was seen by the oncology service at the UMNCVM for further work-up. Piroxicam (compounded 10 mg/ml, University of Minnesota) 0.33mg/kg PO q48h was

Veterinary Clinical Sciences, University of Minnesota, St Paul, MN, USA

### Corresponding author:

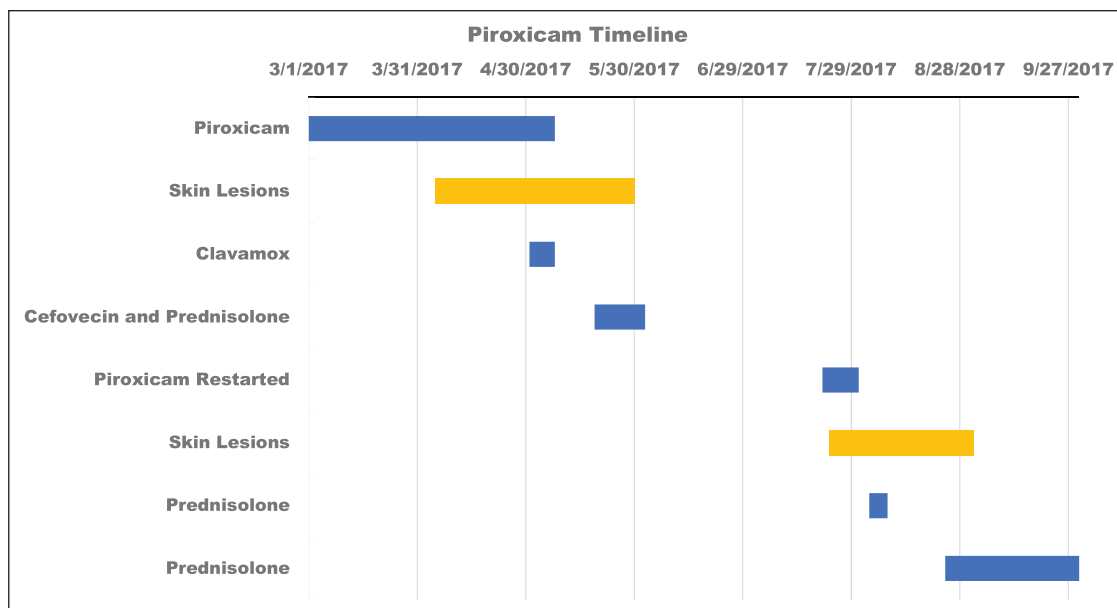
Sheila M Torres MS, PhD, DACVD, College of Veterinary Medicine, University of Minnesota, 1352 Boyd Avenue, St Paul, MN 55108, USA

Email: [torre009@umn.edu](mailto:torre009@umn.edu)



Creative Commons Non Commercial CC BY-NC: This article is distributed under the terms of the Creative Commons

Attribution-NonCommercial 4.0 License (<http://www.creativecommons.org/licenses/by-nc/4.0/>) which permits non-commercial use, reproduction and distribution of the work without further permission provided the original work is attributed as specified on the SAGE and Open Access pages (<https://us.sagepub.com/en-us/nam/open-access-at-sage>).



**Figure 1** Timeline of drug administration and onset of clinical signs

prescribed (day 0) for its anti-tumor activity. A CT scan was performed 2 weeks after starting piroxicam (day 14) and revealed mildly enlarged right retropharyngeal and right deep cervical lymph nodes.

Two weeks later (day 28) the cat was evaluated by the surgery department at UMNCVM for removal of the enlarged lymph nodes and crusting was noted on the ventral abdomen. Surgery was scheduled 4 weeks later; however, this was postponed owing to the development of ulcerative skin lesions 2 months after starting piroxicam (day 60).

Skin lesions were treated by the rDVM with oral amoxicillin/clavulanate potassium (Clavamox; Zoetis) at 14.9 mg/kg PO q12h for 7 days. No response to antibiotic therapy was noted and an aerobic skin bacterial culture and sensitivity test revealed no growth. Piroxicam was then discontinued (day 67). Ten days after discontinuing piroxicam, the ulcerative skin lesions improved, and cefovecin (Convenia; Zoetis) at 7.6 mg/kg SC and prednisolone at a reducing anti-inflammatory oral dose were prescribed by the rDVM (day 77) for a presumed flare of allergic dermatitis.

Three weeks after stopping the piroxicam (day 88), surgery was performed at the UMNCVM to remove the right mandibular salivary gland along with draining regional lymph nodes and a thoracic wall lymph node for staging purposes. No evidence of neoplasia was found. Moreover, there was no report of skin lesions at that time. The cat had an additional surgery 5 weeks later (day 123) and 8 weeks after discontinuation of piroxicam, to obtain wider margins at the initial surgery site. Histopathology of a lymph node revealed a focus of metastatic adenocarcinoma.

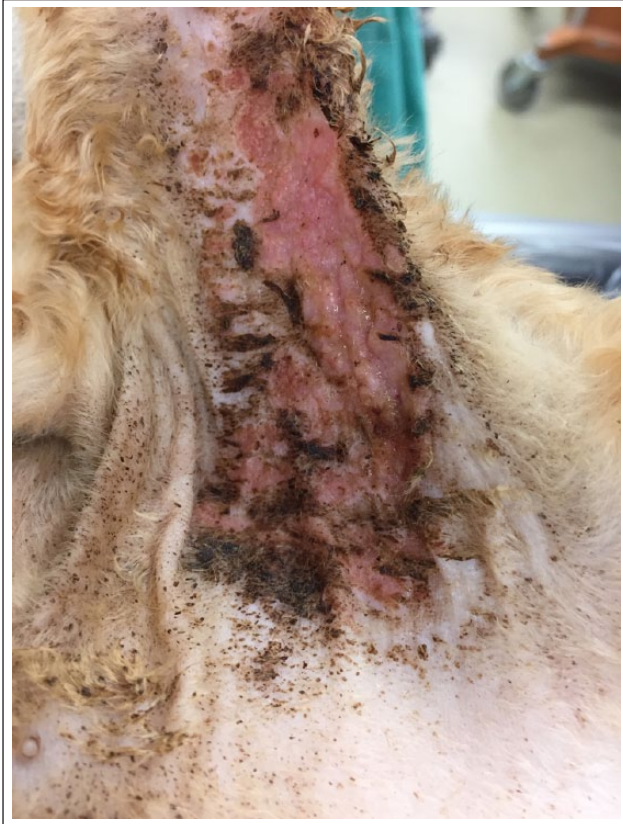The cat was evaluated by the oncology service 2 weeks later (day 137) and was once more prescribed piroxicam at a dosage of 0.39 mg/kg PO q48h for palliative treatment of the adenocarcinoma.

The cat presented to the UMNCVM dermatology service 12 days later (day 149). After a thorough history, it became evident that the lesions developed 2 days after re-starting piroxicam and 5 months since the first treatment with piroxicam (Figure 1). Two days prior to presentation at the UMNCVM dermatology service, an aerobic skin bacterial culture was taken by the rDVM, which revealed no growth.

The general physical examination was unremarkable. The dermatological examination revealed large areas of ulceration symmetrically distributed to the axilla, ventral abdomen, inguinal areas and medial aspect of both front- and hindlimbs (Figure 2). There was a tan-colored mucopurulent exudate covering the lesions and a thick black crusting at the periphery. The cat was noted to obsessively lick the affected areas.

Cytology of the exudate revealed numerous degenerate neutrophils, but no microorganisms. Complete blood cell count revealed mild segmented neutrophilia ( $13.89 \times 10^3 \mu/l$ ; reference interval [RI]  $1.2\text{--}13.2 \times 10^3 \mu/l$ ). Serum biochemical abnormality showed mild hypophosphatemia (2.9 mg/dl; RI 3.3–7.8 mg/dl). Differential diagnoses included a severe flare of allergic dermatitis, eosinophilic granuloma complex and cutaneous ADR.

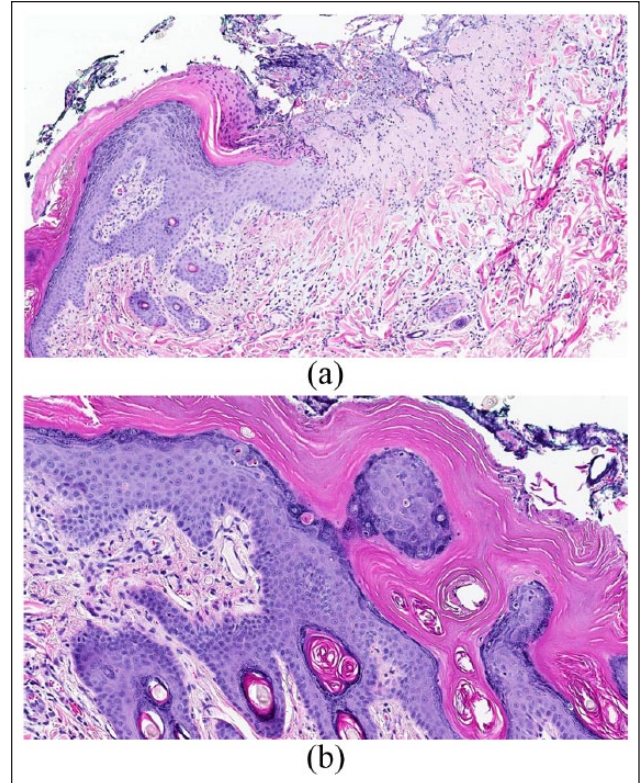
Piroxicam was discontinued (day 149) and prednisolone (compounded 10 mg/ml; University of Minnesota) 1.8 mg/kg PO q24h was prescribed after a 3 day washout period (day 152) for presumptive severe allergic dermatitis. No improvement was noted after 6 days of treatment.



**Figure 2** Ulcerated lesion at presentation. There is a large ulceration in the axilla with central exudation and thick peripheral crusting

Prednisolone was then discontinued and a biopsy was performed 2 days later (day 160). Skin biopsies were taken under general anesthesia with a 6 mm punch and samples were fixed in 10% buffered formalin. Sections were paraffin-embedded and stained with hematoxylin and eosin following standard protocols. Histopathology showed epidermal ulceration covered with a thick fibrinonecrotic exudate (Figure 3a). A focal area of intact epidermis revealed marked hyperplasia with compact orthokeratotic hyperkeratosis, hypergranulosis, acanthosis and spongiosis. There was focal dyskeratotic keratinocytes within the granular layer and remnants of these cells were also found in the stratum corneum (Figure 3b). The underlying dermis was moderately edematous. There was mild dermal infiltrate of eosinophils and mast cells admixed with variable numbers of lymphocytes, plasma cells and fibroblasts. The histopathologic findings indicated a non-specific ulcerative dermatitis.

The skin lesions significantly improved approximately 3 and 2 weeks after piroxicam and prednisolone discontinuation, respectively. Dermatological examination showed only few small crusts on the axillae, ventral abdomen and inguinal regions. Most of the crusts were accompanied by a few, mildly erythematous, serpiginous lesions extending from the central areas of crusting (Figure 4).

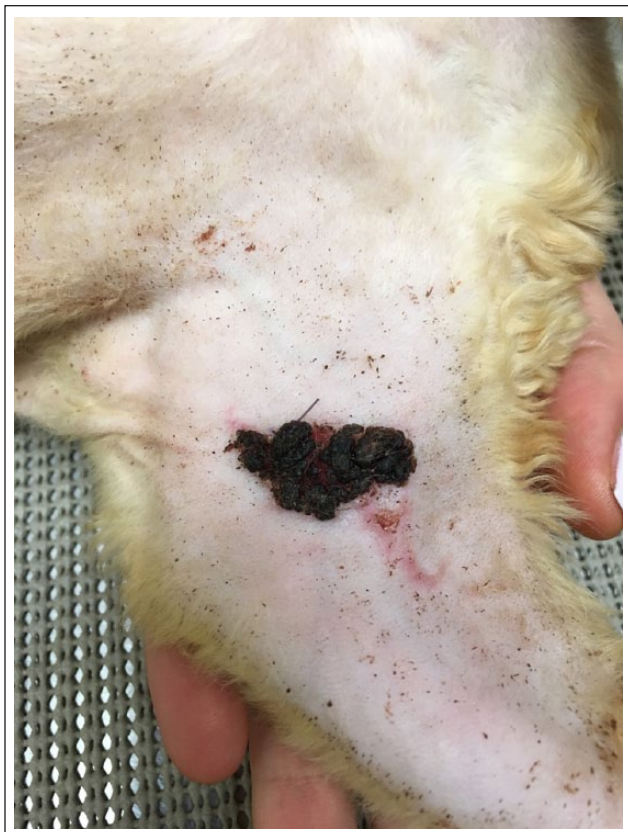

**Figure 3** (a) Hematoxylin and eosin photomicrograph ( $\times 10$ ) revealing abrupt transition from severe epidermal hyperplasia, orthokeratotic hyperkeratosis and focal parakeratosis to ulceration covered with fibrinonecrotic exudate. Moderate perivascular-to-interstitial dermal inflammation and edema. (b) Hematoxylin and eosin photomicrograph ( $\times 20$ ) showing multiple individualized apoptotic/dyskeratotic keratinocytes present in the stratum granulosum. Mild perivascular to interstitial dermal inflammation. There is no lymphocyte satellitosis

Erythematous papules were noted on the dorsal aspect of the head and caudal neck and the owner reported that the cat was itching at these lesions. Prednisolone was restarted at 1.8 mg/kg PO q24h and tapered to 1 mg/kg PO q48h to control a flare of seasonal allergic dermatitis. There was no recurrence of ulcerative lesions 6 months after discontinuation of piroxicam (Figure 5). The Naranjo score (see the supplementary material) was 6 indicating piroxicam as a probable cause for the cutaneous lesions.<sup>5</sup>

## Discussion

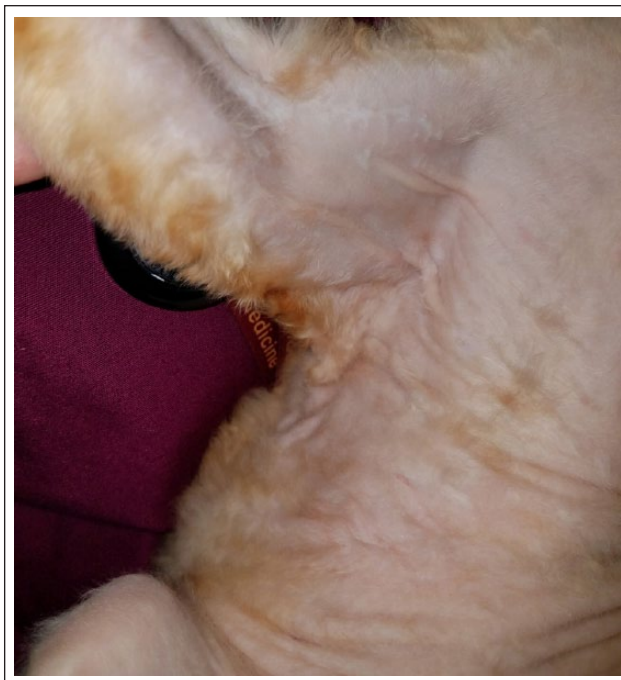
To our knowledge, this is the first report of a probable cutaneous ADR to piroxicam in a cat. The most convincing evidence that supported this diagnosis was the repeatable distinctive ulcerative lesions seen 2 days after piroxicam was re-administered to the patient. Generally, re-administration of a drug suspected to cause an adverse reaction is not recommended as the subsequent reaction can be more severe and even life-threatening; however, piroxicam was unintentionally re-challenged in this case.<sup>6</sup>



**Figure 4** Ulcerated lesion 3 weeks after discontinuing piroxicam. Note the erythematous, serpiginous lesion extending from a central area of crusting in the axilla

NSAIDs have been previously shown to cause cutaneous ADRs in both dogs and people.<sup>7-20</sup> Carprofen and firocoxib have been associated with skin eruptions resembling Sweet's syndrome in four dogs.<sup>8-10</sup> Carprofen has also been associated with toxic epidermal necrolysis in a dog.<sup>11</sup> In another dog, meloxicam caused vasculitis, erosions and ulcers.<sup>12</sup> In people, reports of cutaneous reactions to piroxicam include photosensitivity, urticaria, erythema multiforme, toxic epidermal necrolysis, pemphigus vulgaris, fixed drug eruption, drug rash with eosinophilia and systemic symptoms (DRESS syndrome), and acute generalized pustulosis.<sup>13-18</sup> Most cases resolved rapidly following discontinuation of piroxicam.<sup>13-18</sup> ADRs from NSAIDs are thought to be caused by a hypersensitivity reaction, which can be classified as either cross-reactive among chemically unrelated NSAIDs or selective to a specific NSAID.<sup>19,20</sup> Cross-reactive reactions occur through non-immunological mechanisms related to arachidonic acid metabolism.<sup>19,20</sup> Selective reactions are induced by immunological mechanisms and are either IgE- or T-cell-mediated reactions.<sup>19,20</sup>

Piroxicam has been prescribed for long-term use in cats with a variety of neoplasms for its anti-tumor effects believed to be related to the inhibition of cyclooxygenase and, ultimately, of prostaglandins.<sup>21-27</sup>



**Figure 5** Scar in axilla 6 months after discontinuing piroxicam

A limitation of this case report is the various drugs administered to the cat before and after the onset of distinctive ulcerative lesions. However, the Naranjo scale used in this case to estimate the probability of an ADR to piroxicam revealed a score of 6, indicating a probable causal relation of piroxicam and the skin lesions. In addition, 3 months prior to presentation, similar ulcerative lesions were noted by the rDVM after the cat had received piroxicam for 2 months. At that time, the skin healed after discontinuing piroxicam and treatment with prednisolone and a single injection of cefovecin. Moreover, the rapid development of similar skin lesions after repeat drug exposure and the lack of response to systemic glucocorticoids after piroxicam discontinuation further supported a probable cutaneous ADR. In fact, the use of glucocorticoids in treating drug reactions is controversial as response can be poor.<sup>4,6</sup> After skin biopsy was performed, no treatment was initiated and the skin lesions rapidly improved over the following 2 weeks, adding to the evidence that piroxicam likely caused the ulcerative cutaneous lesions in this case.

Skin biopsies are often performed when suspecting an ADR to rule out other possible dermatoses and support a presumptive diagnosis. The histopathologic findings in this case were non-specific and it is possible the systemic glucocorticoid administered a few days before skin biopsies were performed altered the inflammatory reaction pattern observed histologically. Nevertheless, not all histologic changes associated with cutaneous ADRs are characteristic of a specific disease.

## Conclusions

This is the first known report of a NSAID causing cutaneous ADR in a cat. Discontinuation of piroxicam resulted in complete resolution of skin lesions within 4 weeks. Cutaneous ADRs should be suspected when new skin lesions develop after a medication is initiated. Any suspected drug reactions should be communicated to the owner and all attending veterinarians and should be well documented in the medical record.

**Acknowledgements** The authors would like to thank Dr Michael H Goldschmidt and Marshfield Laboratories for providing photomicrographs of the histology images. The authors would also like to thank Nick Klever for his assistance with graphical design.

**Supplementary material** Table 1: Naranjo Adverse Drug Reaction Probability Scale.

**Conflict of interest** The authors declared no potential conflicts of interest with respect to the research, authorship, and/or publication of this article.

**Funding** The authors received no financial support for the research, authorship, and/or publication of this article.

## References

- Scott D and Miller WH. **Idiosyncratic cutaneous adverse drug reactions in the cat: literature review and report of 14 cases (1990–1996)**. *Feline Pract* 1998; 26: 10–14.
- Scott D and Miller WHJ. **Idiosyncratic cutaneous adverse drug reactions in the dog: literature review and report of 101 cases (1990–1996)**. *Canine Pract* 1999; 24: 16–22.
- Benson L, Scott DW and Miller WH. **Presumed idiosyncratic adverse cutaneous drug reactions in 29 cats (1997–2012)**. *Jpn J Vet Dermatol* 2015; 21: 143–148.
- Miller WH, Griffin CE and Campbell KL. **Autoimmune and immune-mediated dermatoses**. In: Muller and Kirk's small animal dermatology. 7th ed. St Louis, MO: Elsevier Mosby, 2013, pp 432–500.
- Naranjo CA, Busto U, Sellers EM, et al. **A method for estimating the probability of adverse drug reactions**. *Clin Pharmacol Ther* 1981; 30: 239–245.
- Voie KL, Campbell KL and Lavergne SN. **Drug hypersensitivity reactions targeting the skin in dogs and cats**. *J Vet Intern Med* 2012; 26: 863–874.
- Bibgy M and Stern R. **Cutaneous reactions to nonsteroidal anti-inflammatory drugs. A review**. *J Am Acad Dermatol* 1985; 12: 866–876.
- Mellor PJ, Roulois AJA, Day MJ, et al. **Neutrophilic dermatitis and immune-mediated haematological disorders in a dog: suspected adverse reaction to carprofen**. *J Small Anim Pract* 2005; 46: 237–242.
- Vitale C, Zenger E and Hill J. **Putative Rimadyl-induced neutrophilic dermatosis resembling Sweet's syndrome in 2 dogs**. Proceedings of the AAVD/ACVD Meeting Vet Dermatol; 1999 April 22–27; Maui, USA. 1999, pp 69–70.
- Johnson CS, May ER, Myers RK, et al. **Extracutaneous neutrophilic inflammation in a dog with lesions resembling Sweet's Syndrome**. *Vet Dermatol* 2009; 20: 200–205.
- Banovic F, Olivry T, Bazzle L, et al. **Clinical and microscopic characteristics of canine toxic epidermal necrolysis**. *Vet Pathol* 2015; 52: 321–330.
- Niza MMRE, Félix N, Vilela CL, et al. **Cutaneous and ocular adverse reactions in a dog following meloxicam administration**. *Vet Dermatol* 2007; 18: 45–49.
- Vasconcelos C, Magina S, Quirino P, et al. **Cutaneous drug reactions to piroxicam**. *Contact Dermatitis* 1998; 39: 145.
- Rho YK, Yoo KH, Kim BJ, et al. **A case of generalized fixed drug eruption due to a piroxicam plaster**. *Clin Exp Dermatol* 2010; 35: 204–205.
- Montoro J, Diaz M, Genis C, et al. **Non-pigmenting cutaneous-mucosal fixed drug eruption due to piroxicam**. *Allergol Immunopathol* 2003; 31: 53–55.
- Lamchahab F and Baeck M. **Occupationally induced fixed drug eruption caused by a non-steroidal anti-inflammatory agent**. *Contact Dermatitis* 2012; 67: 176–177.
- Bizid S, Haddad W, Ben Abdallah H, et al. **Severe acute hepatitis induced by a DRESS syndrome to piroxicam**. *Tunis med* 2014; 92: 417.
- Cherif Y, Jallouli M, Mseddi M, et al. **Acute generalized exanthematous pustulosis induced by piroxicam: a case report**. *Indian J Pharmacol* 2014; 46: 232–233.
- Blanca-Lopez N, Cornejo-Garcia JA, Plaza-Seron MC, et al. **Hypersensitivity to nonsteroidal anti-inflammatory drugs in children and adolescents: cross-intolerance reactions**. *J Investig Allergol Clin Immunol* 2015; 25: 259–269.
- Pham DL, Kim JH, Trinh TH, et al. **What we know about nonsteroidal anti-inflammatory drug hypersensitivity**. *Korean J Intern Med* 2016; 31: 417–432.
- Bulman-Fleming JC, Turner TR and Rosenberg MP. **Evaluation of adverse events in cats receiving long-term piroxicam therapy for various neoplasms**. *J Feline Med Surg* 2010; 12: 262–268.
- Knapp DW, Richardson RC, Chan TCK, et al. **Piroxicam therapy in 34 dogs with transitional cell carcinoma of the urinary bladder**. *J Vet Intern Med* 1994; 8: 273–278.
- Mohammed SI, Craig BA, Mutsaers AJ, et al. **Effects of the cyclooxygenase inhibitor, piroxicam in combination with chemotherapy on tumor response, apoptosis, and angiogenesis in a canine model of human invasive urinary bladder cancer**. *Mol Cancer Ther* 2003; 2: 183–188.
- Dempke W, Rie C, Grothey A, et al. **Cyclooxygenase-2: a novel target for cancer chemotherapy?** *J Cancer Res Clin Oncol* 2001; 127: 411–417.
- Marnett LJ. **Asiprin and the potential role of prostaglandins in colon cancer**. *Cancer Res* 1992; 52: 5575–5589.
- Schmidt BR, Glickman NW, DeNicola DB, et al. **Evaluation of piroxicam for the treatment of oral squamous cell carcinoma in dogs**. *J Am Vet Med Assoc* 2001; 218: 1783–1784.
- DiBernardi L, Dore M, Davis JA, et al. **Study of feline oral squamous cell carcinoma: potential target for cyclooxygenase inhibitor treatment**. *Prostaglandins Leukot Essent Fatty Acids* 2007; 76: 245–250.