



## **Nasal dermoid cyst with intracranial extension in a cat**

Authors: Brady, Stacey, Bell, Erin, Courtman, Natalie, and Chevoir, Matthias Le

Source: Journal of Feline Medicine and Surgery Open Reports, 5(1)

Published By: SAGE Publishing

URL: <https://doi.org/10.1177/2055116919827404>

---

BioOne Complete ([complete.BioOne.org](https://complete.BioOne.org)) is a full-text database of 200 subscribed and open-access titles in the biological, ecological, and environmental sciences published by nonprofit societies, associations, museums, institutions, and presses.

Your use of this PDF, the BioOne Complete website, and all posted and associated content indicates your acceptance of BioOne's Terms of Use, available at [www.bioone.org/terms-of-use](https://www.bioone.org/terms-of-use).

Usage of BioOne Complete content is strictly limited to personal, educational, and non - commercial use. Commercial inquiries or rights and permissions requests should be directed to the individual publisher as copyright holder.

---

BioOne sees sustainable scholarly publishing as an inherently collaborative enterprise connecting authors, nonprofit publishers, academic institutions, research libraries, and research funders in the common goal of maximizing access to critical research.



# Nasal dermoid cyst with intracranial extension in a cat

Stacey Brady<sup>1</sup>, Erin Bell<sup>2</sup>, Natalie Courtman<sup>3</sup> and Matthias Le Chevoir<sup>1</sup>

*Journal of Feline Medicine and Surgery Open Reports*  
1–6

© The Author(s) 2019  
Article reuse guidelines:  
sagepub.com/journals-permissions  
DOI: 10.1177/2055116919827404  
journals.sagepub.com/home/jfmsopenreports

This paper was handled and processed by the European Editorial Office (ISFM) for publication in *JFMS Open Reports*



## Abstract

**Case summary** An 11-month-old female neutered Ragdoll cat was presented for focal seizures, aggression and altered behaviour. A diagnosis of a nasal dermoid cyst with intracranial extension was made following MRI, cytology and histopathology. The cyst was surgically excised with a resolution of clinical signs, with the exception of ongoing seizure activity requiring anti-seizure medication.

**Relevance and novel information** To our knowledge, this is the first reported case of a nasal dermoid cyst in a cat, and the first reported case in the veterinary literature of any species with a nasal dermoid cyst presenting with neurological signs.

**Keywords:** Dermoid; cyst; seizure; nasal; neurological

**Accepted:** 8 January 2019

## Introduction

A dermoid cyst is a developmental anomaly characterised by an accumulation of keratin, hair and variable amounts of sebum within a cyst lined by keratinised stratified squamous epithelium and adnexal skin structures (eg, hair follicles, sebaceous glands, sweat glands).<sup>1–4</sup> This differs from an epidermoid cyst, which is lined by only stratified squamous epithelium.<sup>5</sup>

Nasal dermoid cysts form as a consequence of abnormal embryogenesis during the development of the frontonasal region.<sup>1,6–8</sup> In people, the ‘cranial theory’ suggests that during development of the nasal cavity, as the dura mater (neuroectoderm) recedes from the pre-nasal space, it remains attached to the nasal ectoderm and pulls this back inwards with it, forming a sinus. If this sinus becomes pinched off, a cyst may form.<sup>3,7</sup>

Externally, there may be a visible punctum on the dorsal nasal surface, often termed a ‘nasal pit’.<sup>9</sup> A smaller number of nasal dermoid cysts in people have an intracranial extension; progressive growth and/or infection of dermoid cysts can cause facial deformity, local infection, meningitis and/or brain abscessation.<sup>8,10–12</sup>

Nasal dermoid cysts are described infrequently in the veterinary literature, with most cases presenting for

evaluation of primarily dermatological complaints from cyst growth, or recurrent infection of the area and surrounding structures.<sup>9</sup> To date, there have been no published reports in the veterinary literature of neurological signs secondary to a nasal dermoid cyst. In addition, no published reports exist of a nasal dermoid cyst occurring in a cat.

## Case description

An 11-month-old neutered female Ragdoll cat was presented for a 24 h history of aggression, vocalisation, hypersalivation and facial twitching. The cat was kept

<sup>1</sup>Department of Neurology, University of Melbourne Veterinary Teaching Hospital, Melbourne, Australia

<sup>2</sup>Department of Internal Medicine, Sydney Veterinary Emergency & Specialists, Sydney, Australia

<sup>3</sup>Department of Clinical Pathology, University of Melbourne, Melbourne, Australia

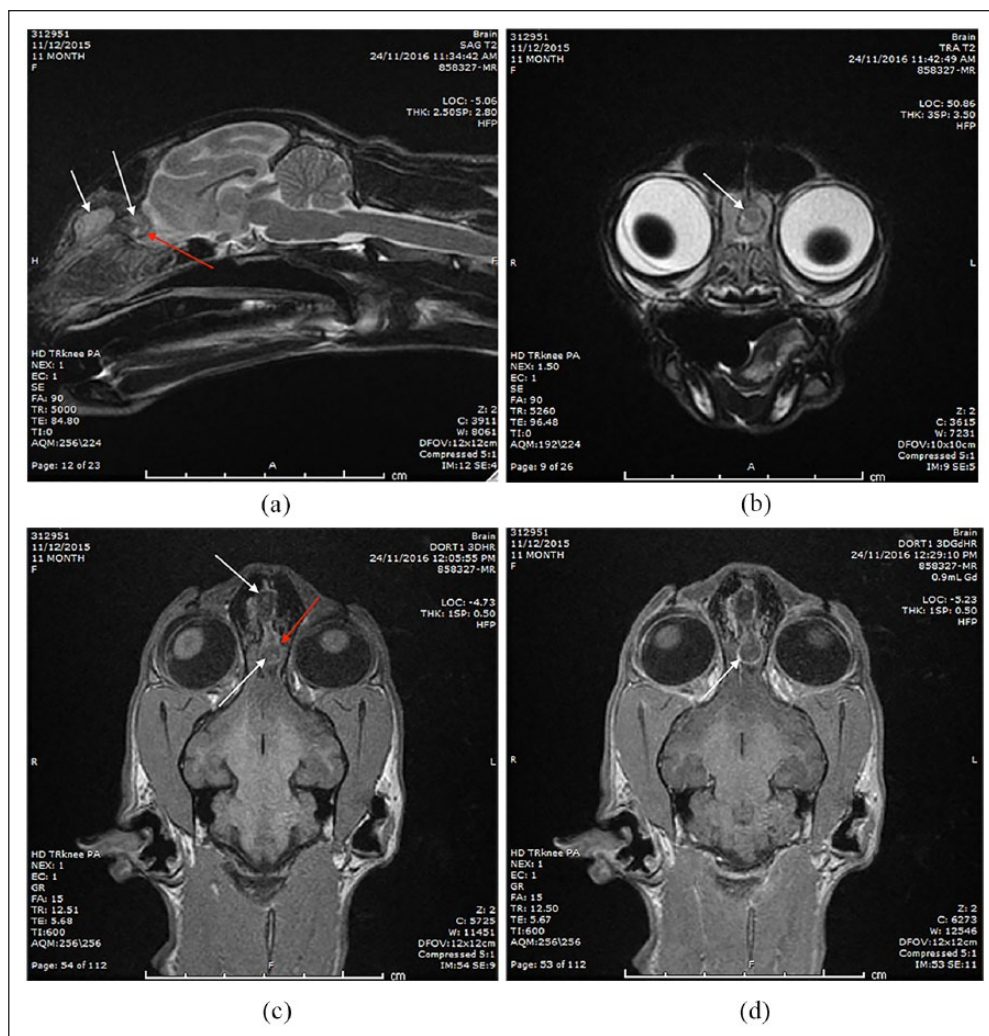
## Corresponding author:

Stacey Brady BVSc (Hons I), MSc (AABAW), Department of Neurology, University of Melbourne Veterinary Teaching Hospital, 250 Princes Hwy, Werribee, VIC 3030, Australia  
Email: brady.stacey@unimelb.edu.au



Creative Commons Non Commercial CC BY-NC: This article is distributed under the terms of the Creative Commons

Attribution-NonCommercial 4.0 License (<http://www.creativecommons.org/licenses/by-nc/4.0/>) which permits non-commercial use, reproduction and distribution of the work without further permission provided the original work is attributed as specified on the SAGE and Open Access pages (<https://us.sagepub.com/en-us/nam/open-access-at-sage>).



**Figure 1** MRI of a nasal dermoid cyst with intracranial extension in a cat. The cyst and contents were heterogeneously hyperintense on T2- and T1-weighted (T2W and T1W, respectively) imaging (white arrows) with rim contrast enhancement following administration of gadolinium. The lesion extended through the cribriform plate (red arrow). (a) Sagittal T2W; (b) transverse T2W; (c) dorsal T1W pre-contrast; (d) dorsal T1W post-contrast (gadolinium)

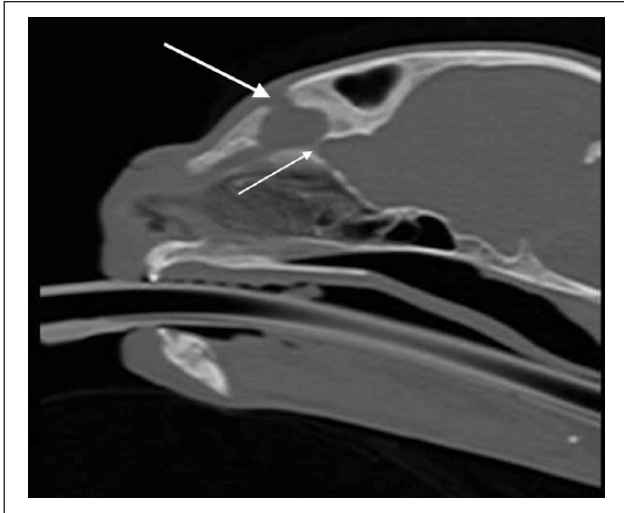
indoors with no reported access to toxins, was up to date with vaccinations and on a balanced commercial diet with additional raw beef.

Initial clinical examination was limited to visual examination (due to temperament) and confirmed the presence of facial twitching, hypersalivation and hissing, interpreted as likely focal seizure activity. The gait was normal, and mentation appeared disoriented. A sedative of alfaxalone 5 mg/kg IV (Alfaxan; Jurox) was administered to facilitate further physical evaluation, which revealed pyrexia (40.1°C), with no other abnormalities, including an unremarkable fundic examination. These findings were consistent with neurolocalisation to the forebrain.

Biochemistry showed a mild elevation in alanine aminotransferase (194 U/l; reference interval [RI] 5–80 U/l) and a markedly elevated creatine kinase (28,224

U/l; RI 50–400 U/l). Haematology demonstrated a moderate leukocytosis ( $26.4 \times 10^9/l$ ; RI  $5.5\text{--}19.5 \times 10^9/l$ ) with a moderate neutrophilia ( $23.2 \times 10^9/l$ ; RI  $2.5\text{--}12.5 \times 10^9/l$ ). Feline immunodeficiency virus and feline leukaemia virus immunoassay (FasTest FeLV-FIV; Megacor), cryptococcal antigen lateral flow assay (Cr Ag LFA; Immy) and *Toxoplasma* IgM and IgG serology (immunofluorescent antibody test; Animal Health Laboratory) were negative. Thoracic radiographs were unremarkable.

Brain MRI revealed a well-demarcated, bi-lobed mass measuring 19.5 mm in length extending from the caudal nasal cavity through the cribriform plate and into the calvarium contacting the left olfactory bulb and frontal lobe (Figure 1). The lesion was heterogeneously hyperintense on T2-weighted (T2W) images relative to grey matter, did not completely null on fluid-attenuated inversion



**Figure 2** Sagittal CT image of the skull of a cat with a nasal dermoid cyst showing a midline fusion defect of the nasal cavity allowing communication with the subcutaneous space (large arrow) and extension of the defect through the cribriform plate (small arrow)

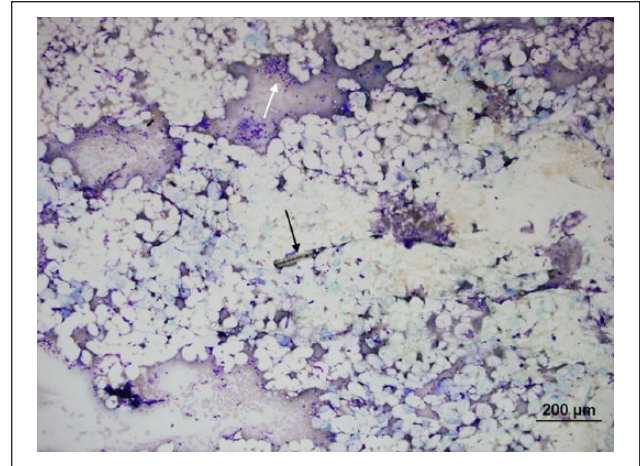
recovery (FLAIR) and was heterogeneously hyperintense on T1-weighted (T1W) images; these characteristics suggested that the lesion had components of fat and fluid with increased protein/cellular content.<sup>13</sup> A thin rim surrounded the lesion, which was hyperintense on T1W images (pre-contrast) and demonstrated contrast enhancement suggesting increased vascularity.<sup>13</sup> A localised region of the rostral left frontal lobe adjacent to the mass had a poorly demarcated pattern of hyperintensity on T2W images; this region was isointense on T1W images and did not null on FLAIR, indicative of possible oedema or gliosis.

In addition, a small soft tissue swelling was noted on the tip of the dorsal nasal planum with a small tubular midline deficit measuring 4 mm in length (not visible on physical examination).

CT of the skull demonstrated a midline fusion defect of the caudodorsal nasal cavity communicating dorsally with the subcutaneous tissue and caudally through the left cribriform plate (Figure 2).

Cisternal cerebrospinal fluid (CSF) analysis was unremarkable; containing small lymphocytes and large mononuclear cells with a total nucleated cell count and total protein within normal RIs, and no infectious agents identified on cytology.

Cytology of fine-needle aspirates (FNAs) of the mass (CT-guided through the defect) revealed rafts of pigmented and non-pigmented squames, degenerate neutrophils, vacuolated macrophages, lymphocytes, plasma cells and multinucleate giant cells in a proteinaceous background containing small amounts of blood (Figure 3). Occasional cocci bacteria were evident extracellularly



**Figure 3** Photomicrograph of fine-needle aspirate cytology of the contents of a nasal dermoid cyst in a cat showing a hair fragment (black arrow) and degenerate neutrophils, macrophages, lymphocytes and blood (white arrow) stained with Wright's Giemsa

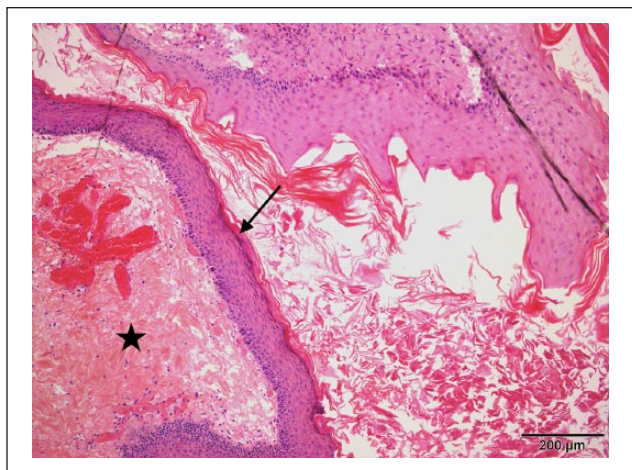
and intracellularly along with rare hair fragments and cholesterol crystals.

Culture of the FNA aspirates produced a heavy, pure growth of *Staphylococcus aureus*. These findings were considered suggestive of a dermoid cyst with secondary pyogranulomatous inflammation and bacterial infection.

Treatment was initiated with cefazolin 22 mg/kg IV q8h (Cefazolin-AFT; AFT Pharmaceuticals), phenobarbitone 2 mg/kg IV q12h (Phenobarbitone; Aspen Pharma) and buprenorphine 0.02 mg/kg IV q6h (Temgesic; Reckitt Benckiser). Levetiracetam 30 mg/kg IV q8h (Keppra; UCB Pharma) was administered for 48 h then discontinued.

The cat was anaesthetised for surgical removal of the cystic mass using a premedication combination of methadone 0.5 mg/kg IM (Physeptone; Aspen Pharma), midazolam 0.3 mg/kg IM (Hypnovel; Roche Products), ketamine 6 mg/kg IM (Ketamine; Ceva) with alfaxalone 1 mg/kg IV (Alfaxan; Jurox) used for induction of anaesthesia.

A mid-sagittal skin incision was made over the nasal and frontal bones from the level of the nasal planum to slightly caudal to level of the orbits. No external pore/opening was identified. Over the rostral nose, a small tag of tissue was identified subcutaneously, extending through a small bone defect. The communicating tissue was dissected using sharp and blunt dissection in addition to burring of the surrounding bone to follow the tract into the nasal cavity. The cyst was identified within the nasal cavity and removed. A defect in the frontal bone was similarly identified and dissected through to the caudal nasal cavity. All identified nasal cystic components were removed and the cystic lining was



**Figure 4** Photomicrograph of histology of the intracranial portion of a nasal dermoid cyst with intracranial extension removed surgically. The cyst was characterised by well-differentiated stratified squamous keratinising epithelium with a granular cell layer (arrow), keratin accumulation (star) and apocrine gland structures (not pictured here)

dissected and followed through the cribriform plate. The intracranial cystic component was predominantly left-sided and adherent to the dura mater of the longitudinal fissure and medial margins of the frontal/olfactory lobes. Gentle dissection was used to separate the cystic lining from the dura mater. Dural substitute (Lyoplast; Aesculap AG) was placed over the defect in the cribriform plate. A plate of polymethylmethacrylate (Surgical Simplex P; Stryker Orthopaedics) was placed over the defect in the frontal bone; skin was closed with intradermal sutures (Monosyn; SilverGlide).

Histopathological analysis confirmed the nasal and intracranial masses were cystic structures filled with abundant keratin and lined with squamous epithelium and embedded apocrine glands and hair follicles, along with a few neutrophils and cocci bacteria, consistent with a diagnosis of an infected dermoid sinus/cyst (Figure 4). Multifocal pyogranulomatous rhinitis was also noted. Culture and sensitivity of the cyst contents removed at surgery again yielded a pure growth of *S aureus*.

Postoperative recovery was uneventful; analgesia was provided with methadone 0.2 mg/kg IV q4h (Physeptone; Aspen Pharma) for 12 h then buprenorphine 0.01 mg/kg q6h (Temgesic; Reckitt Benckiser); the patient was discharged 4 days following the surgery on phenobarbitone 1.8 mg/kg PO q12h (Phenobarb; Arrow Pharma) and cephalexin ~22 mg/kg PO q12h (Cephalexin; Apex Laboratories).

Further suspected seizure activity occurred in the days following hospital discharge; the phenobarbitone dose was increased to 3.3 mg/kg PO q12h and oral prednisolone was commenced at 0.5 mg/kg PO q12h (Pred-X 5; Apex Laboratories) on a tapering course.

Over the following week, the seizure activity increased, and the cat's behaviour was further altered with hissing and apparent hyperaesthesia when touched. A repeat CSF sample was taken, which showed no abnormalities and negative bacterial culture.

Repeat MRI or CT imaging was declined.

The phenobarbitone was increased to 5 mg/kg PO q12h, trimethoprim–sulfadiazine (Tribrissen 20; Jurox) initiated at 20 mg/kg PO q12h (in addition to the cephalexin) and prednisolone continued at 0.5 mg/kg PO q12h.

No further seizure activity was noted. The antibiotics were discontinued 4 weeks later, and the prednisolone was slowly tapered over 4 weeks and discontinued.

Eight months postoperatively, no further seizure activity had been witnessed and the cat's neurological examination was unremarkable. The phenobarbitone dose was slowly reduced by 25% every 4 weeks. During the tapering process, the seizures re-occurred and the phenobarbitone dose was increased back to therapeutic levels with subsequent return to seizure freedom. Repeat MRI at the time of seizure recurrence showed rhinosinusitis with suspected local meningitis of the left olfactory bulb; no evidence of cyst recurrence was present and CSF analysis was unremarkable. The cat responded to treatment with an increase in the phenobarbitone dose and a course of marbofloxacin 5 mg/kg q24h (Zeniquin; Zoetis). Deterioration of seizure control over the subsequent months was controlled with the addition of levetiracetam 41 mg/kg q12h (Keppra; UCB Pharma). Complete seizure freedom was not able to be achieved.

## Discussion

Dermoid cysts are a rare congenital malformation sporadically reported in the veterinary literature. In the medical literature, frontonasal dermoid cysts are reported to occur in 1:20,000–1:40,000 births, comprising 4–12% of all head and neck dermoid cysts.<sup>8,9</sup> In people (mainly paediatric), approximately 20% (5–45%) of frontonasal dermoid cysts are reported to have intracranial extension; neurological signs are, however, rarely reported.<sup>7,14</sup>

In the veterinary literature, dermoid sinuses and cysts are most commonly reported in the subcutaneous and dermal tissues, often over the dorsal midline (with or without communication with the vertebral canal).<sup>15–17</sup> Neurological signs have been reported in a small number of cases with spinal cord involvement and solitary intracranial dermoid cysts; intracranial extension of a nasal dermoid cyst has been reported in one dog with no associated neurological signs.<sup>4,9,15,18–23</sup> All reported cases of nasal dermoid sinus/cyst in dogs were presented for swelling or recurrent infection/draining tracts over the dorsal aspect of the nose, or at the junction of the dorsal nasal skin and nasal planum.<sup>6,9,23–25</sup>

This case is, to the best of our knowledge, the first nasal dermoid cyst reported in a cat, and, additionally, the first nasal dermoid cyst with intracranial extension reported in any animal species with neurological signs as the primary presenting complaint.

The lack of literature on antibiotic treatment for cases such as this led to an initial first-line choice of cephalexin, a broad-spectrum antimicrobial. Continued deterioration in neurological status despite this prompted the addition of trimethoprim–sulfadiazine, an antibiotic with good penetration in the central nervous system.<sup>26</sup> In this case, with identification of rhinosinusitis, suspicion of meningitis on imaging with no changes on CSF analysis, the decision was made to commence marbofloxacin. The use of fluoroquinolones is reserved for those patients for which there is no viable lower-order antimicrobial available and where culture and sensitivity dictates it after sampling; however, in this case sampling of the sinus was unable to be performed due to previous placement of a poly(methyl methacrylate) plate over the surgical defect. With concern over deterioration in the neurological status of the cat, and absence of any changes on CSF analysis, a fluoroquinolone was selected for the reported property of enhanced penetration into CSF in the absence of meningeal inflammation.<sup>27</sup>

MRI characteristics of dermoid cysts have previously been described as hyperintense on T1W images and heterogeneous on T2W images, depending on the fat content.<sup>5,28,29</sup> In this case, the dermoid cyst had heterogeneous hyperintensity on both T1W and T2W images. It has been suggested that the diffusion-weighted imaging (DWI)/apparent diffusion coefficient (ADC) may be useful in differentiating dermoid cysts from other cystic masses, with dermoid cysts typically demonstrating hyperintensity on DWI and isointensity on ADC (compared with brain parenchyma); in this case the cystic contents were DWI hyperintense and ADC isointense to hypointense.<sup>5</sup>

In our case, CT imaging was useful in confirming the fusion defect of the rostral nasal cavity and continuation of the cyst through the osseous cribriform plate. Identification of excessive keratin in CT-guided FNA samples of the mass raised a strong suspicion of dermoid cyst with a definitive diagnosis made based on histopathological findings of apocrine glands and embedded hair follicles within the tissue samples. The prominent inflammation in the surrounding tissues was suspicious of a rupture of the cyst wall, and positive culture of the cyst contents confirmed concurrent cystic infection.

Intracranial dermoid cysts in people are often detected incidentally; however, in cases of rupture of cystic contents, the most common presenting complaints are seizures and headaches.<sup>5</sup> Clinical signs are also expected when the cyst becomes infected, particularly when in contact with the dura mater.<sup>23,30</sup>

In people, surgical excision is recommended over medical management owing to susceptibility of the lesions to recurrent infections and complications associated with continued growth and subsequent mass effect.<sup>23,29</sup> Surgical excision is reported to carry an excellent prognosis when removal of all cystic lining and contents is complete; recurrence rates of up to 100% are reported with incomplete excision.<sup>11,28</sup>

Although idiopathic epilepsy (epilepsy of unknown cause) accounts for 30–60% of cats with seizures, persistent altered behaviour, aggression and pyrexia were indicative of possible underlying structural disease in this case. Advanced imaging is generally always recommended in any cat presenting for seizures, and the presence of additional neurological abnormalities emphasized the need for MRI.<sup>31–33</sup>

## Conclusions

We describe the first report of a nasal dermoid cyst in a cat and the first veterinary report of a nasal dermoid cyst causing neurologic clinical signs as the presenting complaint. We suggest that FNA cytology through the osseous defect may be a useful diagnostic tool and surgical excision may carry a good prognosis if all cystic contents and lining can be removed. Sinonasal infection subsequent to turbinate damage may be an anticipated sequela to surgery.

**Conflict of interest** The authors declared no potential conflicts of interest with respect to the research, authorship, and/or publication of this article.

**Funding** The authors received no financial support for the research, authorship, and/or publication of this article.

## References

- 1 Sessions RB. **Nasal dermal sinuse – new concepts and explanations.** *Laryngoscope* 1982; 92: 1–28.
- 2 Hartley BE, Eze N, Trozzi M, et al. **Nasal dermoids in children: a proposal for a new classification based on 103 cases at Great Ormond Street Hospital.** *Int J Pediatr Otorhinolaryngol* 2015; 79: 18–22.
- 3 Bradley PJ. **The complex nasal dermoid.** *Head Neck Surg* 1983; 5: 469–473.
- 4 Targett MP, McInnes E and Dennis R. **Magnetic resonance imaging of a medullary dermoid cyst with secondary hydrocephalus in a dog.** *Vet Radiol Ultrasound* 1999; 40: 23–26.
- 5 Mucaj S, Ugurel MS, Dedushi K, et al. **Role of MRI in diagnosis of ruptured intracranial dermoid cyst.** *Acta Inform Med* 2017; 25: 141–144.
- 6 van der Peijl GJ and Schaeffer IG. **Nasal dermoid cyst extending through the frontal bone with no sinus tract in a Dalmatian.** *J Small Anim Pract* 2011; 52: 117–120.
- 7 Hedlund G. **Congenital frontonasal masses: developmental anatomy, malformations, and MR imaging.** *Pediatr Radiol* 2006; 36: 647–662.

- 8 Rahbar R, Shah P, Mulliken JB, et al. **The presentation and management of nasal dermoid: a 30-year experience.** *Arch Otolaryngol Head Neck Surg* 2003; 129: 464–471.
- 9 Anderson DM and White RAS. **Nasal dermoid sinus cysts in the dog.** *Vet Surg* 2002; 31: 303–308.
- 10 Phelan AL, Jones CM, Ceschini AS, et al. **Sparing a craniotomy: the role of intraoperative methylene blue in management of midline dermoid cysts.** *Plast Reconstr Surg* 2017; 139: 1445–1451.
- 11 Seidel DU and Sesterhenn AM. **Intracranial nasal dermoid sinus cyst.** *J Craniofac Surg* 2016; 27: 2110–2112.
- 12 Opsomer D, Allaeyts T, Alderweireldt AS, et al. **Intracranial complications of midline nasal dermoid cysts.** *Acta Chir Belg.* Epub ahead of print 5 December 2017. DOI: 10.1080/00015458.2017.1411552.
- 13 Gavin PR. **Sequence selection.** In: Gavin PR and Bagley RS (eds) *Practical small animal MRI.* Ames, IA: Wiley-Blackwell, 2009, pp 8–9.
- 14 El-Fattah AM, Naguib A, El-Sisi H, et al. **Midline nasofrontal dermoids in children: a review of 29 cases managed at Mansoura University Hospitals.** *Int J Pediatr Otorhinolaryngol* 2016; 83: 88–92.
- 15 Kiviranta AM, Lappalainen AK, Hagner K, et al. **Dermoid sinus and spina bifida in three dogs and a cat.** *J Small Anim Pract* 2011; 52: 319–324.
- 16 Fleming JM, Platt SR, Kent M, et al. **Cervical dermoid sinus in a cat: case presentation and review of the literature.** *J Feline Med Surg* 2011; 13: 992–996.
- 17 Akhtardanesh B, Kheirandish R and Azari O. **Dermoid cyst in a domestic shorthair cat.** *Asian Pac J Trop Biomed* 2012; 2: 247–249.
- 18 Henderson JP, Pearson GR and Smerdon TN. **Dermoid cyst of the spinal cord associated with ataxia in a cat.** *J Small Anim Pract* 1993; 34: 402–404.
- 19 Tong T and Simpson DJ. **Case report: spinal dermoid sinus in a Burmese cat with paraparesis.** *Aust Vet J* 2009; 87: 450–454.
- 20 Pratt JN, Knottenbelt CM and Welsh EM. **Dermoid sinus at the lumbosacral junction in an English springer spaniel.** *J Small Anim Pract* 2000; 41: 24–26.
- 21 Chenier S, Quesnel A and Girard C. **Intracranial teratoma and dermoid cyst in a kitten.** *J Vet Diagn Invest* 1998; 10: 381–384.
- 22 Howard-Martin M and Bowles MH. **Intracranial dermoid cyst in a dog.** *J Am Vet Med Assoc* 1988; 192: 215–216.
- 23 Bailey TR, Holmberg DL and Yager JA. **Nasal dermoid sinus in an American cocker spaniel.** *Can Vet J* 2001; 42: 213–215.
- 24 Sturgeon C. **Nasal dermoid sinus cyst in a shih tzu.** *Vet Rec* 2008; 163: 219–220.
- 25 Burrow RD. **A nasal dermoid sinus in an English bull terrier.** *J Small Anim Pract* 2004; 45: 572–574.
- 26 Plumb DC. *Plumb's veterinary drug handbook.* 6th ed. Stockholm, WI: PharmaVet, 2008.
- 27 Nau R, Sorgel F and Eiffert H. **Penetration of drugs through the blood–cerebrospinal fluid/blood–brain barrier for treatment of central nervous system infections.** *Clin Microbiol Rev* 2010; 23: 858–883.
- 28 Ortlip T, Ambro BT and Pereira KD. **Midline approach to pediatric nasofrontal dermoid cysts.** *JAMA Otolaryngol Head Neck Surg* 2015; 141: 174–177.
- 29 Moses MA, Green BC, Cugno S, et al. **The management of midline frontonasal dermoids: a review of 55 cases at a tertiary referral center and a protocol for treatment.** *Plast Reconstr Surg* 2015; 135: 187–196.
- 30 Perazzi A, Berlanda M, Bucci M, et al. **Multiple dermoid sinuses of type Vb and IIb on the head of a Saint Bernard dog.** *Acta Vet Scand* 2013; 55: 62. DOI: 10.1186/1751-0147-55-62.
- 31 Pakozdy A, Halasz P and Klang A. **Epilepsy in cats: theory and practice.** *J Vet Intern Med* 2014; 28: 255–263.
- 32 Heller HB. **Feline epilepsy.** *Vet Clin North Am Small Anim Pract* 2018; 48: 31–43.
- 33 Berendt M, Farquhar RG, Mandigers PJ, et al. **International veterinary epilepsy task force consensus report on epilepsy definition, classification and terminology in companion animals.** *BMC Vet Res* 2015; 11: 182. DOI: 10.1186/s12917-015-0461-2.