



Escherichia coli-induced granulomatous colitis in a cat

Authors: Matsumoto, Isao, Nakashima, Ko, Morita, Hajime, Kasahara, Koichi, Kataoka, Osamu, et al.

Source: Journal of Feline Medicine and Surgery Open Reports, 5(1)

Published By: SAGE Publishing

URL: <https://doi.org/10.1177/2055116919836537>

BioOne Complete (complete.BioOne.org) is a full-text database of 200 subscribed and open-access titles in the biological, ecological, and environmental sciences published by nonprofit societies, associations, museums, institutions, and presses.

Your use of this PDF, the BioOne Complete website, and all posted and associated content indicates your acceptance of BioOne's Terms of Use, available at www.bioone.org/terms-of-use.

Usage of BioOne Complete content is strictly limited to personal, educational, and non - commercial use. Commercial inquiries or rights and permissions requests should be directed to the individual publisher as copyright holder.

BioOne sees sustainable scholarly publishing as an inherently collaborative enterprise connecting authors, nonprofit publishers, academic institutions, research libraries, and research funders in the common goal of maximizing access to critical research.



Escherichia coli-induced granulomatous colitis in a cat

Isao Matsumoto^{1,2}, Ko Nakashima¹, Hajime Morita¹, Koichi Kasahara¹, Osamu Kataoka³ and Kazuyuki Uchida²

Journal of Feline Medicine and Surgery Open Reports
1–5

© The Author(s) 2019

Article reuse guidelines:

sagepub.com/journals-permissions

DOI: 10.1177/2055116919836537

journals.sagepub.com/home/jfmsopenreports

This paper was handled and processed by the European Editorial Office (ISFM) for publication in *JFMS Open Reports*



Abstract

Case summary A 10-year-old castrated male domestic shorthair cat presented with a 6 month history of diarrhoea that responded poorly to medical treatment. Ultrasonography revealed moderate thickening of the colonic wall (4.8 mm) and right colic and jejunal lymphadenomegalies. Endoscopic examination revealed partial circumferential narrowing of the transverse colon and friable colonic mucosa with multiple haemorrhagic regions. Histopathological and immunohistochemical examinations revealed a large number of *Escherichia coli* phagocytosed by periodic acid–Schiff-positive macrophages. Bacterial culture also yielded enrofloxacin-sensitive *E coli*. The cat was initially treated with prednisolone, which resulted in little improvement. Following histopathological examination and bacterial culture, treatment with enrofloxacin was commenced. Antibacterial therapy resulted in remission of the diarrhoea and an increase in body weight within 14 days.

Relevance and novel information Granulomatous colitis (GC) or histiocytic ulcerative colitis has been rarely described in cats. There has only been one previously published case study involving a cat, and the aetiology remains largely unknown. The current article describes the regression of *E coli*-related GC following antibacterial treatment in a cat. Clinical signs, histopathological appearance and response to enrofloxacin were similar to those in canine GC. The current findings suggest that *E coli* also plays an important role in the development of feline GC.

Keywords: *E coli*; enrofloxacin; granulomatous colitis

Accepted: 11 February 2019

Case description

A 10-year-old castrated male domestic shorthair cat presented with a 6 month history of diarrhoea, haematochezia and mucoid faeces. At a referring hospital, diarrhoea initially resolved with prednisolone and a commercial diet consisting of low-molecular-weight peptides but amoxicillin clavulanic acid. Recurrent diarrhoea responded poorly to prednisolone. The cat also developed chronic kidney disease and cardiomyopathy. It was referred to the Japan Small Animal Medical Center (Saitama, Japan) for endoscopic examination.

At the time of presentation, the cat was markedly lethargic and experienced vomiting once a week and large bowel diarrhoea 2–3 times daily. Its body weight had decreased significantly, from 5.6 kg to 4.75 kg. A faecal examination yielded unremarkable results. Serum biochemical tests revealed an elevated creatinine level

(2.6 mg/dl). Abdominal radiographs were normal. Ultrasonography revealed moderately increased intestinal wall thickness (4.8 mm) from the ascending to proximal descending colon (Figure 1). Enlarged right colic and jejunal lymph nodes were noted (9.5 mm × 7.1 mm

¹Japan Small Animal Medical Center, Tokorozawa-shi, Saitama, Japan

²Laboratory of Veterinary Pathology, Graduate School of Agricultural and Life Sciences, The University of Tokyo, Tokyo, Japan

³Kataoka Aiken Animal Hospital, Saitama, Japan

Corresponding author:

Ko Nakashima DVM, Japan Small Animal Medical Center, 1-10-4 Wada, Higashitokorozawa, Tokorozawa-shi, Saitama 359-0023, Japan
Email: endoscopist@jsamc.jp



Creative Commons Non Commercial CC BY-NC: This article is distributed under the terms of the Creative Commons

Attribution-NonCommercial 4.0 License (<http://www.creativecommons.org/licenses/by-nc/4.0/>) which permits non-commercial use, reproduction and distribution of the work without further permission provided the original work is attributed as specified on the SAGE and Open Access pages (<https://us.sagepub.com/en-us/nam/open-access-at-sage>).

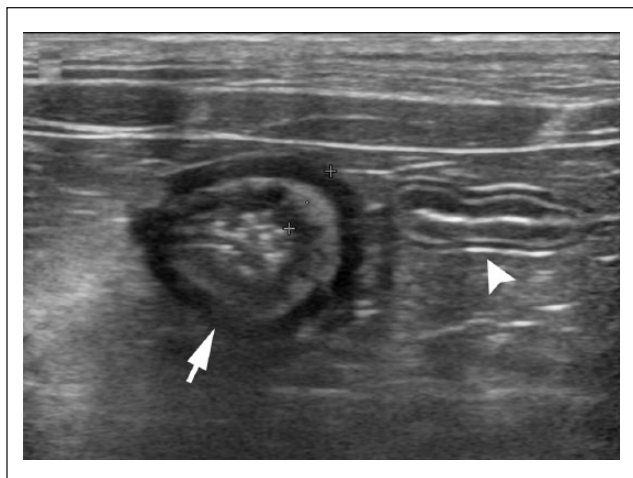


Figure 1 Ultrasonographic appearance of the jejunum (arrowhead) and ascending colon on a transverse section revealing increased wall thickness to 4.8 mm (arrow)

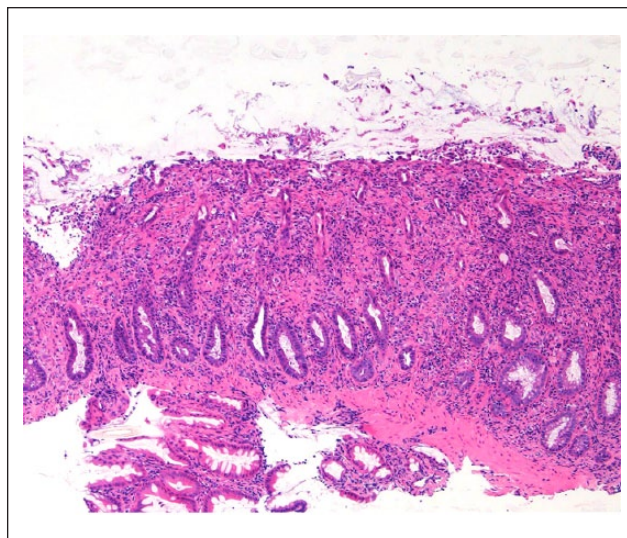


Figure 3 Colon. Lower magnification reveals thickening of the colonic wall. Marked ulceration of the colonic mucosa and distortion of the glandular architecture in the lamina propria are identified. Haematoxylin and eosin

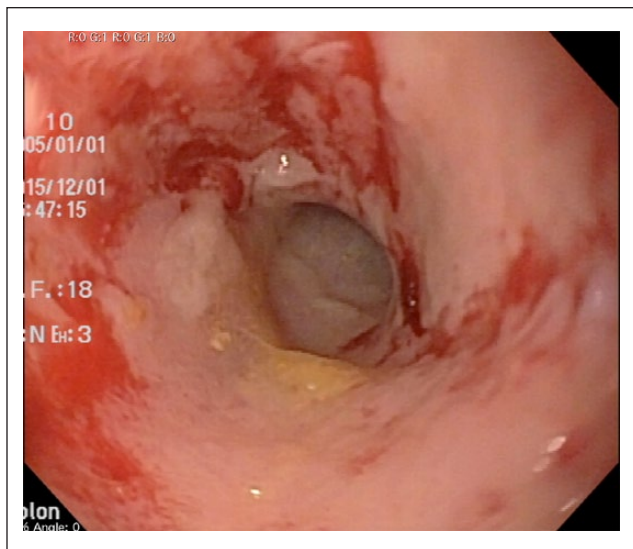


Figure 2 Endoscopic image of the transverse colon. Multiple haemorrhagic lesions are apparent in the friable mucous membrane

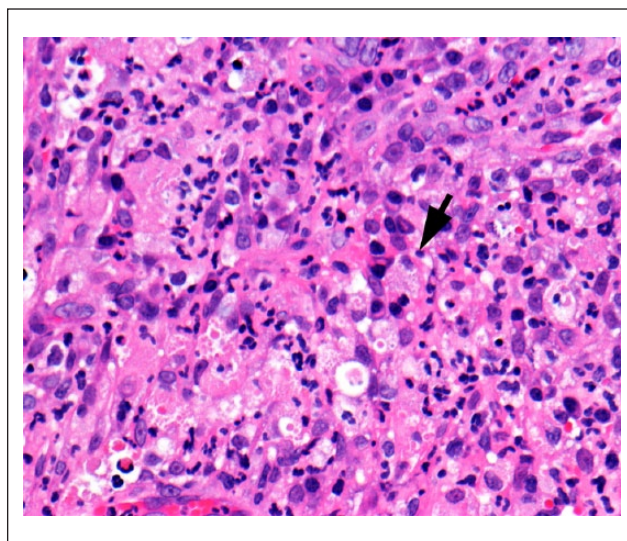


Figure 4 Colon. Marked transmural infiltration of foamy macrophages (arrow) is accompanied by neutrophils, plasma cells and lymphocytes

and 10.4 mm × 6.1 mm, respectively). Endoscopic examination revealed partial circumferential narrowing of the transverse colon and friable colonic mucosa with multiple haemorrhagic regions (Figure 2). The mucosa of the duodenum and jejunum was mildly oedematous. The thickness of the oesophageal and gastric mucosa was within normal limits. Mucosal tissue specimens were obtained from the stomach, duodenum and colon. The collected tissue samples were fixed in 10% buffered formalin and subjected to histopathological examination.

Histological examination with haematoxylin and eosin staining (HE) revealed marked ulceration of the colonic mucosa; marked alteration in the normal glandular

architecture was observed in the lamina propria (Figure 3). The lesions consisted of marked transmural infiltration of foamy macrophages accompanied by neutrophils, plasma cells and lymphocytes (Figure 4). Apart from the colonic lesion, marked infestation of mucosa spirochetes was observed in the stomach. Duodenal lesions were unremarkable. A provisional diagnosis of granulomatous colitis (GC) was made based on the histopathological appearance (HE) at day 7.

Owing to its rarity in cats, additional stains and immunohistochemistry were performed for definitive

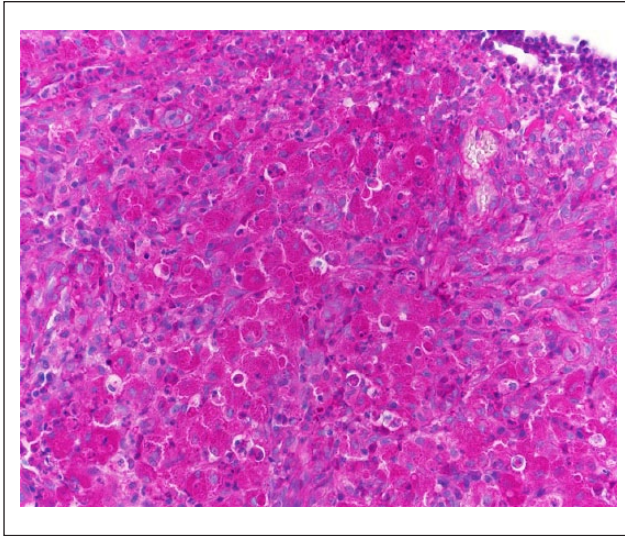


Figure 5 Colon. Infiltration of periodic acid-Schiff stain-positive macrophages in the lamina propria

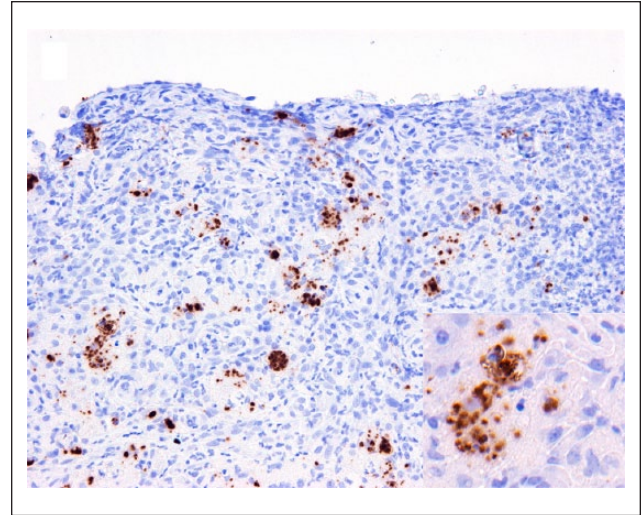


Figure 7 Colon. Numerous bacilli are identified in the colonic lamina propria. Immunohistochemistry for *Escherichia coli* lipopolysaccharide

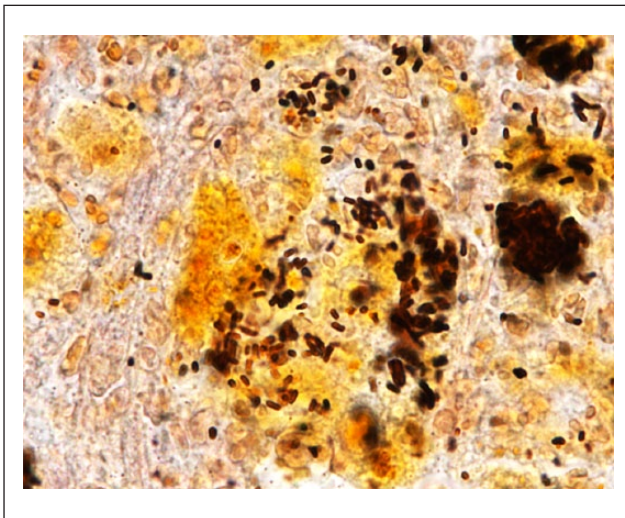


Figure 6 Colon. Colonisation of bacilli is identified in the granulomatous lesion. Warthin-Starry stain

diagnosis. The infiltrating macrophages were predominantly periodic acid-Schiff (PAS) positive (Figure 5). Warthin-Starry, Ziehl-Neelsen and gram stains identified intracytoplasmic non-acid-fast, gram-negative bacilli in the macrophages on tissue section (Figure 6). The infiltration of macrophages and *Escherichia coli* colonisation were further confirmed by immunohistochemical analyses. Immunohistochemistry revealed marked infiltration of CD204+ Iba-1+ macrophages and colonisation of *E coli* in the granulomatous lesions (Figure 7). In view of these findings, a final diagnosis of GC was made at day 21.

At day 0, prior to a definitive diagnosis of GC with histopathology and immunohistochemistry, the cat was

initially treated with prednisolone (1 mg/kg q24h), famotidine (1 mg/kg q24h), metoclopramide (0.25 mg/kg q12h) and probiotics (*Streptococcus faecalis* 129 BIO 3B-R [Biofermin-R; Biofermin Pharmaceutical]; half tablet q24h) for 4 weeks. The cat was fed a therapeutic diet (Renal Support; Royal Canin). The initial treatment appeared to only partially improve clinical signs. The cat had semi-formed stools twice daily, with inconsistent solid stools. Body weight decreased from 4.75 kg to 4.45 kg within the first 28 days of treatment.

Following the definitive diagnosis, additional colonoscopic tissue sampling was performed for bacterial culture and sensitivity at day 28. After saline wash, a homogenised sample was subjected to bacterial culture. Attempts to isolate bacteria on culture media yielded enrofloxacin-sensitive *E coli* (2+). Treatment with enrofloxacin was also initiated at day 28. The animal was prescribed enrofloxacin (5 mg/kg q24h for 13 weeks), as recommended in dogs,¹ prednisolone (0.5 mg/kg q24h for 5 weeks), famotidine (1 mg/kg q24h for 2 weeks), metoclopramide (0.25 mg/kg q12h for 13 weeks) and the aforementioned probiotic half-tablet (q24h for 13 weeks). The cat more consistently produced solid or semi-formed stools once daily and its body weight increased to 4.75 kg by day 42.

The cat's body weight increased to 5.0 kg and formed solid stools twice daily by day 63. Although ultrasound examinations at day 119 showed persistent wall thickening of the ascending and transverse colon (4.6 mm), enrofloxacin was discontinued because the thickness of the right colic lymph nodes was within the normal limit. At day 207, approximately 3 months after cessation of the first course of enrofloxacin, recurrent diarrhoea was noted once every 3 days. Upon examination at day 234,

the cat's body weight was found to have decreased to 4.8 kg. Ultrasonography revealed thickening of the ascending and transverse colonic wall (4.6 mm), and moderately enlarged right colic lymph nodes (8 mm). Serum biochemical tests revealed increased creatinine (3.4 mg/dl) and urea nitrogen (34.5 mg/dl) levels. The cat was treated with enrofloxacin (5 mg/kg q24h for 15 weeks and q48h for the following 8 weeks). Faecal consistency dramatically improved by day 244. However, the cat experienced another episode of diarrhoea at day 751, approximately 12 months after cessation of the second course of enrofloxacin. Enrofloxacin was reinitiated (5 mg/kg q24h for 4 weeks) and a positive clinical response was noted by day 755.

The cat has been free of clinical signs for the following 7 months and has been off enrofloxacin without recurrence for 5 months (day 950). Enrofloxacin-associated retinal degeneration was not observed in the current case.

Discussion

An enteropathy called GC, or histiocytic ulcerative colitis, is characterised by granulomatous inflammation of the colonic mucosa, lamina propria and submucosa, with marked transmural infiltration of PAS-positive macrophages.^{2,3} PAS-positive material is considered to be glycoprotein from bacterial cell walls.⁴ GC has been frequently reported in dogs; however, only a limited number of cases have been reported in cats.⁴ Clinical presentation, and macroscopic and microscopic findings in the present study were consistent with those described in dogs.^{2,3,5} In canine cases, macrophage heterogeneity suggests a difference in function compared with healthy individuals.⁶

Although the pathogenesis is not well understood, recent studies have identified *E coli* in canine patients.^{5,7,8} There are phylogenetic similarities between the *E coli* strain obtained from Boxer dog GC, and adherent and invasive *E coli* (AIEC) in human Crohn's disease.⁸ AIEC is able to replicate within epithelial cells and macrophages without inducing host cell death.⁹ AIEC has been isolated from the feline intestine at an exceptionally high frequency (82%),¹⁰ and the association between AIEC and feline GC needs to be further investigated. In the current case, identification of *E coli* in the granulomatous lesion was consistent with a previous feline study that reported bacilli within the phagocytic vacuoles of macrophages.⁴ Although not performed in the current case study, identification of the *E coli* strain and repeated histopathological evaluation would be valuable to understanding the nature of feline GC.

As demonstrated in canine case studies,¹¹ regression of clinical signs following antibacterial treatment in the present case suggests a critical role of *E coli* in feline GC. The cat responded well to intermittently administered enrofloxacin when it had semi-formed stools or diarrhoea.

Dramatic improvement in faecal consistency was noted within 2 weeks of antibacterial treatment, which is consistent with previous investigations involving dogs.¹ In dogs, at least 6–8 weeks of treatment at doses of 5–10 mg/kg body weight q24h is recommended.¹ However, response to antibacterials varies among individual dogs,^{1,11} and it appears that antibacterial resistance significantly affects clinical outcomes.¹² Although the current single case was insufficient to determine the factors affecting clinical outcomes in cats, a future case series would help in determining the optimal use of antibacterials in feline GC.

Over-representation of the Boxer dog breed suggests that GC might be a breed-specific disease; however, it has also been reported in other canine breeds.^{2,5,7,13–16} While dogs <4 years of age are typically affected by GC,² in this case and the other case study middle-aged cats were affected.⁴ The rarity of the disease in cats may suggest variation in hereditary susceptibility to *E coli*-related GC between dogs and cats.

The present case report described the case of a cat with *E coli*-related GC that regressed following long-term treatment with enrofloxacin. Clinical presentation, and endoscopic and microscopic findings closely resembled those described in dogs. Immunohistochemically, *E coli* was detected within granulomatous lesions, and resolution of gastrointestinal clinical signs following antibacterial treatment may reflect the critical role of *E coli* in feline GC. The rarity of the disease in cats may suggest substantial differences in host susceptibility to *E coli*-induced GC. Together with our findings, additional cases will enable a better understanding of the clinical nature of GC in cats.

Conclusions

GC should be included in the differential diagnoses in feline cases with marked submucosal infiltration of macrophages in the colon that respond poorly to immunosuppressive and dietary treatment. In such cases, further immunohistochemical identification of *E coli* and treatment with enrofloxacin may be suggested.

Conflict of interest The authors declared no potential conflicts of interest with respect to the research, authorship, and/or publication of this article.

Funding The authors received no financial support for the research, authorship, and/or publication of this article.

References

- 1 Mansfield CS, James FE, Craven M, et al. **Remission of histiocytic ulcerative colitis in Boxer dogs correlates with eradication of invasive intramucosal *Escherichia coli*.** *J Vet Intern Med* 2009; 23: 964–969.
- 2 Van Kruiningen HJ, Montali RJ, Strandberg JD, et al. **A granulomatous colitis of dogs with histologic resemblance to Whipple's disease.** *Path Vet* 1965; 2: 521–544.

- 3 Gomez JA, Russell SW, Trowbridge JO, et al. **Canine histiocytic ulcerative colitis. An ultrastructural study of the early mucosal lesion.** *Am J Dig Dis* 1977; 22: 485–496.
- 4 Van Kruiningen HJ and Dobbins WO 3rd. **Feline histiocytic colitis. A case report with electron microscopy.** *Vet Pathol* 1979; 16: 215–222.
- 5 Carvallo FR, Kerlin R, Fredette C, et al. **Histiocytic typhlocolitis in two colony Beagle dogs.** *Exp Toxicol Pathol* 2015; 67: 219–221.
- 6 Nolte A, Junginger J, Baum B, et al. **Heterogeneity of macrophages in canine histiocytic ulcerative colitis.** *Innate Immun* 2017; 23: 228–239.
- 7 Manchester AC, Hill S, Sabatino B, et al. **Association between granulomatous colitis in French Bulldogs and invasive *Escherichia coli* and response to fluoroquinolone antimicrobials.** *J Vet Intern Med* 2013; 27: 56–61.
- 8 Simpson KW, Dogan B, Rishniw M, et al. **Adherent and invasive *Escherichia coli* is associated with granulomatous colitis in boxer dogs.** *Infect Immun* 2006; 74: 4778–4792.
- 9 Glasser AL, Boudeau J, Barnich N, et al. **Adherent invasive *Escherichia coli* strains from patients with Crohn's disease survive and replicate within macrophages without inducing host cell death.** *Infect Immun* 2001; 69: 5529–5537.
- 10 Martinez-Medina M, Garcia-Gil J, Barnich N, et al. **Adherent-invasive *Escherichia coli* phenotype displayed by intestinal pathogenic *E. coli* strains from cats, dogs, and swine.** *Appl Environ Microbiol* 2011; 77: 5813–5817.
- 11 Hostutler RA, Luria BJ, Johnson SE, et al. **Antibiotic-responsive histiocytic ulcerative colitis in 9 dogs.** *J Vet Intern Med* 2004; 18: 499–504.
- 12 Craven M, Dogan B, Schukken A, et al. **Antimicrobial resistance impacts clinical outcome of granulomatous colitis in boxer dogs.** *J Vet Intern Med* 2010; 24: 819–824.
- 13 Craven M, Mansfield CS and Simpson KW. **Granulomatous colitis of boxer dogs.** *Vet Clin North Am Small Anim Pract* 2011; 41: 433–445.
- 14 Stokes JE, Kruger JM, Mullaney T, et al. **Histiocytic ulcerative colitis in three non-boxer dogs.** *J Am Anim Hosp Assoc* 2001; 37: 461–465.
- 15 Tanaka H, Nakayama M and Takase K. **Histiocytic ulcerative colitis in a French bulldog.** *J Vet Med Sci* 2003; 65: 431–433.
- 16 Van der Gaag I, Van Toorenburg JV, Voorhout G, et al. **Histiocytic ulcerative colitis in a French Bulldog.** *J Small Anim Pract* 1978; 19: 283–290.