



## **Late-onset osteosarcoma after onychectomy in a cat**

Author: Breitreiter, Katrina

Source: Journal of Feline Medicine and Surgery Open Reports, 5(1)

Published By: SAGE Publishing

URL: <https://doi.org/10.1177/2055116919842394>

---

BioOne Complete ([complete.BioOne.org](https://complete.BioOne.org)) is a full-text database of 200 subscribed and open-access titles in the biological, ecological, and environmental sciences published by nonprofit societies, associations, museums, institutions, and presses.

Your use of this PDF, the BioOne Complete website, and all posted and associated content indicates your acceptance of BioOne's Terms of Use, available at [www.bioone.org/terms-of-use](https://www.bioone.org/terms-of-use).

Usage of BioOne Complete content is strictly limited to personal, educational, and non - commercial use. Commercial inquiries or rights and permissions requests should be directed to the individual publisher as copyright holder.

---

BioOne sees sustainable scholarly publishing as an inherently collaborative enterprise connecting authors, nonprofit publishers, academic institutions, research libraries, and research funders in the common goal of maximizing access to critical research.



# Late-onset osteosarcoma after onychectomy in a cat

Katrina Breitreiter

*Journal of Feline Medicine and Surgery Open Reports*  
1–6

© The Author(s) 2019

Article reuse guidelines:

sagepub.com/journals-permissions

DOI: 10.1177/2055116919842394

journals.sagepub.com/home/jfmsopenreports

This paper was handled and processed by the American Editorial Office (AAFP) for publication in *JFMS Open Reports*



## Abstract

**Case summary** A 12-year-old neutered male onychectomized Ragdoll cat presented for a 3 day history of swelling and hemorrhagic purulent discharge on the first digit of the left manus. Radiographs revealed fragments of the third phalangeal bone (P3) present in the partially amputated digits with swelling adjacent to the P3 fragment on the first digit of the left manus. Thoracic radiographs revealed no evidence of primary or metastatic neoplasia. Surgery was performed to remove all P3 fragments and the associated swelling on the diseased digit. On gross examination of the excised swelling, a mass was present at the cut edge of P3. The bone fragment and associated mass were submitted for histopathological evaluation. Osteosarcoma was diagnosed. Because neoplastic cells extended to the surgical margins, amputation of the left thoracic limb was performed. The cat recovered from surgery, and survival time at the time of writing was 8 months.

**Relevance and novel information** To our knowledge, this is the first reported case of onychectomy-associated osteosarcoma. Trauma from partial P3 amputation during onychectomy is suspected to have played a role in osteosarcoma development in this case. Malignant transformation may be considered a potential complication of onychectomy achieved by partial P3 amputation.

**Keywords:** Osteosarcoma; declaw; onychectomy; malignant transformation

**Accepted:** 13 March 2019

## Introduction

Osteosarcoma is a malignant neoplasm of mesenchymal spindle cells that produce an extracellular matrix of bone or osteoid.<sup>1</sup> Osteosarcoma is the most common primary feline bone tumor, accounting for approximately 70–80% of all primary bone tumors found in cats.<sup>1–4</sup> Osteosarcomas occur most commonly in older cats with a mean age of approximately 10 years.<sup>1–3,5,6</sup> No consistent sex or breed predilections have been identified.<sup>2</sup>

Osteosarcomas may affect the appendicular skeleton, axial skeleton or extraskeletal structures.<sup>1,2</sup> In cats with appendicular osteosarcomas, the pelvic limbs are more commonly affected than the thoracic limbs.<sup>2,4,6</sup> Clinical signs of osteosarcoma vary depending on tumor location.<sup>3</sup> Appendicular osteosarcomas may present with swelling, pain, lameness and decreased joint mobility.<sup>4,5</sup> Pathological fractures may also occur secondary to appendicular osteosarcoma.<sup>5</sup> Axial osteosarcomas may cause dental problems, skull deformities, firm swellings and nasal

discharge. Extraskeletal osteosarcomas occur more frequently at vaccine and injection sites.<sup>2</sup>

Prognosis varies depending on the location of the tumor. In cases of axial osteosarcoma in cats, prognosis is generally poor with an average survival time of 6 months. Appendicular osteosarcoma carries a more favorable prognosis, particularly when treated with complete surgical excision or amputation, with a reported average survival time of 26–49 months.<sup>5</sup>

Histologically, the mitotic index of the tumor has been shown to have a significant effect on survival time.<sup>1</sup>

South Austin Cat Hospital, Austin, TX 78747, USA

### Corresponding author:

Katrina Breitreiter DVM, South Austin Cat Hospital, 11215 S IH 35 ste 109, Austin, TX 78747, USA  
Email: kbreitreiter@southaustincathospital.com



Creative Commons Non Commercial CC BY-NC: This article is distributed under the terms of the Creative Commons

Attribution-NonCommercial 4.0 License (<http://www.creativecommons.org/licenses/by-nc/4.0/>) which permits non-commercial use, reproduction and distribution of the work without further permission provided the original work is attributed as specified on the SAGE and Open Access pages (<https://us.sagepub.com/en-us/nam/open-access-at-sage>).

Although histologically similar to osteosarcomas in dogs, osteosarcomas in cats carry a more favorable prognosis.<sup>1,5</sup> Compared with osteosarcoma in dogs, feline osteosarcomas are slower growing and less likely to metastasize.<sup>4</sup>

Previous trauma has been shown to play a role in feline osteosarcoma, with numerous documented cases of osteosarcomas forming at old fracture sites.<sup>2,7-10</sup> While many of these tumors have formed within 5 years of the initial trauma, others have documented late-onset fracture-associated osteosarcoma in a cat.<sup>7,10</sup> Other sarcomas, specifically injection-site sarcomas, are known to form at sites of chronic inflammation in cats.

Although osteosarcoma has been reported in the digits of cats, none of those reports addressed the onychectomy status of the cat or documented malignant transformation of a fragment of the third phalangeal bone (P3).<sup>1,2,11</sup> This report describes the diagnosis and treatment of an appendicular osteosarcoma originating from a P3 fragment of the first digit in an onychectomized cat.

### Case description

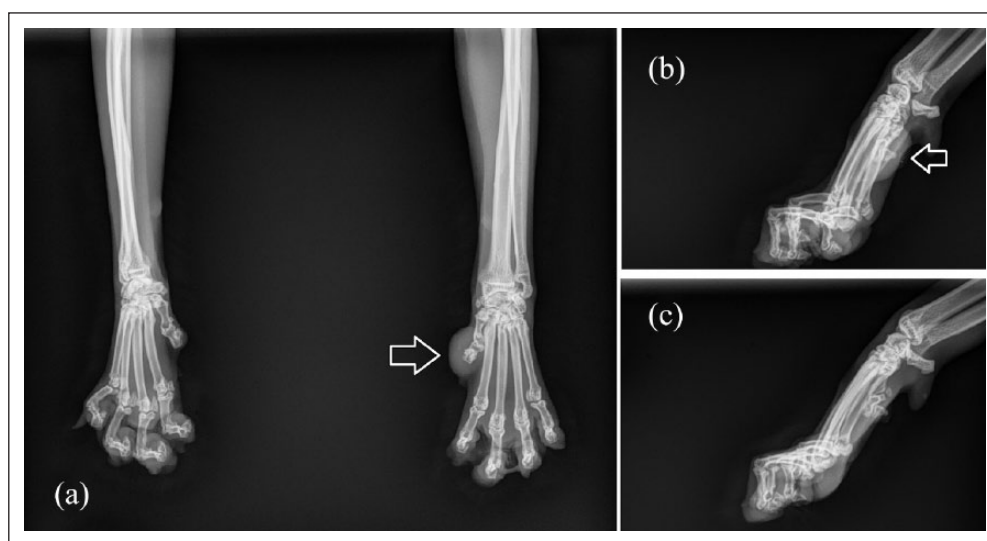
A 12-year-old neutered male onychectomized Ragdoll cat presented for a 3 day history of swelling and hemorrhagic discharge from the left manus. The cat had a history of chronic constipation, which was well managed with cisapride, polyethylene glycol 3350 (Miralax; Bayer) and canned food. The cat also had a history of feline asthma, which was well controlled with a daily fluticasone inhaler (Flovent; GSK). Medical history pertaining to onychectomy was unknown except that the procedure was performed before the owner found the cat 10 years prior to presentation. The cat was housed completely

indoors with one other cat in the household. There was no history of inter-cat aggression.

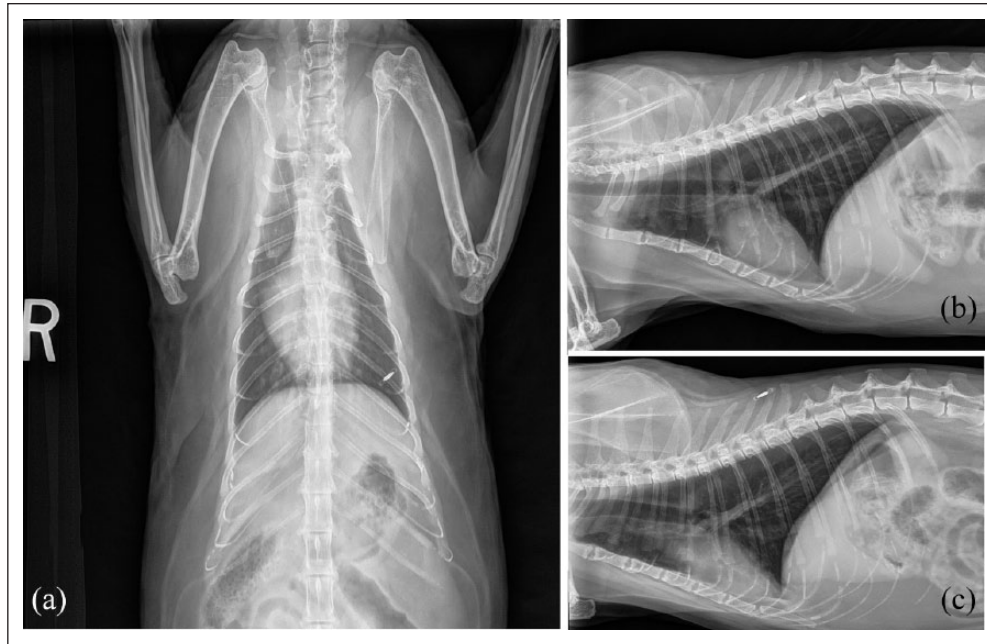
On presentation, the cat was bright, alert, responsive and weighed 4.9 kg, with a body condition score of 5/9 and a muscle condition score of 3/3.<sup>12</sup> On physical examination, an approximately 1.5 cm firm swelling was associated with the first digit of the left manus. A small amount of hemorrhagic purulent discharge was present, and the swelling was mobile on flexion and extension of the partially amputated digit. The cat also had moderate dental calculus present on the carnassial teeth. The physical examination was otherwise normal.

Dorsopalmar and mediolateral manus radiographs revealed P3 fragments present in each partially amputated digit (Figure 1). On the first digit of the left manus, notable soft-tissue swelling and a small amount of mineral opacity were noted distal to the P3 fragment.

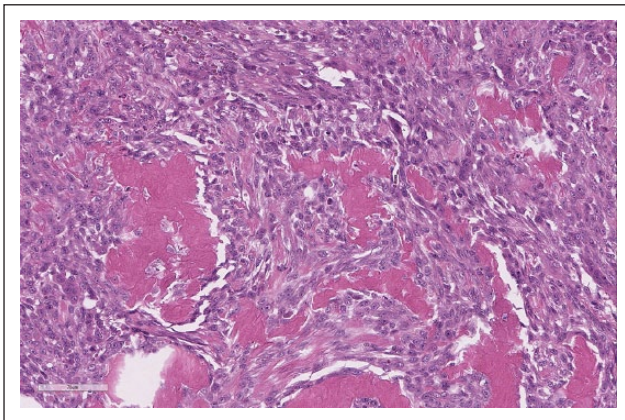
Differentials for swelling of the digit included abscess, trauma, osteomyelitis, cellulitis, primary neoplasia, metastatic neoplasia, subungual cyst and claw regrowth under the skin resulting from remaining germinal cells in the P3 fragment. To further assess the cat for potentially metastatic disease, three-view thoracic radiographs were also evaluated (Figure 2). No abnormalities were identified in the thoracic cavity, and a board-certified veterinary radiologist confirmed that there was no evidence of primary or metastatic neoplasia. A complete blood cell count, chemistry and urinalysis revealed mild prerenal azotemia with a creatinine of 1.7 mg/dl and a urine specific gravity of 1.055. The results were otherwise considered within the reference intervals established for feline patients on the Abaxis Vetscan VS2 and HM5 analyzers used. The cat received a single subcutaneous injection of cefovecin



**Figure 1** (a) Dorsopalmar view of the left and right thoracic limbs, (b) lateral view of the left thoracic limb and (c) lateral view of the right thoracic limb. The arrows indicate the swelling and associated fragment of the third phalanx of the first digit of the left manus. P3 fragments of consistent size and shape are visible in each previously partially amputated digit



**Figure 2** (a) Ventrodorsal, (b) left lateral and (c) right lateral thoracic radiographs. No evidence of primary or metastatic neoplasia was identified



**Figure 3** Histopathology of the neoplasm arising from the distal phalanx of the first digit of the left manus. Spicules of unmineralized osteoid and neoplastic bone are present. Anisocytosis and anisokaryosis are moderate with a mitotic count of three mitotic figures in 10 high-powered fields. Stained with hematoxylin and eosin,  $\times 30$  magnification

(Convenia; Zoetis) 8 mg/kg for infection. Gabapentin (Wedgewood Compounding Pharmacy) 5 mg/kg PO q12h was prescribed for chronic pain and surgical removal of the swelling and remaining P3 fragments was recommended.

Ten days later, the purulent discharge resolved, but the ulcerated swelling remained. The cat was premedicated with a single intramuscular injection of dexmedetomidine (Dexdomitor; Zoetis) 10  $\mu$ g/kg, butorphanol (Torbugesic; Zoetis) 0.2 mg/kg and ketamine (Zetamine;

VetOne) 2 mg/kg. A 22 G intravenous catheter was placed in the medial saphenous vein, and anesthesia was induced with propofol (PropoFlo; Zoetis) 3 mg/kg IV given to effect. The cat was intubated and maintained on isoflurane (Fluriso; VetOne). A four-point ring block was performed, as described elsewhere,<sup>13</sup> using bupivacaine (Bupivacaine Hydrochloride; Hospira). Surgery was performed to remove the swelling, the associated P3 fragment and the P3 fragments present in the other partially amputated digits. Grossly, the excised swollen tissue contained a mass originating from the previously cut edge of the P3 fragment. The mass of tissue and associated P3 fragment were submitted to a reference laboratory for histopathological evaluation.

Postoperative pain was managed with a combination of buprenorphine (Simbadol; Zoetis) 0.18 mg/kg SC q24h for 3 days, gabapentin (Wedgewood Compounding Pharmacy) 5 mg/kg PO q12h for 10 days and injectable robenacoxib (Onsior; Novartis) 2 mg/kg SC q24h for 3 days. Mild swelling and erythema of the first digit of the left manus was noted postoperatively. Ice packs were applied to the swelling every 8–12 h, and the swelling resolved after 3 days.

Histopathological evaluation revealed infiltrative neoplastic cells composed of sheets and bundles of polygonal to stellate cells with spicules of unmineralized osteoid and neoplastic bone arising from the previously cut edge of the P3 fragment. Anisocytosis and anisokaryosis were moderate, the mitotic count was three mitotic figures in 10 high-powered fields and osteolysis of the cortical bone was identified (Figure 3). Osteosarcoma

was diagnosed. Thoracic limb amputation was recommended because the tumor cells extended to the resected margins.

Ten days later, a left thoracic limb amputation was performed using the anesthetic and analgesic protocols as described above. No enlarged axillary lymph nodes could be identified at the time of surgery. A seroma formed at the amputation site postoperatively but resolved without treatment. Two weeks postoperatively, the amputation site was fully healed, and the cat was ambulatory on the remaining three limbs. Eight months postoperatively, the cat was still disease free.

## Discussion

Onychectomy is the elective surgical amputation of the claws and all, or a portion of, the attached P3 bone. The procedure is performed to eliminate destructive scratching behaviors in cats. To our knowledge, there are no previously known reports of onychectomy-associated neoplasia published in the veterinary literature. Although several studies cite the digits as a location for osteosarcoma, none of these studies reported the onychectomy status of the affected cats.<sup>1,2,11</sup> The exact mechanism by which the onychectomy-associated osteosarcoma formed in this case was unknown. However, inflammation, trauma and the potential presence of surgical adhesive foreign material may have played a role.

Bony amputation has been described as a method of onychectomy in which a guillotine-style nail clipper is used to iatrogenically fracture P3, severing the claw, growth plate and unguis crest of P3 from the flexor process, leaving a portion of the fractured bone present in each partially amputated digit.<sup>14</sup> Although the onychectomy method used in the cat in the current case report was unknown, the large consistent size and shape of fragments of P3 identified in each partially amputated digit suggests that the guillotine technique was likely used. Onychectomy may also be performed by disarticulating P3 at the distal interphalangeal joint using a scalpel or surgical laser.<sup>14,15</sup> Although less common than with the guillotine method, remnants of P3 may inadvertently be left behind in the disarticulation method as well.<sup>14,16</sup> In a 2016 survey of veterinarians who perform onychectomy, only 5.4% were aware that fragments of P3 were being left behind at the time of the procedure.<sup>17</sup> However, one study found that 63% of the onychectomized cats evaluated had P3 fragments left behind at the time of surgery, and those cats were the most at risk for postoperative complications related to the onychectomy procedure.<sup>16</sup>

In the current case, osteosarcoma tumor cells extended from the previously cut edge of P3 with no gross attachment to the first or second phalanx. Fracture-associated osteosarcomas have been reported in numerous species,

including cats.<sup>2,7-10</sup> Other forms of trauma have also been linked to osteosarcoma development in soft tissues. Extraskelatal osteosarcomas have been reported in the eye secondary to ocular trauma,<sup>18,19</sup> the duodenum secondary to a foreign body reaction,<sup>20</sup> the mammary gland,<sup>21</sup> metatarsal foot pad,<sup>22</sup> muscle tissue<sup>23</sup> and at vaccination sites.<sup>24</sup> Trauma was thought to play a role in the development of osteosarcoma in these cases. It is plausible that osteosarcoma developed in the current case secondary to the trauma that occurred to the bone during the onychectomy procedure.

A strong association between chronic inflammation and neoplastic change has been established in cats.<sup>25</sup> Injection-site sarcomas, which may include osteosarcoma formation, have been well documented.<sup>24,26-28</sup> Similar-type sarcomas have been reported at the microchip implantation site of a cat, as well as at the site of a subcutaneous fluid port.<sup>29,30</sup> The presence of foreign material was thought to contribute to the chronic inflammatory process in these cases.<sup>29,30</sup> Tissue glue, which is commonly used during closure of onychectomy, has been shown to cause a mild-to-moderate inflammatory reaction, and the foreign material must be broken down by macrophages in the body.<sup>31</sup> Although it was unknown if tissue glue was used in the current cat, a 2016 survey of veterinarians who perform onychectomy found that approximately 70% use surgical adhesive during closure.<sup>17</sup> In our opinion, chronic inflammation and a high likelihood of the presence of foreign material in the surgical site may have contributed to neoplastic change in this case.

Information about the onychectomy procedure in this case was unavailable, and a direct causal relationship between the onychectomy and the malignant transformation of the P3 fragment could not be definitively proven. Consideration must be also given to the hypothesis that this cat could have developed osteosarcoma independently of the onychectomy, and that the tumor originating from the previous surgical site was purely coincidental. The age of the cat and prolonged time frame between onychectomy and osteosarcoma development may support this hypothesis.

Onychectomy has been linked with numerous complications, including pain,<sup>14,32-34</sup> infection,<sup>14,33,35</sup> hemorrhage,<sup>33,35</sup> swelling,<sup>33</sup> lameness,<sup>14,33-35</sup> incomplete healing,<sup>35</sup> reluctance to jump,<sup>14</sup> reluctance to scratch,<sup>14</sup> chewing at the digits,<sup>14</sup> neuropathic pain,<sup>14</sup> neuropraxia,<sup>35</sup> claw regrowth,<sup>14,16,33-35</sup> protrusion of the second phalanx,<sup>33,35</sup> callused and misshapen toe pads,<sup>33,35,36</sup> tissue necrosis,<sup>35</sup> increased aggression and biting behavior,<sup>37</sup> inappropriate elimination,<sup>16,34,37</sup> back pain,<sup>16</sup> muscle loss,<sup>34</sup> barbering,<sup>16</sup> and flexor tendon contracture.<sup>36,38</sup> Based on the current case, neoplasia may also be considered a potential complication of onychectomy in cats.

## Conclusions

The trauma that occurred to P3 during onychectomy and resulting chronic inflammation may have played a role in the development of osteosarcoma in this cat. Neoplasia associated with onychectomy has not previously been reported in the veterinary literature and might be considered a potential complication. In our opinion, it is imperative that veterinarians educate owners about the numerous and potentially life-threatening risk factors after onychectomy in cats.

**Acknowledgements** The author would like to thank Dr Carl Myers for his expertise in pathology, Dr Matthew Cannon for his expertise in radiology and Dr Nicole Martell-Moran for her assistance and feedback.

**Conflict of interest** The authors declared no potential conflicts of interest with respect to the research, authorship, and/or publication of this article.

**Funding** The authors received no financial support for the research, authorship, and/or publication of this article.

**Ethical approval** This study involved the use of client-owned animal(s) only, and followed internationally recognised high standards ('best practice') of individual veterinary clinical patient care. Ethical approval from a committee was not therefore needed.

**Informed consent** Informed consent (either verbal or written) was obtained from the owner or legal guardian of all animal(s) described in this study for the procedure(s) undertaken. No animals or humans are identifiable within this publication, and therefore additional Informed Consent for publication was not required.

## References

- Dimopoulou M, Kirpensteijn J, Moens H, et al. **Histologic prognosticators in feline osteosarcoma: a comparison with phenotypically similar canine osteosarcoma.** *Vet Surg* 2008; 37: 466–471.
- Heldmann E, Anderson MA and Wagner-Mann C. **Feline osteosarcoma: 145 cases (1990–1995).** *J Am Anim Hosp Assoc* 2000; 36: 518–521.
- Quigley PJ and Leedale AH. **Tumors involving bone in the domestic cat: a review of fifty-eight cases.** *Vet Pathol* 1983; 20: 670–686.
- Si-Kwang L, Dorfman HD and Patnaik AK. **Primary and secondary bone tumours in the cat.** *J Small Anim Pract* 1974; 15: 141–156.
- Bitetto WV, Patnaik AK, Schrader SC, et al. **Osteosarcoma in cats: 22 cases (1974–1984).** *J Am Vet Med Assoc* 1987; 190: 91–93.
- Turrel JM and Pool RR. **Primary bone tumors in the cat: a retrospective study of 15 cats and a literature review.** *Vet Radiol* 1982; 23: 152–166.
- Sonnenschein B, Dickomeit MJ and Bali MS. **Late-onset fracture-associated osteosarcoma in a cat.** *Vet Comp Orthop Traumatol* 2012; 25: 418–420.
- Fry PD and Jukes HF. **Fracture associated sarcoma in the cat.** *J Small Anim Pract* 1995; 36: 124–126.
- Bennett D, Campbell JR and Brown P. **Osteosarcoma associated with healed fractures.** *J Small Anim Pract* 1979; 20: 13–18.
- Baum JL, Skinner OT and Boston SE. **Fracture-associated osteosarcoma of the femur in a cat.** *Can Vet J* 2018; 59: 1096–1098.
- Wobeser BK, Kidney BA, Powers SJ, et al. **Diagnoses and clinical outcomes associated with surgically amputated feline digits submitted to multiple veterinary diagnostic laboratories.** *Vet Pathol* 2007; 44: 362–365.
- Baez JL, Michel KE, Sorenmo K, et al. **A prospective investigation of the prevalence and prognostic significance of weight loss and changes in body condition in feline cancer patients.** *J Feline Med Surg* 2007; 9: 411–417.
- American College of Veterinary Anesthesiologists. **Anesthesia case of the month.** *J Am Vet Med Assoc* 2000; 217: 1633–1635.
- Clark K, Bailey T, Rist P, et al. **Comparison of 3 methods of onychectomy.** *Can Vet J* 2014; 55: 255–262.
- Swiderski J. **Onychectomy and its alternatives in the feline patient.** *Clin Tech Small Anim Pract* 2002; 17: 158–161.
- Martell-Moran NK, Solano M and Townsend HGG. **Pain and adverse behavior in declawed cats.** *J Feline Med Surg* 2017; 20: 280–288.
- Ruch-Gallie R, Hellyer PW, Schoenfeld-Tacher R, et al. **Survey of practices and perceptions regarding feline onychectomy among private practitioners.** *J Am Vet Med Assoc* 2016; 249: 291–298.
- Groskopf BS, Dubielzig RR and Beaumont SL. **Orbital extraskelletal osteosarcoma following enucleation in a cat: a case report.** *Vet Ophthalmol* 2010; 13: 179–183.
- Woog J, Albert DM, Gonder JR, et al. **Osteosarcoma in a phthical feline eye.** *Vet Pathol* 1983; 20: 209–214.
- Stimson EL, Cook WT, Smith MM, et al. **Extraskelletal osteosarcoma in the duodenum of a cat.** *J Am Anim Hosp Assoc* 2000; 36: 332–336.
- Easton CB. **Extraskelletal osteosarcoma in a cat.** *J Am Anim Hosp Assoc* 1994; 30: 59–61.
- Almela R, Bomhard W, Anson A, et al. **Subcutaneous extraskelletal osteosarcoma in a metatarsal footpad in a cat.** *Vet Dermatol* 2017; 28: 524–e129.
- Spugnini EP, Ruslander D and Bartolazzi A. **Extraskelletal osteosarcoma in a cat.** *J Am Vet Med Assoc* 2001; 219: 60–62.
- Hendrick MJ and Brooks JJ. **Postvaccinal sarcomas in the cat: histology and immunohistochemistry.** *Vet Pathol* 1994; 31: 126–129.
- Kidney BA. **Role of inflammation/wound healing in feline oncogenesis: a commentary.** *J Feline Med Surg* 2008; 10: 107–109.
- Morrison WB and Starr RM and the Vaccine-Associated Feline Sarcoma Task Force. **Vaccine-associated feline sarcomas.** *J Am Vet Med Assoc* 2001; 218: 697–702.
- McNeil EA. **Vaccine-associated sarcomas in cats a unique cancer model.** *Clin Orthop Relat Res* 2001; 382: 21–27.
- Doddy FD, Glickman LT, Glickman NW, et al. **Feline fibrosarcomas at vaccination sites and non-vaccination sites.** *J Comp Pathol* 1996; 114: 165–174.

- 29 Daly MK, Saba CF, Crochik SS, et al. **Fibrosarcoma adjacent to the site of microchip implantation in a cat.** *J Feline Med Surg* 2008; 10: 202–205.
- 30 McLeland SM, Imhoff DJ, Thomas M, et al. **Subcutaneous fluid port-associated soft tissue sarcoma in a cat.** *J Feline Med Surg* 2013; 15: 917–920.
- 31 Martinez SA, Hauptman J and Walshaw R. **Comparing two techniques for onychectomy in cats and two adhesives for wound closure.** *Vet Med* 1993; 88: 520–525.
- 32 Wilson DV and Rascoe PJ. **Pain and analgesia following onychectomy in cats: a systematic review.** *Vet Anaesth Analg* 2016; 43: 5–17.
- 33 Mison MB, Bohart GH, Walshaw R, et al. **Use of carbon dioxide laser for onychectomy in cats.** *J Am Vet Med Assoc* 2002; 221: 651–653.
- 34 Gerard AF, Larson M, Baldwin CJ, et al. **Telephone survey to investigate relationships between onychectomy or onychectomy technique and house soiling in cats.** *J Am Vet Med Assoc* 2016; 249: 638–643.
- 35 Tobias KS. **Feline onychectomy at a teaching institution: a retrospective study of 163 cases.** *Vet Surg* 1994; 23: 274–280.
- 36 Cabon Q, Plante J and Gatineau M. **Digital flexor tendon contracture treated by tenectomy: different clinical presentations in three cats.** *JFMS Open Rep* 2015; 1. 10.1177/2055116915597237
- 37 Yeon SC, Flanders JA, Scarlett JM, et al. **Attitudes of owners regarding tendonectomy and onychectomy in cats.** *J Am Vet Med Assoc* 2001; 218: 43–47.
- 38 Cooper MA, Lavery PH and Soederer EE. **Bilateral flexor tendon contracture following onychectomy in 2 cats.** *Can Vet J* 2005; 46: 244–246.