



## **Traumatic fragmentation and concurrent infection of a palmar sesamoid in a cat**

Authors: Hernon, Tom, and Langley-Hobbs, Sorrel J

Source: Journal of Feline Medicine and Surgery Open Reports, 6(1)

Published By: SAGE Publishing

URL: <https://doi.org/10.1177/2055116920907417>

---

BioOne Complete ([complete.BioOne.org](https://complete.BioOne.org)) is a full-text database of 200 subscribed and open-access titles in the biological, ecological, and environmental sciences published by nonprofit societies, associations, museums, institutions, and presses.

Your use of this PDF, the BioOne Complete website, and all posted and associated content indicates your acceptance of BioOne's Terms of Use, available at [www.bioone.org/terms-of-use](https://www.bioone.org/terms-of-use).

Usage of BioOne Complete content is strictly limited to personal, educational, and non - commercial use. Commercial inquiries or rights and permissions requests should be directed to the individual publisher as copyright holder.

---

BioOne sees sustainable scholarly publishing as an inherently collaborative enterprise connecting authors, nonprofit publishers, academic institutions, research libraries, and research funders in the common goal of maximizing access to critical research.



# Traumatic fragmentation and concurrent infection of a palmar sesamoid in a cat

Tom Hernon and Sorrel J Langley-Hobbs

*Journal of Feline Medicine and Surgery Open Reports*  
1–4

© The Author(s) 2020

Article reuse guidelines:

sagepub.com/journals-permissions

DOI: 10.1177/2055116920907417

journals.sagepub.com/home/jfmsopenreports

This paper was handled and processed by the European Editorial Office (ISFM) for publication in *JFMS Open Reports*



## Abstract

**Case summary** A 9-year-old neutered male domestic shorthair cat was referred for assessment of a chronic non-weightbearing left forelimb lameness that had an acute onset following a suspected cat bite to the distal limb 4 weeks previously. There was minimal improvement following conservative management. On examination there was discomfort on palpation of the left palmar metacarpal region. An orthopaedic examination performed under sedation identified a moderate effusion of the left fourth metacarpophalangeal joint. A CT scan was performed, which identified fragmentation of the medial palmar sesamoid of the fourth digit (sesamoid V). Arthrocentesis of the fourth metacarpophalangeal joint identified septic inflammation. Surgical removal of the fragmented palmar sesamoid was performed and was submitted for histopathology and bacteriology analysis. Postoperative CT confirmed the removal of all fragments. *Pasteurella* species were isolated from the sesamoid fragments. Histopathology revealed osteomyelitis, neutrophilic inflammation and multifocal necrosis, with evidence of fibrosis present. The cat was re-examined 3 months postoperatively, at which point there was no evidence of lameness and orthopaedic examination of the limb was unremarkable.

**Relevance and novel information** To our knowledge, this is the first reported case of fragmentation of a palmar sesamoid in a cat. This case study describes the diagnosis and the successful management of a cat with fragmentation of a palmar sesamoid, following an altercation with another cat.

**Keywords:** Palmar sesamoid; trauma; orthopaedics; forelimb injury

**Accepted:** 6 January 2020

## Introduction

The sesamoid bones of the metacarpophalangeal joints, also known as the palmar sesamoids, are paired sesamoids located on the palmar aspect of the metacarpophalangeal joints.<sup>1</sup> Fragmentation of the palmar sesamoids has been reported in dogs. There is controversy around the pathogenesis of the condition; however, there appears to be two types that have been identified, a degenerative process termed sesamoid disease and a traumatic form, generally seen in racing greyhounds.<sup>2–5</sup> The presence of palmar sesamoid fragmentation may be a cause of lameness; however, it has been reported as an incidental finding in some dogs.<sup>6</sup>

This case study presents the diagnosis and management of a cat with fragmentation of a palmar sesamoid, following an altercation with another cat.

## Case description

A 9-year-old neutered male domestic shorthair cat was referred for assessment following a 4-week history of a left forelimb lameness, which occurred following a witnessed bite from another cat in the region of the left manus. Initial examination by the referring veterinary surgeon shortly after the incident identified a small

Langford Veterinary Services, Small Animal Hospital, University of Bristol, Langford, Bristol, UK

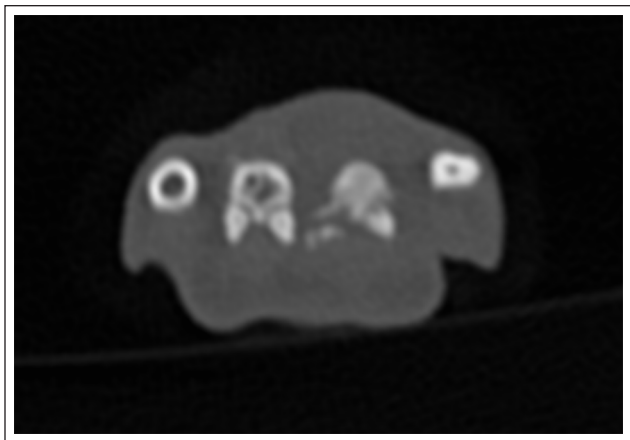
### Corresponding author:

Sorrel J Langley-Hobbs MA, BVetMed, DSAS(O), DECVS, FHEA, MRCVS, Langford Veterinary Services, Small Animal Hospital, University of Bristol, Langford House, Langford, Bristol BS40 5DU, UK  
Email: sj.langley-hobbs@bristol.ac.uk

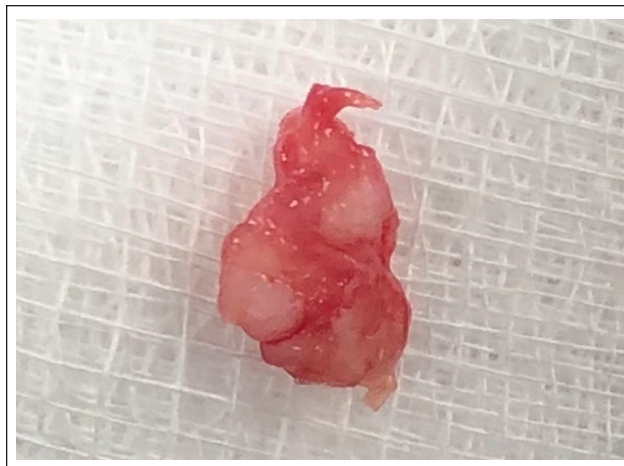

Creative Commons Non Commercial CC BY-NC: This article is distributed under the terms of the Creative Commons

Attribution-NonCommercial 4.0 License (<https://creativecommons.org/licenses/by-nc/4.0/>) which permits non-commercial use, reproduction and distribution of the work without further permission provided the original work is attributed as specified on the SAGE and Open Access pages (<https://us.sagepub.com/en-us/nam/open-access-at-sage>).



**Figure 1** CT image identifying fragmentation of the medial palmar sesamoid bone of the left fourth digit



**Figure 2** Photograph of the resected fragmented sesamoid

puncture wound on the palmar aspect of the distal metacarpal region. Radiographs were performed of the right and left manus; however, no abnormalities were identified. The lameness was initially managed with a 4-week course of meloxicam (0.05 mg/kg q24h PO) and a one-off injection of cefovecin (8 mg/kg SC), in conjunction with restricted exercise. There was minimal improvement noted over the 4 weeks prior to referral.

On presentation, the cat was bright, alert and responsive, with a severe, intermittently non-weightbearing, left forelimb lameness. A complete orthopaedic examination was not possible owing to the cat's temperament and discomfort.

An orthopaedic examination was performed once the cat was sedated with dexmedetomidine (5 µg/kg IV) and butorphanol (0.3 mg/kg IV), which identified a swelling of the distal aspect of the fourth metacarpal, which was painful on palpation, even under sedation. The remaining orthopaedic examination was unremarkable. Radiographs were taken of the left manus, which were largely unremarkable. A CT scan was performed of right and left distal forelimbs, which identified fragmentation of the medial palmar sesamoid bone of the left fourth digit (Figure 1). Arthrocentesis of the left fourth metacarpophalangeal joint was performed for cytological evaluation, which identified septic inflammation with intracellular cocci.

Owing to the lack of response to conservative management, surgical removal of the fragmented sesamoid was recommended. The cat was premedicated with dexmedetomidine (3 µg/kg IV) and methadone (0.2 mg/kg IV), and anaesthesia was induced using propofol (2 mg/kg IV) and was maintained with isoflurane in oxygen via an endotracheal tube. A carpal ring block was performed prior to surgery, using bupivacaine (1 mg/kg). A tourniquet was placed prior to surgery. A palmar approach to the

palmar sesamoids of the fourth digit was performed as described by Johnson.<sup>7</sup> A sesamoidectomy was performed, which removed the fragmented sesamoid in its entirety (Figure 2) and the fragments were submitted for culture and histopathology. The metacarpophalangeal joint was identified and flushed with sterile saline. The fascial and subcutaneous tissues were opposed by simple continuous patterns using 1.5 metric poliglecaprone 25 (Monocryl; Ethicon). The skin was apposed using simple interrupted sutures using 1.5 metric nylon (Monosof; Covidien). A postoperative CT scan was performed, which confirmed the removal of all of the sesamoid fragments. Postoperatively, a modified Robert Jones dressing was applied to the distal limb. The cat's recovery from anaesthesia was uneventful. Postoperatively, the cat received buprenorphine (0.02 mg/kg IV q6h for 24 h), meloxicam (0.05 mg/kg q24h PO) and cephalexin (75 mg q12h PO) while the culture results were pending. The cat was discharged 48 h postoperatively.

Culture of fragments isolated *Pasteurella* species, which was sensitive to amoxicillin/clavulanic acid. A 4-week course of amoxicillin/clavulanic acid (125 mg q12h PO) was dispensed. Histopathological assessment of the fragments identified osteomyelitis, neutrophilic inflammation and multifocal necrosis.

A follow-up assessment 3 months postoperatively identified no lameness and the cat was reported to have no clinical signs. Examination of the left distal limb identified slightly limited flexion of the fourth metacarpophalangeal joint; however, normal extension of the joint was present.

## Discussion

Fragmentation of the palmar sesamoid has been reported to be due to trauma, particularly in racing greyhounds,<sup>4,8</sup>

or as a degenerative disease that is reported in young large-breed dogs, termed sesamoid disease.<sup>2,9</sup> However, to our knowledge there are no documented cases of fragmentation of the palmar sesamoid in cats.

The clinical signs observed in this case are consistent with those reported in dogs with fragmentation of the palmar sesamoids, including an acute lameness, effusion of the metacarpophalangeal joint and pain on manipulation of the manus.<sup>6</sup> In previous studies the diagnosis was based on plain radiography alone.<sup>2,5,9</sup> In this case, radiography was performed prior to referral; however, it failed to identify pathology to the palmar sesamoid and CT was required to confirm the diagnosis. The benefit of CT is that it provides cross-sectional imaging, which facilitates identification of pathology and can aid with surgical planning.<sup>10</sup> To our knowledge, there are no reports documenting the use of CT for assessing this condition in cats or dogs.

There is a reported difference between sesamoid fractures caused by trauma or in cases with sesamoid disease. Traumatic fractures in greyhounds are commonly single transverse fractures, whereas in cases of sesamoid disease, the palmar sesamoid is found in multiple fragments.<sup>2,9</sup> In this case, the palmar sesamoid was found to be in multiple fragments, which is more consistent with sesamoid disease. Taking into account the witnessed trauma, plus the presence of *Pasturella* species, the most common bacteria isolate from cat bites,<sup>11</sup> a degenerative disease was considered unlikely and the cause was presumed to be traumatic.

Arthrocentesis of the metacarpophalangeal joint identified a neutrophilic inflammation with evidence of intracellular bacteria, confirming the presence of septic arthritis, which was in contrast to assessment of synovial fluid assessment in dogs with fragmentation of proximal sesamoid, which has a more mononuclear population consistent with chronic inflammation.<sup>6</sup> This was likely due to the penetrative nature of a cat bite leading to the introduction of bacteria.

Conservative management is the recommendation in dogs, prior to surgical intervention, as lameness has been reported to resolve in 43% of cases; however, these cases were not known to have associated infections.<sup>3</sup> Prior to referral, this case underwent a 4-week period of conservative management, which failed to lead to a significant improvement in the lameness. The conservative management is likely to have failed owing to the concurrent septic arthritis of the metacarpophalangeal joint. A further period of conservative treatment, including a longer course of empirical antibiotics for the management of the septic arthritis, was considered. However, owing to the combination of the infection and fragmentation, there was a concern regarding potential sequestrum formation.

It was therefore deemed more appropriate to explore the area surgically, flush the joint and remove the sesamoid fragments. It is important to be aware that as this is the first documented case of a fragmented palmar sesamoid with concurrent infection in a cat, it is therefore unknown if a successful outcome would have been achieved with appropriate conservative management of the septic arthritis alone.

Histological evaluation of the removed sesamoid identified evidence of osteomyelitis, which has also been documented in humans following penetration into the bone from a cat bite.<sup>12,13</sup> Chronic osteomyelitis can lead to the formation of a sequestrum, a non-healing piece of avascular bone surrounded by necrosis.<sup>14</sup> In small animals the presence of a sequestrum is generally described in relation to complications following surgical stabilisation of a fracture; however, it has been documented in dogs following traumatic injury that did not undergo surgery.<sup>15-17</sup> In the current case, the combination of small bone fragments, osteomyelitis and bacterial infection may have predisposed this cat to the development of a sequestrum if surgical intervention was not pursued.

This case of a fragmented palmar sesamoid following a traumatic incident was successfully managed with complete sesamoidectomy, which led to complete resolution of lameness.

## Conclusions

This report documents a case of traumatic fragmentation of the medial palmar sesamoid bone of the fourth digit on the left forelimb, which was successfully managed with a combination of surgical resection of the affected sesamoid, flushing of the metacarpophalangeal joint and medical management for septic arthritis, leading to complete resolution of the lameness.

**Conflict of interest** The authors declared no potential conflicts of interest with respect to the research, authorship, and/or publication of this article.

**Funding** The authors received no financial support for the research, authorship, and/or publication of this article.

**Ethical approval** This study involved the use of non-experimental animal(s) only, and followed internationally recognised high standards ('best practice') of individual veterinary clinical patient care. Ethical approval from a committee was therefore not necessarily required.

**Informed consent** Informed consent (either verbal or written) was obtained from the owner or legal custodian of all animal(s) described in this work for the procedure(s) undertaken. For any animals or humans individually identifiable within this publication, informed consent (either verbal or

written) for their use in the publication was obtained from the people involved.

**ORCID iDs** Tom Hernon  <https://orcid.org/0000-0001-7662-8601>

Sorrel J Langley-Hobbs  <https://orcid.org/0000-0003-4397-5150>

## References

- 1 Langley-Hobbs SJ, Katja V and Montavon P. **Metacarpus, metatarsus and phalanges**. In: Montavon P, Katja V and Langley-Hobbs SJ (eds). *Feline orthopedic surgery and musculoskeletal disease*. St Louis, MO: Elsevier, 2009, pp 397–406.
- 2 Vaughan LC and France C. **Abnormalities of the volar and plantar sesamoid bones in Rottweilers**. *J Small Anim Pract* 1986; 27: 551–558.
- 3 Mathews KG, Koblik PD, Whitehair JG, et al. **Fragmented palmar metacarpophalangeal sesamoids in dogs: a long-term evaluation**. *Vet Comp Orthop Traumatol* 2001; 14: 7–14.
- 4 Prole JH. **A survey of racing injuries in the Greyhound**. *J Small Anim Pract* 1976; 17: 207–218.
- 5 Davis PE, Bellenger CR and Turner DM. **Fractures of the sesamoid bones in the greyhound**. *Aust Vet J* 1969; 45: 15–19.
- 6 Cake MA and Read RA. **Canine and human sesamoid disease**. *Vet Comp Orthop Traumatol* 1995; 8: 70–75.
- 7 Johnson KA. **Piermattei's atlas of surgical approaches to the bones and joints of the dog and cat**. 5th ed. St Louis, MO: Elsevier, 2014, pp 304–307.
- 8 Gannon JR. **Stress fractures in the greyhound**. *Aust Vet J* 1972; 48: 244–250.
- 9 Bennett D and Kelly DF. **Sesamoid disease as a cause of lameness in young dogs**. *J Small Anim Pract* 1985; 26: 567–579.
- 10 Ober CP and Freeman LE. **Computed tomographic, magnetic resonance imaging, and cross-sectional anatomic features of the manus in cadavers of dogs without forelimb disease**. *Am J Vet Res* 2009; 70: 1450–1458.
- 11 Abrahamian FM and Goldstein EJC. **Microbiology of animal bite wound infections**. *Clin Microbiol Rev* 2011; 24: 231–246.
- 12 Griego RD, Rosen T, Orengo IF, et al. **Dog, cat, and human bites: a review**. *J Am Acad Dermatol* 1995; 33: 1019–1029.
- 13 Pechter EA and Miller TA. **Severe osteomyelitis of the wrist following a cat bite**. *Hand* 1983; 15: 242–245.
- 14 Lew DP and Waldvogel FA. **Osteomyelitis**. *Lancet* 2004; 364: 369–379.
- 15 Seiler G, Rossi F, Vignoli M, et al. **Computed tomographic features of skull osteomyelitis in four young dogs**. *Vet Radiol Ultrasound* 2007; 48: 544–549.
- 16 De Smet AA, Dueland RT and Dubielzig RR. **Case report 775. Canine osteosarcoma with associated avascular necrosis and sequestrum formation**. *Skeletal Radiol* 1993; 22: 146–149.
- 17 Hayes G, Harris K and Langley-Hobbs S. **Post-traumatic septic bone sequestration in three dogs**. *VCOT Open* 2019; 2: e9–e15. DOI: 10.1055/s-0039-1692974.