



Development of alternating, ipsilateral Horner syndrome and Pourfour du Petit syndrome associated with oesophagostomy tube placement in a cat

Authors: Lee, Liu Yi, and Horikawa, Taemi

Source: Journal of Feline Medicine and Surgery Open Reports, 7(1)

Published By: SAGE Publishing

URL: <https://doi.org/10.1177/2055116920984379>

BioOne Complete (complete.BioOne.org) is a full-text database of 200 subscribed and open-access titles in the biological, ecological, and environmental sciences published by nonprofit societies, associations, museums, institutions, and presses.

Your use of this PDF, the BioOne Complete website, and all posted and associated content indicates your acceptance of BioOne's Terms of Use, available at www.bioone.org/terms-of-use.

Usage of BioOne Complete content is strictly limited to personal, educational, and non - commercial use. Commercial inquiries or rights and permissions requests should be directed to the individual publisher as copyright holder.

BioOne sees sustainable scholarly publishing as an inherently collaborative enterprise connecting authors, nonprofit publishers, academic institutions, research libraries, and research funders in the common goal of maximizing access to critical research.



Development of alternating, ipsilateral Horner syndrome and Pourfour du Petit syndrome associated with oesophagostomy tube placement in a cat

Journal of Feline Medicine and Surgery Open Reports
1–4

© The Author(s) 2021

Article reuse guidelines:

sagepub.com/journals-permissions

DOI: 10.1177/2055116920984379

journals.sagepub.com/home/jfmsopenreports

This paper was handled and processed by the European Editorial Office (ISFM) for publication in *JFMS Open Reports*



Liu Yi Lee¹ and Taemi Horikawa²

Abstract

Case summary A 12-year-old spayed female domestic shorthair cat was presented to a referral hospital for chronic intermittent hyporexia and weight loss. An abdominal ultrasound was performed, which revealed a mid-jejunal mass and mesenteric lymphadenomegaly. Surgical resection and placement of an oesophagostomy tube (O-tube) was performed. Upon recovery the cat exhibited signs of Horner syndrome, which resolved over the span of 2 weeks. Subsequently, the cat developed signs of unilateral Pourfour du Petit syndrome in the left eye at day 20 and unilateral Horner syndrome at day 25 ipsilateral to the O-tube insertion site. The O-tube was removed 32 days postoperatively, and Horner syndrome resolved 24h later. Follow-up examination 15 months later did not show any recurrence of ocular signs.

Relevance and novel information To our knowledge, this represents the first report of alternating ipsilateral Horner and Pourfour du Petit syndrome in a single patient that underwent placement of an O-tube. Neurological complications after O-tube placement are uncommon, with only a single previously published report of a cat developing Horner syndrome after O-tube placement. Veterinarians should consider potential ocular and neurological complications after O-tube placement and monitor for such signs postoperatively.

Keywords: Oesophagostomy tube; Horner syndrome; Pourfour du Petit syndrome; complications

Accepted: 4 December 2020

Case description

A spayed female 12-year-old domestic shorthair cat was presented to a referral hospital (Western Australian Veterinary Emergency and Specialty) for an 8-month history of intermittently reduced appetite and gradual weight loss. The patient did not have any ocular abnormalities prior to presentation. Abdominal ultrasonography revealed a mid-jejunal mass and mesenteric lymphadenomegaly. The patient subsequently underwent a coeliotomy where a jejunal resection and anastomosis were performed. An oesophagostomy tube (O-tube) was placed on the left side of the patient's neck for assisted feeding to ensure adequate caloric intake as the patient was hyporexic preoperatively.

During recovery the patient was placed in right lateral recumbency and the left cervical region was prepared for surgery. A 10F red rubber catheter was

measured to the level of the distal third of the oesophagus. Curved Rochester–Carmault forceps were inserted into the oral cavity and directed distally into the oesophagus equidistant between the thoracic inlet and the pharynx, and the tips of the forceps were used to deviate the oesophagus laterally. A sharp incision was made with a size 15 Bard–Parker scalpel blade between the tips of the forceps. The tube was grasped with the forceps and

¹Small Animal Specialist Hospital, Sydney, NSW, Australia

²Perth Animal Eye Hospital, Perth, WA, Australia

Corresponding author:

Liu Yi Lee BSc, DVM, Small Animal Specialist Hospital,
1/1 Richardson Place, North Ryde NSW 2113, Australia
Email: liuyi1805@gmail.com



Creative Commons Non Commercial CC BY-NC: This article is distributed under the terms of the Creative Commons

Attribution-NonCommercial 4.0 License (<https://creativecommons.org/licenses/by-nc/4.0/>) which permits non-commercial use, reproduction and distribution of the work without further permission provided the original work is attributed as specified on the SAGE and Open Access pages (<https://us.sagepub.com/en-us/nam/open-access-at-sage>).

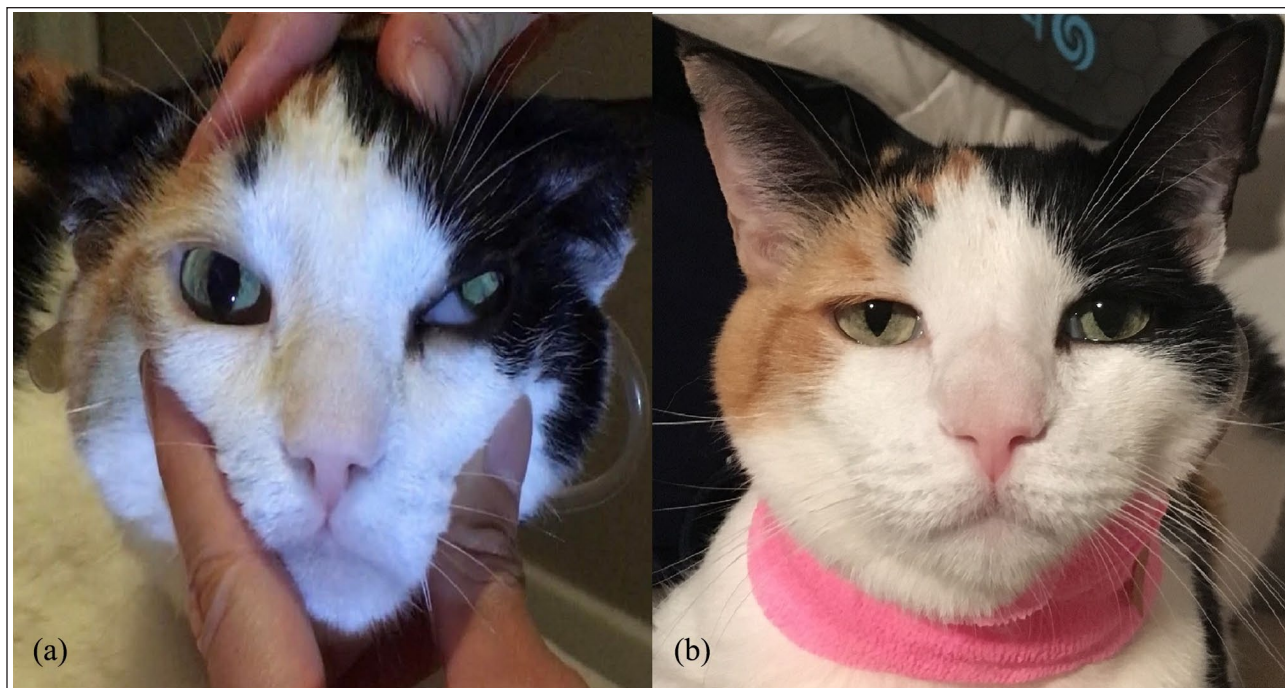

Figure 1 A 12-year-old domestic shorthair cat after placement of O-tube. (a) Cat at day 4 showing signs of Horner syndrome in the left eye (OS), including miosis, enophthalmos and protrusion of the third eyelid; (b) cat at day 20 exhibiting signs of Pourfour du Petit syndrome OS, including mydriasis and a widened palpebral fissure

pulled out orally, then redirected aborally into the oesophagus. The tube was sutured in place with a Chinese fingertrap suture using 3/0 polydioxanone. A soft padded bandage was applied around the neck to hold the tube in place.

Two hours after surgery the patient developed miosis and enophthalmos in the left eye (OS) consistent with Horner syndrome. Four days later a full ophthalmic examination confirmed ptosis, miosis, enophthalmos, prolapse of the nictitans membrane, narrowed left naris and decreased nasal airflow on the left side (Figure 1a, also see video in the supplementary material). One drop of phenylephrine 1% was applied topically OS for neurolocalisation; pupillary dilation and resolution of ptosis were observed 10 mins after application, identifying the lesion as post-ganglionic.¹ The rest of the ocular examination was unremarkable. Physical examination was unremarkable other than good healing of the abdominal incision and O-tube stoma. Histopathology of the resected jejunal mass identified small cell T-cell lymphoma, so the patient was started on prednisolone (2mg/kg PO q24h [Pred X-5 Apex]) and chlorambucil (4mg PO q24h for the first 4 days and then once every 3 weeks [Leukeran; Aspen Pharmacare]). A repeat ocular examination performed 2 weeks later revealed that the signs of Horner syndrome were starting to resolve.

On day 20 after the O-tube placement the patient developed signs clinically resembling Pourfour du Petit syndrome, including mydriasis and a widened palpebral

fissure OS (Figure 1b). The ipsilaterally narrowed naris and nasal congestion had resolved at that point. The patient remained clinically well and there were no other ocular abnormalities. Between days 25 and 26 the patient developed mild miosis OS consistent with Horner syndrome again. On day 32, the O-tube was removed as the stoma was inflamed and the patient was eating well on its own. Repeat examination on day 33 revealed complete resolution of mild miosis OS. Repeat examination 15 months later did not show any recurrence of ocular signs.

Discussion

This report discusses a cat that developed alternating ipsilateral Horner and Pourfour du Petit syndrome after placement of an O-tube. In this particular cat, it was hypothesised that the initial surgical trauma due to O-tube placement led to stretching of the vagosympathetic nerve trunk and subsequently neuropraxia, leading to Horner syndrome. During placement of an O-tube, the oesophagus is elevated laterally with forceps placed through the oral cavity into the oesophagus, and a skin incision is made into the oesophagus to pass the O-tube. The vagosympathetic trunk is located in close proximity to the oesophagus (Figure 2). It would be reasonable to assume that tension placed on oesophageal tissue would also cause tension on the vagosympathetic nerve, making secondary neurological complications from inserting an O-tube a potential, although uncommon, complication.

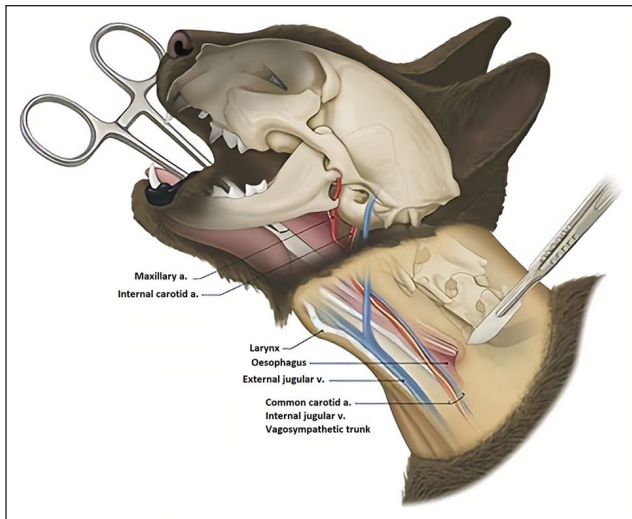


Figure 2 Anatomy of the major nerves in the cervical region of the cat, illustrating the close proximity of the vagosympathetic trunk and the oesophagus²

Horner syndrome is caused by a loss of sympathetic innervation to the ocular muscles. Signs include ptosis, miosis, enophthalmos and protrusion of the nictitating membrane. Idiopathic Horner syndrome is the most common, but other identifiable causes include trauma, otitis media and interna, brachial plexus root avulsion and neoplasia.³ The prognosis for recovery from idiopathic Horner syndrome is excellent, with resolution of signs starting to occur in 4 weeks.⁴ This patient also developed reduced nasal airflow, a complication of Horner syndrome that has not been well documented in the veterinary literature but has been recognised in people.⁵ Decreased nasal airflow in Horner syndrome results from venous engorgement within the nasal mucosa because of reduced sympathetic tone, leading to reduced nasal patency.^{4,5} It is possible that this occurs in veterinary patients, but the incidence is unknown as checking for nasal airflow does not typically form part of the normal ophthalmological examination.

Pourfour du Petit syndrome is caused by sympathetic hyperactivity; signs include mydriasis, exophthalmos and a widened palpebral fissure. There is a case report of three cats developing signs similar to Pourfour du Petit syndrome after undergoing saline irrigation of the middle ear.⁶ One of the cats in this case report also developed signs of Horner syndrome 4 days later. In people, Pourfour du Petit syndrome has been associated with blunt trauma, neoplasia, nerve blocks, central venous catheters and surgical positioning.

There is a single online report detailing the development of Horner syndrome as a complication of O-tube placement.² A review of complications associated with O-tubes in 248 cats found that the most common complications were infection of the stoma site, self-removal by the patient or dislodgement.⁷ The subsequent swelling

and inflammation sustained by the vagosympathetic trunk and surrounding tissue secondary to the tension placed on the tissues during O-tube placement could have led to irritation of the nerve fibres, causing sympathetic hypersensitivity and ipsilateral Pourfour du Petit syndrome. The complete resolution of ocular abnormalities 24 h after O-tube removal further supports the likelihood that the ocular abnormalities were related to O-tube placement.

There are a few possibilities as to why this cat sustained a postganglionic lesion rather than a preganglionic one, as would have been expected if the Horner syndrome was due to neuropraxia of the vagosympathetic trunk, which is a second-order neuron. One possible explanation is that the presence of the tube itself could have caused some generalised swelling around the pharyngeal area, hence causing a third-order lesion. It is also possible that vascular injury associated with O-tube placement could have affected the cranial cervical ganglion and hence caused a postganglionic lesion rather than a preganglionic one. This effect has been documented in horses, where intravenous administration of medication into the external jugular vein causes inadvertent haemorrhage within the adjacent carotid sheath, leading to denervation of skin from the nose to the cranial portion of the neck.⁸ Neurolocalisation of Horner syndrome with 1% phenylephrine is commonly used, but this test has also not been studied in cats; the sensitivity of the test in detecting third-order lesions is unclear in cats at this stage.⁸

Conclusions

This report documents an unusual occurrence where both Horner and Pourfour du Petit syndrome occurred ipsilaterally in the same cat following O-tube placement with spontaneous resolution of all ocular signs after removal of the feeding tube 5 weeks later. The cause for this is suspected to be due to neuropraxia sustained during placement of the O-tube. This report highlights potential neurological complications secondary to O-tube placement, which should be monitored for in the post-operative period.

Acknowledgements The authors would like to express their gratitude to Dr Mark Billson, Dr Joanna White, Dr Jeanie Lau and Dr Georgina Child for their expert help and editorial assistance.



Conflict of interest The author(s) declared no potential conflicts of interest with respect to the research, authorship, and/or publication of this article.

Funding The author(s) received no financial support for the research, authorship, and/or publication of this article.

Ethical approval This work involved the use of non-experimental animals only (including owned or unowned animals and data from prospective or retrospective studies). Established

internationally recognised high standards ('best practice') of individual veterinary clinical patient care were followed. Ethical approval from a committee was therefore not specifically required for publication in *JFMS Open Reports*.

Informed consent Informed consent (either verbal or written) was obtained from the owner or legal custodian of all animal(s) described in this work (either experimental or non-experimental animals) for the procedure(s) undertaken (either prospective or retrospective studies). For any animals or humans individually identifiable within this publication, informed consent (either verbal or written) for their use in the publication was obtained from the people involved.

ORCID iDs Liu Yi Lee  <https://orcid.org/0000-0001-7604-4497>
Taemi Horikawa  <https://orcid.org/0000-0002-7388-0999>

Supplementary material

The following file is available online: Video 1: Cat with Horner syndrome demonstrating reduced nasal airflow ipsilaterally.

References

- 1 Simpson K, Williams D and Cherubini G. **Neuropharmacological lesion localization in idiopathic Horner's syndrome in Golden Retrievers and dogs of other breeds.** *Vet Ophthalmol* 2015; 18: 1–5.
- 2 Glass E, Warren JD, Song R, et al. **Clinical exposures: Horner syndrome an esophagostomy tube placement complication.** <https://www.dvm360.com/view/clinical-exposures-horner-syndrome-esophagostomy-tube-placement-complication> (2019, accessed May 21, 2020).
- 3 Kern TJ, Aromando MC and Erb HN. **Horner's syndrome in dogs and cats: 100 cases (1975–1985).** *J Am Vet Med Assoc* 1989; 195: 369–373.
- 4 Zwueste DM and Grahn BH. **A review of Horner's syndrome in small animals.** *Can Vet J* 2019; 60: 81–88.
- 5 Shaari CM and Scherl MP. **Nasal obstruction and Horner's syndrome.** *Otolaryngol Neck Surg* 1994; 111: 838–840.
- 6 Boydell P. **Iatrogenic pupillary dilation resembling Pourfour du Petit syndrome in three cats.** *J Small Anim Pract* 2000; 41: 202–203.
- 7 Breheny CR, Boag A, Le Gal A, et al. **Esophageal feeding tube placement and the associated complications in 248 cats.** *J Vet Intern Med* 2019; 33: 1306–1314.
- 8 de Lahunta A and Glass E. **Lower motor neuron: general visceral efferent system.** In: de Lahunta A, Glass E and Kent M (eds). *Veterinary neuroanatomy and clinical neurology*. St Louis, MO: Saunders, 2009, pp 173–180.