



Successful resolution of urothorax secondary to non-traumatic uroabdomen in a cat managed with peritoneal dialysis as a bridge to surgery

Authors: Donati, Pablo, Londoño, Leonel A, Fravega, Rodrigo, and Guevara, Juan M

Source: Journal of Feline Medicine and Surgery Open Reports, 7(1)

Published By: SAGE Publishing

URL: <https://doi.org/10.1177/2055116920984748>

BioOne Complete (complete.BioOne.org) is a full-text database of 200 subscribed and open-access titles in the biological, ecological, and environmental sciences published by nonprofit societies, associations, museums, institutions, and presses.

Your use of this PDF, the BioOne Complete website, and all posted and associated content indicates your acceptance of BioOne's Terms of Use, available at www.bioone.org/terms-of-use.

Usage of BioOne Complete content is strictly limited to personal, educational, and non - commercial use. Commercial inquiries or rights and permissions requests should be directed to the individual publisher as copyright holder.

BioOne sees sustainable scholarly publishing as an inherently collaborative enterprise connecting authors, nonprofit publishers, academic institutions, research libraries, and research funders in the common goal of maximizing access to critical research.



Successful resolution of urothorax secondary to non-traumatic uroabdomen in a cat managed with peritoneal dialysis as a bridge to surgery

Journal of Feline Medicine and Surgery Open Reports
1–7

© The Author(s) 2021

Article reuse guidelines:

sagepub.com/journals-permissions

DOI: 10.1177/2055116920984748

journals.sagepub.com/home/jfmsopenreports

This paper was handled and processed by the American Editorial Office (AAFP) for publication in *JFMS Open Reports*



Pablo Donati¹ , Leonel A Londoño² , Rodrigo Fravega³ and Juan M Guevara¹

Abstract

Case summary A 9-year-old neutered male domestic shorthair cat was presented for evaluation of severe hemodynamic collapse and suspected lower urinary tract disease. On admission, severe metabolic acidosis, hyperkalemia and azotemia, and electrocardiographic findings consistent with cardiotoxicity were identified. The diagnosis of uroabdomen was made based on abdominal fluid to plasma concentration ratios of creatinine and potassium. A central line catheter was placed percutaneously into the abdomen for peritoneal drainage and used for peritoneal dialysis as a bridge to surgery. Retrograde contrast cystography confirmed rupture of the urinary bladder. Point-of-care ultrasound of the chest postoperatively revealed the presence of mild pleural effusion. Echocardiography was then performed showing no evidence of cardiac disease. Pleural fluid analysis revealed a transudate with a creatinine ratio of 2.38 ($[\text{Creatinine}]_{\text{pleural fluid}}/[\text{Creatinine}]_{\text{plasma}}$), consistent with the diagnosis of urothorax. The cat recovered uneventfully from surgery and was monitored for signs of respiratory distress during the rest of its stay in hospital. The cat was discharged 4 days later and the pleural effusion resolved without further medical intervention.

Relevance and novel information There is limited information on the causes of urothorax and uroabdomen management of feline patients. Pleural effusion is a complication observed in critically ill cats secondary to fluid overload, underlying cardiomyopathy, primary thoracic pathology or a combination of these. To our knowledge, this is the first report of urothorax in a cat secondary to non-traumatic uroabdomen. Careful monitoring of respiratory signs consistent with pleural space disease is recommended in cases of uroabdomen.

Keywords: Uroabdomen; azotemia; peritoneal dialysis; pleural effusion; urothorax

Accepted: 9 December 2020

Introduction

Urothorax is a medical condition defined as the accumulation of urine in the pleural cavity. This condition is an exceedingly rare cause of pleural effusion in humans.^{1,2} The main etiologies associated with urothorax in people are obstructive uropathy and trauma.³ It can result from urine accumulation and extravasation from the abdominal cavity or retroperitoneal space. Lymphatic channels have been shown to drain particulate matter from the peritoneum to the pleural space, as well as lymphatic

¹Intensive Care Unit UCICOOP, CABA, Buenos Aires, Argentina

²Department of Small Animal Clinical Sciences, University of Florida, Gainesville, FL, USA

³Internal Medicine Service, Hospital Veterinario de Santiago, Santiago, Chile

Corresponding author:

Leonel A Londoño DVM, DACVECC, Department of Small Animal Clinical Sciences, University of Florida, 2015 SW 16th Avenue, PO Box 100126, Gainesville, FL 32610, USA

Email: londonol@ufl.edu



Creative Commons Non Commercial CC BY-NC: This article is distributed under the terms of the Creative Commons

Attribution-NonCommercial 4.0 License (<https://creativecommons.org/licenses/by-nc/4.0/>) which permits non-commercial use, reproduction and distribution of the work without further permission provided the original work is attributed as specified on the SAGE and Open Access pages (<https://us.sagepub.com/en-us/nam/open-access-at-sage>).

vessels connecting the diaphragm and lymph nodes in the region of the kidneys and pancreas.^{4,5} These connections have been proposed to explain pleural effusions in patients with pancreatitis and could also explain the development of urothorax.

Only three case reports of urothorax are documented in the veterinary literature, all three cases (two dogs and one cat) were secondary to traumatic uroabdomen, and only in one of the canine cases was the diaphragm not compromised.⁶⁻⁸ In the other two cases, there was a concurrent rupture of the bladder and diaphragm. In the case where the thoracic cavity was not compromised, the diagnosis of urothorax was made based on a creatinine ratio >2 ($[\text{Creatinine}]_{\text{pleural fluid}}/[\text{Creatinine}]_{\text{plasma}}$), and other causes of pleural effusion were ruled out. In people, the diagnosis of urothorax is based on the presence of pleural effusion associated with traumatic or obstructive uropathy that resolves with the treatment of the obstruction or surgical correction of the rupture. A creatinine ratio >1 is usually recommended to make the definitive diagnosis of urothorax.² To our knowledge, this is the first report of urothorax secondary to non-traumatic uroabdomen in a cat managed with peritoneal dialysis as a bridge to surgery.

Case description

A 9-year-old neutered male domestic shorthair cat presented to a tertiary referral hospital for further evaluation of acute hemodynamic decompensation. The cat originally presented to the primary veterinarian with signs of weakness and suspected signs of lower urinary tract disease, but the caretaker of the cat was unable to give more details on the history as he was only looking after the cat for a few days. The caretaker reported no history of trauma and the cat was indoors only. Initial evaluation by the primary veterinarian showed severe cardiovascular collapse and the cat was immediately referred with no diagnostics or treatments performed.

On presentation to the critical care service, the cat was obtunded, had a prolonged capillary refill time, bradycardia of 70 beats/min, hypothermia of 35°C (95°F) and weak femoral pulses. Blood pressure readings were too low to detect via Doppler (Ultrasonic Doppler; Parks Medical Electronics). Initial resuscitation included a 10ml/kg intravenous (IV) bolus of lactated Ringer's solution (Solución Ringer Lactato; B Braun) followed by a fluid rate of 29ml/h in an attempt to replace an estimated 7% dehydration, provide maintenance and replace ongoing losses. Further diagnostics included point-of-care ultrasound of the thorax and abdomen using an ultrasound machine with a microconvex probe (Sonoscape S6; Sono-Scape Medical). Results showed moderate volume of free abdominal fluid with fluid in all four sites: diaphragmaticohepatic, splenorenal, cystocolic and hepatorenal sites; no evidence of pleural/pericardial effusion or B-lines were identified in the thorax. ECG findings were consistent with atrial standstill with

idioventricular escape rhythms. A jugular venous sample was obtained for minimum database and blood gas analysis (Table 1). Based on the initial blood gas and electrolyte results consistent with severe metabolic acidosis and hyperkalemia, along with large volume of free abdominal fluid on focal ultrasound, the presumptive diagnosis of uroabdomen was made.

Additional treatments included 10% calcium gluconate (Gluconato de calcio; Laboratorios Biol) at 1 ml/kg IV over 30mins, with ECG monitoring and sodium bicarbonate (Maxfusor 542-H; Laboratorio Rivero) at 12.9mEq IV over 45mins based on 80% replacement of the bicarbonate dose calculation ($\text{body weight} \times 0.3 \times \text{base deficit}$).⁹ Abdominocentesis revealed a serosanguinous fluid, and fluid analysis was consistent with uroabdomen (Table 1): $[\text{Creatinine}]_{\text{abdominal-fluid}}/[\text{Creatinine}]_{\text{serum}} = 6.09$, and $[\text{K}^+]_{\text{abdominal-fluid}}/[\text{K}^+]_{\text{plasma}} = 2.28$. Cytological analysis of the fluid also revealed the presence of intracellular bacteria (cocci) and, owing to the concern of urosepsis, ceftazidime (Crima1000; FADA Pharma) at 25 mg/kg IV q8h was added to the treatments.

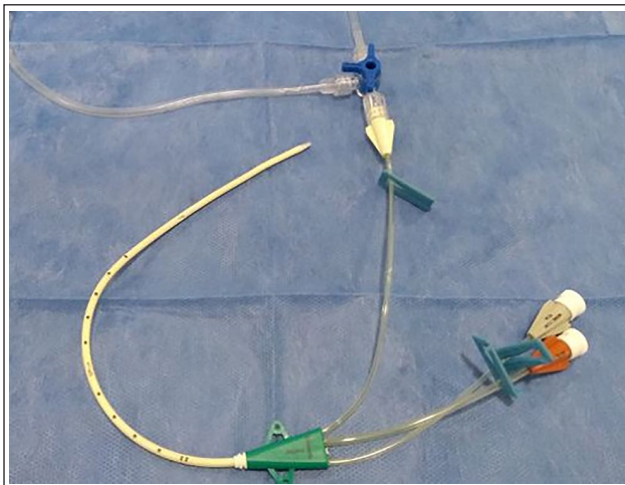
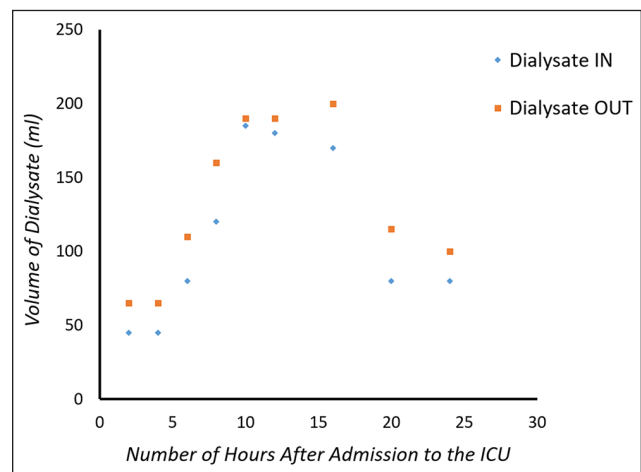
A 7F×13cm triple-lumen central venous line (Catéter multi-lumen: triple vía; Arrow) was placed percutaneously using a modified Seldinger technique, with prior application of a local block to the abdominal wall at the entry site, using 0.5ml lidocaine (Lidocaina 2%; Laboratorio Paul). The catheter was used for drainage of the urine from the abdomen initially, then as a form of peritoneal dialysis catheter (Figure 1). At the same time a urinary catheter (Argyle Tomcat Catheters; Penn Veterinary Supply) was placed and connected to a closed urine collection system for monitoring of the urinary output. There was a moderate degree of difficulty in passing the urinary catheter, raising the concern for urethral obstruction as the primary cause of the uroabdomen. IV administration of a 10ml/kg bolus of lactated Ringer's solution (Solución Ringer Lactato; B Braun) over 15mins was given with subsequent monitoring of arterial blood pressure, heart rate and capillary refill time, to assess cardiovascular response. After 2h and a total of five 10ml/kg boluses of crystalloid fluids, systolic blood pressure increased to 110mmHg, heart rate increased to 180 beats/min, capillary refill time decreased to <2 s and the ECG rhythm changed to a sinus rhythm. External heat support was provided and the cat's temperature returned to normal within the first 2h. Pain management was initiated with injectable tramadol at 3 mg/kg IV q8h (Tramadol 50mg/ml; Laboratorio Jhon Martin).

Once the cat appeared more hemodynamically stable, peritoneal dialysis was performed using the peritoneal drainage catheter. A peritoneal dialysis solution was created with 500 ml lactated Ringer's solution supplemented with 2.5% dextrose (Solución de Dextrosa al 50% en agua; Laboratorio Rivero) and 500 units of heparin (Heparina; Laboratorios Duncan). Initial dialysate volume of exchange was 10ml/kg with the solution infused over 15mins, dwell time of 1h and fluid

Table 1 Blood gas, electrolyte and renal values in a cat with non-traumatic uroabdomen and secondary urothorax

Time since admission (h)	0 (serum)	0 (abdominal fluid)	8	36	50	74	122	Reference interval
pH	7.10		7.31					7.25–7.40
pvCO ₂	47.6		45.7					33–51
pvO ₂	43		40					NA
SvO ₂	61.8		69.7					NA
HCO ₃ ⁻ (mmol/l)	12.5		20.9					25–30
BE _{ecf}	-13.4		-2.8					-5 to 2
Na ⁺ (mmol/l)	140		155					147–162
K ⁺ (mmol/l)	8.78	20.02	4.63					2.90–4.20
Ca ⁺⁺ (mmol/l)	0.79		1.14					1.20–1.32
Cl ⁻ (mmol/l)	91		110					112–119
Glucose (mmol/l)	18.48		13.15	6.77				3.33–7.22
Lactate (mmol/l)	6.8		4.8	3.3				<2.5
Creatinine (μmol/l)	510.07	3106.32		121.11	57.46	110.5	101.66	44.2–132.6
BUN (mmol/l)	74.15			20.32		11.41	19.61	8.91–21.39

pvCO₂ = venous partial pressure of carbon dioxide; PvO₂ = venous partial pressure of oxygen; SvO₂ = mixed venous oxygen saturation; BE_{ecf} = base excess in the extracellular fluid compartment. This is a more representative parameter that takes into account all of the body's buffer systems (including HCO₃⁻) and can influence the metabolic component of acid-base derangements; BUN = blood urea nitrogen; NA = not available

**Figure 1** Central venous catheter placed percutaneously into the abdomen and used as a peritoneal dialysis catheter in a cat with non-traumatic uroabdomen and urothorax**Figure 2** Scatter plot diagram displaying the difference in volumes of peritoneal dialysate solution infused (Dialysate IN) and dialysate solution retrieved (Dialysate OUT) at different time points during the first 24h of hospitalization in a cat with non-traumatic uroabdomen and secondary urothorax. ICU = intensive care unit

removal by gravity over 15 mins following dwell time. The treatment was repeated every 2h for the first 12h and the volume of dialysate infusion was increased from 10 ml/kg to 40 ml/kg over that time frame. After the fourth treatment (approximately 8h after admission to the hospital), blood gas analysis revealed improvement in electrolyte and pH values (Table 1). No complications were observed with the increased volume of dialysate infusion and the cat appeared brighter and more responsive. The volume of dialysate infused and volume of dialysate retrieved at each dialysis treatment point during the first 24h are presented

in Figure 2. No fluid retention from peritoneal dialysate infusion was identified, and in most cases the volume of dialysate retrieved was slightly higher than the volume infused, likely representing intra-abdominal urine accumulation.

Eighteen hours after admission to the hospital, a diagnostic abdominal ultrasound was performed showing evidence of large volume of gravity-dependent sediment in the urinary bladder and suspected rupture at the dorsal aspect of the urinary bladder. The cat spiked a fever while in hospital and clindamycin (Clindamicina; Veinfar) at 15 mg/kg IV q12h, was added to the antibiotic protocol.

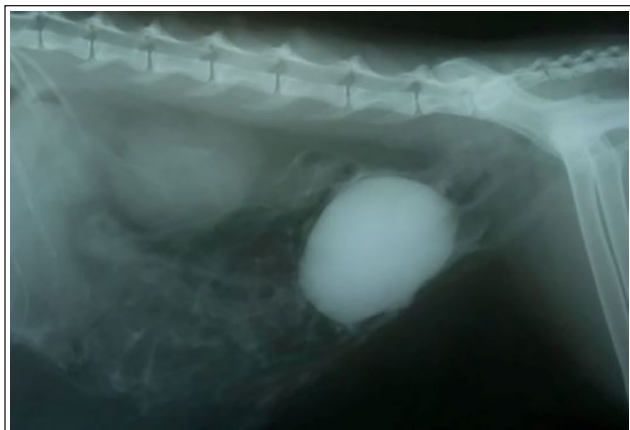


Figure 3 Retrograde contrast cystography in a cat with non-traumatic uroabdomen and secondary urothorax. Note the decreased serosal detail and leakage of contrast into the peritoneum

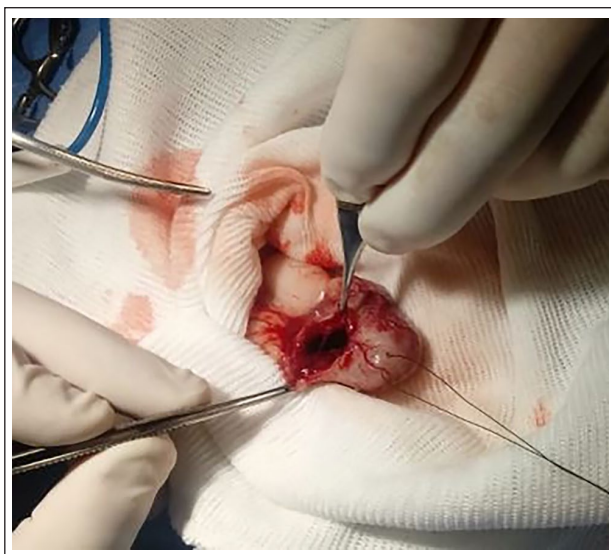

Figure 4 Intraoperative visualization of the site of rupture in the dorsal urinary bladder wall causing uroabdomen and secondary urothorax in a cat

The cat otherwise remained stable and recheck bloodwork 36h after admission showed significant improvement of azotemia, glucose and lactate (Table 1). The peritoneal drainage/dialysis catheter was removed, and retrograde contrast cystography was performed showing evidence of urinary bladder rupture (Figure 3). Immediately after the contrast study, the cat was placed under general anesthesia and an exploratory laparotomy was performed. The urinary rupture site was surgically corrected (Figure 4), and full-thickness urinary bladder biopsy samples were obtained for culture and sensitivity.

During recovery point-of-care ultrasound of the abdomen and chest were performed as a routine postoperative

screening procedure to establish a baseline for ongoing monitoring in the intensive care unit, and revealed an unexpected mild-to-moderate volume of bilateral pleural effusion. A complete echocardiogram was performed, which showed no evidence of cardiac disease or fluid overload. The total fluid balance was negative 240ml from the time of admission to the time of surgery (36h approximately). Despite the negative balance, the cat appeared clinically euhydrated and euvolemic prior to anesthesia and surgery. Thoracocentesis was then performed, and fluid analysis revealed a pure transudate (specific gravity: 1.022; total protein: 1.8g/dl; nucleated cell count: 800/ μ l). A paired blood sample was also obtained and a creatinine ratio ($[\text{Creatinine}]_{\text{pleural fluid}} / [\text{Creatinine}]_{\text{plasma}}$) was equal to 2.38, consistent with the diagnosis of urothorax.

The cat recovered uneventfully from surgery, no signs of respiratory distress were noted during the rest of hospitalization and the pleural effusion slowly resolved based on serial focal ultrasound assessments of the thorax. The culture and sensitivity results from the urinary bladder wall showed *Klebsiella pneumoniae* and *Mannheimia haemolytica* sensitive to ceftazidime, as well as *Micrococcus* species and *Staphylococcus* species (coagulase negative) sensitive to enrofloxacin. Based on these results, enrofloxacin at 5mg/kg IV q24h was added to the treatment protocol. The cat was discharged 4 days later and no further medical intervention was required. A week later, a new point-of-care ultrasound evaluation showed no abdominal or pleural fluid.

Discussion

This case report describes the presence of urothorax related to uroabdomen in a cat with a ruptured bladder in the absence of trauma or compromised diaphragmatic integrity. In a previous report, a case of urothorax in a cat was described to be due to trauma leading to kidney avulsion and a ruptured diaphragm.⁷ Two cases of urothorax have been described in dogs, both related to blunt trauma and only one where the diaphragm appeared intact.^{6,8}

In people, the main causes of urothorax are obstructive uropathy and trauma. A favorable clinical outcome in people with urothorax has been reported in 74/77 (96.1%) cases when the treatment was focused on the management of primary urinary pathology.² In the present report, the urothorax was identified after surgical resolution of the ruptured bladder and no specific therapy was instituted for the urothorax, which resolved spontaneously. Thoracocentesis was only performed for diagnostic purposes, as the cat in this report never developed clinical signs of respiratory distress secondary to the pleural effusion. In people, signs of dyspnea are reported in up to 92.8% of cases of urothorax.²

The pathophysiology of urothorax in patients without diaphragm defects, and in the absence of hydro-nephrosis as in the present case, is likely secondary to migration of urine from the abdomen into the pleural space through the pleural lymphatics.^{1,2,5} The presence of pleural effusion in dogs and people with pancreatitis, and in dogs with biliary peritonitis, has also been associated with lymphatic migration of abdominal fluid into the pleural space.^{10–13}

Owing to the high concentrations of potassium and creatinine in the peritoneal cavity of patients with uroabdomen, the ratios of effusion to serum concentrations of potassium and creatinine have been used to diagnose this condition.¹⁴ A study in dogs showed that an abdominal fluid creatinine concentration to peripheral blood creatinine concentration ratio >2 was predictive of uroabdomen with a 100% specificity and 86% sensitivity, and an abdominal fluid potassium concentration to peripheral blood potassium concentration >1.4 was also predictive of uroabdomen with 100% specificity and 100% sensitivity.¹⁵ In this report, the abdominal fluid to serum creatinine ratio and potassium ratio were 6.09 and 2.28, respectively. A creatinine ratio ($[\text{Creatinine}]_{\text{pleural fluid}} / [\text{Creatinine}]_{\text{plasma}} \geq 1$) has been previously used for the diagnosis of urothorax in people.² The cat in this report had a creatinine ratio (pleural fluid/plasma) of 2.38.

In a previous report of traumatic urothorax in a cat, the pleural fluid had a serosanguineous appearance with a specific gravity of 1.017 and total protein of 1.95 g/dl, with a rich population of inflammatory cells, almost exclusively degenerate neutrophils, and was classified as modified transudate.⁷ These findings are similar to the case reported here. The pleural fluid pH in people with urothorax is usually acidic (pH ≤ 7.30 in 60% of cases), which is explained by the presence of acidic urine.² However, in the same study, 24% of the cases had an alkalotic pleural fluid (pH ≥ 7.50). In this report, the pleural effusion was alkalotic with a pH of 7.5. We suspect that the presence of bacteriuria identified in the abdominal effusion could have increased the pH in the urine of this cat.

The severity of electrocardiographic changes that occur as a consequence of hyperkalemia appear to increase with increasing potassium levels.^{16–18} However, in cases of naturally occurring hyperkalemia in cats and dogs, a good correlation between the expected electrocardiographic changes and the level of hyperkalemia of the patient has not been found.¹⁸ These differences are mainly due to the effect in the threshold potential caused by the serum changes of ionized calcium.¹⁸ In a retrospective study of cats with urethral obstruction, 75% of the cases had ionized hypocalcemia.¹⁹ The effect of hypocalcemia on the myocardium increases the degree of cardiotoxicity induced by hyperkalemia, as the decrease in ionized calcium levels decreases the difference between the resting membrane potential and the

action potential.¹⁹ The cat in the present report presented to the intensive care unit with electrocardiographic changes suggestive of severe cardiotoxicity secondary to severe hyperkalemia ($[\text{K}^+] = 8.78 \text{ mmol/l}$). In this case, sodium bicarbonate was used in addition to peritoneal dialysis in order to decrease serum potassium levels. The use of sodium bicarbonate as a first-line drug to treat hyperkalemia has been considered controversial.¹⁴ Among the risks associated with the use of sodium bicarbonate is the potential to significantly decrease serum calcium levels,²⁰ which in turn could have further contributed to the risk of cardiotoxicity in this case. Owing to the lack of frequent electrolyte monitoring in this case, it is difficult to conclude whether the use of sodium bicarbonate contributed significantly to the reduction in serum potassium levels, or if the combination of treatments, including IV fluid therapy, sodium bicarbonate and peritoneal dialysis, led to the stabilization of this patient.

Owing to the limited history obtained in this case from the current caretaker of the patient, a definitive diagnosis of urethral obstruction causing the bladder rupture and uroabdomen cannot be made. The difficult catheterization of the urinary tract, along with biochemical changes of severe azotemia and hyperkalemia in a previously healthy male cat, could support this differential diagnosis. Nevertheless, azotemia and hyperkalemia are also common biochemical findings in cases of uroabdomen not associated with obstructive uropathies.^{14,15} However, other differentials such as neoplasia or a thromboembolic event cannot be ruled out, as histopathological analysis of the bladder wall was not performed in this case.

Bacterial infections are not commonly identified as the underlying cause of urethral obstruction in male cats.²¹ In this patient a total of four species were isolated from the urinary bladder wall, a very uncommon finding in a cat without underlying pathologies that would predispose it to the development of a polymicrobial urinary tract infection. This sample of the urinary bladder was obtained under a surgical sterile field and the probability of these isolated bacteria being contaminants at the time of collection is extremely low, unless contamination occurred in the laboratory setting during handling of the tissue. Of the four organisms, *Klebsiella* species is considered a common uropathogen, but there is a possibility that other pathogens such as *Micrococcus* species and *Staphylococcus* species are skin contaminants that could have been iatrogenically introduced in the urinary tract at the time of urethral catheterization, peritoneal dialysis catheter placement or peritoneal dialysate exchange. No reports describing colonization of the urinary tract with *M haemolytica* are available in the literature, raising the concern for contamination rather than true infection. In people, urosepsis has been reported as the underlying cause of spontaneous urinary bladder rupture.^{22,23} Based on these facts, the spontaneous rupture of the urinary bladder in

this cat could be secondary to infection and it should be part of the differentials when evaluating cases of spontaneous uroabdomen in small animals.

The clinical decision to use peritoneal dialysis as a bridge to surgery in the present case was based on the limited literature in veterinary peritoneal dialysis suggesting that reduction of azotemia, along with normalization of electrolyte and pH derangements prior to surgery, is beneficial before surgical intervention is pursued as it makes the patient a better anesthetic candidate and reduces the risk of anesthetic complications.^{14,24,25} In this specific case, the use of peritoneal dialysis, along with other supportive care treatments, reduced the serum creatinine concentrations from 510.07 $\mu\text{mol/l}$ to 121.11 $\mu\text{mol/l}$ prior to surgery. Owing to financial and logistic limitations in this case, more frequent evaluations of blood gas, electrolyte and renal values could not be performed. In the management of uroabdomen cases it is recommended to monitor renal, electrolyte and pH values every 2–4 h during the acute phase and until stabilization is achieved, in order to better guide treatment and assess the response to interventions.

In the present case, a central venous catheter was used as an abdominal drain for the urine accumulated in the abdomen, and as a peritoneal dialysis catheter. This technique has previously been reported as a way to provide renal replacement support, but the patency of these catheters may be of short duration.^{24,26} In this case, the catheter worked appropriately for 36 h, allowing rapid stabilization of pH, and concentrations of urea, creatinine and potassium prior to surgery. In human neonates, a similar technique has been reported in a case series where a 14G single-lumen central venous catheter, serving as a peritoneal dialysis catheter, was inserted by the Seldinger technique with minimal complications.²⁷ A comparison of costs indicated that the novel peritoneal dialysis system was less expensive than, and provided similar results to, conventional systems. No complications were observed with the use of a central line for peritoneal dialysis in this case and the cat recovered uneventfully from surgery.

The volume of dialysate drained each time peritoneal dialysis was performed was always higher than the volume of dialysate infused prior to dwelling time. We suspect that this was due to the osmotic effect generated by the dextrose added to the peritoneal dialysate solution increasing the osmotic pull of water from the intravascular space into the peritoneum, in addition to the extravasation of urine from the ruptured bladder. The negative fluid balance of 240 ml was significant, as it approximated the cat's blood volume. Several factors could have played a role in the negative fluid balanced based on ins and outs quantification. First, the time frame since rupture of the urinary bladder was unknown and the volume of urine accumulated in the abdomen could have

falsely increased the total outs of the patient. Second, if the cat had a urethral obstruction as the underlying cause of urinary bladder rupture, then postobstructive diuresis could have increased the volume of urine extravasation into the abdomen and increased the total volume of dialysate retrieved during the first day of hospitalization.

Despite this negative fluid balance and increased volume of dialysate retrieved compared with the volume of dialysate infused, the cat's macrovascular parameters of perfusion significantly improved after initial volume resuscitation and normalization of its electrolyte and creatinine values. Additionally, the cat started to drink water on the second day of hospitalization and this amount was not quantified; therefore, the total ins could have been higher bringing the total fluid balance towards a more neutral point. Finally, fluid therapy was based on cardiovascular response and reassessment of the patient, in order to prevent volume overload secondary to liberal fluid therapy.

Based on these findings and the positive outcome observed in this case, it appears that the short-term use of central venous catheters for abdominal drainage and performance of peritoneal dialysis may prove useful in small animals with acute uroabdomen.

Conclusions

This report is the first to describe the development and successful resolution of urothorax in a cat with non-traumatic uroabdomen. Urothorax is a potential complication of patients with uroabdomen and it should be included in the list of differentials for pleural effusion without any other apparent cause. Further investigation is needed to identify the incidence of urothorax secondary to non-traumatic and traumatic cases of uroabdomen in cats and other veterinary species.

Conflict of interest The authors declared no potential conflicts of interest with respect to the research, authorship, and/or publication of this article.


Funding The authors received no financial support for the research, authorship, and/or publication of this article.


Ethical approval This work involved the use of non-experimental animals only (including owned or unowned animals and data from prospective or retrospective studies). Established internationally recognized high standards ('best practice') of individual veterinary clinical patient care were followed. Ethical approval from a committee was therefore not necessarily required.

Informed consent Informed consent (either verbal or written) was obtained from the owner or legal custodian of all animal(s) described in this work (either experimental or non-experimental animals) for the procedure(s) undertaken (either prospective or retrospective studies). No animals or humans

are identifiable within this publication, and therefore additional informed consent for publication was not required.

ORCID iD Pablo Donati  <https://orcid.org/0000-0002-3618-6658>

Leonel A Londoño  <https://orcid.org/0000-0002-8023-926X>

Juan M Guevara  <https://orcid.org/0000-0003-4259-4065>

References

- 1 Austin A, Jogani SN, Brasher PB, et al. **The urinothorax: a comprehensive review with case series.** *Am J Med Sci* 2017; 354: 44–53.
- 2 Toubes ME, Lama A, Ferreiro L, et al. **Urinothorax: a systematic review.** *J Thorac Dis* 2017; 9: 1209–1218.
- 3 Ranjan V, Agrawal S, Chipde SS, et al. **Urinothorax: a path, less travelled: case report and review of literature.** *J Nat Sci Biol Med* 2015; 6: 213–216.
- 4 Courtice FC and Simmonds WJ. **Physiological significance of lymph drainage of the serous cavities and lungs.** *Physiol Rev* 1954; 34: 419–448.
- 5 Lemon W and Higgins G. **Lymphatic absorption of particulate matter through the normal and paralyzed diaphragm: an experimental study.** *Am J M Sci* 1929; 178: 536–547.
- 6 Tsompanidou PP, Anagnostou TL, Kazakos GM, et al. **Urothorax associated with uroperitoneum in a dog without diaphragmatic disruption.** *J Am Anim Hosp Assoc* 2015; 51: 256–259.
- 7 Störk CK, Hamaide AJ, Schwedes C, et al. **Hemithorax following diaphragmatic hernia and kidney prolapse in a cat.** *J Feline Med Surg* 2003; 5: 91–96.
- 8 Klainbart S, Merchav R and Ohad D. **Traumatic urothorax in a dog: a case report.** *J Small Anim Pract* 2011; 52: 544–546.
- 9 Hopper K. **Traditional acid–base analysis.** In: Silverstein DC and Hopper K (eds). *Small animal critical care medicine*. 2nd ed. St Louis, MO: Elsevier-Saunders, 2015, p 294.
- 10 Maringhini A, Ciambra M, Patti R, et al. **Ascites, pleural and pericardial effusions in acute pancreatitis: a retrospective study of incidence, natural history, and prognostic role.** *Dig Dis Sci* 1996; 41: 848–852.
- 11 Barnhart MD and Rasmussen LM. **Pleural effusion as a complication of extrahepatic biliary tract rupture in a dog.** *J Am Anim Hosp Assoc* 1996; 32: 409–412.
- 12 Guillaumin J, Chanoit G, Decosne-Junot C, et al. **Bilothorax following cholecystectomy in a dog.** *J Small Anim Pract* 2006; 47: 733–736.
- 13 Steyn PF and Wittum TE. **Radiographic, epidemiologic, and clinical aspects of simultaneous pleural and peritoneal effusions in dogs and cats: 48 cases (1982–1991).** *J Am Vet Med Assoc* 1993; 202: 307–312.
- 14 Stafford JR and Bartges JW. **A clinical review of pathophysiology, diagnosis, and treatment of uroabdomen in the dog and cat.** *J Vet Emerg Crit Care* 2013; 23: 216–229.
- 15 Schmiedt C, Tobias KM and Otto CM. **Evaluation of abdominal fluid: peripheral blood creatinine and potassium ratios for diagnosis of uroperitoneum in dogs.** *J Vet Emerg Crit Care* 2001; 11: 275–280.
- 16 Ettinger PO, Regan TJ and Oldewurtel HA. **Hyperkalemia, cardiac conduction, and the electrocardiogram: a review.** *Am Heart J* 1974; 88: 360–371.
- 17 Surawicz B. **Relationship between electrocardiogram and electrolytes.** *Am Heart J* 1967; 73: 814–834.
- 18 Tag TL and Day TK. **Electrocardiographic assessment of hyperkalemia in dogs and cats.** *J Vet Emerg Crit Care* 2008; 18: 61–67.
- 19 Drobatz KJ and Hughes D. **Concentration of ionized calcium in plasma from cats with urethral obstruction.** *J Am Vet Med Assoc* 1997; 211: 1392–1395.
- 20 DiBartola SP. **Metabolic acid–base disorders.** In: DiBartola SP (ed). *Fluid, electrolyte, and acid base disorders*. 3rd ed. St Louis, MO: Elsevier, 2006, pp 251–283.
- 21 Cooper ES, Lasley E, Daniels JB, et al. **Incidence of bacteriuria at presentation and resulting from urinary catheterization in feline urethral obstruction.** *J Vet Emerg Crit Care* 2019; 29: 472–477.
- 22 Lutwak N and Dill C. **Urosepsis complicated by a spontaneous bladder perforation.** *BMJ Case Rep* 2011; 2011. DOI: 10.1136/bcr0820114609.
- 23 Sawalmeh H, Al-Ozaibi L, Hussein A, et al. **Spontaneous rupture of the urinary bladder (SRUB): A case report and review of literature.** *Int J Surg Case Rep* 2015; 16: 116–118.
- 24 Bersenas AM. **A clinical review of peritoneal dialysis.** *J Vet Emerg Crit Care* 2011; 21: 605–617.
- 25 Dzyban LA, Labato MA, Ross LA, et al. **Peritoneal dialysis: a tool in veterinary critical care.** *J Vet Emerg Crit Care* 2000; 10: 91–102.
- 26 Ross LA and Labato MA. **Current techniques in peritoneal dialysis.** *J Vet Emerg Crit Care* 2013; 23: 230–240
- 27 Ao X, Zhong Y, Yu XH, et al. **Acute peritoneal dialysis system for neonates with acute kidney injury requiring renal replacement therapy: a case series.** *Perit Dial Int* 2018; 38 Suppl 2: S45–S52.