



Hepatosplenic T-cell lymphoma with hepatocytotropism in a cat

Authors: Ii, Tatsuhiro, Chambers, James K, Segawa, Kazuhito, and Uchida, Kazuyuki

Source: Journal of Feline Medicine and Surgery Open Reports, 7(1)

Published By: SAGE Publishing

URL: <https://doi.org/10.1177/20551169211005914>

BioOne Complete (complete.BioOne.org) is a full-text database of 200 subscribed and open-access titles in the biological, ecological, and environmental sciences published by nonprofit societies, associations, museums, institutions, and presses.

Your use of this PDF, the BioOne Complete website, and all posted and associated content indicates your acceptance of BioOne's Terms of Use, available at www.bioone.org/terms-of-use.

Usage of BioOne Complete content is strictly limited to personal, educational, and non-commercial use. Commercial inquiries or rights and permissions requests should be directed to the individual publisher as copyright holder.

BioOne sees sustainable scholarly publishing as an inherently collaborative enterprise connecting authors, nonprofit publishers, academic institutions, research libraries, and research funders in the common goal of maximizing access to critical research.



Hepatosplenic T-cell lymphoma with hepatocytotropism in a cat

Tatsuhito Ii¹, James K Chambers¹,
Kazuhito Segawa² and Kazuyuki Uchida¹

Journal of Feline Medicine and Surgery Open Reports
1–5

© The Author(s) 2021

Article reuse guidelines:

sagepub.com/journals-permissions

DOI: 10.1177/20551169211005914

journals.sagepub.com/home/jfmsopenreports

This paper was handled and processed by the European Editorial Office (ISFM) for publication in *JFMS Open Reports*



Abstract

Case summary A 14-year 3-month-old spayed female mixed-breed cat presented with jaundice, anaemia and thrombocytopenia. Haemophagocytic syndrome associated with lymphoma was suspected after cytological examination of the spleen. Despite treatment with prednisolone, L-asparaginase and nimustine, the cat died 176 days after the initial presentation. Necropsy revealed splenomegaly and hepatomegaly, without lymphadenopathy. Histopathologically, neoplastic lymphoid cells infiltrated the hepatic sinusoid and splenic sinus. The neoplastic lymphoid cells showed marked hepatocytotropism and contained erythrocytes, which was also confirmed by electron microscopy. Immunohistochemically, neoplastic lymphoid cells were positive for CD3, TIA1 (GMP-17) and granzyme B, and negative for CD8, CD20, CD56, CD57, CD79a and Iba1. Based on these findings, the cat was diagnosed with hepatosplenic T-cell lymphoma (HS-TCL) with hepatocytotropism.

Relevance and novel information This case shows cytotoxic immunophenotype of HS-TCL in a cat, which has not been demonstrated before. Severe hepatocytotropism and haemophagocytosis of the neoplastic cells were likely to be associated with jaundice and anaemia, respectively, and the poor outcome of the present case.

Keywords: Lymphoma; hepatocytotropism; erythrophagocytosis liver; spleen; granzyme B; TIA-1/GMP-17

Accepted: 8 March 2021

Introduction

Hepatosplenic T-cell lymphoma (HS-TCL) is an aggressive extranodal lymphoma, defined by hepatosplenic presentation without lymphadenopathy. In humans, neoplastic lymphoid cells have gamma delta ($\gamma\delta$) T-cell receptors, and show sinusoidal infiltration of the liver, spleen and bone marrow. Clinical features include marked thrombocytopenia and anaemia. Patients may respond initially to chemotherapy, but the disease often relapses with a median survival of <2 years.¹ HS-TCL has been well described in dogs; it has an aggressive clinical course and a cytotoxic immunophenotype.^{2–4} However, only a few cases of HS-TCL have been reported in the cat, which showed erythrophagocytosis and an indolent clinical course. Treatment was with chlorambucil and prednisolone; the cytotoxic immunophenotype was not examined.⁵ Here, we report the clinical and pathological findings of a feline case of

HS-TCL with hepatocytotropism, erythrophagocytosis and cytotoxic immunophenotype. Despite treatment with prednisolone, L-asparaginase and nimustine, the disease progressed and the cat died 176 days after initial presentation.

¹Laboratory of Veterinary Pathology, Graduate School of Agricultural and Life Sciences, University of Tokyo, Bunkyo-ku, Tokyo, Japan

²Sagamihara Animal Medical Centre, Sagamihara, Kanagawa, Japan

Corresponding author:

James K Chambers DVM, PhD, JCVP, Laboratory of Veterinary Pathology, Graduate School of Agricultural and Life Sciences, University of Tokyo, 1-1-1 Yayoi, Bunkyo-ku, Tokyo 113-8657, Japan

Email: achamber@g.ecc.u-tokyo.ac.jp



Creative Commons Non Commercial CC BY-NC: This article is distributed under the terms of the Creative Commons

Attribution-NonCommercial 4.0 License (<https://creativecommons.org/licenses/by-nc/4.0/>) which permits non-commercial use, reproduction and distribution of the work without further permission provided the original work is attributed as specified on the SAGE and Open Access pages (<https://us.sagepub.com/en-us/nam/open-access-at-sage>).

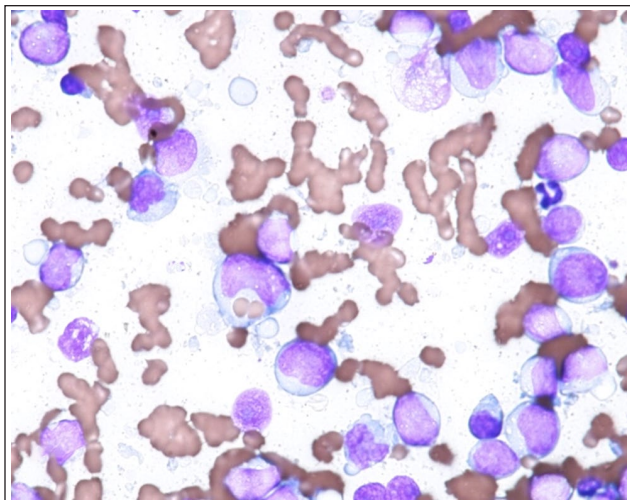


Figure 1 Spleen. Fine-needle aspiration cytology. Large lymphoid cells exhibit pleomorphism and occasionally contain erythrocytes in their cytoplasm. Wright–Giemsa staining

Case description

A 14-year 3-month-old spayed female mixed-breed cat exhibited jaundice and anorexia. Complete blood count revealed severe non-regenerative anaemia (haematocrit 18%, reference interval [RI] 30.3–52.3) and thrombocytopenia (47,000/ μ l; RI 151,000–600,000). Serum chemistry tests revealed an increased bilirubin (4.6 mg/dl; RI 0–0.9) and a mild elevation in alanine aminotransferase (171 U/l; RI 12–130) and alkaline phosphatase (253 IU/L; RI 14–111). On fine-needle aspiration of the spleen and liver, a large population of pleomorphic lymphocytes of intermediate size (10–15 μ m diameter) was found (Figure 1). Their nuclei were round or indented with a stippled or fine, evenly distributed chromatin. Nucleoli were multiple and of variable size. These cells occasionally contain erythrocytes; mitotic figures were rare. In addition, hepatocytes with green pigments, consistent with bile, were seen in the liver.

The cat was treated with prednisolone at a dose of 1.0 mg/kg/day and L-asparaginase at a dose of 400 U/kg at days 2, 15, 36 and 58 of treatment. After 15 days, the treatment induced clinical remission and improvement of the thrombocytopenia (298,000/ μ l) and bilirubin (0.6 mg/dl). Administration of prednisolone was continued and L-asparaginase was administered on days 15, 36 and 58 of follow-up. Seventy-three days after the initial treatment, the cat showed loss of appetite and thrombocytopenia (121,000/ μ l) and high bilirubin concentration (2.5 mg/dl). The cat was subsequently treated with an intravenous administration of nimustine at a dose of 20 mg/m²; administration of prednisolone was terminated gradually. The treatment induced clinical remission again until 114 days after initial treatment, and the cat was maintained with

nimustine and prednisolone. However, the cat died 176 days after initial treatment owing to loss of appetite, severe anaemia (haematocrit 12%) and liver dysfunction. A complete necropsy was performed on the day by a clinician at the animal hospital.

At necropsy, the cat presented with severe jaundice, and mild hepatomegaly and splenomegaly. No lymphadenopathy was confirmed at necropsy. On the cut surface, the spleen was reddish-brown, and the serosal surface was rough. The liver was also reddish-brown and bile ducts were enlarged and filled with greenish-brown bile. The liver and spleen were collected and fixed in 10% neutral-buffered formalin for histopathological examination.

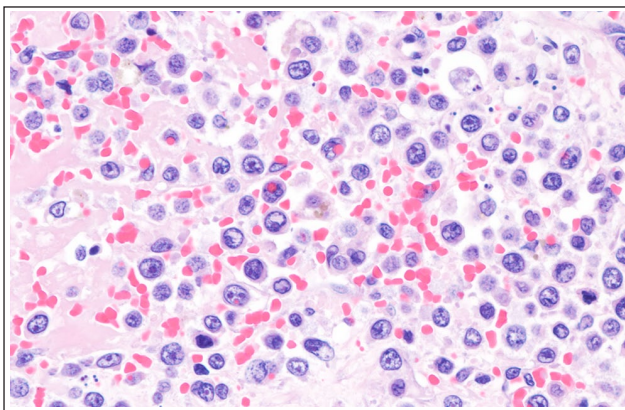
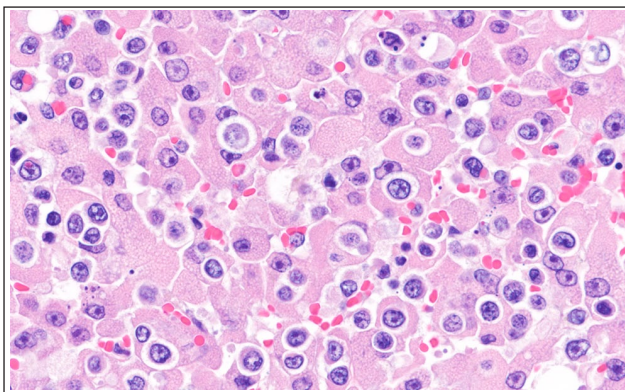
Formalin-fixed and paraffin-embedded tissues were sectioned at a thickness of 3 μ m and stained with haematoxylin and eosin. Serial sections were subjected to immunohistochemistry using the primary antibodies listed in Table 1. After a reaction with the primary antibodies, the sections were incubated with the Envision polymer (Dako), an optiview DAB detection kit (Roche Diagnostics) or biotinylated rabbit anti-rat IgG (Funakoshi) followed by peroxidase-conjugated streptavidin. Finally, the sections were visualised with diaminobenzidine tetrahydrochloride and counterstained with haematoxylin. The antibodies were validated by a positive reaction in feline lymph node and brain tissues, and negative reaction by omitting primary antibody. For electron microscopy, small pieces of formalin-fixed liver were re-fixed in 1% osmium tetroxide in 0.1 M phosphate buffer and then embedded in epoxy resin. Ultrathin sections were stained with uranyl acetate and lead citrate and examined using a transmission electron microscope (JEM-1400Plus; JEOL).

In the spleen, extensive necrosis and haemorrhage with infiltration of neoplastic lymphoid cells were observed (Figure 2). The neoplastic lymphoid cells diffusely infiltrated the hepatic sinusoids and hepatic cords in the liver (Figure 3). Neoplastic lymphoid cells were often observed in the cytoplasm of hepatocytes. Necrosis of affected hepatocytes and intracanalicular bile plugs were frequently observed. The neoplastic lymphoid cells were of variable size and had scarce cytoplasm. The size of the nuclei was 2–2.5 times the diameter of an erythrocyte, and had coarse chromatin, prominent nucleoli and an irregular nuclear membrane. Mitotic count was 4/10 high-power fields (2.37 mm² field of view); apoptotic bodies were frequently observed. Neoplastic lymphoid cells often contained erythrocytes in both the liver and spleen.

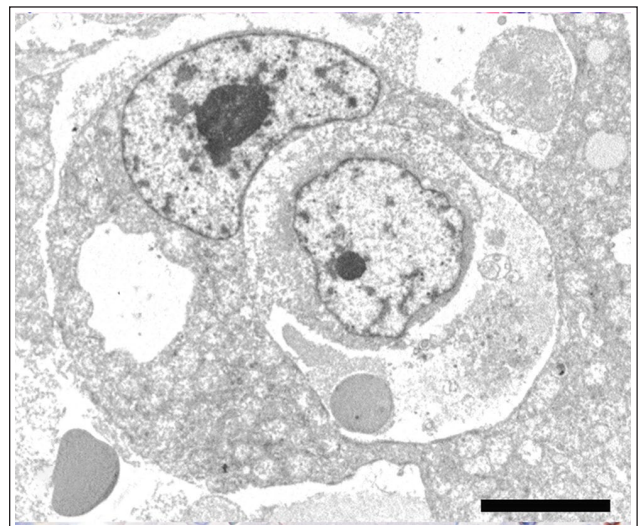
Ultra-structurally, the neoplastic cells were often located in the cytoplasm of degenerated hepatocytes and they often contained one or more erythrocytes (Figure 4). Immunohistochemically, the membrane of neoplastic

Table 1 Primary antibodies used for immunohistochemical analysis

	Host (clone)	Dilution	Antigen retrieval	Source
CD3	Rabbit	Ready to use	Heat, pH 6.0	Dako
CD8	Rat (F3-B2) ⁶	1:100	Heat, pH 9.0	Mizuno
CD20	Rabbit	1:150	Heat, pH 6.0	Thermo Fisher Scientific
CD30	Mouse (Bar-H2)	1:400	Heat, pH 9.0	Dako
CD56	Mouse (1G4)	1:150	Heat, pH 6.0	LSBio
CD57	Mouse (VC1.1)	1:500	Heat, pH 6.0	Sigma Aldrich
CD79a	Mouse (HM57)	1:50	Heat, pH 9.0	Dako
Granzyme B	Rabbit	1:100	Heat, pH 6.0	Abcam
Ki-67	Mouse (MIB1)	Ready to use	Heat, pH 6.0	Dako
TIA-1/GMP-17	Mouse (2G9A10F5)	1:50	Heat, pH 9.0	Beckman Coulter
Iba1	Rabbit	1:250	Heat, pH 6.0	Wako

**Figure 2** Spleen. Neoplastic lymphoid cells infiltrate red pulp. Haematoxylin and eosin staining**Figure 3** Liver. Hepatic cords are infiltrated by neoplastic lymphoid cells, and hepatocytes exhibited degeneration and necrosis. Haematoxylin and eosin staining

cells was strongly positive for CD3 (Figure 5). Granular positivity for granzyme B and T-cell intracellular antigen 1 (TIA-1/GMP-17) were observed in the cytoplasm of neoplastic lymphoid cells (Figures 6 and 7). Neoplastic lymphoid cells were negative for CD8, CD20, CD30,

**Figure 4** A neoplastic lymphoid cell in a hepatocyte containing an erythrocyte. Transmission electron microscopy. Scale bar = 10 μm

CD56, CD57, CD79a and Iba-1. The Ki-67 index of the neoplastic lymphoid cells was 50.2% in the liver and 56.8% in the spleen.

Discussion

The clinical manifestations of the present case, such as anaemia and thrombocytopenia, were comparable to that of humans and dogs with HS-TCL. Erythrophagocytosis has been reported in canine and feline cases of HS-TCL.^{3,6} Considering previous human and canine cases, there may have been infiltration of neoplastic lymphoid cells in the bone marrow associated with non-regenerative anaemia and thrombocytopenia in the present case. However, bone marrow was not examined. Erythrophagocytosis by neoplastic lymphoid cells may also have been associated with the non-regenerative anaemia and thrombocytopenia in the present case.

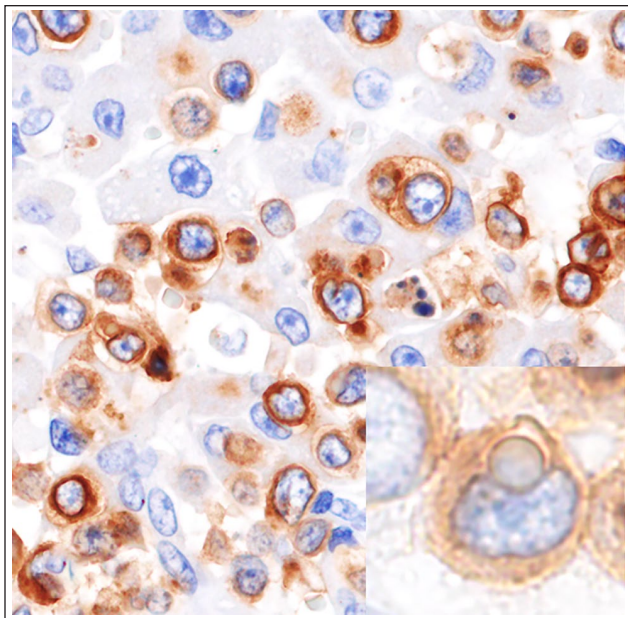
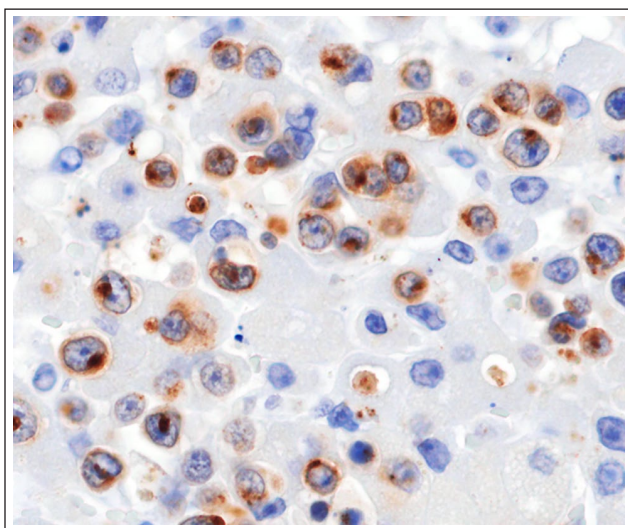
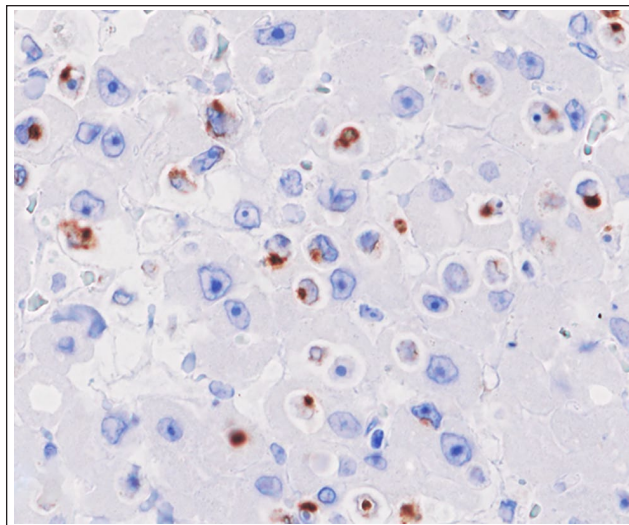


Figure 5 Liver. Neoplastic lymphoid cells in the cell membrane and cytoplasm are positive for CD3. Inset: a neoplastic lymphoid cell inside a hepatocyte is also positive



Figures 6 Liver. Neoplastic lymphoid cells in the cytoplasm are positive for granzyme B

HS-TCL is an aggressive extranodal lymphoma defined by a hepatosplenic presentation without lymphadenopathy. In humans, neoplastic lymphoid cells have $\gamma\delta$ T-cell receptors, and exhibit sinusoidal infiltration of the liver, spleen and bone marrow.¹ This definition also applies to dogs, but cats are not mentioned.² HS-TCL has been well described in dogs, exhibiting an aggressive clinical course and cytotoxic immunophenotype.⁵



Figures 7 Liver. Neoplastic lymphoid cells in the cytoplasm are positive for TIA-1/GMP-17

In the present case, the neoplastic lymphoid cells were located in the spleen and liver. The present case matched the definition of HS-TCL. This finding is also noted in canine hepatocytotropic T-cell lymphoma (HC-TCL), and the present case demonstrated distinct tropism for hepatic cords of neoplastic lymphoid cells.⁵ Immunophenotype of HS-TCL and HC-TCL cells are comparable, except for positivity of CD11d in HS-TCL. Immunohistochemistry for CD11d was performed using anticanine CD11d antibody,³ while the antibody did not cross-react with feline lymphocytes. Neoplastic lymphoid cells invaded into hepatocytes, which is called hepatocytotropism, and has been described in feline cases of lymphoma.⁷ Therefore, HC-TCL may be a subtype of HS-TCL. We diagnosed the present case as HS-TCL with hepatocytotropism. However, in the present case, only liver and spleen tissues were collected for histological evaluation at necropsy, because no significant gross changes were noticed in other organs.

Neoplastic lymphoid cells of HS-TCL originate from the $\gamma\delta$ T-cell population in humans and dogs.^{5,8} Experimental studies demonstrated the phagocytic and cytotoxic ability of a subset of $\gamma\delta$ T cells.^{9,10} Moreover, some lymphocytes can phagocytose blood cells.¹¹ In the present case, the neoplastic lymphoid cells expressed CD3, granzyme B and TIA-1/GMP-17, which indicates the neoplastic lymphoid cells were T cells with cytotoxicity. The neoplastic lymphoid cells were negative for CD8⁺ T cell (CD8), B cell (CD20 and CD79a), NK cell (CD56 and CD57) and histiocyte (Iba-1) markers. The immunophenotype of the neoplastic cells in the present case was consistent with that of $\gamma\delta$ T cells, although we were unable to perform immunohistochemistry against the $\gamma\delta$ T-cell receptor owing to the

lack of an antibody available for formalin-fixed, paraffin-embedded tissue. Neoplastic lymphoid cells in human HS-TCL cases are positive for TIA-1/GMP-17, which mediates cytotoxicity, and usually negative for granzyme B, which causes apoptosis of target cells. In canine cases of HS-TCL, neoplastic cells were commonly positive for granzyme B; however, TIA-1/GMP-17 expression was not examined. In a previous feline case of HS-TCL, the cytotoxic immunophenotype was not examined.

HS-TCL is considered an aggressive lymphoma in humans and dogs. However, a previous feline case of haemophagocytic HS-TCL showed an indolent clinical course with chlorambucil and prednisolone treatment, and the cat lived more than 2.5 years after initial presentation.⁶ In the present case, despite treatment with prednisolone, L-asparaginase and nimustine, the disease progressed and the cat died 176 days after initial presentation. The different clinical outcome in the present case may be attributed to hepatic injury by tumour invasion in the hepatic cords and/or cytotoxicity of the neoplastic cells.

Conclusions

The present report describes a unique case of feline HS-TCL with hepatocytotropism. The neoplastic lymphoid cells were of a cytotoxic phenotype and aggressively invaded into hepatic cords, which was associated with the poor outcome.

Acknowledgements The authors would like to thank Dr Kimura for his excellent technical assistance with the electron microscopy.

Conflict of interest The authors declared no potential conflicts of interest with respect to the research, authorship, and/or publication of this article.

Funding The authors received no financial support for the research, authorship, and/or publication of this article.

Ethical approval This work involved the use of non-experimental animals only (including owned or unowned animals and data from prospective or retrospective studies). Established internationally recognised high standards ('best practice') of individual veterinary clinical patient care were

followed. Ethical approval from a committee was therefore not specifically required for publication in *JFMS Open Reports*.

Informed consent Informed consent (either verbal or written) was obtained from the owner or legal custodian of all animal(s) described in this work (either experimental or non-experimental animals) for the procedure(s) undertaken (either prospective or retrospective studies). For any animals or humans individually identifiable within this publication, informed consent (either verbal or written) for their use in the publication was obtained from the people involved.

Reference

- 1 Swerdlow SH, Campo E, Harris NL, et al. WHO classification of tumours of haematopoietic and lymphoid tissues. 4th ed. Lyon: IARC Press, 2017.
- 2 Valli VE, Bienzle D and Meuten DJ. **Tumors of the hemolymphatic system.** In: Meuten DJ (ed). *Tumors in domestic animals*. 5th ed. Ames, IA: Wiley, 2017, pp 203–336
- 3 Keller SM, Vernau W, Hodges J, et al. **Hepatosplenic and hepatocytotropic T-cell lymphoma: two distinct types of T-cell lymphoma in dogs.** *Vet Pathol* 2013; 50: 281–290.
- 4 Cienava EA, Barnhart KF, Brown R, et al. **Morphologic, immunohistochemical, and molecular characterization of HS-TCL in a dog.** *Vet Clin Pathol* 2004; 33: 105–110.
- 5 Fry MM, Vernau W, Pesavento PA, et al. **Hepatosplenic lymphoma in a dog.** *Vet Pathol* 2003; 40: 556–562.
- 6 Carter JE, Tarigo JL, Vernau W, et al. **Erythrophagocytic low-grade extranodal T-cell lymphoma in a cat.** *Vet Clin Pathol* 2008; 37: 416–421.
- 7 Suzuki M, Kanae Y, Kagawa Y, et al. **Emperipolesis-like invasion of neoplastic lymphocytes into hepatocytes in feline T-cell lymphoma.** *J Comp Pathol* 2011; 144: 312–316.
- 8 Wu Y, Wu W, Wong WM, et al. **Human $\gamma\delta$ T cells: a lymphoid lineage cell capable of professional phagocytosis.** *J Immunol* 2009; 183: 5622–5629.
- 9 Chien YH, Meyer C and Bonneville M. **$\gamma\delta$ T cells: first line of defense and beyond.** *Annu Rev Immunol* 2014; 32: 121–155.
- 10 Holderness J, Hedges JF, Ramstead A, et al. **Comparative biology of $\gamma\delta$ T cell function in humans, mice, and domestic animals.** *Annu Rev Anim Biosci* 2013; 1: 99–124.
- 11 Hughes NR. **Erythrocyte phagocytosis by human lymphocytes.** *Nature* 1966; 212: 1575–1576.