



Surgical management of traumatic atlantoaxial subluxation in two cats

Authors: Gilbert, Emma, and Driver, Colin J

Source: Journal of Feline Medicine and Surgery Open Reports, 7(1)

Published By: SAGE Publishing

URL: <https://doi.org/10.1177/20551169211027070>

BioOne Complete (complete.BioOne.org) is a full-text database of 200 subscribed and open-access titles in the biological, ecological, and environmental sciences published by nonprofit societies, associations, museums, institutions, and presses.

Your use of this PDF, the BioOne Complete website, and all posted and associated content indicates your acceptance of BioOne's Terms of Use, available at www.bioone.org/terms-of-use.

Usage of BioOne Complete content is strictly limited to personal, educational, and non - commercial use. Commercial inquiries or rights and permissions requests should be directed to the individual publisher as copyright holder.

BioOne sees sustainable scholarly publishing as an inherently collaborative enterprise connecting authors, nonprofit publishers, academic institutions, research libraries, and research funders in the common goal of maximizing access to critical research.



Surgical management of traumatic atlantoaxial subluxation in two cats

Emma Gilbert and Colin J Driver

Journal of Feline Medicine and Surgery Open Reports
1–6

© The Author(s) 2021

Article reuse guidelines:

sagepub.com/journals-permissions

DOI: 10.1177/20551169211027070

journals.sagepub.com/home/jfmsopenreports

This paper was handled and processed by the European Editorial Office (ISFM) for publication in JFMS Open Reports



Abstract

Case series summary We describe here the surgical management of two pure breed cats with traumatic atlantoaxial subluxation. One cat was ambulatory tetraparetic on presentation and the second was tetraplegic, both with cervical spinal pain and acute onset of paresis with subsequent deterioration. MRI was performed in both cases, demonstrating spinal cord injury. Flexed lateral cervical radiographs were needed to confirm atlantoaxial subluxation in one case. CT was performed for surgical planning and surgical stabilisation was achieved with threaded pins and polymethyl methacrylate (PMMA) cement; odontoidectomy was required in one case. Both cats showed improvement postoperatively, with no complications or deterioration seen. Following surgery, one cat made a complete recovery; however, the second cat retained significant deficits.

Relevance and novel information We present the first report of surgically managed atlantoaxial subluxation of traumatic aetiology in cats, and report its occurrence in two novel breeds for this disease, Ragdoll and Persian. One case required odontoidectomy due to previous fracture and malunion of the odontoid process of the axis; both cases underwent surgical stabilisation of the atlantoaxial joint utilising multiple threaded pins and PMMA cement without transarticular implants – a technique that has not been previously reported in cats.

Keywords: Atlantoaxial subluxation; trauma; vertebral stabilisation; atlantoaxial instability

Accepted: 3 June 2021

Introduction

Atlantoaxial subluxation is an uncommon cause of tetraparesis, ataxia and cervical pain in cats. In dogs, it is most commonly recognised in toy breeds and associated with malformations of the odontoid process, the absence of ligaments of the atlantoaxial joint or trauma. Previous reports of feline atlantoaxial subluxation describe transarticular stabilisation^{1,2} and conservative management.³ We describe two traumatic presentations: a previous C2 fracture with malunion of the odontoid process, and atlantoaxial subluxation and acute-onset signs in a second case associated with body weight trauma. Both cases were treated surgically and demonstrated subsequent improvements in neurological status.

Case description

Case 1

A 1-year-old entire male Ragdoll cat was presented following a fall from a first-floor window 3 months prior to presentation. Immediately following this incident the cat

was non-ambulatory tetraparetic and painful on palpation of its neck. Radiographs were taken by the referring veterinarian, but no abnormalities were noted. The cat was treated with non-steroidal anti-inflammatory drugs (NSAIDs) and exercise restriction, and had shown neurological improvements, being independently ambulatory, but would still intermittently vocalise, suggesting recurrences of pain. In the week prior to referral, the cat deteriorated and showed a reluctance to move and pain on examination of the neck. This prompted referral.

On presentation the cat was ambulatory with mild generalised ataxia and tetraparesis. Hopping responses appeared delayed on both thoracic limbs. Segmental spinal reflexes were normal. There was marked neck

Lumbry Park Veterinary Specialists, Alton, UK

Corresponding author:

Emma Gilbert iBSc, BVetMed, MRCVS, Lumbry Park Veterinary Specialists, Selborne Road, Alton GU34 3HL, UK
Email: e.gilbert@live.com



Creative Commons Non Commercial CC BY-NC: This article is distributed under the terms of the Creative Commons

Attribution-NonCommercial 4.0 License (<https://creativecommons.org/licenses/by-nc/4.0/>) which permits non-commercial use, reproduction and distribution of the work without further permission provided the original work is attributed as specified on the SAGE and Open Access pages (<https://us.sagepub.com/en-us/nam/open-access-at-sage>).

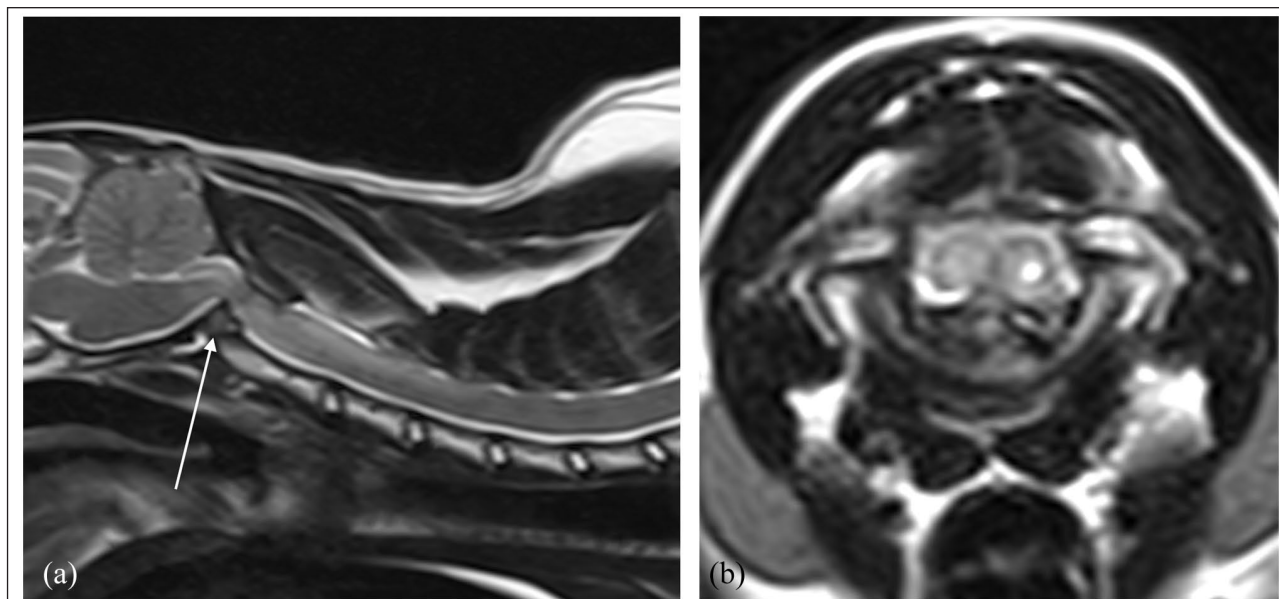


Figure 1 T2-weighted MRI of the cervical spine and caudal brain of case 1. (a) Sagittal and (b) transverse views showing compression of the spinal cord at the level of the atlantoaxial joint with the fractured odontoid process arrowed

pain on cervical ventroflexion. The problem was localised to a C1–T2 spinal cord segment disease; with the history of trauma, a differential diagnosis of vertebral fracture or luxation were considered most likely.

MRI of the cervicothoracic spine revealed marked spinal cord compression at C1–C2 associated with fracture and dorsal displacement of the odontoid process of the axis (Figure 1), which was positioned at 90 degrees vertical to its normal orientation with the vertebral body, suggesting malunion. The C1 vertebral body appeared to have a ventral mid-line defect and craniodorsal displacement of the pedicles and transverse processes, suggesting prior comminuted fracture of the body and pedicles. The C2 vertebra appeared to be displaced rostrally from its normal position. The atlanto-occipital joints appeared congruent in an extended position. A CT scan was performed for preoperative assessment in dorsal recumbency and the vertebrae were reduced into normal alignment with this positioning.

The cat was positioned in dorsal recumbency for surgery with the neck extended and thoracic limbs tied and pulled caudally. A standard ventral approach to the atlantoaxial region was made. The joint capsule was dissected, and the joint space debrided with a curette. With gentle caudal retraction of C2 using a freer periosteal elevator in the atlantoaxial joint, the base of the odontoid process could be visualised. An odontoidectomy and partial vertebrectomy of the cranial vertebral body of C2 was performed using a high-speed burr (Figure 2). Atlantoaxial stabilisation was then performed with implant placement similar to previous descriptions with

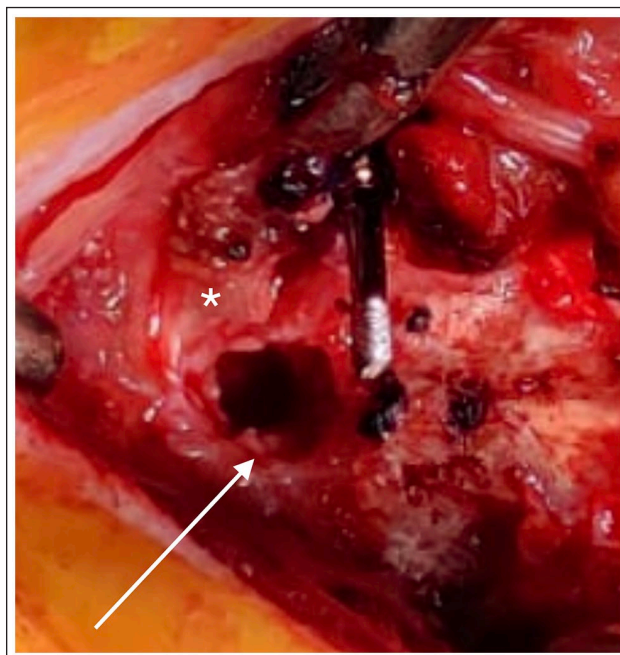


Figure 2 Intraoperative photograph of the surgical site of case 1. The asterisk marks the body of C1 and the arrow points to the narrow atlantoaxial joint adjacent to the site of odontoidectomy

screws⁴ by placing two 1.1 mm stainless steel threaded interface pins (Imexx) into the pedicles of C1 from caudoventromedial to craniodorsolateral; these were more caudal and lateral than normal for this procedure, given the displacement of the pedicles caused by the previous

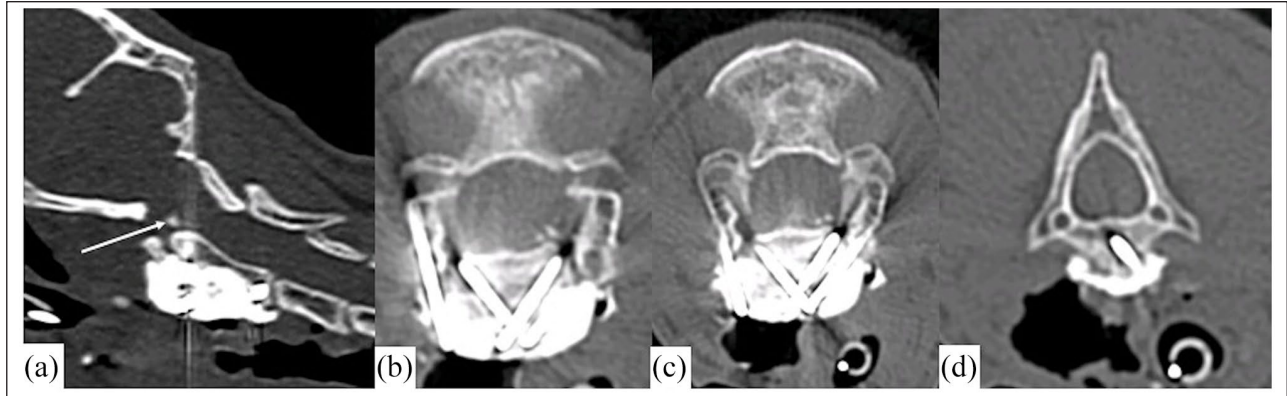


Figure 3 Postoperative CT of case 1. (a) Sagittal view with an arrow indicating the remainder of the odontoid process following odontoidectomy; (b) implants in C1 and cranial C2; (c) slice caudal to (b) of implants in C1 and C2; and (d) implant in caudal C2

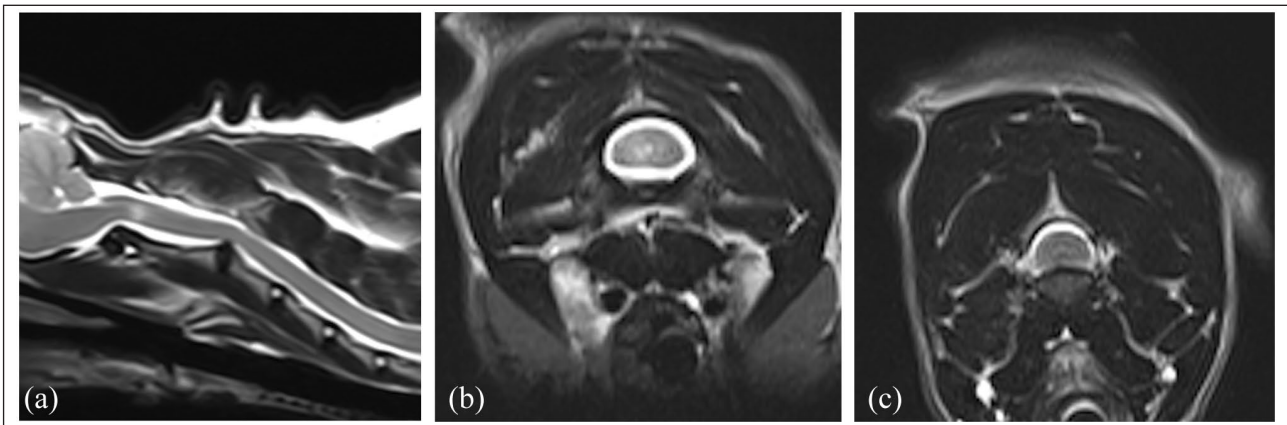


Figure 4 T2-weighted MRI of case 2 in (a) sagittal position; (b) in transverse at the level of C2 showing focal and lateralising hyperintensity within the spinal cord; and (c) at the level of C2/C3 intervertebral disc, showing mild compression

vertebral body fracture. Subsequently, two pins were driven in the cranial body of C2 ventromedial to dorso-lateral and one in the caudal body cranioventrolateral; to caudodorsomedial; these were cut short and enshrouded in a sculpted bolus of polymethyl methacrylate (PMMA) bone cement and copious flushing with saline was applied to prevent thermal injury to the soft tissues. A postoperative CT scan confirmed adequate implant positioning and removal of compression by the odontoid process (Figure 3) and the cat improved to neurologically normal and without cervical spinal pain. At the follow-up CT scan after 10 weeks, no movement or breakage of implants were seen. At the 6-month postoperative follow-up examination, the cat continued to be neurologically normal with no signs of deterioration.

Case 2

An 8-year-old neutered male Persian cat was presented for acute-onset non-ambulatory tetraparesis and neck pain. The cat had been found indoors in lateral recumbency vocalising; a fall from stairs was suspected. On examination, the cat was in lateral recumbency with a

persistent head turn to the right. It was non-ambulatory tetraparetic and almost tetraplegic, with only weak voluntary movements in the right pelvic limb. Proprioception and hopping responses were absent in all limbs; segmental spinal reflexes and cranial nerve examination were normal. Conscious perception of a painful stimulus applied to the skin was evident in the limbs and tail.

T2-weighted MRI sequences revealed a hyperintense lesion confined to the grey matter of the spinal cord at the level of the C2 vertebral body, slightly lateralised to the left side (Figure 4). This lesion was hypointense on T1-weighted imaging and enhanced heterogeneously following the administration of gadolinium contrast. The C2/C3 disc was degenerate and mildly protrusive, causing mild spinal cord compression. MRI changes were considered to be most consistent with focal ischaemia, oedema and/or inflammation, following a vascular accident or a whiplash trauma. The injury was caudal to the atlantoaxial joint and in the absence of pain on examination and radiological evidence for subluxation, medical management was initiated with exercise restriction,

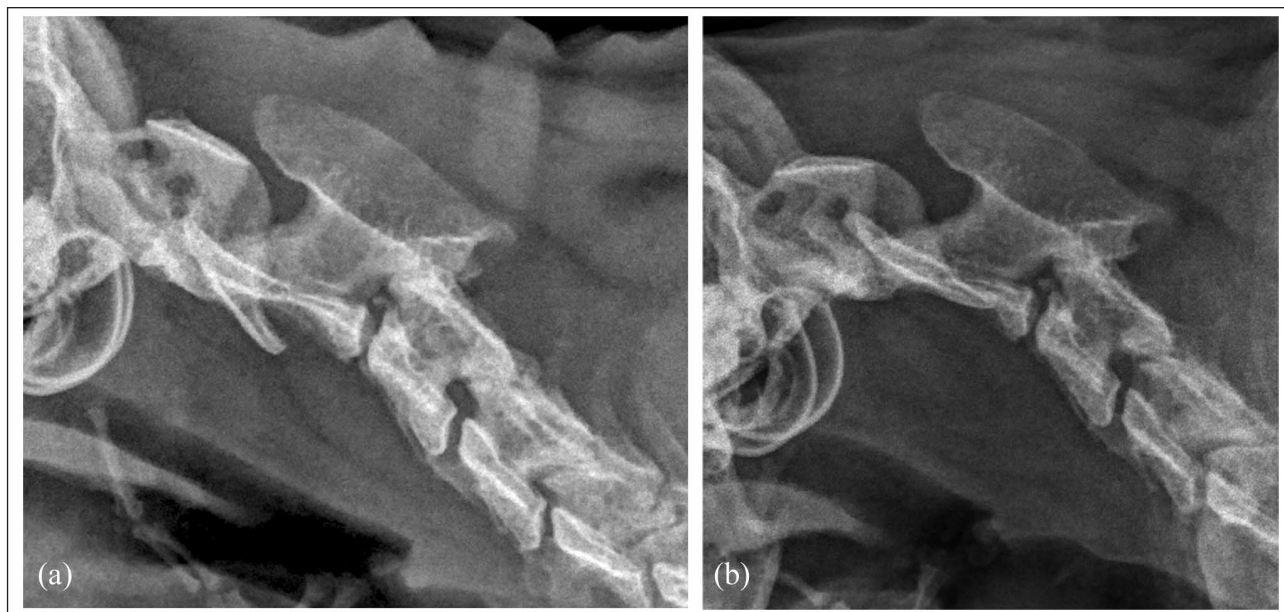


Figure 5 Radiographs of the cervical spine of case 2 in (a) extended and (b) flexed position, showing the dynamic atlantoaxial subluxation with flexion of the neck

NSAIDs and physiotherapy. The cat suffered a recurrence of vocalisation 2 weeks later and was re-examined. It presented with the same neurological deficits as before but with more consistent signs of pain on gentle ventroflexion of the neck.

Lateral radiographs of the cervical spine, in both extended and flexed views, revealed atlantoaxial subluxation (Figure 5). A CT of the neck was performed for surgical planning with the cervical spine in an extended position, which demonstrated a reduction of the subluxation. Measurements and implant trajectories were assessed from this scan.

Atlantoaxial stabilisation was performed as described in case 1 with 1.1 mm diameter stainless steel threaded pins (Imexx interface) placed bilaterally in a ventromedial to dorsolateral direction in C1, bilaterally in a ventromedial to dorsolateral orientation in the cranial body of C2 and a single pin placed on the right from dorsolateral to ventromedial in the caudal body of C2. The pins were cut short and enshrouded in a sculpted bolus of PMMA bone cement (Technivet). CT and plain-film orthogonal radiographs postoperatively confirmed satisfactory implant placement (Figure 6). Wound closure was performed in a routine manner with skin sutures placed externally. Analgesia of opioid boluses and ketamine continuous rate infusion were reduced over 72 h.

The cat showed improvements in voluntary movement of all limbs while hospitalised but remained non-ambulatory tetraparetic; it remained urinary continent. At the 6-week follow-up, a CT scan showed no migration or breakage of implants and neurological

improvement to have good voluntary movement of all limbs and no recurrence of pain; however, the cat remained non-ambulatory. The cat was euthanased 6 months postoperatively for failure to become independently ambulatory.

Discussion

Atlantoaxial subluxation has been rarely reported in cats. There have been four case reports of this disease in cats.^{1-3,5} Atlantoaxial subluxation has been reported in cats as the result of instability of the atlantoaxial joint traumatic hyperflexion and ligament damage,³ odontoid process hypoplasia⁵ or occipito-atlantoaxial malformation.² No previous reports of cats with fracture of the odontoid process causing atlantoaxial subluxation were found in the literature. Three cats have been described with C2 vertebral fractures.⁶ One of these cases with a vertebral body fracture with contact to the atlantoaxial joint was treated surgically, although the technique was not described, and a full recovery was reported.⁶ A second cat with a vertebral body fracture without joint involvement was medically managed and a partial recovery was reported. The third case had a fracture of the tip of the dens causing stupor; however, the cat was euthanased after investigations.⁶ Surgical management of atlantoaxial subluxations in cats has been described previously with a ventral approach using a cross-pinning technique with Kirschner wires.^{1,2} An odontoidectomy was also described in a cat with a hypoplastic dens.² The surgery performed in both cats here has not previously been reported in cats. We saw no

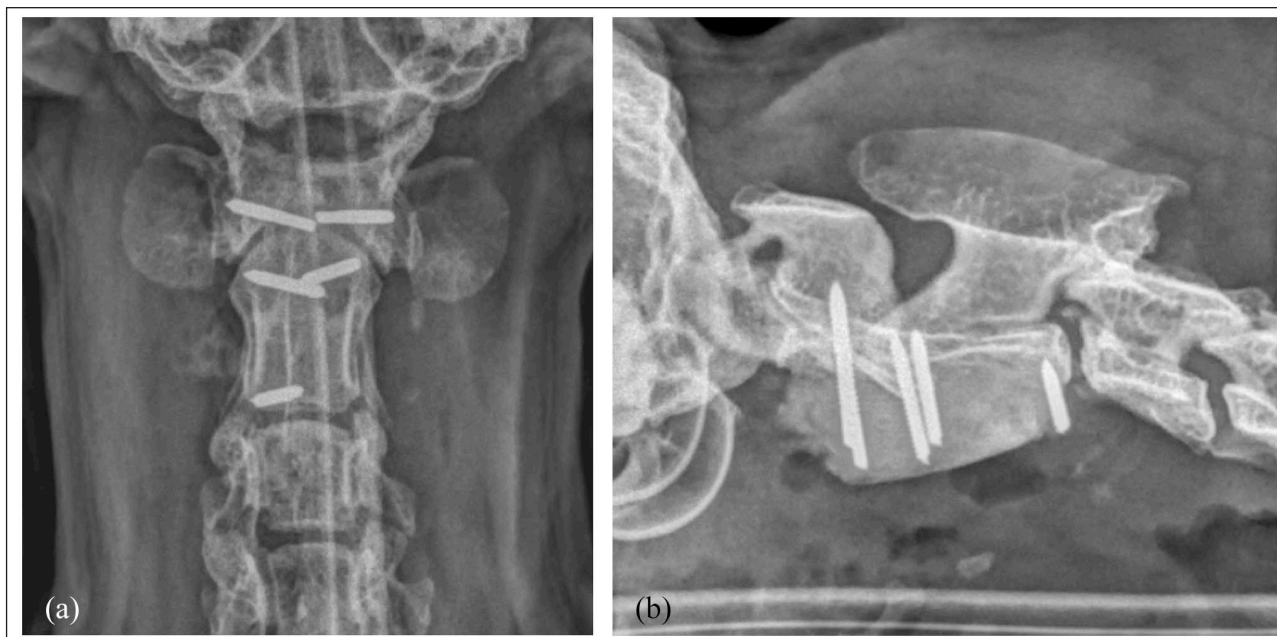


Figure 6 Radiographs showing (a) dorsoventral and (b) lateral views confirming the correct implant placement and reduction to the atlantoaxial subluxation

deterioration or complications following surgery at the 6-month follow-ups. In cases where emergency stabilisation is not required, consideration of surgical guides to achieve bi-cortical pin or screw placement could also be undertaken as has been described in dogs.⁷

Both cats had acute onset of signs but improved on NSAID treatment and restricted exercise. Conservative management has previously been reported as successful in one cat;³ however, both cases described here showed relapse and deterioration of signs later on. Although both cats improved after surgery, the extent of improvement reflected the initial severity of neurological signs. We suspect that the second case failed to recover ambulatory status as a result of permanent neuronal damage secondary to gliosis and oedema following the severe contusion and compression.

In case 2, the C2/3 intervertebral disc protrusion caused only mild compression of the spinal cord and was unlikely to significantly contribute to the clinical signs. A significant association with C2/3 intervertebral disc herniation with atlantoaxial subluxation in dogs has been reported,⁸ which may suggest a more chronic instability in case 2.

Herein, we presented flexed views of an atlantoaxial subluxation exposing instability, which was not evidenced by extended-position lateral radiographic views of the cervical spine (Figure 5). This has been described previously in a cat and is widely documented in dogs.^{3,9,10}

Conclusions

Ventral surgical fixation with pins and cement without transarticular implants can be a successful and safe

method for stabilisation of atlantoaxial subluxation in cats. Although uncommon, atlantoaxial subluxation secondary to trauma should be considered in cases of cervical spinal pain or tetraparesis following trauma.

Conflict of interest The authors declared no potential conflicts of interest with respect to the research, authorship, and/or publication of this article.

Funding The authors received no financial support for the research, authorship, and/or publication of this article.

Ethical approval The work described in this manuscript involved the use of non-experimental (owned or unowned) animals. Established internationally recognised high standards ('best practice') of veterinary clinical care for the individual patient were always followed and/or this work involved the use of cadavers. Ethical approval from a committee was therefore not specifically required for publication in *JFMS Open Reports*. Although not required, where ethical approval was still obtained it is stated in the manuscript.

Informed consent Informed consent (verbal or written) was obtained from the owner or legal custodian of all animal(s) described in this work (experimental or non-experimental animals, including cadavers) for all procedure(s) undertaken (prospective or retrospective studies). No animals or people are identifiable within this publication, and therefore additional informed consent for publication was not required.

ORCID iD Emma Gilbert  <https://orcid.org/0000-0001-5057-0923>

References

- 1 Thomson MJ and Read RA. **Surgical stabilisation of the atlantoaxial joint in a cat.** *Vet Comp Orthop Traumatol* 1996; 9: 36–39.
- 2 Jaggy AH, Roberts VL and Oliver RE. **Occipitoatlantoaxial malformation with atlantoaxial subluxation in a cat.** *J Small Anim Pract* 1991; 32: 366–372.
- 3 Wessmann A, McLaughlin A and Hammond G. **Traumatic spinal cord injury caused by suspected hyperflexion of the atlantoaxial joint in a 10-year-old cat.** *JFMS Open Rep* 2015; 1. DOI: 10.1177/2055116915589839.
- 4 Stout Steele MW, Hodshon AW, Hopkins AL, et al. **Multi-center retrospective evaluation of screw and polymethylmethacrylate constructs for atlantoaxial fixation in dogs.** *Vet Surg* 2016; 45: 909–915.
- 5 Shelton B, Bellah J, Chrisman C, et al. **Hypoplasia of the odontoid process and secondary atlantoaxial luxation in a Siamese cat.** *Prog Vet Neurol* 1991; 2: 209–211.
- 6 Schmidli FE, Stein VM, Aikawa T, et al. **Fractures of the second cervical vertebra in 66 dogs and 3 cats: a retrospective study.** *Vet Comp Orthop Traumatol* 2019; 32: 200–206.
- 7 Toni C, B Oxley B and Behr S. **Atlanto-axial ventral stabilisation using 3D-printed patient-specific drill guides for placement of bicortical screws in dogs.** *J Small Anim Pract* 2020; 61: 609–616.
- 8 Schneider M, Waschk M, Precht M, et al. **Incidence of abnormalities of the second and third cervical vertebral junction in dogs with atlantoaxial instability: a multicentre study.** *Vet Comp Orthop Traumatol* 2017; 30: 424–429.
- 9 Shores A and Tepper LC. **A modified ventral approach to the atlantoaxial junction in the dog.** *Vet Surg* 2007; 36: 765–770.
- 10 White DA, Renberg WC and Roush JK. **Flexed radiographic angles for determination of atlantoaxial instability in dogs.** *Vet Surg* 2019; 48: 1406–1415.