



Minimally invasive spinal surgery in a young cat with vertebral hypertrophy

Authors: Sakamoto, Karin, Nozue, Yuta, Murakami, Mami, Nakata, Kohei, Nakano, Yukiko, et al.

Source: Journal of Feline Medicine and Surgery Open Reports, 7(2)

Published By: SAGE Publishing

URL: <https://doi.org/10.1177/20551169211048460>

BioOne Complete (complete.BioOne.org) is a full-text database of 200 subscribed and open-access titles in the biological, ecological, and environmental sciences published by nonprofit societies, associations, museums, institutions, and presses.

Your use of this PDF, the BioOne Complete website, and all posted and associated content indicates your acceptance of BioOne's Terms of Use, available at www.bioone.org/terms-of-use.

Usage of BioOne Complete content is strictly limited to personal, educational, and non - commercial use. Commercial inquiries or rights and permissions requests should be directed to the individual publisher as copyright holder.

BioOne sees sustainable scholarly publishing as an inherently collaborative enterprise connecting authors, nonprofit publishers, academic institutions, research libraries, and research funders in the common goal of maximizing access to critical research.



Minimally invasive spinal surgery in a young cat with vertebral hypertrophy

Karin Sakamoto¹, Yuta Nozue², Mami Murakami¹, Kohei Nakata², Yukiko Nakano², Shinya Soga³, Sadatoshi Maeda^{1,2,4} and Hiroaki Kamishina^{1,2,4}

Journal of Feline Medicine and Surgery Open Reports
1–5

© The Author(s) 2021

Article reuse guidelines:

sagepub.com/journals-permissions

DOI: 10.1177/20551169211048460

journals.sagepub.com/home/jfmsopenreports

This paper was handled and processed by the European Editorial Office (ISFM) for publication in *JFMS Open Reports*



Abstract

Case summary A 2-year-old neutered female Scottish Fold cat was presented with an 8-week history of progressive back pain, paraparesis and decrease of postural reactions in both pelvic limbs. MRI showed spinal cord compression from both ventral sides, which originated from the T4 vertebral body and pedicle. The lesion compressing the spinal cord had a bone-like density on CT, and endoscopic surgery was performed to excise it. Histopathological examination of the resected tissue showed no evidence of malignancy and the lesion was diagnosed as vertebral hypertrophy. After surgery, the neurological status of the cat gradually improved. The cat was ambulant at the follow-up evaluation 2 weeks after surgery. Six months later, hindlimb paresis had improved considerably, and no recurrence was observed on CT.

Relevance and novel information This is the first description of thoracic vertebral canal stenosis due to hypertrophy of a single vertebra in a young cat. Excision of the hypertrophic vertebra by endoscopic surgery is less invasive than open surgery and may give a good prognosis.

Keywords: Vertebral hypertrophy; Scottish Fold cats; thoracic vertebral canal stenosis; endoscopic surgery

Accepted: 6 September 2021

Introduction

Non-lymphoid neoplasia and intervertebral disc disease (IVDD) are the top two causes of spinal disease in cats, and thoracic vertebral canal stenosis (TVCS) is the seventh most common.¹ Non-lymphoid neoplasia often occurs in older cats, whereas IVDD tends to occur in middle-aged cats; however, the age range of TVCS is unknown.¹ TVCS is a narrowing of the vertebral canal that results in the compression of the T3–L3 segments of the spinal cord or nerve roots. TVCS causes neurological abnormalities in the hindlimbs such as ataxia, paraparesis and pain. Vertebral canal stenosis is classified into three causes: malformation; active bone growth throughout the growth period; and age-related changes, including hypertrophied ligaments, intervertebral disc herniation and degenerative articular changes.² In cats, reports of TVCS are limited. In retrospective research on TVCS in cats, all cats were over 5 years and the median age was 9 years.³ TVCS secondary to articular process hypertrophy in two cats and diffuse idiopathic skeletal hyperostosis

(DISH) in one cat have been reported.^{4,5} The age of the cats in these studies was ≥ 9 years. TVCS in young cats has not been reported.

Endoscopic spinal surgery is a minimally invasive surgical technique for spinal surgery in humans. In fully endoscopic spinal surgery, an endoscope is inserted into the muscles and instruments are inserted into the

¹Joint Department of Veterinary Medicine, Faculty of Applied Biological Sciences, Gifu University, Gifu, Japan

²The Animal Medical Center of Gifu University, Gifu University, Gifu, Japan

³Heart Animal Clinic, Aichi, Japan

⁴The United Graduate School of Veterinary Sciences, Gifu University, Gifu, Japan

Corresponding author:

Hiroaki Kamishina BVSc, PhD, AiCVIM (neurology), Joint Department of Veterinary Medicine, Faculty of Applied Biological Sciences, Gifu University, Yanagido1-1, Gifu, 501-1193, Japan
Email: kamicna@gifu-u.ac.jp



Creative Commons Non Commercial CC BY-NC: This article is distributed under the terms of the Creative Commons

Attribution-NonCommercial 4.0 License (<https://creativecommons.org/licenses/by-nc/4.0/>) which permits non-commercial use, reproduction and distribution of the work without further permission provided the original work is attributed as specified on the SAGE and Open Access pages (<https://us.sagepub.com/en-us/nam/open-access-at-sage>).

endoscope. Under endoscopic surgery, spinal surgery can be performed with a smaller incision, which results in less muscle damage and blood loss, earlier return to daily life and better visualisation during the operation than conventional open surgery.⁶ Most previous reports on endoscopic spinal surgery were limited to the excision of degenerated and herniated intervertebral discs; however, its indications have widened to include spinal stenosis in humans.⁷

Herein, we describe the clinical presentation, imaging characteristics, minimally invasive surgical technique with an endoscope and outcome of TVCS due to hypertrophy of a single vertebra in a young cat.

Case description

A 2-year-old female neutered Scottish Fold cat was presented with progressive gait abnormalities of both hindlimbs. The cat had begun to exhibit mild ataxia of the pelvic limbs and back pain as the first clinical signs a week before presentation to the primary veterinarian. The primary veterinarian prescribed robenacoxib for pain management; however, no improvement was seen after a week. Gabapentin (4 mg/kg q24h) and mono ammonium glycyrrhizinate (5 mg/kg q24) were prescribed by the referring veterinarian in place of robenacoxib; however, the ataxia of the hindlimbs progressed to paresis in the following week. One month after clinical onset, MRI showed vertebral canal stenosis at the level of T4. Prednisolone (0.5 mg/kg q24h) was prescribed, and the paresis and back pain were slightly improved.

The cat was referred to the Animal Medical Center of Gifu University for further evaluation and treatment of TVCS 2 months after clinical onset. At the time of presentation to the Animal Medical Center of Gifu University, vital parameters and physical examination findings were within normal limits. Neurological examination revealed ambulatory paraparesis, decreased postural responses in both hindlimbs and normal segmental spinal reflexes (see Video 1 in the supplementary material). The cat was able to urinate without any problems and exhibited no back pain. These findings indicated that the lesion was located at the T3–L3 spinal cord segment. Haematology and plasma biochemistry revealed mild changes, including elevated total protein (8.2 g/dl; range 5.7–7.8) and albumin (4.4 g/dl; range 2.3–3.5). Serological tests for feline immunodeficiency virus and feline leukaemia virus were negative. Thoracic and abdominal radiographs showed no abnormality.

For further examination of the vertebral column, MRI (Achieva 3.0T; Philips) and CT (Alexion Advance; Canon Medical Systems) were performed. On MRI, the vertebral body of T4 appeared hypointense on sagittal T2-weighted images (T2WI), compared with other vertebral bodies (Figure 1a). The spinal cord at the level of T4 was compressed from the ventral sides on transverse T2WI (Figure 1b).

The periphery of the lesion was contrast enhanced after administration of gadodiamide hydrate (Figure 1c). CT showed that this compression was from both ventral sides, and it originated from the vertebral body and pedicle of the T4 vertebra (Figure 1d–f).

On day 13, hemilaminectomy was performed to remove the compressive lesion of the right side of T3–4 (see Video 2 in the supplementary material). The laminectomy was performed as a fully endoscopic spinal surgery using an endoscope (Surgi-Max Endoscope; Elliquence) with a 30° angle of vision, an outer diameter of 7.0 mm and a length of 130 mm. The working tube had an outer diameter of 8.0 mm, a length of 125 mm and a flat opening. The light source, irrigation system, camera control unit and camera head were supplied by Karl Storz Endoscopy Japan. After premedication with atropine sulfate hydrate (5 µg/kg IV), midazolam (0.2 mg/kg IV) and ketamine hydrochloride (2 mg/kg IV), anesthesia was induced with alfaxalone (1 mg/kg IV) and maintained with sevoflurane (1.5–2.3%) in oxygen. Fentanyl citrate (10–20 µg/kg/h) and ketamine hydrochloride (0.8–1.6 mg/kg/h) were administered for intraoperative analgesia. Perioperative antibiotic therapy consisted of cefazolin sodium (20 mg/kg IV). The cat was positioned in ventral recumbency and the forelimbs were retracted cranially.

A parasagittal skin incision was made over the T4 vertebral region. Under fluoroscopic guidance, a dilation sleeve was inserted in the muscle layer after which the endoscopic working tube was placed over the right vertebral arch of T4. Using a radiofrequency system (Elliquence Trigger Flex Radiofrequency System; Elliquence), the muscles attached to the articular process of T3–T4, vertebral arch and the base of the spinous process of T4 were removed to completely expose the bony surface of T3–T4 to which the laminectomy was performed. A hemilaminectomy of T3–T4 and removal of hypertrophied portions of the pedicle and vertebral body of T4 were performed with a motorised burr (Primado2; Nakanishi) and Kerrison rongeurs, in order to decompress the spinal cord (Figure 2a). A portion of bone hypertrophy was removed by forceps and submitted for histopathological examination.

After surgery, the cat was administered fentanyl citrate (2 µg/kg/h) and ketamine hydrochloride (0.16 mg/kg/h) as a postoperative analgesic. Postoperative CT revealed that the area of the hemilaminectomy was adequate and the spinal cord was decompressed (Figure 2b,c). The cat recovered uneventfully and was discharged 2 days after surgery. After discharge, oral administration of cefalexin (25 mg/kg q12h) and prednisolone (0.3 mg/kg q24h) was continued for 2 weeks.

Histopathological examination revealed irregular trabeculae suggesting hyperostosis of the removed bony tissue; however, there was no evidence of malignancy or inflammatory reaction (Figure 3). Between the trabeculae, the connective tissue was oedematously separated and multiple small angiogenic sites were observed.

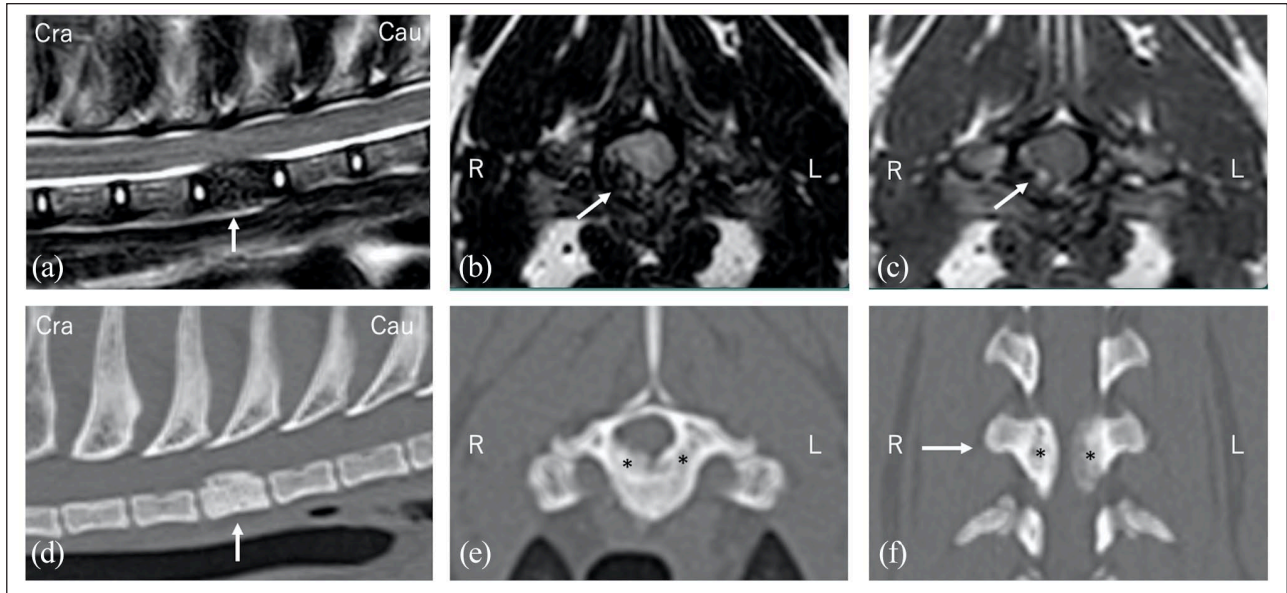


Figure 1 MRI and CT findings of vertebral hypertrophy in T4. (a) T2-weighted (T2W) sagittal MRI showing the vertebral body of T4 as hypointense vs other vertebral bodies. (b) T2W transverse MRI showing compression of the spinal cord from the ventral sides. (c) T1-weighted post-contrast transverse image showing the periphery of the structure compressing the spinal cord enhanced with contrast medium. (d) Reconstructed sagittal CT. (e) Transverse CT. (f) Dorsal CT revealed compression from both ventral sides that originated from the vertebral body and pedicle of T4. Lesions are indicated by arrows (a–d) and asterisks (e,f). Cra = cranial; Cau = caudal; R = right; L = left

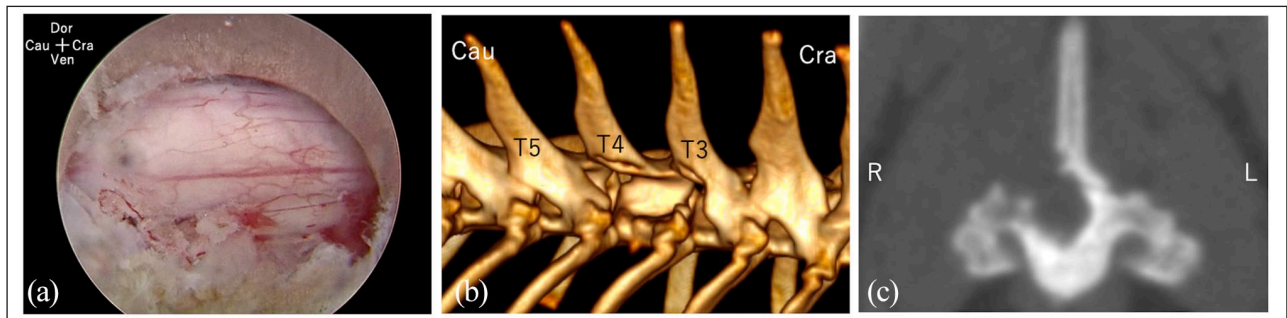


Figure 2 (a) Intraoperative endoscopic image. After hemilaminectomy, the spinal cord compressed by the hypertrophied pedicle and vertebral body was observed. The bony structure was removed by a motorised burr and Kerrison rongeurs. (b) Reconstructed three-dimensional image of the postoperative CT shows the extent of the hemilaminectomy of T3–T4. (c) Postoperative transverse CT of T4. Dor = dorsal; Cau = caudal; Cra = cranial; Ven = ventral; R = right; L = left

Follow-up examination was conducted 2 weeks after surgery. Mild proprioceptive ataxia was observed and postural responses in both pelvic limbs were normal (see Video 1 in the supplementary material). Three months after surgery, the cat was neurologically normal without any signs of ataxia, discomfort or pain. CT revealed no evidence of bony regrowth or spinal cord compression (Figure 4a). The latest recheck was performed 6 months after surgery, at which point the cat had no neurological abnormalities. CT at this point revealed a somewhat sclerotic vertebral body of T4, but recurrence of vertebral canal stenosis was not observed (Figure 4b).

Discussion

In a previous report, inflammatory, infectious and neoplastic diseases were the most common diseases of the spinal cord in cats.⁸ In a more recent study, non-lymphoid neoplasia and IVDD were the most common causes of spinal diseases, and TVCS was the seventh most common.¹ In a case series of TVCS in cats, all cats included in the report were middle-aged or older;³ hence, TVCS is considered one of the differential diagnoses of middle-aged or older cats presenting with a chronic, progressive, possibly painful T3–L3 myelopathy. Contrary to previous reports, the cat in the present report developed neurological signs

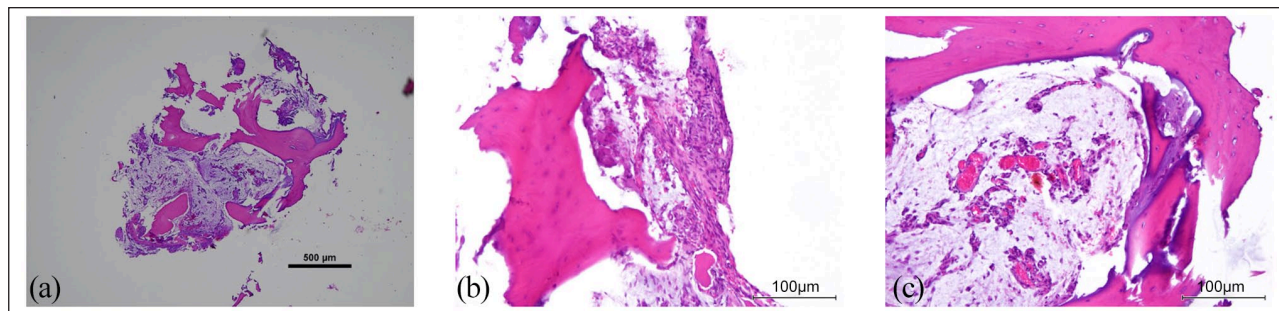


Figure 3 Histological presentation stained with haematoxylin and eosin. (a) The excised bony structure had irregular trabeculae suggesting hyperostosis without evidence of malignancy or inflammatory reaction. Between the trabeculae, connective tissues were oedematously separated and multiple small angiogenic sites were observed. (b) Enlarged image of the trabeculae. (c) Enlarged image of the connective tissues between the trabeculae

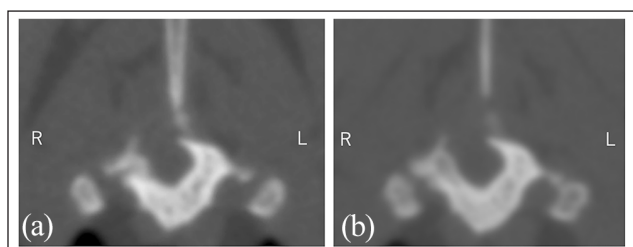


Figure 4 Postoperative follow-up transverse CT images. (a) CT 3 months after surgery shows no noticeable bone regrowth or recurrence of spinal cord compression. (b) CT 6 months after surgery revealed the somewhat sclerotic vertebral body of T4. R = right; L = left

caused by TVCS at a young age; thus, TVCS should be included in the differential diagnoses of young cats with progressive, painful T3–L3 myelopathy.

Previous studies reported TVCS owing to vertebral degeneration or vertebral hypertrophy in cats with DISH ($n = 1$) and TVCS secondary to articular process hypertrophy ($n = 2$).^{4,5} Generally, DISH accompanies calcification and ossification of the ventrolateral aspect of at least four consecutive vertebral bodies.⁹ In one report, new bone formation extended from T5 to S1 in a 9-year-old cat diagnosed with TVCS caused by DISH.⁵ In the present study, the imaging features, which consisted of deformed vertebrae that were being restricted to T4, and the age of onset (2 years old) did not support a diagnosis of DISH. In two cats with TVCS due to articular process hypertrophy, the lesions were at the level of T3–T4 and T11–T12 at 13 years old and 9 years old, respectively.⁴ In the present study, a single lesion originated from the vertebral body and pedicle of the T4 vertebra. As the cat had been kept indoors, it was unlikely that the spinal deformity resulted from trauma. In addition, the age of our cat differed from the past reports of DISH and TVCS; thus, the cat was diagnosed with a different condition from previously reported cases.

Scottish Fold cats have folded ears that arise from an autosomal dominant gene mutation.¹⁰ This mutation causes osteochondrodysplasia and affects bone structures, leading to progressive skeletal deformations at the distal limbs, tail and, in some cases, vertebrae.¹¹ The exact cause of osteochondrodysplasia in Scottish Fold cats is unknown; however, the *TRPV4* gene has been associated with this condition.¹² This condition follows an autosomal dominant inheritance with incomplete penetrance, and cats with homozygous fold-eared genes are severely affected by this disease, whereas cats with heterozygous genes tend to develop mild clinical signs.¹³ Although our case did not receive mutational analysis, abnormality of the vertebrae may be associated with the osteochondrodysplasia seen in this breed.

Histopathological characteristics of osteochondrodysplasia in cats are defective endochondral ossification in the epiphyseal cartilage and disorganised cartilage columns in the epiphyseal cartilage that cause the cartilage to thicken irregularly.¹⁰ In the present case, there were no observable chondrocytes in the excised bone tissue; therefore, whether the vertebral hypertrophy was associated with osteochondrodysplasia was unknown. Although endoscopic removal of the hypertrophied bone structure in a minimally invasive fashion led to rapid and complete recovery of the clinical signs, a definitive diagnosis of osteochondrodysplasia by endoscopic surgery was not made as a limited amount of tissue was obtained during the surgery.

There have been no reports of endoscopic surgery for vertebral canal stenosis in cats. Previously, spinal endoscopic surgery was applied only to herniated discs in humans, and vertebral canal stenosis was a contraindication for spinal endoscopy.^{7,14} Recently, endoscopic surgery has been applied to vertebral canal stenosis in humans.¹⁵ The advantage of spinal endoscopy is that it is less invasive because it requires less muscle detachment and less postoperative pain than conventional open surgery.¹⁶ Randomised studies in humans found

that endoscopic surgery minimised skin incisions, muscular retraction and bone removal, leading to an early return to daily life.^{17–19} The present case took only 2 days from surgery to discharge and recovered quickly. Full endoscopic surgery is minimally invasive and effective for the surgical treatment of vertebral canal stenosis in cats.

Conclusions

This is the first report to present a young Scottish Fold cat with vertebral hypertrophy resulting in TVCS. This case report describes clinical findings, imaging features, histopathological findings, surgical treatment and follow-up of this rare case. In addition, the removal of the hypertrophic vertebral arch by full endoscopic surgery is also described for the first time in a cat.

Conflict of interest The light source, irrigation system, camera control unit and camera head were supplied by KARL STORZ Endoscopy Japan KK.

Funding The authors received no financial support for the research, authorship, and/or publication of this article.

Ethical approval This work involved the use of non-experimental animals only (including owned or unowned animals and data from prospective or retrospective studies). Established internationally recognised high standards ('best practice') of individual veterinary clinical patient care were followed. Ethical approval from a committee was therefore not specifically required for publication in *JFMS Open Reports*.

Informed consent Informed consent (either verbal or written) was obtained from the owner or legal custodian of all animal(s) described in this work (either experimental or non-experimental animals) for the procedure(s) undertaken (either prospective or retrospective studies). For any animals or people individually identifiable within this publication, informed consent (either verbal or written) for their use in the publication was obtained from the people involved.

ORCID iD Hiroaki Kamishina  <https://orcid.org/0000-0001-9929-6654>

Supplementary material The following files are available online:

Video 1: Video of the cat's gait before and after surgery.

Video 2: Intraoperative endoscopic video.

References

- 1 Mella SL, Cardy TJ, Volk HA, et al. **Clinical reasoning in feline spinal disease: which combination of clinical information is useful?** *J Feline Med Surg* 2020; 22: 521–530.

- 2 Sturges B and Westworth D. **Congenital spinal malformations.** *Vet Clin North Am Small Anim Pract* 2010; 40: 951–981.
- 3 Gillespie S and De Decker S. **Thoracic vertebral canal stenosis in cats: clinical features, diagnostic imaging findings, treatment and outcome.** *J Feline Med Surg* 2020; 22: 1191–1199.
- 4 Carletti BE, Espadas I and Sanchez-Masian D. **Thoracic vertebral canal stenosis due to articular process hypertrophy in two cats treated by hemilaminectomy with partial osteotomy of the spinous process.** *JFMS Open Rep* 2019. DOI: 10.1177/2055116919863176.
- 5 Bossens K, Bhatti S, Van Soens I, et al. **Diffuse idiopathic skeletal hyperostosis of the spine in a nine-year-old cat.** *J Small Anim Pract* 2016; 57: 33–35.
- 6 Momin AA and Steinmetz MP. **Evolution of minimally invasive lumbar spine surgery.** *World Neurosurg* 2020; 140: 622–626.
- 7 Kim M, Kim HS, Oh SW, et al. **Evolution of spinal endoscopic surgery.** *Neurospine* 2019; 16: 6–14.
- 8 Marioni-Henry K, Vite CH, Newton AL, et al. **Prevalence of diseases of the spinal cord of cats.** *J Vet Intern Med* 2004; 18: 851–858.
- 9 Resnick D and Niwayama G. **Radiographic and pathologic features of spinal involvement in diffuse idiopathic skeletal hyperostosis (DISH).** *Radiology* 1976; 119: 559–568.
- 10 Malik R, Allan GS, Howlett CR, et al. **Osteochondrodysplasia in Scottish Fold cats.** *Aust Vet J* 1999; 77: 85–92.
- 11 Turan G and Bozkan Z. **Osteochondrodysplasia in a 9-year-old Scottish Fold cat.** *VCOT Open* 2019; 2: e60–e63.
- 12 Gandolfi B, Alamri S, Darby WG, et al. **A dominant TRPV4 variant underlies osteochondrodysplasia in Scottish Fold cats.** *Osteoarthritis Cartilage* 2016; 24: 1441–1450.
- 13 Craig LE, Dittmer KE and Thompson KG. **Bones and joints.** In: Maxie G (ed). *Jubb, Kennedy & Palmer's pathology of domestic animals*. 6th ed. Philadelphia, PA: Elsevier Health Sciences, 2015, pp 45–46.
- 14 Ahn Y. **Transforaminal percutaneous endoscopic lumbar discectomy: technical tips to prevent complications.** *Expert Rev Med Devices* 2012; 9: 361–366.
- 15 Ahn Y. **Percutaneous endoscopic decompression for lumbar spinal stenosis.** *Expert Rev Med Devices* 2014; 11: 605–616.
- 16 Bresnahan LE, Smith JS, Ogden AT, et al. **Assessment of paraspinal muscle cross-sectional area after lumbar decompression: minimally invasive versus open approaches.** *Clin Spine Surg* 2017; 30: E162–E168.
- 17 Mayer HM and Brock M. **Percutaneous endoscopic discectomy: surgical technique and preliminary results compared to microsurgical discectomy.** *J Neurosurg* 1993; 78: 216–225.
- 18 Hermantin FU, Peters T, Quartararo L, et al. **A prospective, randomized study comparing the results of open discectomy with those of video-assisted arthroscopic microdiscectomy.** *J Bone Joint Surg Am* 1999; 81: 958–965.
- 19 Ruetten S, Komp M, Merk H, et al. **Full-endoscopic interlaminar and transforaminal lumbar discectomy versus conventional microsurgical technique: a prospective, randomized, controlled study.** *Spine (Phila Pa 1976)* 2008; 33: 931–939.