



Surgical treatment of a distal oesophageal stricture by mucosal radial incision and dilation in a kitten with secondary megaesophagus

Authors: Kurtz, Maxime, Paulin, Mathieu V, Fournet, Alexandre, Decambron, Adeline, Fabrès, Virginie, et al.

Source: Journal of Feline Medicine and Surgery Open Reports, 7(1)

Published By: SAGE Publishing

URL: <https://doi.org/10.1177/2055116921994516>

BioOne Complete (complete.BioOne.org) is a full-text database of 200 subscribed and open-access titles in the biological, ecological, and environmental sciences published by nonprofit societies, associations, museums, institutions, and presses.

Your use of this PDF, the BioOne Complete website, and all posted and associated content indicates your acceptance of BioOne's Terms of Use, available at www.bioone.org/terms-of-use.

Usage of BioOne Complete content is strictly limited to personal, educational, and non - commercial use. Commercial inquiries or rights and permissions requests should be directed to the individual publisher as copyright holder.

BioOne sees sustainable scholarly publishing as an inherently collaborative enterprise connecting authors, nonprofit publishers, academic institutions, research libraries, and research funders in the common goal of maximizing access to critical research.



Surgical treatment of a distal oesophageal stricture by mucosal radial incision and dilation in a kitten with secondary megaesophagus

Journal of Feline Medicine and Surgery Open Reports
1–8

© The Author(s) 2021

Article reuse guidelines:

sagepub.com/journals-permissions

DOI: 10.1177/2055116921994516

journals.sagepub.com/home/jfmsopenreports

This paper was handled and processed by the European Editorial Office (ISFM) for publication in *JFMS Open Reports*



Maxime Kurtz¹ , Mathieu V Paulin¹, Alexandre Fournet², Adeline Decambron², Virginie Fabrès¹ and Valérie Freiche¹

Abstract

Case summary A 7-month-old intact female Maine Coon cat was presented with a 2-month history of regurgitations. Contrast radiographic and endoscopic examinations revealed a diffuse megaesophagus secondary to a severe lower oesophageal stricture. An epiphrenic diverticulum was noted. Endoscopic balloon dilation was unsuccessful. Gastrotomy was thus performed in order to incise the oesophageal wall radially along the stricture site, and then to dilate the stricture. A diameter of 20mm was reached. With the aim of preventing stricture recurrence, submucosal injections of triamcinolone acetonide were performed. An 18Fr oesophagogastric feeding tube was placed and a left gastropexy was performed in order to exert some traction on the gastroesophageal junction, with the aim of reducing the oesophageal diverticulum. Twelve months postoperatively, clinical signs had completely resolved and follow-up radiographs revealed marked improvement of the oesophageal dilatation.

Relevance and novel information Lower oesophageal strictures should be considered when evaluating regurgitations or megaesophagus in a kitten. Surgical mucosal radial incision is a therapeutic option in cases of lower oesophageal stricture refractory to balloon dilation, and can lead to a marked improvement of clinical signs and of the oesophagus diameter leading to clinical success.

Keywords: Oesophagus; dilation; diverticulum; endoscopy; balloon dilation; triamcinolone

Accepted: 21 January 2021

Case description

A 7-month-old intact female Maine Coon was referred for further evaluation of a 2-month history of severe regurgitations, involving both kibble and water, occurring seconds to minutes after food intake (about twice a week to twice a day). Weight loss was reported over the previous 2 months. No improvement was noted after symptomatic treatment, including maropitant, cimetidine and amoxicillin/clavulanic acid, or with gastrointestinal diet trials. The cat showed a normal appetite and water consumption, as well as a normal level of activity. Review of the patient's medical history revealed chronic vomiting of undigested food and bile from the age of 3–5 months, and an episode of self-resolving acute vomiting (about three times a day, for 10 days),

when it was 5 months old. No episode of regurgitation or vomiting was reported before the age of 3 months. The referring veterinarian had performed thoracic radiographs, taken before and after oral administration of contrast medium mixed with canned food, which

¹Internal Medicine Department, National Veterinary School of Alfort, Maisons-Alfort, France

²Surgery Department, National Veterinary School of Alfort, Maisons-Alfort, France

Corresponding author:

Valérie Freiche DVM, PhD, DESV-MI, Internal Medicine Department, National Veterinary School of Alfort, 7 Avenue du Général de Gaulle, Maisons-Alfort F-94700, France
Email: valerie.freiche@vet-alfort.fr



Creative Commons Non Commercial CC BY-NC: This article is distributed under the terms of the Creative Commons

Attribution-NonCommercial 4.0 License (<https://creativecommons.org/licenses/by-nc/4.0/>) which permits non-commercial use, reproduction and distribution of the work without further permission provided the original work is attributed as specified on the SAGE and Open Access pages (<https://us.sagepub.com/en-us/nam/open-access-at-sage>).

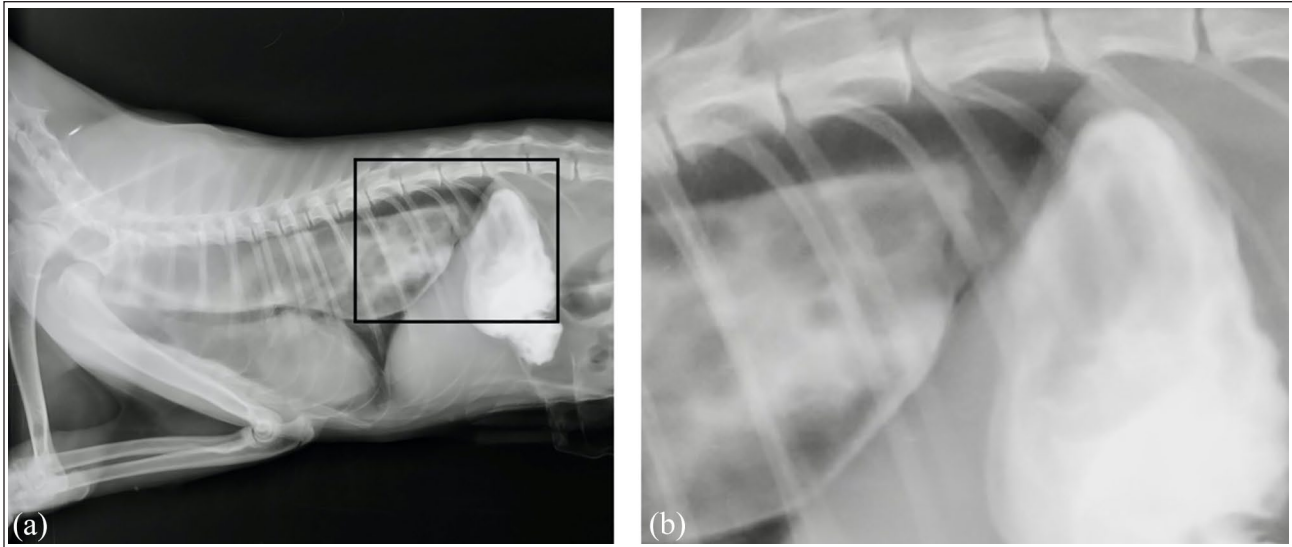


Figure 1 (a) Right lateral thoracic radiograph after contrast medium ingestion. Note the severe and diffuse oesophageal aeric dilatation indicating generalised megaesophagus, as well as (b) the loss of continuity between the distal oesophagus and the stomach. *Courtesy of Dr C Muller*

demonstrated a generalised oesophageal distension. As a significant amount of residual ingesta was observed in the oesophageal lumen several minutes after swallowing, oesophageal motility was subjectively considered reduced (Figure 1). No evidence of aspiration pneumonia was noted.

At the time of presentation, the cat was bright, alert and responsive, with a body weight of 2.5 kg and a body condition score of 2/9. Stunted growth was noted. The remainder of the physical examination was unremarkable.

Because of the previously mentioned loss of continuity between the distal oesophagus and the stomach on contrast lateral thoracic radiographs, endoscopy was performed to evaluate the oesophagogastric mucosa and to investigate a potential distal oesophageal obstruction (eg, stricture or foreign body). After premedication with methadone (0.2 mg/kg [Comfortan; Dechra]) and dexmedetomidine (5 µg/kg [Sedadex; Dechra]), general anaesthesia was induced by an intravenous injection of propofol and ketamine (1 mg/kg each [Propovet; Abbott] [Imalgene; Merial]), followed by endotracheal intubation for anaesthetic maintenance by isoflurane. The oesophagoscopy was performed using an 8.8 mm external diameter videogastroscope: a diffusely dilated oesophagus was noted, with oral to an annular luminal narrowing adjacent to the cardia. Only a 2.8 mm biopsy forceps could be passed through the stricture. A small distal oesophageal diverticulum was noted laterally to the narrowing, probably resulting from the food accumulation in the distal oesophagus. In this context, endoscopic examination of the stomach was not possible. Taken together, these findings were consistent with a severe lower oesophageal stricture.

Attempts to pass an endoscopy-guided balloon dilator entirely throughout the stricture were unsuccessful. Balloons were partially inserted into the stenotic canal and filled up to reach their maximum burst pressure, which was held for 120 s, and no significant improvement of the stricture was noted (Figure 2). Therefore, the procedure was discontinued and another approach was decided.

The cat underwent coeliotomy for a transgastric retrograde approach of the gastroesophageal junction a few days after the endoscopic examination. After cranioventral body gastrotomy, the stricture was visualised intraluminally throughout the cardia. Four radial full-thickness mucosal incisions were performed using an #11 scalpel blade; each incision was performed so as to reach only the submucosa, taking care not to breach the oesophageal wall. Incisions were approximately 1 cm in length. These allowed an initial progressive dilation, and further dilation was obtained first with gentle finger manipulation (bougienage), and then using balloon dilators of increasing sizes. The stricture diameter reached 20 mm after the last dilation. To reduce the risk of recurrence, four injections of triamcinolone acetonide (0.25 mg each [Kenacort; Bristol-Myers Squibb]) were performed during surgery in the submucosa within the site of the stricture. Two incisional biopsies of the gastric fundus were performed at the time of gastrotomy to query underlying gastric disease, and histological analysis revealed no significant abnormality. After gastric closure, a left gastropexy was performed to exert traction on the distal oesophagus, with the aim of reducing the oesophageal diverticulum. An 18 Fr latex oesophagostomy feeding tube was placed to extend across the gastroesophageal junction and

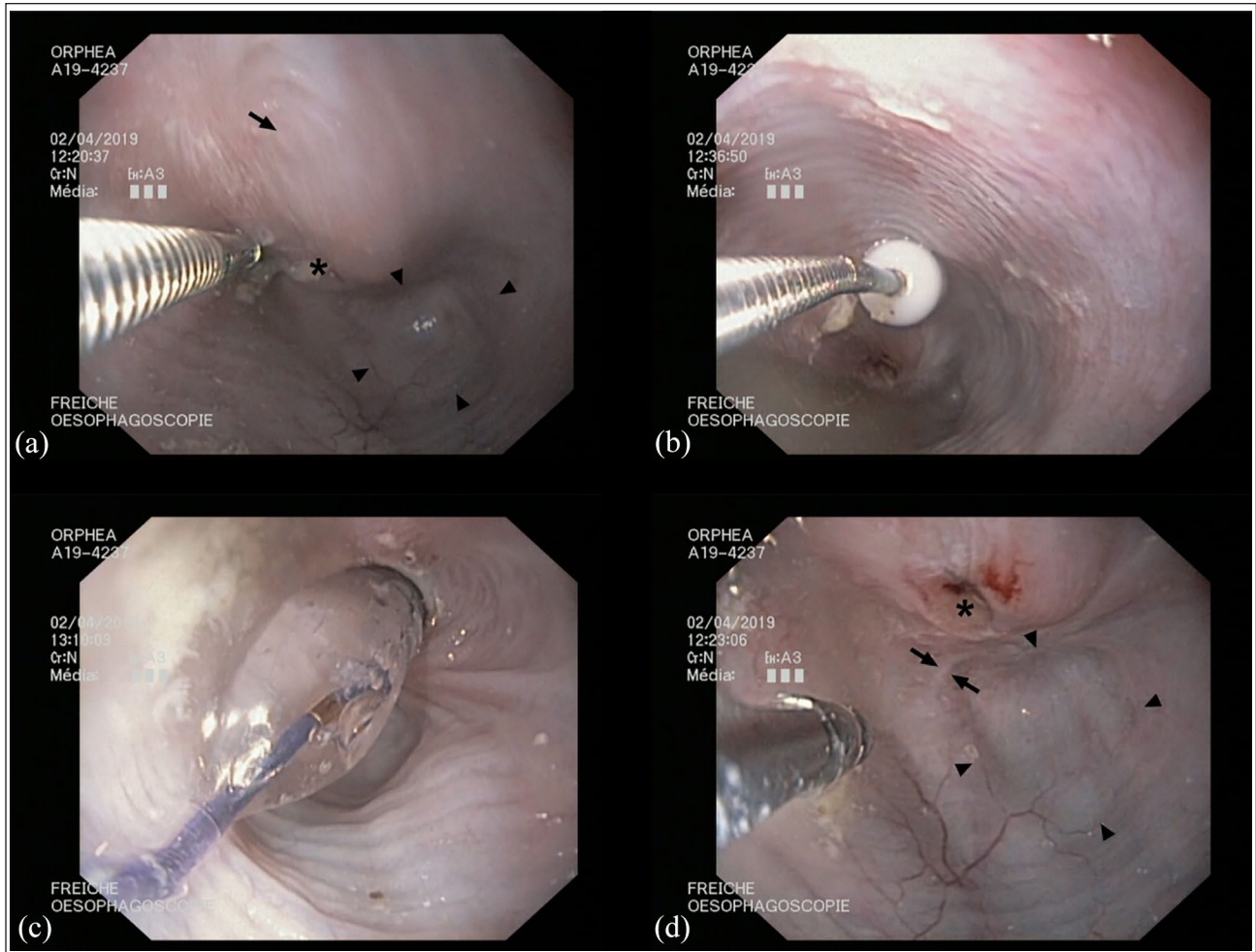


Figure 2 Endoscopic view of the stricture (asterisks), the oesophageal diverticulum (arrowheads) and cicatricial fibrosis suggestive of a peptic stenosis (arrows), (a) before balloon dilation attempts. (b) The diameter of the stricture was estimated to be 3mm. (c) Attempts to pass through the stricture and dilate using balloon devices were unsuccessful. (d) Note the slight and non-significant improvement of the stricture after balloon dilation attempts

approximately 10cm into the lumen of the stomach, to feed the patient while protecting oesophageal wounds, and keeping the stricture open and dilated. Overall anaesthesia and procedure durations were 140 and 80 mins, respectively.

Postoperative analgesia (buprenorphine 20 µg/kg IV q8h [Bupaq; Virbac]) was administered for 3 days. Treatment including maropitant (1 mg/kg IV q24h [Cerenia; Zoétis]), pantoprazole (1 mg/kg IV q12h [Inipomp, Takeda]) and sucralfate (0.5g PO q8h [Ulcars; Sanofi]) was started immediately after surgery. A nutritional plan was prescribed, divided into four feedings a day of Recovery Liquid (Royal Canin) as a total of 150ml a day through the oesophagostomy tube for 15 days. Recovery from surgery was otherwise uneventful. Follow-up endoscopy at 6 days postoperatively revealed no procedural complication (eg, mural necrosis and leakage) (Figure 3). The endoscope was passed easily

through the cardia. Mucosal healing was judged to be satisfactory and the cat was discharged from hospital.

The patient was reported to be stable at home. The oesophagostomy feeding tube was removed after a period of 15 days, following which the cat appeared to be comfortable. The cat was able to eat wet and dry food without regurgitating, and is still doing so at the time of writing this report (12-month follow-up). As food-responsive gastropathy was suspected, a dietary change for a hydrolysed source of protein (Specific FDD HY; Dechra) was implemented. Marked weight gain (2kg) was reported. Follow-up endoscopic examinations were performed both 1 and 3 months after surgery. No stricture was noted, and the oesophageal diverticulum was no longer noticeable. The endoscope was passed easily through the cardia at both time points (Figure 4). Moreover, at the 1-month follow-up, serial contrasted thoracic radiographs taken by the referring

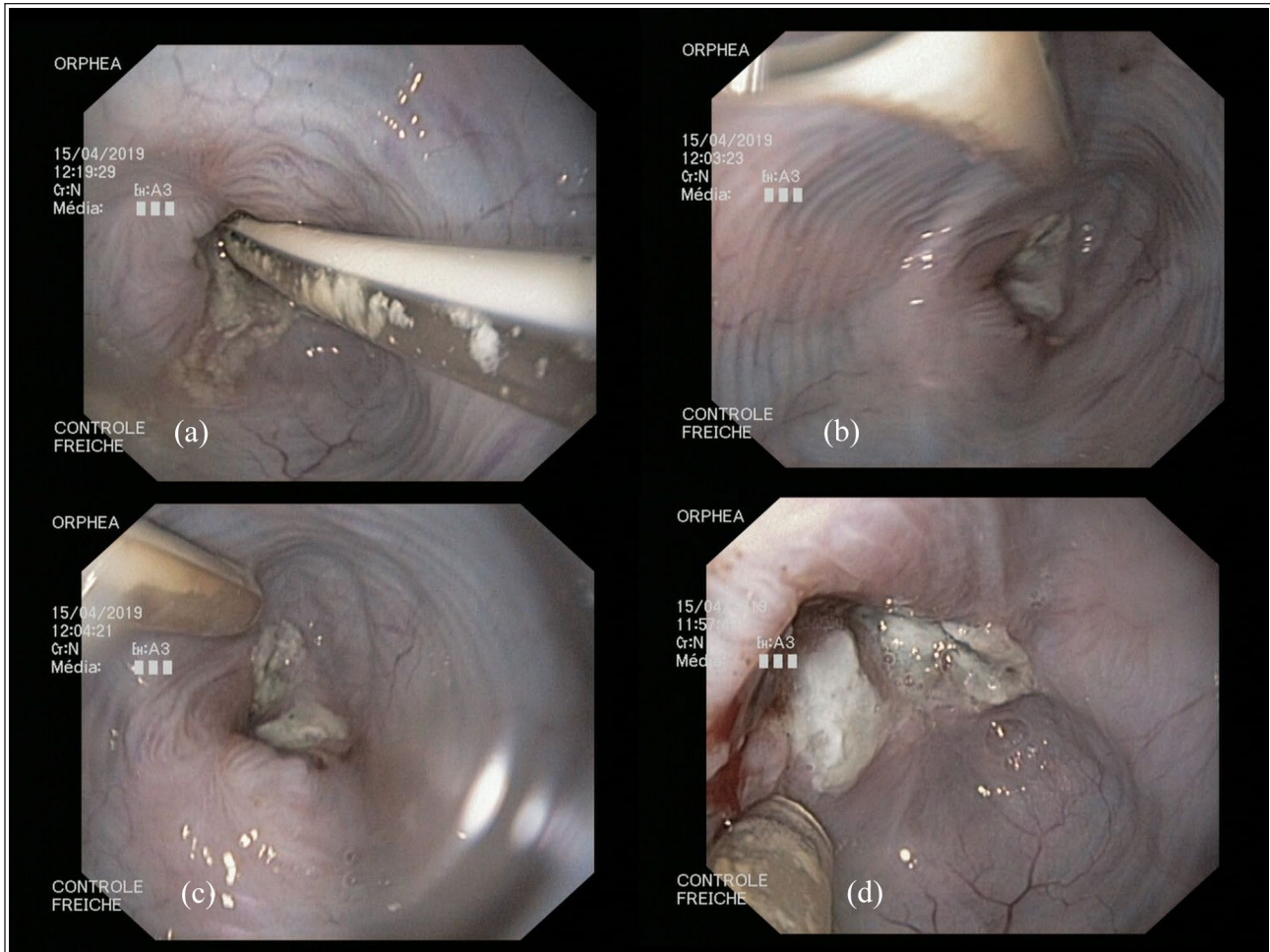


Figure 3 Follow-up endoscopy 6 days postoperatively. (a) Note the oesophagostomy tube that was placed through the cardia and (b–d) withdrawn for further examination. Note the small amount of fibrinous material, consistent with the recent surgery. The epiphrenic diverticulum is detectable when the oesophagus is maximally inflated

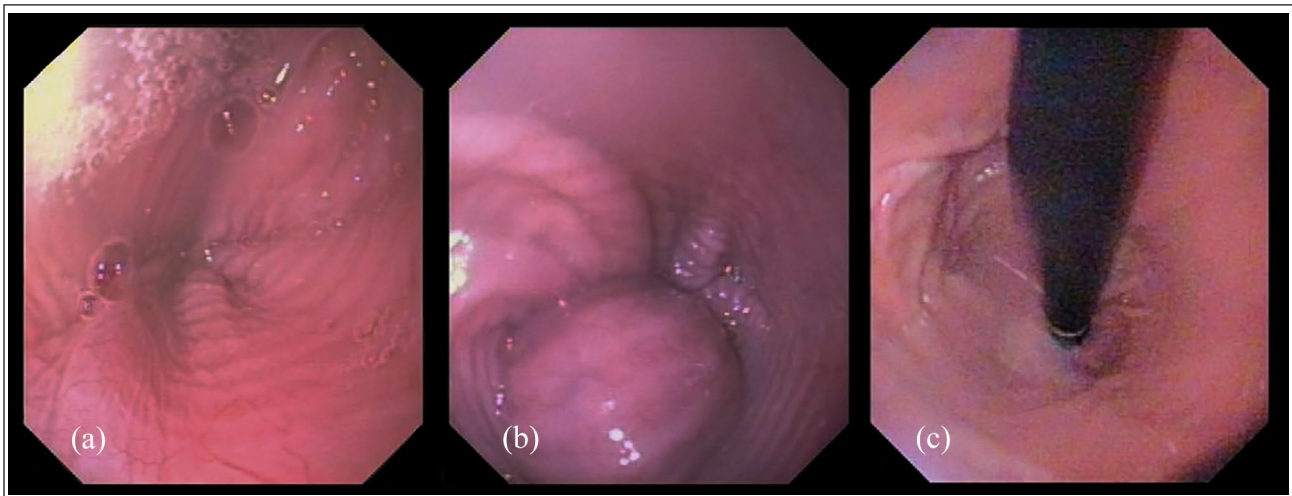


Figure 4 Follow-up endoscopy 1 month postoperatively. The cardia is examined from the (a,b) oesophagus and (c) stomach using a retrovision. *Courtesy of Dr C Muller*

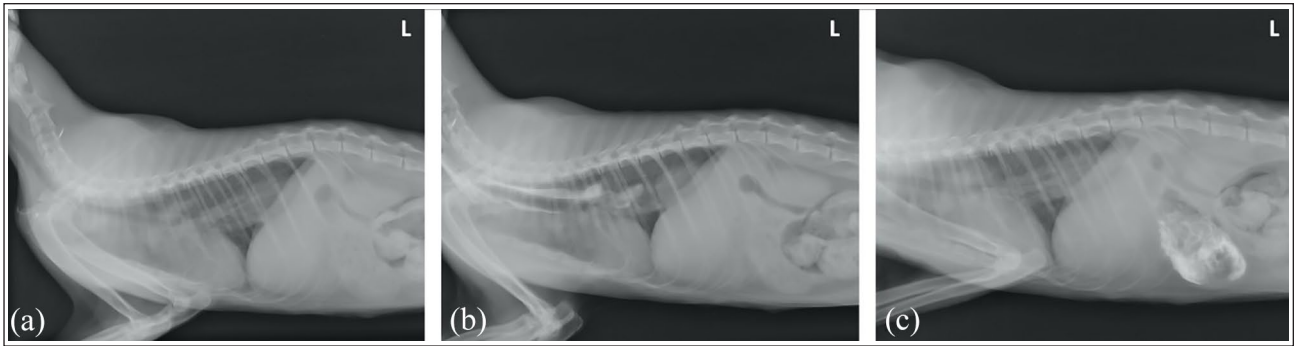

Figure 5 Follow-up left lateral contrast thoracic radiographs, 1 month after surgery: (a) before contrast medium administration, and (b) 5 s and (c) 1 min after contrast medium administration. The dilatation of the oesophagus was reduced and food stagnation was no longer observed. *Courtesy of Dr C Muller*

veterinarian showed reduction of the oesophageal distension (Figure 5). Antacid treatment was discontinued 6 weeks postoperatively.

Discussion

Strictures are one of the most frequent causes of oesophageal dysphagia and regurgitations in cats.¹ However, this case report is only the second description of an acquired lower oesophageal stricture causing diffuse megaesophagus in a kitten and, to our knowledge, the first mention of surgery as an alternative treatment for refractory lower oesophageal strictures in cats.

We think it is most likely that the stricture in the cat presented herein was acquired, and of chemical origin, secondary to irritation from gastric acid in the context of chronic vomiting, which was reported between the ages of 3 and 5 months. Other origins for oesophageal strictures in cats include gastroesophageal reflux (mostly occurring during anaesthesia owing to reduced cardiac tonus), oral administration of caustic drugs such as doxycycline or clindamycin, or a foreign body causing mucosal lesions.² A congenital stenosis could not be definitively ruled out. Partial oesophageal atresia or congenital stricture have been described in neonates and could also have appeared as a differential diagnosis.³ However, both these hypotheses seemed discordant with normal food intake in the first months of the kitten's life and the late onset of regurgitations (at the age of 5 months). A biopsy on the site of stricture might have helped understanding its origin but was not performed in our case.

Chronic vomiting in this kitten may have been attributable to food-responsive gastropathy, as no episode of vomiting was reported after dietary modification. Although histological examination of the gastric biopsies was within normal limits, it is usually recommended to perform at least six gastric endoscopic biopsies in cats, in order to achieve representativity.⁴ Only two incisional, full-thickness biopsies were performed in our cat: this be considered insufficient to establish an accurate

diagnosis. However, food-responsive enteropathy or gastropathy does not necessarily rely on histopathological evaluation, but rather on a positive response to a dietary modification, and no episode of vomiting has been reported in our cat since its food was switched to a novel protein diet.

Distal oesophageal obstructions are not routinely mentioned in the differential diagnosis of megaesophagus, especially in cats. Among oesophageal obstructive disorders, lower oesophageal sphincter achalasia is a primary oesophageal motility disorder. It results from a selective loss of inhibitory myenteric neurons causing failure of the lower oesophageal sphincter to relax in response to a pharyngeal swallow, leading to functional obstruction of the oesophagogastric junction.⁵ The disease has been sporadically reported either as suspected or as confirmed in both dogs⁶⁻¹⁰ and cats^{11,12} presenting with megaesophagus. In the present case, the endoscopic aspect of the oesophagogastric junction was characteristic of a stricture, and the decreased oesophageal motility that was suspected on contrasted swallow studies was supposed to be secondary to chronic oesophageal distension due to food stagnation. Thus, achalasia was not retained as a possible hypothesis. However, human literature reports possible misdiagnosis between lower oesophageal achalasia and stricture,¹³ even when endoscopic lesions are highly evocative of the latter. Therefore, functional examinations (eg, real-time oesophageal manometry studies^{7,14}) are sometimes recommended to rule out achalasia because other subjective criteria (eg, can the endoscope pass through the cardia or not?) may lack accuracy.¹³ Among causes of distal oesophageal obstructive disorders, neoplasms of the gastric cardia are known to cause megaesophagus in dogs,¹⁵ but, to our knowledge, have not been reported in cats, and would have been unexpected in such a young patient.

Other causes of megaesophagus (eg, congenital megaesophagus, hypothyroidism, polymyopathy or polyneuropathy) have not been excluded in the case

presented herein. Nevertheless, such causes were judged implausible after endoscopic examination, and regarding the age and history of the patient. In addition, no clinical signs of dysautonomia or myasthenia gravis were reported. Evaluation of serum thyroxine and thyroid-stimulating hormone levels, baseline cortisol and acetylcholine receptor antibodies might have helped excluding other causes of megaesophagus. Similar to what has been previously reported, it is important to note that without an endoscopic examination, history and medical imaging could have erroneously led to the diagnosis of a congenital megaesophagus. In cases of congenital megaesophagus, euthanasia is frequently elected owing to poor prognosis and quality of life. It should therefore be recommended to rule out a distal oesophageal stricture with an endoscopic evaluation in young cats presented with megaesophagus.

A lower oesophageal stricture has been recently described as a cause of megaesophagus in a kitten, presenting a narrow distal stenosis comparable to ours.¹⁶ Similar to the case presented herein, the stenotic canal was initially too narrow to allow endoscopic balloon dilation. Because of the age and weight of the patient, a surgically placed gastrostomy tube was used to provide nutritional support while waiting for the cat to grow. A natural expansion of this stricture was noted as its size increased from 2 to 10 mm in diameter, making a classical balloon dilation possible 2 months after the first endoscopic examination. We chose to attempt an endoluminal therapeutic approach as a more direct surgical intervention rather than a strategy that would have been less invasive but that would have required a lot more time and multiple balloon dilations.

In our case, mucosal radial incisions during gastrotomy permitted efficient and lasting loosening of the stricture. Such a surgical procedure has never been described in the cat. In human medicine, mucosal radial incisions are frequently performed with an endoscopically guided electrosurgical knife (eg, insulated-tipped knife).¹⁷ Other endoscopic alternatives to balloon dilation for the treatment of oesophageal strictures include endoscopically assisted circular incisions and cutting, use of cutting balloons, dilation with bougies and stent placement.¹⁸ Incisional therapies and stenting are usually reserved for refractory cases.¹⁹ Of all the aforementioned techniques, only stent placement and cutting balloon dilation have been reported in companion animals.^{20–22} In our case, use of bougies, cutting balloon or balloon stenting were not an option because it was impossible to pass an instrument throughout the stricture owing to its very narrow diameter, and possibly because it might have not been rectilinear. Consequently, surgical endoluminal radial incisions technique was elected because it was considered to be the safest option. We think this approach can be considered in patients presenting lower oesophageal strictures close to the

oesophagogastric junction, in which balloon dilation has failed.

Epiphrenic diverticula are small sacculations arising just cranially to the lower oesophageal sphincter. They are believed to be caused by abnormal forces applied to a portion of the oesophageal wall, resulting in outpouching of mucosa through the muscular layer.²³ Thus, epiphrenic diverticula are frequently identified in humans presenting with lower oesophageal obstructions, especially achalasia.²⁴ Although diverticulectomy used to be considered as necessary in human medicine,²⁵ recent studies show that correction of the primary cause, without performing a diverticulectomy, may be sufficient to resolve clinical signs.²⁶ It is difficult to assess if the identified diverticulum would have been responsible for therapeutic failure in our case, had it not been specifically treated. Left-sided gastropexy has not been reported as a therapeutic option for epiphrenic diverticula. The procedure is considered well tolerated in cats,²⁷ and we hoped that exerting traction on the distal oesophagus would help to limit stagnation of food, thereby increasing the chances for the diverticulum to resolve. Retrospectively, in our case, it is more likely that the gastropexy has contributed to the resolution of clinical signs by increasing the anti-reflux barrier at the gastroesophageal junction, as previously described,²⁸ rather than by limiting food stagnation in the distal oesophagus.

Both duration of anaesthesia and invasiveness of the procedure are critical points in patients with high American Society of Anaesthesiologists scores, such as our young cat with megaesophagus. The total procedure duration was 80 mins, including gastrotomy, mucosal incisions, bougienage, iterative balloon dilations and gastropexy. In people, endoscopically assisted incisional techniques usually require less than 30 mins when performed by experienced manipulators.¹⁹ Concerning the gastropexy, an endoscopically assisted procedure has been described in veterinary medicine.²⁹ Although its duration is not clearly stated, we estimate it might approximately last 30 mins. Considering the lack of familiarity with endoscopic oesophageal surgery and the additional time required for endoscopic-assisted gastropexy, the procedure would be probably longer than if performed by traditional open surgical means: we think it is unlikely that an entire endoscopic approach would have been time-saving, despite definitely being less invasive.

Submucosal triamcinolone acetonide injections have been demonstrated to have a positive therapeutic effect in human studies when compared with balloon dilation alone, with decreased recurrence rates and increased time before recurrence.^{30,31} To date, only a few case reports have documented the use of intralesional corticosteroids after balloon dilation in veterinary literature.^{32–35} As triamcinolone acetonide is inexpensive, and because the procedure was estimated to be safe, triamcinolone submucosal injections were performed

in our case to maximise the odds of success. Triamcinolone submucosal injections should not yet be considered risk free, as major complications (mural necrosis, mediastinal abscess) have been described in people receiving intralesional corticosteroids injections after endoscopic submucosal dissections, for treatment of oesophageal cancer.³⁶ Further studies are needed to evaluate whether their use can be systematically advocated for the treatment of oesophageal strictures in cats.

To our knowledge, placement of a large-diameter oesophagostomy tube in order to avoid recurrence of the stricture has never been reported in the veterinary literature cats, despite occasional use in some institutions. It was well tolerated in our case. The large-diameter oesophagostomy tube was placed to help with keeping the previously strictured section wide enough during healing of the mucosal incisions it is hoped to prevent recurrence of the stenosis and allow moist food to transit to the stomach after tube removal. Further studies are needed to evaluate the usefulness of large diameter indwelling oesophagostomy tubes to prevent stricture recurrence after initial dilation in cats. The placement of an indwelling oesophageal balloon dilation feeding tube ('B-tube') would have allowed iterative dilations³⁷ but was not available at the time of admission. Use of a B-tube has never been reported in this context, and one might worry that iterative dilations after initial mucosal radial incision could lead to pressure necrosis or further disruption of the gastroesophageal junction and anti-reflux barrier.

Conclusions

The present case report is the second description of an acquired lower oesophageal stricture causing diffuse megaesophagus associated with a distal diverticulum in a kitten. As previously reported, without endoscopic examination, history and medical imaging could have led to the incorrect diagnosis of a congenital megaesophagus, which may have led to euthanasia. Endoscopic examination should be considered in kittens with a history of vomiting presenting with regurgitations to rule out lower oesophageal obstruction, and particularly lower oesophageal stricture. Mucosal radial incisions followed by bougienage and/or balloon dilation can be considered for treatment of strictures of the gastroesophageal junction that are refractory to initial balloon dilation.

Acknowledgements We thank the referring veterinarian, Dr Claude Muller, for initial care and follow-up.

Conflict of interest The authors declared no potential conflicts of interest with respect to the research, authorship or publication of this case report.

Funding The authors received no financial support for the research, authorship or publication of this case report.

Ethical approval This work involved the use of non-experimental animals only (including owned or unowned animals and data from prospective or retrospective studies). Established internationally recognised high standards ('best practice') of individual veterinary clinical patient care were followed. Ethical approval from a committee was therefore not specifically required for publication in *JFMS Open Reports*.

Informed consent Informed consent (either verbal or written) was obtained from the owner or legal custodian of all animal(s) described in this work (either experimental or non-experimental animals) for the procedure(s) undertaken (either prospective or retrospective studies). No animals or humans are identifiable within this publication and therefore additional informed consent for publication was not required.

ORCID iD Maxime Kurtz  <https://orcid.org/0000-0003-4494-2975>

References

- Moses L, Harpster NK, Beck KA, et al. **Esophageal motility dysfunction in cats: a study of 44 cases.** *J Am Anim Hosp Assoc* 2000; 36: 309–312.
- Adamama-Moraitou KK, Rallis TS, Prassinos NN, et al. **Benign esophageal stricture in the dog and cat: a retrospective study of 20 cases.** *Can J Vet Res* 2002; 66: 55–59.
- Dingemann C, Eaton S, Aksnes G, et al. **ERNICA consensus conference on the management of patients with esophageal atresia and tracheoesophageal fistula: diagnostics, preoperative, operative, and postoperative management.** *Eur J Pediatr Surg* 2020; 30: 326–336.
- Couëtill L, Hoffman A, Hodgson J, et al. **ACVIM consensus statement: endoscopic, biopsy, and histopathologic guidelines for the evaluation of gastrointestinal inflammation in companion animals.** *J Vet Intern Med* 2007; 21: 356–361.
- Furuzawa-Carballeda J, Torres-Landa S, Valdovinos MÁ, et al. **New insights into the pathophysiology of achalasia and implications for future treatment.** *World J Gastroenterol* 2016; 22: 7892–7907.
- Earlam RJ, Zollman PE and Ellis FH. **Congenital oesophageal achalasia in the dog.** *Thorax* 1967; 22: 466–472.
- Kempf J, Heinrich H, Reusch CE, et al. **Evaluation of esophageal high-resolution manometry in awake and sedated dogs.** *Am J Vet Res* 2013; 74: 895–900.
- Kempf J, Beckmann K and Kook PH. **Achalasia-like disease with esophageal pressurization in a myasthenic dog.** *J Vet Intern Med* 2014; 28: 661–665.
- Dye C, Fina C and Brissot H. **Distal esophageal sphincter achalasia in a Labrador retriever dog with polypoid gastric mucosal hyperplasia and pyloric stenosis.** *Can Vet J* 2019; 60: 1183–1188.
- Diamant N, Szczepanski M and Mui H. **Manometric characteristics of idiopathic megaesophagus in the dog: an unsuitable animal model for achalasia in man.** *Gastroenterology* 1973; 65: 216–223.
- Clifford DH, Soifer FK, Wilson CF, et al. **Congenital achalasia of the esophagus in four cats of common ancestry.** *J Am Vet Med Assoc* 1971; 158: 1554–1560.
- Cawley AJ and Gendreau CL. **Esophageal achalasia in a cat.** *Can Vet Med Assoc* 1969; 10: 195–197.

- 13 Hocking MP, Ryckman FC and Woodward ER. **Achalasia mimicking peptic esophageal stricture.** *Am Surg* 1985; 51: 563–566.
- 14 Kahrilas PJ, Bredenoord AJ, Fox M, et al. **Expert consensus document: advances in the management of oesophageal motility disorders in the era of high-resolution manometry: a focus on achalasia syndromes.** *Nat Rev Gastroenterol Hepatol* 2017; 14: 677–688.
- 15 Fabres V, Jolivet F, Massal M, et al. **Megaesophagus associated with gastro-oesophageal junction neoplasia in dogs: 7 cases (2004–2016)** [abstract]. *J Vet Intern Med* 2018; 32: 525–609.
- 16 Schneider J, Ames M, DiCicco M, et al. **Recovery of normal esophageal function in a kitten with diffuse megaesophagus and an occult lower esophageal stricture.** *J Feline Med Surg* 2015; 17: 557–561.
- 17 Muto M, Ezoe Y, Yano T, et al. **Usefulness of endoscopic radial incision and cutting method for refractory esophago-gastric anastomotic stricture (with video).** *Gastrointest Endosc* 2012; 75: 965–972.
- 18 Van Boeckel PGA and Siersema PD. **Refractory esophageal strictures: what to do when dilation fails.** *Curr Treat Options Gastroenterol* 2015; 13: 47–58.
- 19 Samanta J. **Endoscopic incisional therapy for benign esophageal strictures: technique and results.** *World J Gastrointest Endosc* 2015; 7: 1318. DOI: 10.4253/wjge.v7.i19.1318.
- 20 Glanemann B, Hildebrandt N, Schneider MA, et al. **Recurrent single oesophageal stricture treated with a self-expanding stent in a cat.** *J Feline Med Surg* 2008; 10: 505–509.
- 21 Battersby I and Doyle R. **Use of a biodegradable self-expanding stent in the management of a benign oesophageal stricture in a cat.** *J Small Anim Pract* 2010; 51: 49–52.
- 22 Gallagher AE and Specht AJ. **The use of a cutting balloon for dilation of a fibrous esophageal stricture in a cat.** *Case Reports Vet Med* 2013; 2013. DOI: 10.1155/2013/467806.
- 23 Richter JE and Achkar E. **Advances in GERD esophageal diverticula.** *Gastroenterol Hepatol N Y* 2008; 4: 691–693.
- 24 Fisichella PM, Jalilvand A and Dobrowolsky A. **Achalasia and epiphrenic diverticulum.** *World J Surg* 2015; 39: 1614–1619.
- 25 Tedesco P, Fisichella PM, Way LW, et al. **Cause and treatment of epiphrenic diverticula.** *Am J Surg* 2005; 190: 902–905.
- 26 Westcott CJ, O'Connor S, Preiss JE, et al. **Myotomy-first approach to epiphrenic esophageal diverticula.** *J Laparoendosc Adv Surg Tech* 2019; 29: 726–729.
- 27 Phillips H, Corrie J, Engel DM, et al. **Clinical findings, diagnostic test results, and treatment outcome in cats with hiatal hernia: 31 cases (1995–2018).** *J Vet Intern Med* 2019; 33: 1970–1976.
- 28 Pratschke KM, Bellenger CR, McAllister H, et al. **Barrier pressure at the gastroesophageal junction in anesthetized dogs.** *Am J Vet Res* 2001; 62: 1068–1072.
- 29 Dujowich M and Reimer SB. **Evaluation of an endoscopically assisted gastropexy technique in dogs.** *Am J Vet Res* 2008; 69: 537–541.
- 30 Randhawa FA, Butt NF, Talat SO, et al. **Effectiveness of intralesional steroid injections with dilatation in corrosive oesophageal strictures – a randomized control trial.** *J Pak Med Assoc* 2018; 68: 1556–1559.
- 31 Qi L, He W, Yang J, et al. **Endoscopic balloon dilation and submucosal injection of triamcinolone acetonide in the treatment of esophageal stricture: a single-center retrospective study.** *Exp Ther Med* 2018; 16: 5248–5252.
- 32 Chavkin JA, Spector DJ and Stanley SW. **Balloon dilation and intralesional steroid for benign rectal stricture management in a cat.** *J Feline Med Surg* 2010; 12: 663–665.
- 33 Fraune C, Gaschen F and Ryan K. **Intralesional corticosteroid injection in addition to endoscopic balloon dilation in a dog with benign oesophageal strictures.** *J Small Anim Pract* 2009; 50: 550–553.
- 34 Berent AC, Kinns J and Weisse C. **Balloon dilatation of nasopharyngeal stenosis in a dog.** *J Am Vet Med Assoc* 2006; 229: 385–388.
- 35 Webb CB, McCord KW and Twedt DC. **Rectal strictures in 19 dogs: 1997–2005.** *J Am Anim Hosp Assoc* 2007; 43: 332–336.
- 36 Yamashita S, Kato M, Fujimoto A, et al. **Inadequate steroid injection after esophageal ESD might cause mural necrosis.** *Endosc Int Open* 2019; 7: E115–E121. DOI: 10.1055/a-0781-2333.
- 37 Tan DK, Weisse C, Berent A, et al. **Prospective evaluation of an indwelling esophageal balloon dilatation feeding tube for treatment of benign esophageal strictures in dogs and cats.** *J Vet Intern Med* 2018; 32: 693–700.