



Electrochemotherapy as a treatment option for feline nasal melanoma

Authors: Little, Annika, and Macfarlane, Michael

Source: Journal of Feline Medicine and Surgery Open Reports, 8(1)

Published By: SAGE Publishing

URL: <https://doi.org/10.1177/20551169221074231>

BioOne Complete (complete.BioOne.org) is a full-text database of 200 subscribed and open-access titles in the biological, ecological, and environmental sciences published by nonprofit societies, associations, museums, institutions, and presses.

Your use of this PDF, the BioOne Complete website, and all posted and associated content indicates your acceptance of BioOne's Terms of Use, available at www.bioone.org/terms-of-use.

Usage of BioOne Complete content is strictly limited to personal, educational, and non - commercial use. Commercial inquiries or rights and permissions requests should be directed to the individual publisher as copyright holder.

BioOne sees sustainable scholarly publishing as an inherently collaborative enterprise connecting authors, nonprofit publishers, academic institutions, research libraries, and research funders in the common goal of maximizing access to critical research.



Electrochemotherapy as a treatment option for feline nasal melanoma

Annika Little and Michael Macfarlane

Journal of Feline Medicine and Surgery Open Reports
1–5

© The Author(s) 2022

Article reuse guidelines:

sagepub.com/journals-permissions

DOI: 10.1177/20551169221074231

journals.sagepub.com/home/jfmsopenreports

This paper was handled and processed by the European Editorial Office (ISFM) for publication in *JFMS Open Reports*



Abstract

Case summary A 4-year-old domestic shorthair cat presented to North Downs Specialist Referrals for treatment of a 7 mm melanoma of the nasal planum. Two treatments of electrochemotherapy using intravenous bleomycin as a chemotherapeutic agent were administered. The tumour was no longer visible after treatment. At the 292-day follow-up there was no recurrence at the site and the patient was clinically well.

Relevance and novel information There are few data concerning the outcomes of cats with non-ocular feline melanomas and there are currently minimal descriptions in the literature of electrochemotherapy as a treatment option. The available data suggest that nasal melanoma may have a worse prognosis, and that melanomas are locally invasive and have a high propensity for metastasis. The current most effective means for local control is surgery with wide margins. Given the location in this case, this would have required nasal planectomy, while electrochemotherapy provided an effective and possibly more attractive alternative.

Keywords: Electrochemotherapy; nasal planum melanoma; bleomycin; melanoma treatment options

Accepted: 24 December 2021

Case description

A 4-year-old neutered female domestic shorthair cat presented to the primary care veterinarian for a 5 mm diameter mass affecting the right side of the nose, just distal to the planum. A wedge biopsy was taken from the mass at the primary care veterinarian on initial presentation, and was sent to Nationwide Laboratories, where it was diagnosed on histology as melanoma. The histology showed 11 mitoses within 10 high-power fields. This was consistent with a 'high-grade melanoma', based on the histological classification scheme for non-ocular feline melanoma.¹ The cat was referred to the oncology department at North Downs Specialist Referrals for treatment. Concern was raised by the rapid growth of the mass, which had increased from 5 to 7 mm in the 2 weeks between initial presentation and treatment (Figure 1).

The cat was not clinically affected by the mass. A full clinical examination yielded no other concerns, and there was no other pertinent medical history.

Blood samples were collected for routine haematology and a serum biochemical panel; all results were within normal limits. There was no palpable lymphadenopathy;

however, no needle samples were taken from local lymph nodes.

A 22G intravenous catheter was placed in the left cephalic vein. A premedication of 0.005 mg/kg medetomidine (Sedator 1 mg/ml; Dechra) and 0.2 mg/kg methadone (Synthadon 10 mg/ml; Animalcare) was given, which gave good sedation. The patient was induced with propofol (Propofol-Lipuro Vet 10 mg/ml; Virbac) to effect (2 mg/kg was required). The patient was intubated with a size 3.5 endotracheal tube, which was subsequently cuffed.

Orthogonal inflated radiographs were taken of the chest and reviewed; no signs of chest metastases were visible radiographically.

North Downs Specialist Referrals, Bletchingley, UK

Corresponding author:

Annika Little BVMS(Hons), MRCVS, North Downs Specialist Referrals, 3 & 4 The Brewerstreet Dairy Business Park, Brewer St, Bletchingley RH1 4QP, UK
Email: annika.little@ndsr.co.uk



Creative Commons Non Commercial CC BY-NC: This article is distributed under the terms of the Creative Commons

Attribution-NonCommercial 4.0 License (<https://creativecommons.org/licenses/by-nc/4.0/>) which permits non-commercial use, reproduction and distribution of the work without further permission provided the original work is attributed as specified on the SAGE and Open Access pages (<https://us.sagepub.com/en-us/nam/open-access-at-sage>).

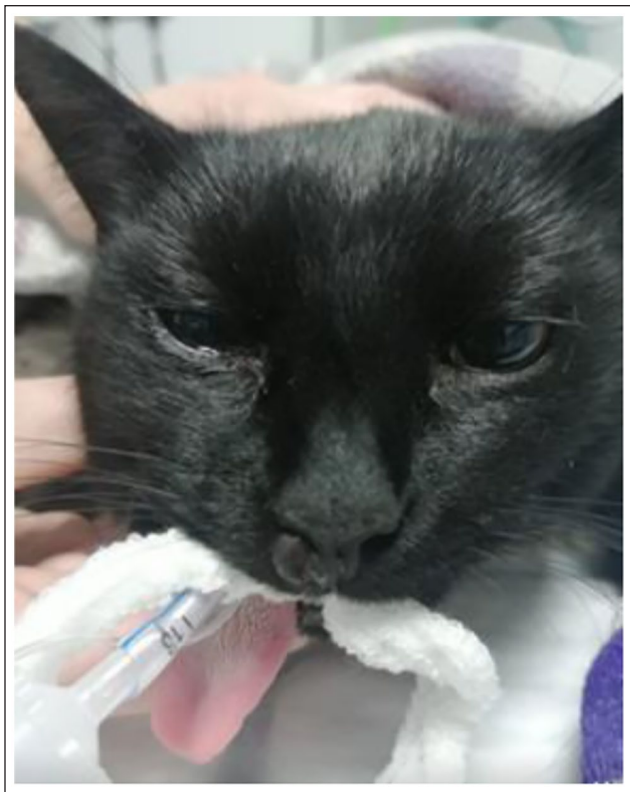

Figure 1 Mass prior to initial treatment; it was 7 mm in diameter and affected the right side of the nose, just distal to the planum

Bleomycin was injected intravenously as a bolus at a dose of 20 mg/m². Pulses were generated using an electroporator certified for veterinary use (Onkodisruptor). Contact between the patients and the electrodes (M1 clamp electrodes; Onkodisruptor) was optimised using an electroconductive gel. Five minutes after the chemotherapy injections, the sequences of eight biphasic pulses (two phases of 50 µs given in each pulse of electricity) were delivered in bursts of 1200 V/cm.

The general anaesthetic was stable. Recovery was slow but uneventful. Atipamezole 0.001 mg/kg (Atipam 5.0 mg/ml; Dechra) was given intramuscularly prior to extubation. The patient was discharged later the same day. No acute-onset side effects were noted during or after the procedure.

The patient was discharged with a 5 day course of meloxicam at 0.05 mg/kg PO q24h (Metacam 0.5 mg/ml oral suspension for cats; Boehringer Ingelheim). A rigid Elizabethan collar was also dispensed to prevent any self-trauma to the area.

The patient returned 2 weeks later for a second course of electrochemotherapy (ECT). The owners had reported tumour shrinkage from the initial ECT session, with some local inflammation and crusting. The patient's owner reported that the Elizabethan collar was not used at home as the patient had not shown any interest in the

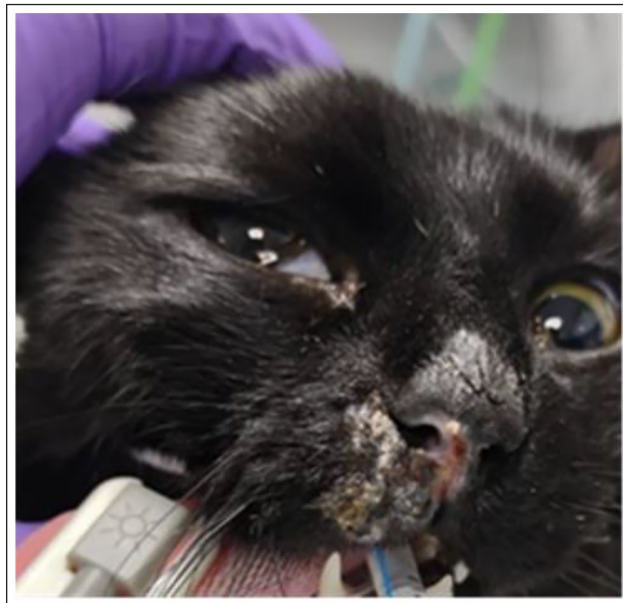


Figure 2 Tumour shrinkage 2 weeks after the initial electrochemotherapy session. Some local inflammation and crusting was present

area, and there had been no self-trauma, with the patient being closely supervised (Figure 2).

An identical general anaesthesia and ECT protocol was repeated for the second session. Again, the anaesthesia and procedure were smooth and recovery was uneventful. The patient was discharged the same day with no concerns. A rigid Elizabethan collar was dispensed should it be required, but the owner again reported that it was not indicated as the patient showed no interest in the site. Following the second course of ECT, the oral course of meloxicam was repeated and extended to a more protracted course of 2 weeks (0.05 mg/kg PO q24h) owing to sneezing being noted at home, as well as local inflammation and crusting over the site (Figure 3). However, the patient was back to its normal self within 3 weeks of the second ECT treatment, with complete resolution of the mass, as well as the local crusting and inflammation.

Six months after ECT treatment, there was no recurrence of tumour growth at the site of the original mass. There was a local area of alopecia and mild thickening of skin at the site (Figure 4). The cat was clinically well, and there was no palpable lymphadenopathy or abnormalities on clinical examination. At the time of writing, 292 days (9 months) from the second ECT treatment, the patient continues to do very well clinically, with no clinical signs or recurrence of the mass.

Discussion

Melanomas are tumours that arise from an uncontrolled proliferation of melanocytes or their precursors, cells that generate the pigment melanin via the melanosome.^{2,3}

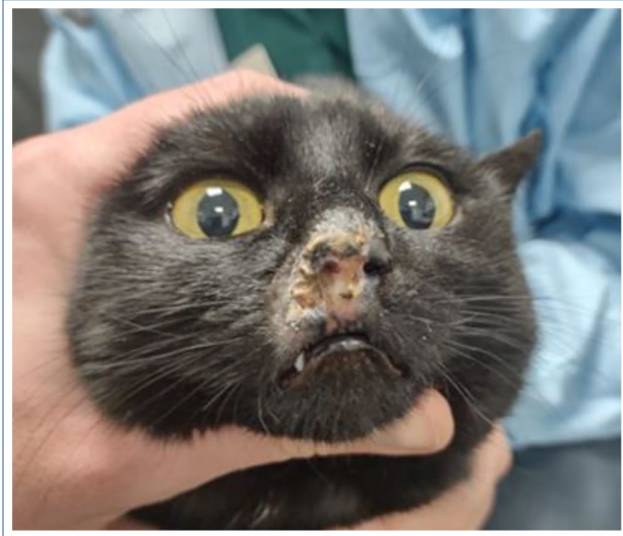


Figure 3 Nasal planum 2 weeks after the second electrochemotherapy session. Inflammation and crusting were present. The cat was clinically bright but sneezing



Figure 4 Six months after electrochemotherapy treatment. There is a local area of alopecia and mild thickening of skin at the site

In humans, the incidence of melanoma has been increasing over the last 50 years. Despite accounting for <5% of cutaneous human malignancies, they are the leading cause of human skin cancer deaths, owing to their propensity for metastasis.^{3,4} ECT is an effective treatment for cutaneous metastasis of melanoma in humans, resulting in a tumour response (complete or partial response) in 74% of over 2000 tumours in

500 patients.⁵ Furthermore, the results of the ESOPE study (European Standard Operating Procedures of Electrochemotherapy) found that there was no variance in the efficacy of ECT with the size of the nodule in the treatment of cutaneous and subcutaneous tumour nodules of human patients with malignant melanoma.⁶ Melanomas are also a common neoplasm in dogs, and account for the highest incidence of oral neoplasms in this species,^{2,7,8} where ECT has also been described as an effective treatment option.⁹

Conversely, melanocytic neoplasms are rarer in the cat, although generally malignant.^{2,7,8} The most common predilection site is in the eye and melanoma is the most common intraocular mass in the cat.^{7,8} There are few data concerning outcomes for non-ocular feline melanomas.¹ Hence, the information available for the clinical presentation, biological behaviour and treatment of these tumours in clinical practice is very limited. In a retrospective case series of 10 cats with melanocytic tumours of the nasal planum, pigmentation of the nasal planum was found to be a predisposing factor.¹⁰ The cat in this case study also had a pigmented nasal planum.

Prior to proceeding with the ECT protocol outlined in this case report, the current treatment options available for feline melanoma were discussed with the owners.

There is currently no set treatment recommendation for feline melanoma in general. In a retrospective study of 30 non-ocular melanomas in cats, the cats that had surgical excision survived for significantly longer than cats that received medical treatment only.⁷ However, given the location on the nasal planum in this case, surgical treatment would require a radical nasal planectomy. One previous case study of a nasal melanoma in a cat showed that nasal planectomy was a successful treatment with no recurrence at 5 years.¹¹ In this case, the owners found surgery an unacceptable option owing to its radical and invasive nature, as well as concerns regarding the cosmetic outcome, and so this was not pursued.

Hypofractionated radiation has been minimally explored in the treatment of feline melanoma. One study in five cats found some responsiveness to the radiation protocol in oral malignant melanoma; however, this response was not found to be durable, and all cats in the study went on to be euthanased owing to progression of disease, with the median survival time being 146 days.¹² In another study, six cats with nasal melanoma were treated with hypofractionated radiation, all of the cats treated showed tumour regression with treatment, with 50% showing a partial and 50% showing a complete response. However, in all cases, progression or recurrence of the tumour occurred within a short time frame (30, 43 and 92 days until tumour progression in the animals showing a partial response, and 84, 97 and 160 days until recurrence in the animals showing a complete

response, respectively). All animals were euthanased owing to progression of disease, which had caused clinical signs that reduced quality of life (anorexia, apathy and weight loss).¹⁰ At the time of writing, the patient reported herein is currently 9 months post-ECT treatment, with no local tumour recurrence and no clinical signs of disease, showing that, in this instance, ECT gave a significantly more durable response compared with hypofractionated radiation.

Immunotherapy in cancer treatment has evolved enormously over the past decade and has been used in the treatment of various different neoplasms in humans and animals, including canine malignant melanoma.¹³ The first licensed immunotherapeutic agent in veterinary medicine is the canine melanoma vaccine (Oncept; Merial). This is a xenogeneic human tyrosinase DNA vaccine licensed in dogs with stage II or III oral melanoma in which local disease control has already been achieved.¹⁴ This vaccine was also found to be well tolerated, with a minimal risk of adverse side effects in cats.¹⁵ The Oncept melanoma vaccine carries the advantage of ease of treatment, given that sedation or general anaesthesia is not required. There is controversy regarding its efficacy as, in retrospective studies, it has been found not to increase the median survival time in canine oral malignant melanoma.¹⁶ It was not considered to be an appropriate sole treatment modality in the outlined case, but was discussed as an adjunct to surgery or ECT with the aim of reducing the risk of recurrence. In this case, the significant financial implication of incorporating the vaccine as an adjunctive treatment meant that it was not used; however, this could be an area of potential interest for future studies of the treatment of feline cutaneous melanoma.

ECT is the use of chemotherapeutic drugs (bleomycin or cisplatin) combined with electric pulses at a high voltage. This causes a transient permeabilisation of the cell membrane, thus allowing entry of the chemotherapeutic drugs into the neoplastic cells. It is a treatment modality that is widely used in human oncology in the treatment of cutaneous and subcutaneous masses.⁶ ECT has also been shown to have good safety and efficacy in treating feline squamous cell carcinoma of the nasal planum.¹⁷

There is currently minimal literature describing ECT treatment for feline nasal melanoma. One case report describes the use of ECT combined with calcium electroporation (CaEP) for the treatment of a cat with cutaneous malignant melanoma with regional metastasis; the affected animal had a cutaneous peripalpebral plaque lesion, with submandibular lymph node enlargement. Five months of remission was achieved in that case (after two ECT and CaEP treatments), prior to the recurrence of disease in the retropharyngeal lymph node, confirmed by fine-needle aspiration. CaEP causes

calcium influx at supra-physiological levels into neoplastic cells, causing cell death by necrosis.¹⁸ The combination of these two novel cancer treatment modalities requires further investigations to understand their synergistic effect. That case suggests that both ECT and CaEP may be effective treatments for cutaneous melanoma in cats and, given the favourable response also seen in this case report, indicates further investigation of ECT as a treatment option for feline cutaneous melanoma.

Another case study outlined the use of nano-ECT as an adjunct after the CO₂ laser surgical removal of the bulk of an oral melanoma in a cat.¹⁹ Nano-ECT is a form of ECT that delivers a pulsed electric field with a duration of nanoseconds rather than microseconds,²⁰ as is more commonly used, and which was utilised in this case. In that case report the patient was treated with nanosecond pulses and bleomycin. The modality showed promise in that case as there was no recurrence of the primary mass 16 weeks after nano-ECT. However, the patient described already had metastatic disease to the local lymph node at initial presentation, and despite the control of the local mass the cat was euthanased for metastatic disease that caused a decline in general health 17 weeks after nano-ECT.

Although ECT is thus far minimally described in the literature, given some promising results in the two aforementioned case reports, it was deemed an appropriate treatment modality in this case, and is a treatment modality that merits further investigation. A major deficiency in this case report is that FNA sampling of local lymph nodes was not undertaken at presentation, indicating that local metastatic disease cannot be excluded. It was presumptively assumed that there was no spread to local lymph nodes as there was no palpable lymphadenopathy; however, cytology would have been the more appropriate course of action to confirm this. Direct comparison of this case reports results with the aforementioned two case reports is limited as in both previous case reports local lymph node metastases had been confirmed. Furthermore, ECT was used in conjunction with other modalities to achieve local control (CaEP and CO₂ laser surgical removal of mass bulk, respectively). In this case, at the time of writing, the patient had no mass recurrence or clinical signs at 292 days after the second ECT session, with ECT being the sole modality used to treat melanoma of the nasal planum.

Palliative care was also discussed, which would have involved pain relief when the tumour became painful, along with careful ongoing assessment of the patient's quality of life, which at the time of presentation was very good. Given the metastatic nature of the mass on histology and the known propensity of melanomas to cause metastatic disease, it would be prudent to assume that disease progression could have been swift. Median

survival of cats with melanocytic tumours arising within the oral cavity, lips or nose was found, in a retrospective study, to be 83 days.⁷ Hence, given that the patient is currently in remission 292 days after the second ECT session, ECT as a treatment protocol shows significant value in feline nasal melanoma.

Conclusions

ECT, to our knowledge, is not a currently described treatment option for feline melanoma of the nasal planum, although case reports exist of its use in combination with other modalities (one in a cat with oral melanoma, and the other in a cat with a peripalpebral melanoma). Given the positive outcome in this described case, further prospective studies are indicated to confirm the efficacy of ECT as a treatment modality, and to compare it with other available options, as a means of effective local control.

Conflict of interest The authors declared no potential conflicts of interest with respect to the research, authorship, and/or publication of this article.

Funding This work was supported by North Downs Specialist Referrals, part of Linnaeus Veterinary Limited.

Ethical approval This work involved the use of non-experimental animals only (including owned or unowned animals and data from prospective or retrospective studies). Established internationally recognised high standards ('best practice') of individual veterinary clinical patient care were followed. Ethical approval from a committee was therefore not specifically required for publication in *JFMS Open Reports*.

Informed consent Informed consent (verbal or written) was obtained from the owner or legal custodian of all animal(s) described in this work (experimental or non-experimental animals, including cadavers) for all procedure(s) undertaken (prospective or retrospective studies). No animals or people are identifiable within this publication, and therefore additional informed consent for publication was not required.

ORCID iD Annika Little  <https://orcid.org/0000-0001-9363-953X>

References

- Pittaway R, Dobromylskyj M, Erles K, et al. **Nonocular melanocytic neoplasia in cats: characterization and proposal of a histologic classification scheme to more accurately predict clinical outcome.** *Vet Pathol* 2019; 56: 868–877.
- Vail DM, Thamm DH and Liptak JM. *Withrow & MacEwen's small animal clinical oncology*. St Louis, MO: Elsevier, 2020.
- Matthews NH, Li W-Q, Qureshi AA, et al. **Epidemiology of melanoma.** In: *Cutaneous melanoma: etiology and therapy*. Singapore: Codon Publications, 2017, pp 3–22.
- Davis LE, Shalin SC and Tackett AJ. **Current state of melanoma diagnosis and treatment.** *Cancer Biol Ther* 2019; 20: 1366–1379.
- Wichtowski M and Murawa D. **Electrochemotherapy in the treatment of melanoma.** *Contemp Onkol (Pozn)* 2018; 22: 8–13.
- Marty M, Sersa G, Garbay J, et al. **Electrochemotherapy – an easy, highly effective and safe treatment of cutaneous and subcutaneous metastases: results of ESOPE (European Standard Operating Procedures of Electrochemotherapy) study.** *Eur J Cancer Suppl* 2006; 4: 3–13.
- Chamel G, Abadie J, Albaric O, et al. **Non-ocular melanomas in cats: a retrospective study of 30 cases.** *J Feline Med Surg* 2016; 19: 351–357.
- Patnaik AK and Mooney S. **Feline melanoma: a comparative study of ocular, oral, and dermal neoplasms.** *Vet Pathol* 1988; 25: 105–112.
- Tellado M, Maglietti F, Michinski S, et al. **Electrochemotherapy in treatment of canine oral malignant melanoma and factors influencing treatment outcome.** *Radiol Oncol* 2020; 54: 68–78.
- Reck A and Kessler M. **Melanocytic tumours of the nasal planum in cats: 10 cases (2004–2019).** *J Small Anim Pract* 2020; 62: 131–136.
- Kojimoto A, Itoh T, Uchida K, et al. **Malignant melanoma on the nasal planum treated with nasal planectomy in a cat.** *Jpn J Vet Anesth Surg* 2020; 51: 8–12.
- Farrelly J, Denman DL, Hohenhaus AE, et al. **Hypofractionated radiation therapy of oral melanoma in five cats.** *Vet Radiol Ultrasound* 2004; 45: 91–93.
- Almela R and Ansón A. **A review of immunotherapeutic strategies in canine malignant melanoma.** *Vet Sci* 2019; 6: 15.
- Biller B, Berg J, Garrett L, et al. **2016 AAHA oncology guidelines for dogs and cats.** *J Am Anim Hosp Assoc* 2016; 52: 181–204.
- Sarbu L, Kitchell BE and Bergman PJ. **Safety of administering the canine melanoma DNA vaccine (Oncept) to cats with malignant melanoma – a retrospective study.** *J Feline Med Surg* 2016; 19: 224–230.
- Otnod J, Smedley R, Walshaw R, et al. **A retrospective analysis of the efficacy of Oncept vaccine for the adjunct treatment of canine oral malignant melanoma.** *Vet Comp Oncol* 2013; 11: 219–229.
- Simčić P, Pierini A, Lubas G, et al. **A retrospective multicentric study of electrochemotherapy in the treatment of feline nasal planum squamous cell carcinoma.** *Vet Sci* 2021; 8: 53. DOI: 10.3390/vetsci8030053.
- Dos Anjos D, Rodrigues C, Silva N, et al. **Electrochemotherapy associated with calcium electroporation in metastatic feline cutaneous malignant melanoma.** *Acta Sci Vet* 2019; 47. DOI: 10.22456/1679-9216.96498.
- Tunikowska J, Antończyk A, Rembiałkowska N, et al. **The first application of nanoelectrochemotherapy in feline oral malignant melanoma treatment – case study.** *Animals* 2020; 10: 556. DOI: 10.3390/ani10040556.
- Beebe JS. **Mechanisms of nanosecond pulsed electric field (NsPEF)-induced cell death in cells and tumors.** *J Nanomed Res* 2015; 2. DOI: 10.15406/jnmr.2015.02.00016.