

Primary pulmonary diffuse large B-cell lymphoma associated with feline leukaemia virus infection in a young cat

Authors: Ishikawa, Kento, Nagashima, Tomokazu, Machida, Yukino, Yasuda, Akiko, Yoshida, Karin, et al.

Source: Journal of Feline Medicine and Surgery Open Reports, 8(1)

Published By: SAGE Publishing

URL: <https://doi.org/10.1177/20551169221074240>

The BioOne Digital Library (<https://bioone.org/>) provides worldwide distribution for more than 580 journals and eBooks from BioOne's community of over 150 nonprofit societies, research institutions, and university presses in the biological, ecological, and environmental sciences. The BioOne Digital Library encompasses the flagship aggregation BioOne Complete (<https://bioone.org/subscribe>), the BioOne Complete Archive (<https://bioone.org/archive>), and the BioOne eBooks program offerings ESA eBook Collection (<https://bioone.org/esa-ebooks>) and CSIRO Publishing BioSelect Collection (<https://bioone.org/csiro-ebooks>).

Your use of this PDF, the BioOne Digital Library, and all posted and associated content indicates your acceptance of BioOne's Terms of Use, available at www.bioone.org/terms-of-use.

Usage of BioOne Digital Library content is strictly limited to personal, educational, and non-commercial use. Commercial inquiries or rights and permissions requests should be directed to the individual publisher as copyright holder.

BioOne is an innovative nonprofit that sees sustainable scholarly publishing as an inherently collaborative enterprise connecting authors, nonprofit publishers, academic institutions, research libraries, and research funders in the common goal of maximizing access to critical research.



Primary pulmonary diffuse large B-cell lymphoma associated with feline leukaemia virus infection in a young cat

Journal of Feline Medicine and Surgery Open Reports
1–5

© The Author(s) 2022
Article reuse guidelines:
sagepub.com/journals-permissions
DOI: 10.1177/20551169221074240
journals.sagepub.com/home/jfmsopenreports

This paper was handled and processed by the European Editorial Office (ISFM) for publication in *JFMS Open Reports*



Kento Ishikawa¹, Tomokazu Nagashima^{1,2}, Yukino Machida¹, Akiko Yasuda², Karin Yoshida², Michio Fujita³, Kazuhiko Ochiai^{4,5}, Daigo Azakami⁶ and Masaki Michishita^{1,5}

Abstract

Case summary A 4-year-old castrated male domestic shorthair cat with a continuous cough was brought to a private veterinary clinic for detailed examination. Radiography of the thoracic cavity revealed a severe radiopaque region in the caudal lobe of the right lung. At 108 days after the initial visit, CT showed a mass of 27 × 23 × 18 mm in the caudal lobe of the right lung. At that time, no abnormalities in other organs except for the lung were detected on CT and peripheral blood and blood biochemistry tests. The mass in the caudal lobe of the right lung was resected by lobectomy; it had a white surface and was firm. Histopathologically, the mass was non-encapsulated, showing an unclear boundary with surrounding tissues. The mass comprised large, round or polygonal neoplastic cells arranged in a diffuse pattern. Immunohistochemically, neoplastic cells were diffusely positive for CD20, feline leukaemia virus (FeLV) p27 and FeLV glycoprotein 70 but negative for CD3, CD204 and E-cadherin. Based on these findings, diffuse large B-cell lymphoma associated with FeLV infection was diagnosed. Although the cat showed no clinical signs of gastrointestinal or respiratory injury, a routine ultrasonography revealed thickening in the jejunum wall 196 days after lobectomy, and subsequent fine-needle aspiration examination confirmed high-grade lymphoma.

Relevance and novel information This is the first report of primary pulmonary diffuse large B-cell lymphoma associated with FeLV infection in a young cat.

Keywords: B-cell lymphoma; feline leukaemia virus; gp70; lung; p27

Accepted: 24 December 2021

Case description

A 4-year-old castrated male domestic shorthair cat with a continuous cough was brought to a private veterinary clinic for detailed examination. Physical examination, complete blood count and routine serum biochemical profile indicated no abnormalities. The cat was annually vaccinated with a triple vaccine against the feline herpesvirus, feline calicivirus and feline parvovirus but not against the feline leukaemia virus (FeLV). Serological analysis for the FeLV antigen and for the antibody against the feline immunodeficiency virus (FIV) yielded positive results. Radiography of the thoracic cavity revealed a severely radiopaque region in the caudal lobe of the left lung. The cat was prescribed 7 mg/ml enrofloxacin (Baytril; Bayer) by a private veterinarian,

¹Department of Veterinary Pathology, Nippon Veterinary and Life Science University, Tokyo, Japan

²Veterinary Medical Center, Nippon Veterinary and Life Science University, Tokyo, Japan

³Division of Veterinary Radiology, Nippon Veterinary and Life Science University, Tokyo, Japan

⁴Department of Veterinary Hygiene, Nippon Veterinary and Life Science University, Tokyo, Japan

⁵Research Center for Animal Life Science, Nippon Veterinary and Life Science University, Tokyo, Japan

⁶Laboratory of Veterinary Clinical Oncology, Tokyo University of Agriculture and Technology, Tokyo, Japan

Corresponding author:

Masaki Michishita DVM, PhD, Diplomate JCVF, Department of Veterinary Pathology, Nippon Veterinary and Life Science University, 1-7-1 Kyouunan-chi, Musashino, Tokyo 180-8602, Japan
Email: michishita@nvlu.ac.jp



Creative Commons Non Commercial CC BY-NC: This article is distributed under the terms of the Creative Commons

Attribution-NonCommercial 4.0 License (<https://creativecommons.org/licenses/by-nc/4.0/>) which permits non-commercial use, reproduction and distribution of the work without further permission provided the original work is attributed as specified on the SAGE and Open Access pages (<https://us.sagepub.com/en-us/nam/open-access-at-sage>).

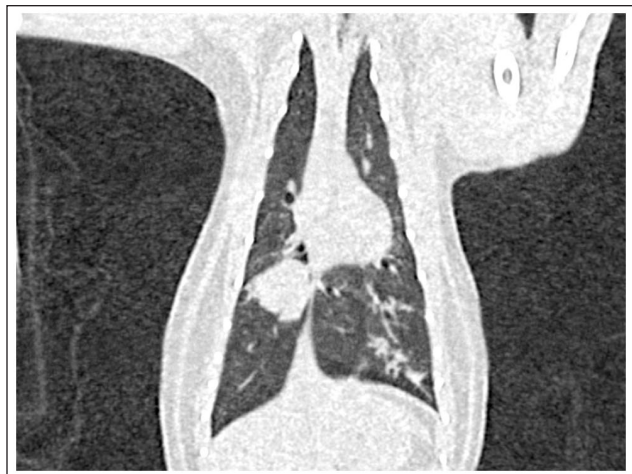

Figure 1 CT of the thoracic cavity revealed a mass measuring 27×23 cm in the caudal lobe of the right lung

and its clinical signs improved following the drug's administration.

At 48 days after the initial visit, the cat was brought to the Veterinary Medical Centre, Nippon Veterinary and Life Science University, with a recurrent cough for further detailed examination. Analysis for FeLV antigen (but not for the anti-FIV antibody) yielded a positive result on the same day; however, regular virus tests were not performed, at the request of the owner. At radiography, a radiopaque region was noted; bronchopneumonia was suspected in the caudal lobe of the left lung and a nodule measuring approximately 11×7 mm was detected in the caudal lobe of the right lung. Doxycycline hydrochloride hydrate (7 mg/kg q12h for 13 days and then q24h for 66 days [vibramycin; Pfizer]) was administered to treat bronchopneumonia. No abnormalities in other organs were observed on thoracic radiography and abdominal ultrasonography; haematological and serum biochemical parameters were within normal limits.

At 90 days after the initial visit to the private veterinary clinic, the nodule in the caudal lobe of the right lung showed an increase in size to approximately $16 \times 14 \times 12$ mm vs the size detected on radiography at 48 days; CT then showed an increase in the size of the mass in the caudal lobe of the right lung to $27 \times 23 \times 18$ mm (Figure 1).

At 108 days after the initial visit, and a radiopaque region in the accessory lobe was revealed. Fine-needle aspiration (FNA) was not performed because the mass was located far from the thoracic margin. None of the sternal, cranial mediastinal, tracheobronchial nor abdominal lymph nodes was enlarged, and abdominal organs, including the liver, kidneys, spleen and gastrointestinal tract, appeared normal on CT examination of the whole body under contrast medium administration. On the same day, pulmonary lobectomy of the caudal lobe

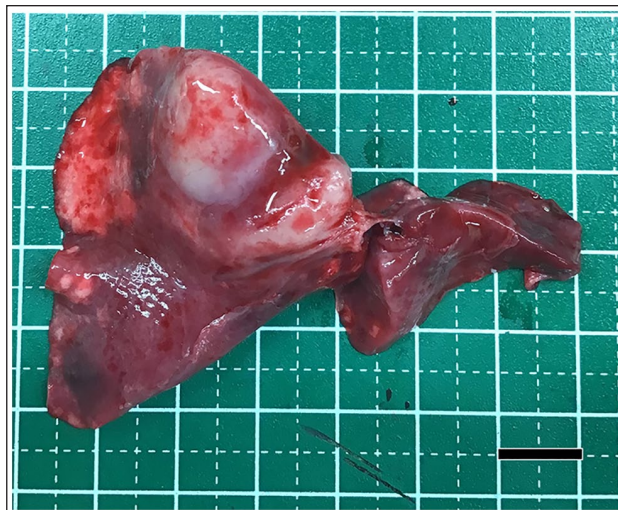


Figure 2 Macroscopical appearance of the pulmonary mass removed from the caudal right lung lobe. Scale bar = 2 cm

of the right lung and accessory lobe was performed via an incision made at the fifth intercostal muscle. General anaesthesia was induced with 1% propofol (Propofol; Fresenius Kabi) intravenous injection until the desired effect was obtained. As soon as jaw relaxation was achieved, endotracheal intubation was performed. Anaesthesia was maintained with 100% oxygen and isoflurane (isoflurane inhalation solution; Pfizer), ranging from 1.0% to 1.9%. Rocuronium bromide (Eslax; MSD) was administered at a dose of 0.5 mg/kg intravenously for the induction of muscle relaxation. The cat was infused with $2\text{--}8 \mu\text{g}/\text{kg}/\text{min}$ fentanyl citrate (fentanyl injection; Terumo) during the operation, as well as at 10h postoperatively for pain management. Cefazolin (25 mg/kg cefazolin sodium; Nipro) was administered every 2h to prevent infection perioperatively and every 12h postoperatively. The resected tissues were submitted to the Department of Veterinary Pathology, Nippon Veterinary and Life Science University.

Grossly, the mass located in the posterior lobe of the right lung had a white surface and was firm (Figure 2). A nodule-like lesion in the accessory lobe showed a pale-reddish colour. The resected pulmonary lobes were fixed in 10% neutral buffered formalin, processed routinely and embedded in paraffin wax. Sections ($4 \mu\text{m}$) were stained with haematoxylin and eosin, Gram, periodic acid-Schiff (PAS) and Grocott stains. Microscopically, the mass was non-encapsulated with an unclear margin with the surrounding tissues. It comprised large round or polygonal neoplastic cells arranged in a diffuse pattern. The neoplastic cells displayed large, round, hypochromatic nuclei with scant pale eosinophilic cytoplasm (Figure 3). The frequency of mitosis was ≥ 2 per high-power field ($\times 400$). No intravascular embolisation by neoplastic cells was identified. Immunohistochemical (IHC) analysis was performed with the resected caudal

right lung mass using labelled streptavidin–biotin and primary antibodies specific for CD3, CD20, CD204, E-cadherin, the ionised calcium-binding adaptor molecule-1 (Iba-1), granzyme B, FeLV p27 and FeLV glycoprotein (gp) 70 (Table 1), to distinguish between T-cell lymphoma, B-cell lymphoma and pulmonary Langerhans cell histiocytosis. A combination of CD20 and FeLV p27 antibodies was also used to perform double-labelled immunofluorescence. Neoplastic cells were diffusely positive for CD20 but negative for CD3, CD204, Iba-1, granzyme B and E-cadherin. The cytoplasm of neoplastic cells was positive for FeLV p27 and gp70. Neoplastic cells coexpressed CD20 and FeLV p27 (Figure 4). T lymphocytes and macrophages were often observed in the peripheral area of neoplastic tissue.

Based on the morphological and IHC findings, the neoplasm was diagnosed to be diffuse large B-cell lymphoma, according to the World Health Organization (WHO) classification of malignant lymphoma in

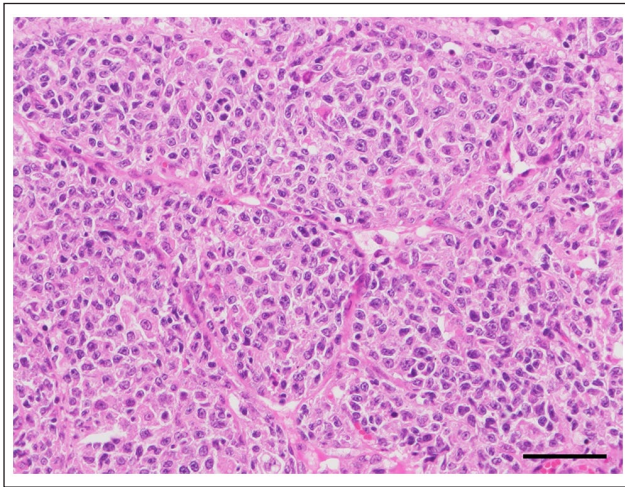


Figure 3 The mass comprised round-to-polygonal neoplastic cells arranged in a diffuse pattern. Haematoxylin and eosin. scale bar = 50 µm

domestic animals.¹ Chronic bronchopneumonia was observed in the accessory lobe; however, no lymphoma or bacterial or fungal infections were observed on histopathological examination using special stains, including Gram, PAS and Grocott. Additional chemotherapy according to the cyclophosphamide, doxorubicin/hydroxydaunorubicin, vincristine/oncovin and prednisolone (CHOP) protocol² was administered following surgical excision, in addition to doxycycline hydrochloride hydrate (7 mg/kg q24h). In a detailed examination performed 196 days after surgical resection, abdominal ultrasonography showed thickening of the jejunum, and a subsequent FNA under ultrasonography detected a high-grade lymphoma arising from the jejunum (Figure 5). The cat showed no associated clinical signs such as weight loss, vomiting or diarrhoea, and tumour lesions in the lung or other haematopoietic organs were not seen. Bronchopneumonia was immediately cured after doxycycline hydrochloride hydrate administration, although the cat showed slight respiratory signs after lobectomy. At 224 days after surgical resection, the cat died with black defecation suggestive of intestinal haemorrhage a few days previously.

Discussion

Primary pulmonary neoplasms, such as adenocarcinoma, bronchioloalveolar carcinoma, adenosquamous carcinoma, carcinosarcoma or pulmonary Langerhans cell histiocytosis, are uncommon in cats.^{2–7} However, lymphomas are common neoplasms in cats.⁸ Based on their anatomical origin, feline lymphomas are classified into five types: multicentric, alimentary, mediastinal, cutaneous and extranodal.⁸ Cats predominantly present with alimentary and mediastinal lymphoma types.⁸ Lymphomas occurring in the lungs are classified into primary neoplasms, and secondary involvement of those arising from the other thoracic organs (such as the thymus, mediastinal, sternal or tracheobronchial lymph nodes) or from extrathoracic organs (such as the liver,

Table 1 Primary antibodies used in the immunohistochemistry analysis

Antibody	Host (clone)	Dilution	Antigen retrieval	Source
CD3	Mouse (F7.2.38)	1:300	121°C for 20 mins in citrate buffer, pH 6.0	Dako
CD20	Mouse (N/A)	1:200	121°C for 20 mins in citrate buffer, pH 6.0	Biocare Medical
CD204	Mouse (SRA-E5)	1:100	Microwave for 10 mins in citrate buffer, pH 2.0	TransGenic
E-cadherin	Mouse (NCH-38)	1:100	121°C for 10 mins in Tris-EDTA buffer, pH 9.0	Dako
Granzyme B	Mouse (GrB-7)	1:50	121°C for 20 mins in citrate buffer, pH 6.0	Nichirei Biosciences
FeLV p27	Mouse (PFI2J-10A)	1:100	121°C for 20 mins in citrate buffer, pH 6.0	Custom Monoclonals International
FeLV gp70	Mouse (C11D8)	1:200	121°C for 20 mins in citrate buffer, pH 6.0	Bio-Rad Laboratories
Iba-1	Rabbit	1:1,000	121°C for 20 mins in citrate buffer, pH 6.0	Wako

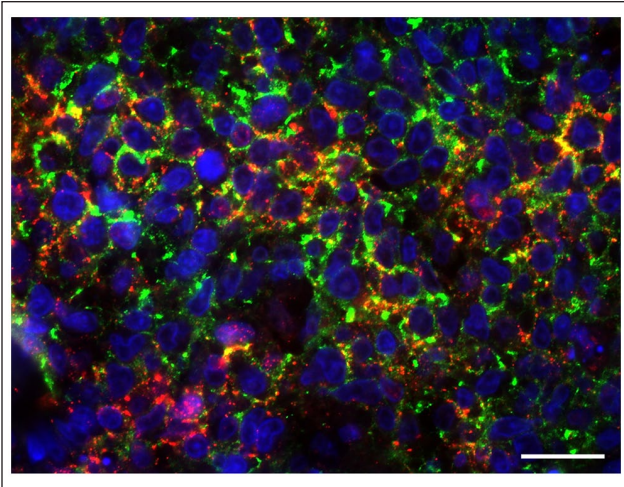


Figure 4 Double immunofluorescence staining showing coexpression of CD20 (green) and feline leukaemia virus p27 (red) in neoplastic cells. Scale bar = 50 μ m

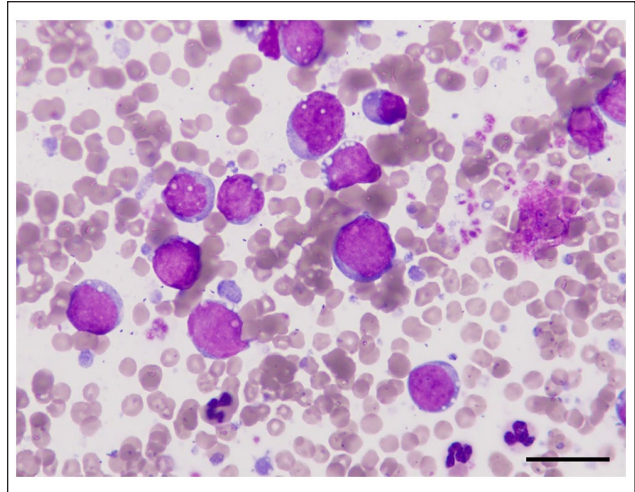


Figure 5 Fine-needle aspirate cytology of the jejunum revealed large round cells with rounded nuclei and small amounts of basophilic cytoplasm, consistent with high-grade lymphoma. Wright–Giemsa stain, scale bar = 20 μ m

kidneys and spleen).^{9,10} However, to our knowledge, pulmonary involvement of feline lymphoma has not previously been reported in cats. Based on the histological appearance, the most distinct lung neoplasm is Langerhans cell histiocytosis. Pulmonary Langerhans cell histiocytosis originates from dendritic cells that express CD18, E-cadherin and Iba-1 but not CD204; initially, it results in the formation of a nodular lesion surrounding the bronchi before spreading throughout the lung.^{5,7} Pulmonary Langerhans cell histiocytosis can be excluded based on the aforementioned IHC features.

The WHO classification of tumours of the lung in humans subclassifies lymphohistiocytic tumours to include extranodal marginal zone lymphoma of mucosa-associated lymphoid tissue, diffuse large B-cell lymphoma, lymphomatoid granulomatosis, intravascular large B-cell lymphoma, pulmonary Langerhans cell histiocytosis and Erdheim–Chester disease.¹¹ In humans, the occurrence of primary pulmonary lymphoma is extremely rare, representing <1% of all lymphomas, and it is defined as clonal proliferation in the parenchyma of the lung in a patient with no detectable extrapulmonary involvement at diagnosis or during the subsequent 3 months.^{12,13} In cats, primary pulmonary lymphoma has not yet been reported, although secondary involvement of lymphoma in the lung has been reported.^{9,10,14} Pulmonary involvement of lymphoma is observed in 12% of the cases (16/125 on necropsy). It forms macroscopic masses and nodules, and shows histologically predominant peribronchial invasion, followed by pleural, interstitial, nodular and alveolar patterns.¹⁰ Although no clinical signs were noted for almost 7 months after surgery and chemotherapy based on the CHOP protocol, abdominal ultrasonography and FNA examination detected high-grade lymphoma in the jejunum. No gastrointestinal signs or abnormal findings in the

gastrointestinal tract, including the jejunum, were detected on abdominal ultrasonography after lobectomy. Furthermore, lymphoma occurring in the right caudal lung lobe was considered a primary pulmonary neoplasia as jejunal lymphoma was not detected until 196 days after surgical resection.

FeLV causes immune dysfunction by suppressing immunoglobulin production and neutrophil function in infected cats.¹⁵ Furthermore, FeLV is involved in the development of various tumours, including haematopoietic tumours such as lymphoma and leukaemia, and non-haematopoietic tumours such as osteochondroma. Overall, 15% or 25% of infected cats develop cancers such as lymphoma.^{15,16} The most important mechanism by which as FeLV causes tumours is that the FeLV genome is integrated near oncogenes such *c-myc* and *bmi-1*, causing activation and overexpression of these genes.¹⁷ FeLV-induced lymphomas derived from both T and B lymphocytes occur as several types, including multicentric, mediastinal, alimentary and renal types, as well as upper respiratory type, which induce the development of diffuse B-cell lymphoma.^{17–21} FeLV infection in feline lymphoma can be demonstrated by IHC staining of FeLV capsid p27 and envelope gp70.^{10,20,22,23} On IHC, FeLV-positive cats are immunohistochemically regarded as productively FeLV-infected cats.²² Moreover, 87% (34/39 cases) of lymphomas occurring in the upper airways such as the nasal cavity and nasopharynx have been found to be of the B-cell type, and in 62% of these cases (n = 21/34) FeLV p27 and/or gp70 were detected on IHC examination.²⁰ FeLV may be involved in the development of lymphoma in the upper respiratory tract in cats, although the association between serum FeLV test- and IHC-positive cases has not been evaluated owing to the small number cases in which serum FeLV

tests have been performed.²⁰ FeLV viral RNA can also be detected by in situ hybridisation in case of B-cell lymphoma of the spinal cord.²⁴ In the present case, FeLV antigen was detected by both serum tests and IHC staining, suggesting that tumourigenesis in this case was related to the effects of FeLV infection on immune surveillance.

Conclusions

To the best of our knowledge, this is the first report of a primary pulmonary diffuse B-cell lymphoma case associated with FeLV infection in a young cat.

Conflict of interest The authors declared no potential conflicts of interest with respect to the research, authorship, and/or publication of this article.

Funding The authors received no financial support for the research, authorship, and/or publication of this article.

Ethical approval The work involved the use of non-experimental (owned or unowned) animals. Established internationally recognised high standards ('best practice') of veterinary clinical care for the individual patient were always followed. Ethical approval from a committee was therefore not specifically required for publication in *JFMS Open Reports*.

Informed consent Informed consent (either verbal or written) was obtained from the owner or legal custodian of all animal(s) described in this work (either experimental or non-experimental animals for all procedure(s) undertaken (prospective or retrospective studies). For any animals or people individually identifiable within this publication, informed consent (either verbal or written) for their use in the publication was obtained from the people involved.

References

- Valli VE, Jacobs RM, Parodi AL, et al. Histological classification of hematopoietic tumors of domestic animals. Washington, DC: Armed Forces Institute of Pathology, 2002.
- Hahn KA and McEntee MF. **Primary lung tumors in cats: 86 cases (1979–1994)**. *J Am Vet Med Assoc* 1997; 211: 1257–1260.
- Hahn KA and McEntee MF. **Prognosis factors for survival in cats after removal of a primary lung tumor: 21 cases (1979–1994)**. *Vet Surg* 1998; 27: 307–311.
- Ghisleni G, Grieco V, Mazzotti M, et al. **Pulmonary carcinosarcoma in a cat**. *J Vet Diagn Invest* 2003; 15: 170–173.
- Busch MD, Reilly CM, Luff JA, et al. **Feline pulmonary Langerhans cell histiocytosis with multiorgan involvement**. *Vet Pathol* 2008; 45: 816–824.
- D'Costa S, Yoon BI, Kim DY, et al. **Morphologic and molecular analysis of 39 spontaneous feline pulmonary carcinomas**. *Vet Pathol* 2012; 49: 971–978.
- Argenta FF, de Britto FC, Pereira PR, et al. **Pulmonary Langerhans cell histiocytosis in cats and a literature review of feline histiocytic diseases**. *J Feline Med Surg* 2020; 22: 305–312.
- Vail D. **Feline lymphoma and leukemia**. In: Withrow SJ, Vail DM and Page RM (eds). *Withrow and MacEwen's small animal clinical oncology*. 5th ed. St Louis, MO: Elsevier, 2013, pp 638–653.
- Geyer NE, Reichle JK, Valdés-Martínez A, et al. **Radiographic appearance of confirmed pulmonary lymphoma in cats and dogs**. *Vet Radiol Ultrasound* 2010; 51: 386–390.
- Leite-Filho RV, Panziera W, Bandinelli MB, et al. **Pathological characterization of lymphoma with pulmonary involvement in cats**. *J Comp Pathol* 2018; 165: 6–12.
- Nicholson AG, Jaffe ES and Guinee D. **Lymphohistiocytic tumours of the lung**. In: WHO classification of tumours of the lung, pleura, thymus and heart. 4th ed. Lyon: IARC Press, 2015, pp 134–143.
- Cadranel J, Wislez M and Antoine M. **Primary pulmonary lymphoma**. *Eur Respir J* 2002; 20: 750–762.
- William J, Variakojis D, Yeldandi A, et al. **Lymphoproliferative neoplasms of the lung: a review**. *Arch Pathol Lab Med* 2013; 3: 382–391.
- Brown AL, Beatty JA, Nicoll RG, et al. **Dyspnoea and pulmonary consolidation in a cat with T-cell lymphoma**. *J Feline Med Surg* 2011; 13: 772–775.
- Ortega C, Valencia AC, Duque-Valencia J, et al. **Prevalence and genomic diversity of feline leukemia virus in privately owned and shelter cats in Aburrá Valley, Colombia**. *Viruses* 2020; 12: 464. DOI: 10.3390/v12040464.
- Ogilvie GK and Moore AS. **Lymphoma**. In: Ogilvie GK and Moore AS (eds). *Feline oncology: a comprehensive guide to compassionate care*. Yardley, PA: Veterinary Learning Systems, 2001, pp 191–219.
- Hartmann K. **Clinical aspects of feline retroviruses: a review**. *Viruses* 2012; 4: 2684–2710.
- Valli VE, Bienzle D and Meuten DJ. **Tumors of the haemolymphatic system**. In: Meuten DJ (ed). *Tumors in domestic animals*. 5th ed. Ames, IA: Wiley, 2017, pp 203–321.
- Cristo TG, Biezu G, Noronha LF, et al. **Feline lymphoma and a high correlation with feline leukaemia virus infection in Brazil**. *J Comp Pathol* 2019; 166: 20–28.
- Santagostino SF, Mortellaro CM, Boracchi P, et al. **Feline upper respiratory tract lymphoma: site, cyto-histology, phenotype, FeLV expression, and prognosis**. *Vet Pathol* 2015; 52: 250–259.
- Mooney SC, Hayes AA, Matus RE, et al. **Renal lymphoma in cats: 28 cases (1977–1984)**. *J Am Vet Med Assoc* 1987; 191: 1473–1477.
- Suntz M, Failing K, Hecht W, et al. **High prevalence of non-productive FeLV infection in necropsied cats and significant association with pathological findings**. *Vet Immunol Immunopathol* 2010; 136: 71–80.
- Leite-Filho RV, Panziera W, Bandinelli MB, et al. **Epidemiological, pathological and immunohistochemical aspects of 125 cases of feline lymphoma in Southern Brazil**. *Vet Comp Oncol* 2020; 18: 224–230.
- Szilasi A, Dénes L, Jakab C, et al. **In situ hybridization of feline leukemia virus in a primary neural B-cell lymphoma**. *J Vet Diagn Invest* 2020; 32: 454–457.