



Recovery after inadvertent intramedullary microchip implantation at C1–C2 in a kitten

Authors: Schneider, Nina, Blutke, Andreas, and Parzefall, Birgit

Source: Journal of Feline Medicine and Surgery Open Reports, 8(1)

Published By: SAGE Publishing

URL: <https://doi.org/10.1177/20551169221081398>

BioOne Complete (complete.BioOne.org) is a full-text database of 200 subscribed and open-access titles in the biological, ecological, and environmental sciences published by nonprofit societies, associations, museums, institutions, and presses.

Your use of this PDF, the BioOne Complete website, and all posted and associated content indicates your acceptance of BioOne's Terms of Use, available at www.bioone.org/terms-of-use.

Usage of BioOne Complete content is strictly limited to personal, educational, and non - commercial use. Commercial inquiries or rights and permissions requests should be directed to the individual publisher as copyright holder.

BioOne sees sustainable scholarly publishing as an inherently collaborative enterprise connecting authors, nonprofit publishers, academic institutions, research libraries, and research funders in the common goal of maximizing access to critical research.



Recovery after inadvertent intramedullary microchip implantation at C1–C2 in a kitten

Nina Schneider¹, Andreas Blutke²
and Birgit Parzefall¹

Journal of Feline Medicine and Surgery Open Reports
1–6

© The Author(s) 2022

Article reuse guidelines:

sagepub.com/journals-permissions

DOI: 10.1177/20551169221081398

journals.sagepub.com/home/jfmsopenreports

This paper was handled and processed by the European Editorial Office (ISFM) for publication in *JFMS Open Reports*



Abstract

Case summary A 15-week-old male British Shorthair cat was presented for peracute paralysis immediately after microchip implantation. Neurological examination revealed a non-ambulatory tetraparesis and left thoracic limb plegia localised to C1–C5 spinal cord segments. CT of the cervical spine showed a diagonally orientated metallic foreign body (microchip transponder, 10 mm in length) within the vertebral canal at the level of C1–C2, resulting in a penetrating spinal cord injury. Based on concerns about further iatrogenic spinal cord injury through surgery, medical management was chosen. Despite the severe clinical signs, the kitten returned to ambulation within 6 days of the injury, with controlled urination and defecation. Continuous neurological improvement was seen for up to 6 weeks after the injury at which point a mild-to-moderate ambulatory tetraparesis and ataxia remained, with an overall good quality of life. Follow-up CT at the age of 13 months revealed a relative cranial displacement and rotation of the microchip towards the foramen magnum, while the cat's neurological status was unchanged.

Relevance and novel information This case demonstrated a cervical penetrating spinal cord injury in a growing cat caused by a microchip, which was successfully managed with medical treatment, suggesting that this might be an option for patients at risk of severe surgery-related complications or where owners reject surgery.

Keywords: Spinal cord; penetrating; medical; cervical spine

Accepted: 28 January 2022

Introduction

Penetrating spinal cord injuries (PSCIs) in humans are often associated with severe myelopathies, and the prognosis for neurological improvement is guarded to poor in the majority of affected patients.^{1,2} There are still ongoing discussions about whether medical or surgical therapy is the treatment of choice, as recent studies have not demonstrated a difference in outcome in humans with PSCI.^{2–4} In veterinary medicine, PSCIs appear to be rare and only a small number of cases in companion animals have been reported, which were all treated surgically.^{5–9}

Here, we report on a 15-week-old male British Shorthair (BSH) cat with a PSCI due to inappropriate microchip placement that was successfully managed with medical treatment.

Case description

A 15-week-old intact male BSH cat weighing 1.3 kg was referred to the Neurology Service of the Small Animal Clinic Oberhaching 1 day after peracute onset of paralysis immediately following microchip implantation (Figure 1). According to the owner, clinical signs

¹Neurology Department, Small Animal Clinic Oberhaching, Oberhaching, Germany

²Institute for Experimental Genetics, Helmholtz Zentrum München, Neuherberg, Germany

Corresponding author:

Birgit Parzefall DVM, MVetMed, DiplECVN, Neurology Department, Small Animal Clinic Oberhaching, Bajuwarenring 10, Oberhaching 82041, Germany
Email: parzefall@tierklinik-oberhaching.de



Creative Commons Non Commercial CC BY-NC: This article is distributed under the terms of the Creative Commons

Attribution-NonCommercial 4.0 License (<https://creativecommons.org/licenses/by-nc/4.0/>) which permits non-commercial use, reproduction and distribution of the work without further permission provided the original work is attributed as specified on the SAGE and Open Access pages (<https://us.sagepub.com/en-us/nam/open-access-at-sage>).

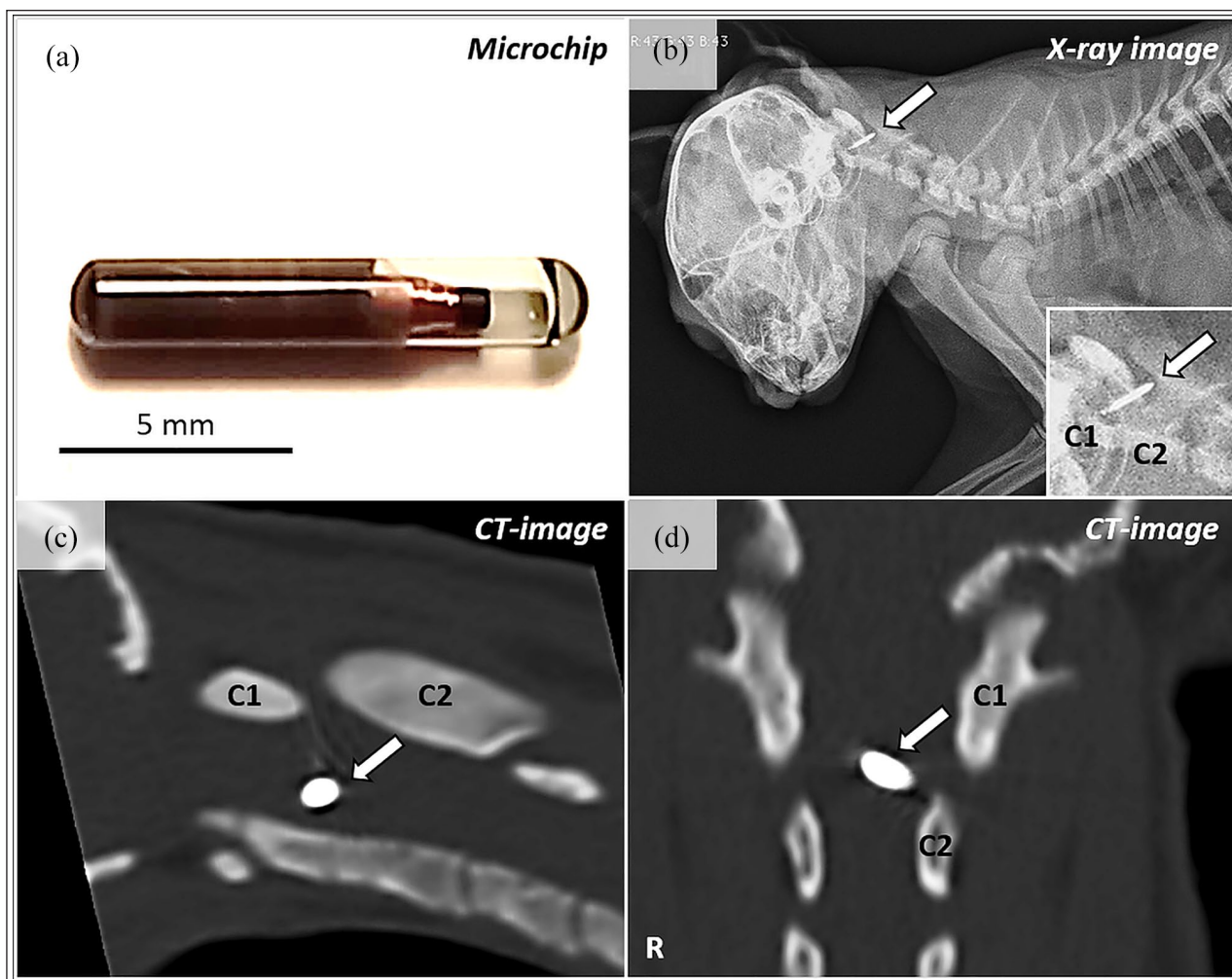


Figure 1 (a) Microchip of the same construction type and size as implanted in the presented case. The microchip transponder was lodged diagonally within the vertebral canal at the level of C1–C2 as shown in a lateral radiograph (b); (c) sagittal and (d) dorsal CT image reconstruction

had already mildly improved at the time of presentation. A radiograph of the cervical spine provided by the referring veterinarian showed a diagonally orientated microchip transponder within the vertebral canal at the level of C1–C2 (Figure 1a,b). The patient was pretreated with corticosteroids and vitamin B complex injections.

On presentation, the physical examination was unremarkable and neurological examination revealed the kitten to be alert and responsive with mild ventroflexion, a non-ambulatory tetraparesis with plegia in the left thoracic limb (Figure 2a), preserved nociception and a normal cranial nerve examination. Paw positioning was absent in the left thoracic and left pelvic limb, mildly reduced in the right thoracic limb and normal in the right pelvic limb. Withdrawal and patellar reflexes were normal apart from a crossed flexor–extensor reflex in the right pelvic limb. A markedly increased muscle tone was present in the left thoracic and left pelvic limb and the patient showed no signs of discomfort on spinal

palpation. The neuroanatomical localisation was consistent with a slightly lateralising C1–C5 myelopathy (see Video 1 in the supplementary material) with a traumatic or vascular cause (haematoma secondary to trauma) as the most likely differential diagnosis.

Complete blood count, serum biochemistry and electrolytes were within normal limits, except for a mildly decreased haematocrit of 28.4% (reference interval 30.3–52.3), which was most likely age related. The cat was sedated with an intravenous bolus of propofol (Narcofol; CP-Pharma) and positioned in dorsal recumbency for CT of the cervical spine. Scans were performed using a 16-multislice helical CT scanner (Supria; Hitachi) with a slice thickness of 1.25 mm and 0.63 mm for soft tissue and bone window, respectively. Transverse planes and additional multiplanar reconstruction were obtained. On CT, the microchip could be identified as a linear, well-defined, strongly hyperattenuating structure, which was 10 mm in length and 2 mm in transverse diameter,

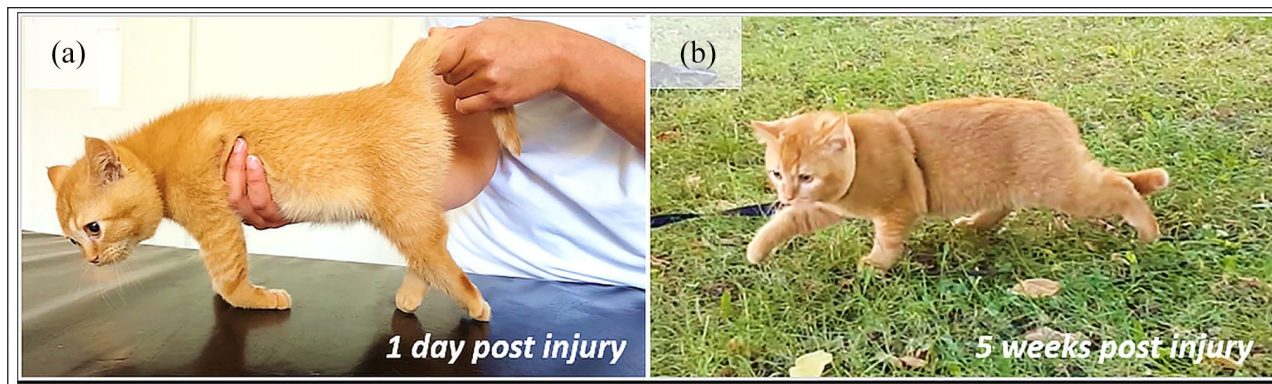


Figure 2 Clinical signs (a) 1 day post-injury and (b) at the 5-week follow-up. The cat's signs improved from (a) non-ambulatory tetraparesis with plegia in the left thoracic limb to (b) ambulatory mild-to-moderate tetraparesis and ataxia

and was diagonally lodged within the vertebral canal (diameter 6×7 mm) at C1–C2 and surrounded by streak artefacts (Figure 1c,d). No obvious deviation of the spinal cord was noted, and all bony structures appeared to be intact. Based on the CT findings, the diagnosis was PSCI at the level of C1–C2 by an intramedullary placed microchip.

As the kitten's neurological status had already slightly improved and further iatrogenic spinal cord injury through surgery was a concern, continued medical management was chosen. Treatment included continuous rate infusion of lactated Ringer's solution (B Braun) and dexamethasone (Hexadreson; MSD Animal Health) $0.1 \text{ mg/kg q24h IV}$ for two consecutive days, followed by physiotherapy after discharge. During hospitalisation normal urination was observed and the cat demonstrated no signs of pain, with a Glasgow composite measure pain scale (CMPS-Feline) score of 1/20, indicating that no additional analgesia was required.^{10,11}

As the long-term prognosis and possible future complications were uncertain, the breeder transferred the kitten to one of the authors, who was willing to take care of it. The kitten was discharged 3 days after the first presentation with non-ambulatory tetraparesis; however, there was markedly improved motor function in all but the left thoracic limb, which was still plegic. The cat returned to ambulation within 6 days of the injury with resolution of the ventroflexion, and controlled urination and defecation. In the following 6 weeks the kitten continuously improved to an ambulatory mild-to-moderate tetraparesis and ataxia with the ability to climb, run and jump (Figure 2b). Hyperthermia of the left ear was repeatedly noticed after exercise. No further neurological improvement was seen 6 weeks after the PSCI.

The patient was anaesthetised for routine neutering at the age of 13 months at which point follow-up radiographs and CT were performed. General anaesthesia was performed using medetomidine hydrochloride ($2 \mu\text{g/kg IV}$ [Dorbene; Zoetis]) and ketamine (0.2 mg/kg

IV [Ketamin; CP-pharma]) and the cat was intubated. Meloxicam (0.2 mg/kg SC [Metacam; Boehringer Ingelheim]) was applied in terms of standard analgesic management for castration.

Compared with the initial CT, both imaging modalities demonstrated a more cranial displacement and rotation of the microchip relative to the surrounding vertebral bone, which was now straight in orientation and reaching from the dens axis to the foramen magnum (Figure 3). The hyperattenuating microchip was surrounded by a hypoattenuating rim, consistent with beam hardening.

At the time of writing, the patient was 20 months old with a stable neurological status and overall good quality of life (see Video 2 in the supplementary material).

Discussion

Spinal cord injuries (SCIs) caused by inappropriate placement of a microchip are rare in animals, but have been reported in three dogs and one cat, most commonly presenting as an acute-onset ambulatory or non-ambulatory tetraparesis.^{8,9,12,13} All of these animals underwent surgical treatment with a good outcome, although small residual deficits remained in some patients.^{9,12,13} The patient with the most similarities compared with our cat was a 6-week-old, 1.6 kg, Tibet Terrier with the microchip located within the vertebral canal at C2, which was removed during hemilaminectomy.⁹ In the other two dogs the microchip could be removed without hemilaminectomy because a part of it still protruded into the paraspinal soft tissue, while the other part protruded into the vertebral canal, causing the SCI.^{8,13} The cat was 2 years old at the time of the SCI; the microchip was located within the vertebral canal at C5–C6 and was removed during dorsal laminectomy.¹²

In our cat an intramedullary location of the microchip seemed most likely, owing to its position across the midline of the vertebral canal and no obvious signs of deviation of the spinal cord on CT. An intramedullary location was also compatible with the lack of pain on

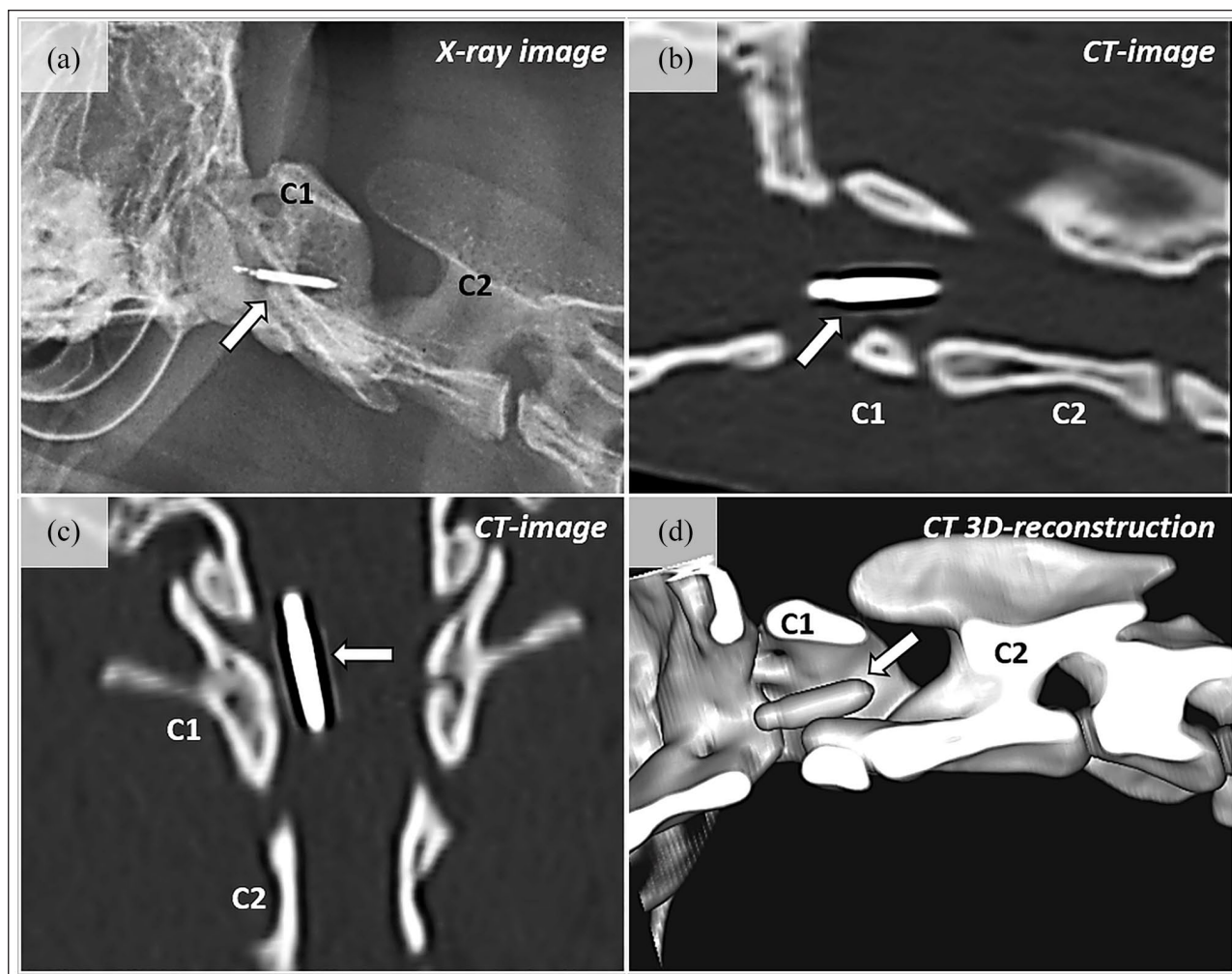


Figure 3 (a) Follow-up lateral radiograph, (b) sagittal CT, (c) dorsal CT and (d) sagittal CT three-dimensional reconstruction of the cervical spine of the cat at 13 months of age. Note the more cranial displacement and rotation of the microchip (arrow) vs the CT images at the time of first presentation. The microchip is located ventrally and left-sided within the vertebral canal, reaching from the base of the left side of the dens axis to the foramen magnum

cervical palpation due to the lack of sensory innervation of the spinal cord parenchyma;¹⁴ and also with the ventroflexion in our cat, which has frequently been reported in intramedullary lesions caused by feline cervical ischaemic myelopathy and is thought to arise from an involvement of spinal grey matter, which leads to paralysis of the cervical dorsal epaxial musculature.¹⁵ Interestingly, the cat showed repeated hyperthermia of the left ear after exercise, which could have arisen from a left-sided sympathetic lesion attributed to an impairment of the left lateral tectospinal tract of the cervical spinal cord.¹⁶

To the best of our knowledge, this is the first report of the successful medical management of a cervical PSCI in a kitten caused by a microchip with an outcome comparable to surgically treated animals.^{9,12,13} The treatment of choice for PSCIs in humans is still a matter

of debate. While some authors recommend the surgical removal of all foreign bodies within the vertebral canal as they are at risk for migration, recent studies in humans with PSCIs could not demonstrate a difference in outcome between surgically and medically treated patients.^{2-4,17} PSCIs in humans are normally caused by stab wounds or, more commonly, as a consequence of gunshot injuries.^{1,18} Affected patients often present with severe neurological grades with a rate of 50–61% for complete SCIs (total loss of motor and sensory function).^{1,2} In more than 50% of patients with incomplete PSCIs, no improvement or a worsening of their initial neurological grade has been reported at the 1-year follow-up.² This seems to be in contrast to PSCIs in cats and dogs, which have shown good recovery after surgery and after medical management, although large controlled studies in animals are lacking.^{5,6,8,9,12}

There are a number of complications of PSCIs in humans, including neurological deterioration, spinal instability and cerebrospinal fluid (CSF) fistulas, which prompt the decision for surgical removal of the foreign body; otherwise, no guidelines exist on indications for either surgical or medical management of PSCIs in humans.^{1,4,17} Medical management in humans with acute SCIs involves fluid therapy, the administration of vaso-pressors like norepinephrine for maintaining spinal cord perfusion in the case of hypotension, analgesic therapy (eg, opioids or ketamine) and antithrombotic therapy.^{19,20} Airway and ventilator support might be necessary in severely affected patients.¹⁹ Broad-spectrum antibiotics are recommended for 7–14 days after PSCI injury in humans.²¹ In our cat, no antibiotics were administered as identification microchips are generally placed as an aseptic technique. As our cat was pretreated with prednisolone, we administered dexamethasone instead of non-steroidal anti-inflammatory drugs, to avoid gastrointestinal adverse events.²² In humans, there is no evidence for a beneficial effect of corticosteroids on functional neurological recovery in SCI.^{19,23}

Although our cat demonstrated a favourable outcome with medical management, the clinician should be aware of late-onset complications in patients with central nervous system (CNS) foreign body diseases. Migration of foreign bodies,^{13,24,25} inflammatory reactions like granuloma^{26–30} and abscess formation,^{31–33} myelitis,³⁴ arachnoiditis with and without subsequent subarachnoid diverticula or syrinx formation^{35,36} and CSF leakage³⁷ have been reported in veterinary and human medicine. In our cat, some degree of migration of the microchip was identified on follow-up CT that might have occurred in the context of maturing of the spine. However, migration was not associated with neurological deterioration. Abscess formation within the CNS is mostly described with foreign bodies of plant origin.^{31,32,38} Sterile CNS foreign bodies like suture material,³⁰ cotton pledget^{28,29} and bone wax³⁹ have been reported to cause late-onset clinical signs in humans due to granulomatous reactions that could potentially lead to complications in our cat in the future.

Conclusions

Our findings suggest that medical management may be an alternative treatment option for kittens and perhaps also other patients with PSCIs caused by a microchip inadvertently placed within the cervical spine, if severe surgery-related complications are anticipated or surgery is rejected by the owner. The clinician should be aware of late-onset complications that might occur weeks to years after the primary insult.

Author note The content of this paper was presented in part as a poster at the ECVN congress 2021.

Acknowledgements The authors thank Dr Bettina Gutmannsbauer and Sebastian Hunger for technical support, and the referring veterinarian for providing the initial radiograph.

Conflict of interest The authors declared no potential conflicts of interest with respect to the research, authorship, and/or publication of this article.

Funding The authors received no financial support for the research, authorship, and/or publication of this article.

Ethical approval The work described in this manuscript involved the use of non-experimental (owned or unowned) animals. Established internationally recognised high standards ('best practice') of veterinary clinical care for the individual patient were always followed. Ethical approval from a committee was therefore not specifically required for publication in *JFMS Open Reports*.

Informed consent Informed consent (verbal or written) was obtained from the owner or legal custodian of all animal(s) described in this work (experimental or non-experimental animals, including cadavers) for all procedure(s) undertaken (prospective or retrospective studies). For any animals or people individually identifiable within this publication, informed consent (verbal or written) for their use in the publication was obtained from the people involved.

ORCID iD Birgit Parzefall  <https://orcid.org/0000-0003-2154-5993>

Supplementary material The following files are available online:

Video 1: Part of the neurological examination of the 15-week-old British Shorthair cat the day after a penetrating cervical spinal cord injury caused by a microchip.

Video 2: Follow-up videos 6 days, 5 weeks and 15 months post-injury.

References

- 1 Roach MJ, Chen Y and Kelly ML. **Comparing blunt and penetrating trauma in spinal cord injury: analysis of long-term functional and neurological outcomes.** *Top Spinal Cord Inj Rehabil* 2018; 24: 121–132.
- 2 Kelly ML, Roach MJ, Nemunaitis G, et al. **Surgical and nonsurgical treatment of penetrating spinal cord injury: analysis of long-term neurological and functional outcomes.** *Top Spinal Cord Inj Rehabil* 2019; 25: 186–193.
- 3 Lawless MH, Lytle EJ, McGlynn AF, et al. **Surgical management of penetrating spinal cord injury primarily due to shrapnel and its effect on neurological outcome: a literature review and meta-analysis.** *J Neurosurg Spine* 2018; 28: 63–71.
- 4 Klimo P, Ragel BT, Rosner M, et al. **Can surgery improve neurological function in penetrating spinal injury? A review of the military and civilian literature and treatment recommendations for military neurosurgeons.** *Neurosurg Focus* 2010; 28: E4. DOI: 10.3171/2010.2.FOCUS1036.

- 5 Tanaka T, Akiyoshi H, Shimazaki H, et al. **Spinal cord trauma in a cat caused by ingestion of a splinter.** *J Feline Med Surg* 2012; 14: 155–157.
- 6 Rayward RM. **Acute onset quadriplegia as a sequela to an oropharyngeal stick injury.** *J Small Anim Pract* 2002; 43: 295–298.
- 7 Le Roux C, Venter FJ and Kirberger RM. **Cervical porcupine quill foreign body involving the spinal cord of a dog: a description of various imaging modality findings.** *J S Afr Vet Assoc* 2017; 88: 1–7.
- 8 Hicks DG and Bagley RS. **Imaging diagnosis – spinal injury following aberrant microchip implantation.** *Vet Radiol Ultrasound* 2008; 49: 152–153.
- 9 Smith TJ and Fitzpatrick N. **Surgical removal of a microchip from a puppy's spinal canal.** *Vet Comp Orthop Traumatol* 2009; 22: 63–65.
- 10 Steagall PV and Monteiro BP. **Acute pain in cats: recent advances in clinical assessment.** *J Feline Med Surg* 2019; 21: 25–34.
- 11 Reid J, Scott EM, Calvo G, et al. **Definitive Glasgow acute pain scale for cats: validation and intervention level.** *Vet Rec* 2017; 180: 449. DOI: 10.1136/vr.104208.
- 12 Platt S, Wieczorek L, Dennis R, et al. **Spinal cord injury resulting from incorrect microchip placement in a cat.** *J Feline Med Surg* 2007; 9: 157–160.
- 13 Joslyn SK, Witte PG and Scott HW. **Delayed spinal cord injury following microchip placement in a dog.** *Vet Comp Orthop Traumatol* 2010; 23: 214–217.
- 14 Devereaux MW. **Anatomy and examination of the spine.** *Neurol Clin* 2007; 25: 331–351.
- 15 Simpson KM, De Risio L, Theobald A, et al. **Feline ischaemic myelopathy with a predilection for the cranial cervical spinal cord in older cats.** *J Feline Med Surg* 2014; 16: 1001–1006.
- 16 de Lahunta A, Glass E and Kent M. **Lower motor neuron: general visceral efferent system.** In: *Veterinary neuro-anatomy and clinical neurology.* St Louis, MO: Saunders/Elsevier, 2015, pp 197–221.
- 17 de Barros Filho TEP, Cristante AF, Marcon RM, et al. **Gunshot injuries in the spine.** *Spinal Cord* 2014; 52: 504–510.
- 18 National Spinal Cord Injury Statistical Center. **The 2020 annual statistical report.** <https://www.nscisc.uab.edu/public/2020%20Annual%20Report%20-%20Complete%20Public%20Version.pdf> (2020, accessed April 29, 2021).
- 19 Consortium for Spinal Cord Medicine. **Early acute management in adults with spinal cord injury: a clinical practice guideline for health-care professionals.** *J Spinal Cord Med* 2008; 31: 403–479.
- 20 Karsy M and Hawryluk G. **Modern medical management of spinal cord injury.** *Curr Neurol Neurosci Rep* 2019; 19: 65. DOI: 10.1007/s11910-019-0984-1.
- 21 Bono CM and Heary RF. **Gunshot wounds to the spine.** *Spine J* 2004; 4: 230–240.
- 22 Lascelles BDX, Blikslager AT, Fox SM, et al. **Gastrointestinal tract perforation in dogs treated with a selective cyclooxygenase-2 inhibitor: 29 cases (2002–2003).** *J Am Vet Med Assoc* 2005; 227: 1112–1117.
- 23 Walters BC, Hadley MN, Hurlbert RJ, et al. **Guidelines for the management of acute cervical spine and spinal cord injuries.** *Neurosurgery* 2013; 60: 82–91.
- 24 Cottam EJ and Gannon K. **Migration of a sewing needle foreign body into the brainstem of a cat.** *JFMS Open Rep* 2015; 1. DOI: 10.1177/2055116915589841.
- 25 Macharla DK, Harpanahalli R and Panigrahi M. **Unusual intraspinal migration of ingested foreign body.** *World Neurosurg* 2018; 120: 516–520.
- 26 Narouze SN, Casanova J and Souzdamitski D. **Patients with a history of spine surgery or spinal injury may have a higher chance of intrathecal catheter granuloma formation.** *Pain Pract* 2014; 14: 57–63.
- 27 Leskovar A, Coates JR, Russell KE, et al. **Surgical removal of an intramedullary spinal cord foreign body granuloma in a dog.** *J Am Anim Hosp Assoc* 2003; 39: 306–310.
- 28 Meshkini A, Salehpour F, Rezakhah A, et al. **Textiloma: a case of foreign body mimicking a spinal tumor.** *Spine (Phila Pa 1976)* 2017; 42: E1272–E1274.
- 29 Peloquin P, Vannemreddy PSSV, Watkins LM, et al. **Intracranial cotton ball gossypiboma mimicking recurrent meningioma: report of a case with literature review for intentional and unintentional foreign body granulomas.** *Clin Neurol Neurosurg* 2012; 114: 1039–1041.
- 30 Onodera H, Furuya Y, Uchida M, et al. **Intracranial foreign body granuloma caused by dural tenting suture.** *Br J Neurosurg* 2011; 25: 652–654.
- 31 Cloquell A and Mateo I. **Surgical management of a brain abscess due to plant foreign body in a dog.** *Open Vet J* 2019; 9: 216–221.
- 32 Silva RT da, Souza HC de, Gepp R de A, et al. **Penetrating cervical spine injury and spinal cord intramedullary abscess.** *Arq Neuropsiquiatr* 2012; 70: 308–309.
- 33 Chen J-M, Wang Z-Y and Ni G-X. **Thoracic spinal epidural abscess caused by fishbone perforation.** *Medicine (Baltimore)* 2016; 95: e5283.
- 34 Jesmanas S, Norvainytė K, Gleiznienė R, et al. **Retained glass fragment in the cervical spinal canal in a patient with acute transverse myelitis: a case report and literature review.** *Case Rep Neurol Med* 2018. DOI: 10.1155/2018/5129513.
- 35 Gnanalingham KK, Joshi SM and Sabin I. **Thoracic arachnoiditis, arachnoid cyst and syrinx formation secondary to myelography with Myodil, 30 years previously.** *Eur Spine J* 2006; 15: 661–663.
- 36 Kochany JZ, Tran ND and Sarria JE. **Increasing back and radicular pain 2 years following intrathecal pump implantation with review of arachnoiditis.** *Pain Med* 2013; 14: 1658–1663.
- 37 Santangelo G, Stone J, Schmidt T, et al. **Imaging and surgical approach to a pediatric penetrating intradural wooden splinter: case report.** *J Neurosurg Pediatr* 2018; 21: 409–413.
- 38 Sutton A, May C and Coughlan A. **Spinal osteomyelitis and epidural empyema in a dog due to migrating conifer material.** *Vet Rec* 2010; 166: 693–694.
- 39 Ateş Ö, Çaylı S and Gürses İ. **Bone wax can cause foreign body granuloma in the medulla oblongata.** *Br J Neurosurg* 2004; 18: 538–540.