



Type III colonic atresia in a 6-week-old kitten

Authors: Quirk, Zoe, Hemmelgarn, Carey, and Goodman, Andrew R

Source: Journal of Feline Medicine and Surgery Open Reports, 9(2)

Published By: SAGE Publishing

URL: <https://doi.org/10.1177/20551169231191408>

BioOne Complete (complete.BioOne.org) is a full-text database of 200 subscribed and open-access titles in the biological, ecological, and environmental sciences published by nonprofit societies, associations, museums, institutions, and presses.

Your use of this PDF, the BioOne Complete website, and all posted and associated content indicates your acceptance of BioOne's Terms of Use, available at www.bioone.org/terms-of-use.

Usage of BioOne Complete content is strictly limited to personal, educational, and non - commercial use. Commercial inquiries or rights and permissions requests should be directed to the individual publisher as copyright holder.

BioOne sees sustainable scholarly publishing as an inherently collaborative enterprise connecting authors, nonprofit publishers, academic institutions, research libraries, and research funders in the common goal of maximizing access to critical research.



Type III colonic atresia in a 6-week-old kitten

Zoe Quirk¹, Carey Hemmelgarn²
and Andrew R Goodman³

Journal of Feline Medicine and Surgery Open Reports
1–4

© The Author(s) 2023

Article reuse guidelines:

sagepub.com/journals-permissions

DOI: 10.1177/20551169231191408

journals.sagepub.com/home/jfmsopenreports

This paper was handled and processed by the American Editorial Office (AAFP) for publication in *JFMS Open Reports*



Abstract

Case series summary A 6-week-old intact male domestic shorthair kitten presented for abdominal distension, small stature, vomiting and inappetence. Abdominal radiographs showed marked generalized gaseous gastrointestinal dilation. Exploratory laparotomy revealed type III colonic atresia which was surgically corrected via jejunocolic anastomosis. The kitten survived the immediate postoperative period and was discharged from the hospital but subsequently declined and was euthanized 7 days after surgery.

Relevance and novel information The patient described in this report is a rare case of colonic atresia diagnosed in the postneonatal period. To our knowledge, this is the first ante-mortem case diagnosed with type III colonic atresia and description of surgical management reported in companion animal medicine. The patient had short-term survival after surgery that, with adjustments to the postoperative care, may result in long-term survival for future patients.

Keywords: Colonic atresia; intestinal atresia; jejunocolic anastomosis; abdominal distension

Accepted: 16 July 2023

Introduction

Colonic atresia is a rare congenital malformation reported in humans, dogs, cats, cows, horses, sheep, alpacas and pigs.^{1–7} Surgical correction is necessary to establish a patent intestinal tract. In the veterinary literature, surgery is best described in calves with reported short-term survival to discharge of 48–71% and long-term survival greater than 28 days of 0–56%.^{1,2,4,8–10} Cases generally present for abdominal distension and lack of defecation within 10 days of birth,^{1–7} though case reports describe colonic atresia diagnosed at necropsy in a 52-day-old puppy¹¹ and 66-day-old kitten.¹² Ante-mortem diagnosis, surgical repair of colonic atresia and outcome in companion animal medicine have not been reported to our knowledge and are described here in a 6-week-old kitten.

Case description

A 6-week-old male intact domestic shorthair kitten was referred to a specialty hospital for exploratory laparotomy following previous evaluations with its primary care veterinarian starting at 5 weeks of age. The initial presenting complaint was abdominal distension

noted 1 week after transition from a liquid kitten diet to gruel. The owner also reported the kitten, owned since birth, was smaller than its littermates and had a normal appetite but was unsure of its elimination habits owing to shared litter boxes. Physical examination was unremarkable other than abdominal distension. Abdominal radiography showed marked generalized gaseous gastrointestinal dilation (Figure 1a,b). The kitten was treated with pyrantel pamoate 10 mg/kg PO in case of gastrointestinal parasitism. The kitten returned the following week for vomiting and inappetence. Repeat abdominal radiography revealed static generalized gastrointestinal gas. Complete blood count and serum biochemistry were unremarkable. Owing to clinical decline and continued

¹Mobius Veterinary Services, NY, USA

²Eclipse Specialty and Emergency Pet Care, Whippany, NJ, USA

³Kansas City Canine Orthopedics, Shawnee, KS, USA

Corresponding author:

Zoe Quirk DVM, Mobius Veterinary Services, Mobile Practice, NY, USA

Email: zoe.quirk@gmail.com



Creative Commons Non Commercial CC BY-NC: This article is distributed under the terms of the Creative Commons

Attribution-NonCommercial 4.0 License (<https://creativecommons.org/licenses/by-nc/4.0/>) which permits non-commercial use, reproduction and distribution of the work without further permission provided the original work is attributed as specified on the SAGE and Open Access pages (<https://us.sagepub.com/en-us/nam/open-access-at-sage>).

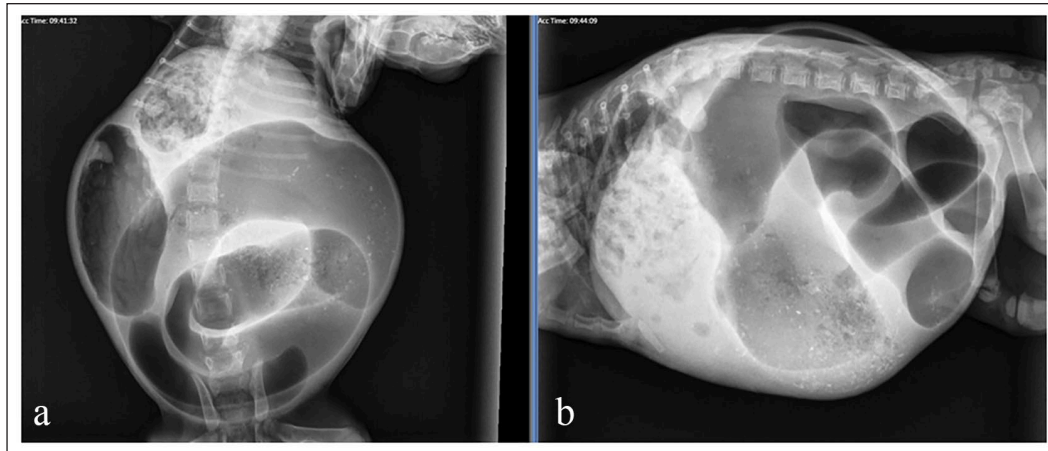


Figure 1 Ventrodorsal (a) and lateral (b) abdominal radiographs demonstrating marked gaseous dilation of the gastrointestinal tract

abdominal imaging abnormalities, mechanical obstruction was strongly suspected and patient care was transferred to the specialty hospital.

Physical examination at the referral hospital revealed hypothermia (35.6°C) and 5% dehydration. The abdomen was markedly distended and firm. Body condition score was 3/9 the patient weight was 0.52 kg. An intravenous (IV) catheter was placed and the patient started on fluid therapy (lactated Ringer's solution [LRS]) pending surgery.

General anesthesia was induced with fentanyl 0.003 mg/kg IV and midazolam 0.2 mg/kg IV, followed by alfaxalone IV to effect (total dose 4 mg/kg) facilitating endotracheal tube placement. Anesthesia was maintained with fentanyl continuous rate infusion (CRI) 0.005 mg/kg/h IV and isoflurane in oxygen at 1.5%. Routine abdominal clip and three-part preparation was performed. A standard ventral midline approach to the abdomen extending from xyphoid to pubis was made. Upon entry to the abdominal cavity, a severely dilated blind-ended sac was identified as the terminal ileum and cecum with no connection to the colon (Figure 2). Dilation of the intestinal tract extended orally into the distal jejunum. The terminal colon was identified by passing a 12-French red rubber catheter into the anus leading to a blind-ended colonic stump. The remaining abdominal organs appeared normal. To allow end-to-end anastomosis of similarly sized jejunum and colon, the dilated cecum, ileum and jejunum, and associated vasculature were resected using a vessel sealing device (Ligasure; Covidien). The colonic stump was transected and jejunocolic anastomosis completed using a simple interrupted pattern. A serosal patch was completed using three jejunal loops. Gloves and instruments were changed, the abdomen lavaged, then suctioned dry and closed in two layers. The patient was stable under anesthesia with routine recovery.

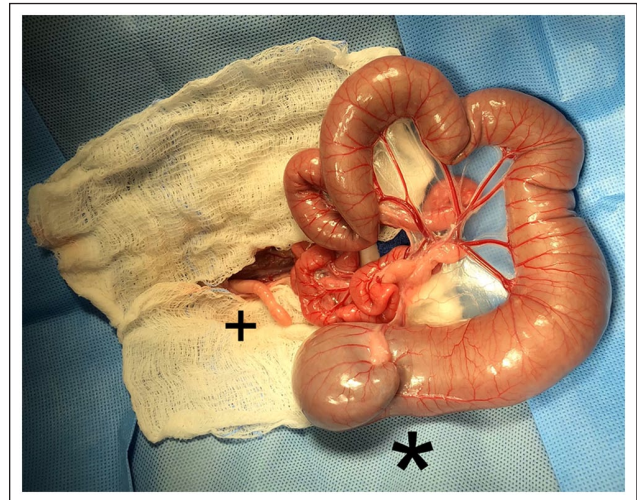


Figure 2 Intraoperative photo of the dilated distal jejunum, ileum and cecum terminating as a blind sac with no connection to the colon (*). The colonic stump is also seen (+)

The kitten was hospitalized in the intensive care unit on IV fluids (LRS) 140 ml/kg/day, ampicillin–sulbactam 30 mg/kg IV q8h, enrofloxacin 5 mg/kg IV q24h, famotidine 1 mg/kg IV q24h and fentanyl CRI 0.001 mg/kg/h IV. Antibiotic choices were due to colonic anastomosis involvement. Syringe feeding every 4h of 3 ml of urgent care diet (Hill's Prescription Diet a/d; Hill's Pet Nutrition, Inc.) was tolerated without vomiting or regurgitation. Vitamin B₁₂ supplementation 100 µg subcutaneous every 7 days was started due to ileectomy.

The patient's supportive therapy was de-escalated over the following 2 days. On postoperative day 3, the patient was eating approximately 25% of resting energy requirements with no vomiting and mild diarrhea, did not require IV fluids to maintain hydration and was tolerating oral amoxicillin–clavulanic acid. Enrofloxacin

was discontinued. Vitals were normal with a weight of 0.42 kg; weight loss from presentation was attributed to surgical removal of tissue and intestinal contents. The owner was eager for discharge and the kitten was released with amoxicillin–clavulanic acid 15 mg/kg PO q12h, metronidazole 12 mg/kg PO q12h (added due to ongoing diarrhea) and metoclopramide 0.2 mg/kg PO q8h as needed in case of nausea or inappetence from decreased gastrointestinal motility. The owner was instructed to monitor the kitten for vomiting, inappetence or behavior changes. Recheck evaluation was recommended in 1–2 days.

The owner reported the kitten was doing well the next day. The owner presented the kitten on postoperative day 6 for a recheck. The owner approximated the kitten was eating one-quarter of a can of a variety of kitten food daily. Supplemental syringe feedings of uncertain volume were also given. The kitten was defecating daily with consistency ranging from liquid to soft formed. Physical examination revealed 7–8% dehydration with a soft and non-painful abdomen. The kitten was hypothermic (37°C) and body weight was 0.31 kg, a decrease of 26% from discharge. Brief gastrointestinal ultrasound examination performed by a board-certified criticalist showed diffusely fluid-filled intestines with peristalsis. The owner elected to take the kitten home to monitor appetite carefully and supplement with syringe feeding if it was not eating at least one-quarter of a can of kitten food daily. Subcutaneous fluids (LRS) 30 ml/kg were given and amoxicillin–clavulanic acid stopped in case of any contribution to inappetence. Metronidazole and metoclopramide were continued.

The kitten returned the following day for weakness, anorexia and lack of defecation. The kitten was 5% dehydrated and dull. Body temperature was too low to read. Body weight was 0.34 kg. An abdominal-focused assessment with sonography for trauma (AFAST) scan was negative. An IV catheter was placed. Blood glucose was low (1.1 mmol/l; reference interval [RI] 4.4–9.4) and the patient became hyperglycemic (11.9 mmol/l) after dextrose bolus (1 ml of 50% dextrose IV diluted 1:1 with sterile 0.9% saline). Intravenous fluid therapy (LRS) with 5% dextrose at 150 ml/kg/day, metoclopramide CRI (1 mg/kg/day) and antibiotics (ampicillin–sulbactam 30 mg/kg IV q8h and enrofloxacin 5 mg/kg IV q24h) were started. The patient was provided heat support by forced air warmer (Bair Hugger; 3M) until body temperature exceeded 37.2°C. The initial improvements in the kitten's attitude and vitals were followed by signs of deterioration. Blood glucose was normal (7.9 mmol/l) but blood pressure was unobtainable. The patient was given IV fluid boluses (LRS) totaling 74 ml/kg over 1 h without improvement in hypotension; a norepinephrine (noradrenaline) CRI (0.5 µg/kg/min) was initiated with minimal response. Abdominal distension was noted and repeat AFAST showed gastric dilation but no

ascites. A 5-French nasogastric tube was placed with removal of 32 ml of brown fluid. An additional IV fluid bolus (10 ml/kg) was given with persistent hypotension. At that time, the owner requested euthanasia; however, necropsy was declined.

Discussion

Colonic atresia is a rare congenital deformity of the large intestine. No genetic cause, risk factors, sex predilection or breed predisposition in companion animals have been determined.^{3,7} Four anatomic types of intestinal atresia are described in animals based on human classifications in ascending order of severity: type I, membranous atresia, is a complete diaphragm or membrane in the intestine resulting in lack of patency; type II, cord atresia, is the absence of an intestinal segment with the blind ends joined by a small tissue cord; type III, blind-end atresia, is the absence of a segment of intestine with disconnected blind ends and a gap in the mesentery subdivided into type IIIa and IIIb based on the absence (IIIa) or presence (IIIb) of coiled atretic ends in an 'apple-peel' appearance; and type IV, multiple atresias.^{2,4} The kitten in this case had an absent segment of colon and mesentery without coiling of the atretic ends. Consequently, the deformity in this case was classified as type IIIa atresia.

Colonic atresia typically presents in neonatal animals. In retrospective and prospective studies of colonic atresia in cattle, calves presented between 1 and 10 days of age.^{1,2,4,7,8} Three kittens that died between 1 and 3 days of age were diagnosed with colonic atresia at necropsy in a retrospective study.⁷ These data suggest clinical signs associated with colonic atresia are usually present and severe in the first few days of life. This is contrary to the 6-week-old kitten described in this report and additional case reports of necropsy-diagnosed colonic atresia in a 9-week-old kitten¹² and a 7-week-old puppy.¹¹ In these postneonatal cases, the most profound clinical sign was abdominal distension. Smaller stature is also described where littermates were known. Colonic atresia should be a diagnostic consideration in similar cases.

In this case, the kitten initially did well after surgery and was discharged but then deteriorated with eventual euthanasia. There was no conclusive evidence of dehiscence of the jejunocolic anastomosis though this or other complication such as stricture cannot be ruled out because necropsy was not performed. The kitten's decline was suspected to be related to malnutrition, dehydration and intestinal bacterial translocation. In retrospect, adjustments to the patient's care may have resulted in a better outcome. The kitten's small size was a deterrent to frequent blood sampling that may have resulted in a delay in recognizing emerging decline. The owner also did not monitor the kitten as closely as expected and could only approximate the kitten's activities. While malnutrition resulting from a

shortened intestinal tract is possible, the kitten did not receive adequate nutrition throughout the postoperative period, with estimated caloric intake meeting about 30% resting energy requirements. While syringe-feeding calories were calculated, specific oral dietary offerings were not part of the kitten's treatments during hospitalization and contributed to incomplete caloric intake. Recommended oral nutritional intake of 90kcal/day was made at discharge but the volume of food needed to meet this goal varied based on the food offered. No specific food was recommended, which likely affected the compliance of the owner regarding when to initiate syringe feedings or to notify the hospital that the patient was not meeting caloric requirements. In addition, with ongoing gastrointestinal water losses owing to diarrhea, the patient's hydration requirements should have been calculated. Unfortunately, the degree of malnutrition was not realized until retrospective review. Continuation of syringe feedings or feeding tube placement would likely have helped ensure proper nutrition and hydration which may have resulted in improved outcome.

Conclusions

This report describes the presentation and ante-mortem diagnosis of type III colonic atresia with attempted surgical correction in a post-neonatal kitten not currently documented in veterinary medicine. While the outcome of this case was unfavorable, the short-term postoperative survival of this patient suggests type III colonic atresia may be treatable in cats with aggressive management. Colonic atresia should be considered as a differential diagnosis in young companion animals presenting primarily for abdominal distension and small stature because survival past the neonatal stage is possible contrary to most previously published reports.

Acknowledgements We thank Jack Hershey DVM, PhD for his assistance in preparing this manuscript.

Conflict of interest The authors declared no potential conflicts of interest with respect to the research, authorship, and/or publication of this article.

Funding The authors received no financial support for the research, authorship, and/or publication of this article.

Ethical approval The work described in this manuscript involved the use of non-experimental (owned or unowned)

animals. Established internationally recognized high standards ('best practice') of veterinary clinical care for the individual patient were always followed and/or this work involved the use of cadavers. Ethical approval from a committee was therefore not specifically required for publication in *JFMS Open Reports*. Although not required, where ethical approval was still obtained, it is stated in the manuscript.

Informed consent Informed consent (verbal or written) was obtained from the owner or legal custodian of all animal(s) described in this work (experimental or non-experimental animals, including cadavers) for all procedure(s) undertaken (prospective or retrospective studies). No animals or people are identifiable within this publication, and therefore additional informed consent for publication was not required.

ORCID iD Zoe Quirk  <https://orcid.org/0000-0002-1256-4191>

References

- 1 Dreyfuss DJ and Tulleners EP. **Intestinal atresia in calves: 22 cases (1978–1988)**. *J Am Vet Med Assoc* 1989; 195: 508–513.
- 2 Ducharme NG, Arighi M, Horney FD, et al. **Colonic atresia in cattle: a prospective study of 43 cases**. *Can Vet J* 1988; 29: 818–824.
- 3 Johnson R. **Intestinal atresia and stenosis: a review comparing its morphology**. *Vet Res Commun* 1986; 10: 105–111.
- 4 Kiliç N and Sarierler M. **Congenital intestinal atresia in calves: 61 cases (1999–2003)**. *Revue Méd Vét* 2004; 155: 381–384.
- 5 Knecht I, Pinn-Woodcock T, Craven A, et al. **Atresia coli in a 1-day-old cria**. *Vet Rec Case Rep* 2021; 9. DOI: 10.1002/vrc2.148.
- 6 Poulsen KP, Elce YA, Frederico LM, et al. **Atresia coli in an alpaca cria**. *Vet Rec* 2006; 158: 598–599.
- 7 Van der Gaag I and Tibboel D. **Intestinal atresia and stenosis in animals: a report of 34 cases**. *Vet Pathol* 1980; 17: 565–574.
- 8 Azizi S, Mohammadi R and Mohammadpour I. **Surgical repair and management of congenital intestinal atresia in 68 calves**. *Vet Surg* 2010; 39: 115–120.
- 9 Constable PD, Huhn JC, Morin DE, et al. **Atresia coli in calves: etiopathogenesis and surgical management**. *Bov Pract* 1999; 33: 70–73.
- 10 Constable PD, Rings DM, Hull BL, et al. **Atresia coli in calves: 26 cases (1977–1987)**. *J Am Vet Med Assoc* 1989; 195: 118–123.
- 11 Mullen HS. **Atresia of the colon in a 52-day-old puppy**. *Vet Med Small Anim Clin* 1982; 77: 1621–1624.
- 12 Bredal WP, Thoresen SI and Kvellestad A. **Atresia coli in a nine-week-old kitten**. *J Smal Anim Pract* 1994; 35: 643–645.