



## **Limb sparing in a cat with a humeral osteosarcoma using a customised three-dimensional printed endoprosthesis**

Authors: Malak, Anthony, Parr, William CH, Levien, Andrew S, and Basa, Rachel M

Source: Journal of Feline Medicine and Surgery Open Reports, 9(2)

Published By: SAGE Publishing

URL: <https://doi.org/10.1177/20551169231199445>

---

BioOne Complete ([complete.BioOne.org](https://complete.BioOne.org)) is a full-text database of 200 subscribed and open-access titles in the biological, ecological, and environmental sciences published by nonprofit societies, associations, museums, institutions, and presses.

Your use of this PDF, the BioOne Complete website, and all posted and associated content indicates your acceptance of BioOne's Terms of Use, available at [www.bioone.org/terms-of-use](https://www.bioone.org/terms-of-use).

Usage of BioOne Complete content is strictly limited to personal, educational, and non - commercial use. Commercial inquiries or rights and permissions requests should be directed to the individual publisher as copyright holder.

---

BioOne sees sustainable scholarly publishing as an inherently collaborative enterprise connecting authors, nonprofit publishers, academic institutions, research libraries, and research funders in the common goal of maximizing access to critical research.



# Limb sparing in a cat with a humeral osteosarcoma using a customised three-dimensional printed endoprosthesis

*Journal of Feline Medicine and Surgery Open Reports*  
1–6

© The Author(s) 2023

Article reuse guidelines:

sagepub.com/journals-permissions

DOI: 10.1177/20551169231199445

journals.sagepub.com/home/jfmsopenreports

This paper was handled and processed by the European Editorial Office (ISFM) for publication in *JFMS Open Reports*



Anthony Malak<sup>1</sup> , William CH Parr<sup>2</sup>,  
Andrew S Levien<sup>1</sup> and Rachel M Basa<sup>1,3</sup>

## Abstract

**Case summary** A 12-year-old male neutered Bengal cat presented for a left thoracic limb lameness of several weeks' duration. Abnormal advanced imaging findings depicted the presence of an irregularly margined osteolytic lesion in the proximal-mid diaphysis of the left humerus. A histopathological evaluation of the humerus confirmed a diagnosis of osteoblastic osteosarcoma. Limb-sparing surgery was planned with a custom-designed three-dimensional printed endoprosthesis. Mild neuropraxia was noted immediately postoperatively and deemed to have resolved by the 2-week follow-up. Stereotactic radiation was planned, though pulmonary metastasis was noted on planning CT. The cat was euthanased 90 days postoperatively owing to the development of pulmonary clinical signs.

**Relevance and novel information** This is the first reported case of a humeral limb salvage procedure in a cat using a custom-designed three-dimensional printed endoprosthesis. Although the survival time in this case was short, the patient maintained an adequate quality of life and limb function was preserved.

**Keywords:** Osteosarcoma; limb sparing; prosthesis; humerus

**Accepted:** 19 August 2023

## Introduction

Feline osteosarcoma is rare, accounting for 0.5% of all feline tumours.<sup>1</sup> Osteosarcoma in cats usually affects older cats (aged 8–10 years), although it has been observed in younger cats (aged 1–20 years).<sup>2</sup> Feline osteosarcoma is usually less aggressive and carries a more favourable prognosis than canine osteosarcoma.<sup>3</sup>

Limb amputation is considered the gold standard of care for the treatment of bone and joint neoplasia in small animals.<sup>4</sup> Although cats tolerate limb amputation well, recent methods of limb salvage have allowed for preservation of the affected limb without complete amputation. One method that was recently reported in two cats is the use of a custom-designed femoral endoprosthesis with an integrated total knee replacement for the treatment of osteosarcoma, which yielded good results.<sup>5</sup>

This case report describes the novel use of a three-dimensional printed patient-specific humeral endoprosthesis in a cat with osteosarcoma as a limb-sparing technique.

<sup>1</sup>Veterinary Specialists of Sydney, Miranda, NSW, Australia

<sup>2</sup>Surgical and Orthopaedic Research Laboratories, Prince of Wales Clinical School, University of New South Wales, Randwick, NSW, Australia

<sup>3</sup>Sydney School of Veterinary Science, Faculty of Science, University of Sydney, Sydney, NSW, Australia

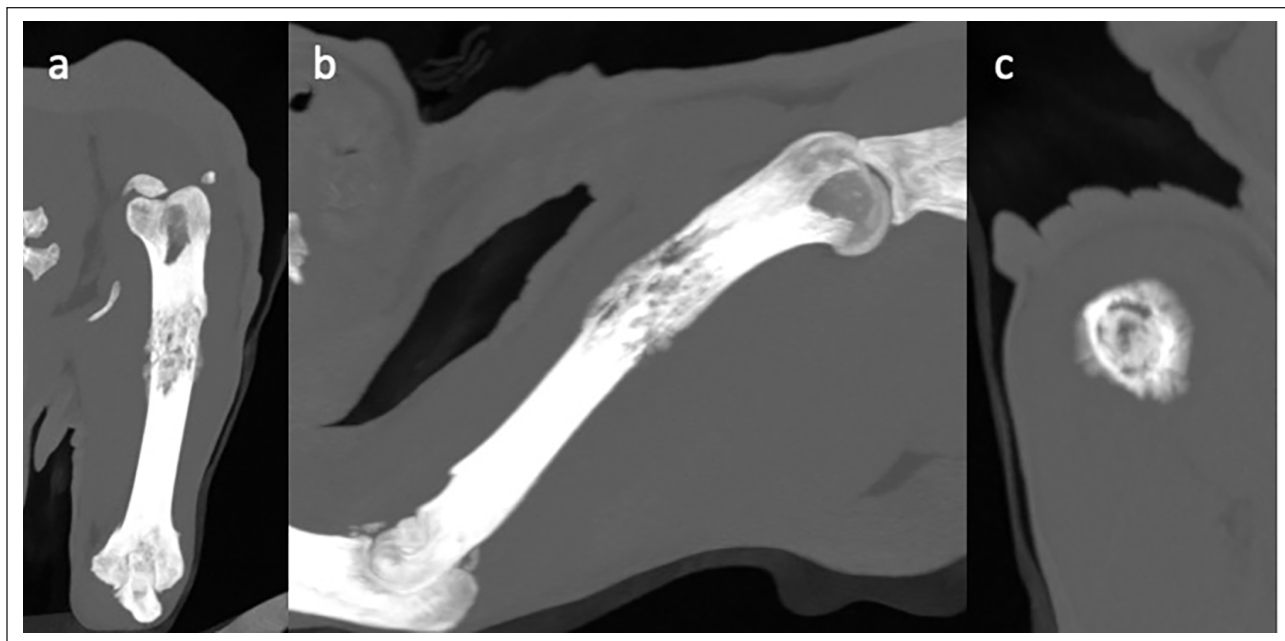### Corresponding author:

Anthony Malak BVSc, Veterinary Specialists of Sydney, 106 Parraweena Road, Miranda, NSW 2228, Australia  
Email: anthony.malak@vsos.com.au



Creative Commons Non Commercial CC BY-NC: This article is distributed under the terms of the Creative Commons

Attribution-NonCommercial 4.0 License (<https://creativecommons.org/licenses/by-nc/4.0/>) which permits non-commercial use, reproduction and distribution of the work without further permission provided the original work is attributed as specified on the SAGE and Open Access pages (<https://us.sagepub.com/en-us/nam/open-access-at-sage>).



**Figure 1** CT image showing osteolytic lesion of the mid-proximal humerus, multiplanar reconstruction: (a) frontal plane depicting proximal humeral osteolytic lesion; (b) sagittal plane; and (c) transverse plane at the centre of the humeral lesion demonstrating mixed bone lysis and periosteal proliferation

### Case description

A 12-year-old male neutered Bengal cat presented to its primary care veterinarian for a left thoracic limb lameness of several weeks' duration. Whole-body CT (SOMATOM go.Up [64-slice]; Siemens Healthcare) depicted the presence of an irregularly marginated osteolytic lesion in the proximal-mid diaphysis of the left humerus. Mild left axillary lymphadenomegaly was also observed. The case was referred to a specialist surgery service for bone biopsies and confirmation of advanced imaging findings (Figure 1). A Jamshidi bone biopsy sample was obtained from the osteolytic lesion in the proximal humerus, and histopathology confirmed a diagnosis of osteoblastic osteosarcoma. The owners were informed of the nature of the disease and options available. They opted for limb-sparing ostectomy and endoprosthetic placement followed by adjuvant stereotactic body radiation therapy.

Orthogonal radiographs (MOBILETT Elara Max; Siemens Healthcare) were performed. A custom three-dimensional printed cutting guide and prosthesis were designed and printed based on these images in conjunction with the original CT images (3D Morphic). The cutting guide was created to allow for a 10 mm surgical margin of tomographically normal bone proximal and distal to the tumour as assessed by CT. The endoprosthesis was an interbody device made with titanium (Ti6Al4V alloy specifications according to ASTM F1472 and F2924) that was printed with contours of the patient's contralateral humerus, and both proximal and

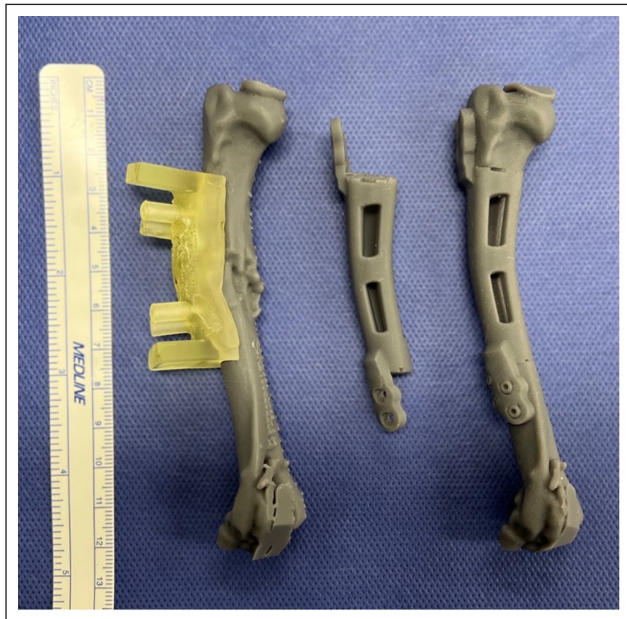distal plate flanges that would accept five 2 mm locking stainless-steel screws proximally and four 2 mm locking stainless-steel screws distally. This was designed by a biochemical engineer (WP) at 3DMorphic using 3DMCAD (3DMorphic's in-house software). The interbody portion of the device was designed to fit within the humerus once the tumour and affected bone were resected, with the amount of bone resection specified by the lead surgeon (RB). The overall curvature of the interbody portion of the device was designed from the contralateral 'normal' humerus. The interbody region of the implant featured a graft window. Fusion occurs when the biomechanical environment is suitable. This means that the construct needs stability and to limit motion, which is why the plate regions of the implant featured locking screws (Figure 2). Bone models of the humerus were created to enable contouring of an orthogonal plate before surgery.

Premedication intraoperative antibiotics consisted of three doses of cephazolin sodium (Cefazolin; Hospira; 22 mg/kg IV) every 90 mins.

A standardised anaesthetic protocol was used, including premedication, which involved dexmedetomidine hydrochloride (Dexdomitor; Zoetis Australia; 5 µg/kg IM) and methadone (Methone; Ceva Animal Health; 0.2 mg/kg IM), induction with propofol (Propofol-Lipuro; B Braun Melsungen; 2–4 mg/kg IV) and maintenance with isoflurane in 100% oxygen delivered via an endotracheal tube. Anaesthetic monitoring

included end-titrate carbon dioxide, indirect Doppler blood pressure, pulse oximetry and electrocardiography. Hartmann's solution was administered (5–10 ml/kg/h IV) to maintain haemodynamic status. Body temperature was monitored and maintained with a warm air blanket. For surgery, cefazolin (22 mg/kg IV) was administered at induction and every 120 mins perioperatively.

The patient was positioned in lateral recumbency and a lateral approach was first made to the wing of the ilium. A

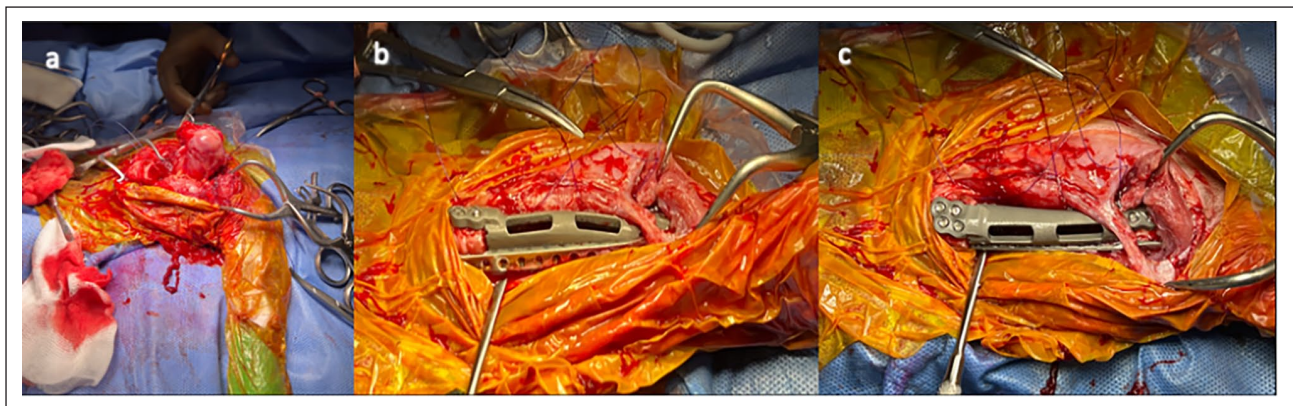


**Figure 2** Three-dimensional printed bone models used to assist with surgical planning. Left: bone cutting guide affixed to the humerus with tumour. Centre: endoprosthesis. Right: three-dimensional printed endoprosthesis applied to the humerus after ostectomy of the humeral osteosarcoma

corticocancellous graft was harvested using a size 18 acetabular reamer (BFX; Biomedtrix). Next, a lateral approach was made to the humerus.<sup>6</sup> The radial nerve was identified and preserved by caudal retraction. The tumour was excised with a 1 cm margin of normal-looking bone. Soft tissue was dissected away from the tumour capsule, which remained intact and the osteotomised bone was removed. The endoprosthesis was fitted into the bone defect, ensuring the plate flanges fit on the predetermined surface of the bone, and 2.0 mm locking screws were inserted both proximally and distally through the flanges. A pre-contoured 2.0 mm locking compression plate was then applied to the cranial surface of the bone and two locking screws were inserted both proximally and distally. Both the autologous bone graft and ixobone paste (Ixobone; Exabone GmbH) were packed into spaces of the endoprosthesis and the bone-implant interface after having lavaged the site with 2 l of saline. Closure was routine, with the fascia and subcutaneous layer over the implants closed using 3/0 Polydioxanone (DemeDIOX) and the skin in 4/0 Nylon (DemeLON; DemeTech) (Figures 3 and 4).

Postoperatively, medication included amoxicillin and clavulanic acid (Clavulox; Zoetis Australia; 20 mg/kg IV), meloxicam (Apex Meloxicam 0.5 mg/ml Oral Suspension For Cats; Dechra Veterinary Products (Australia); 0.05 mg/kg PO) and gabapentin (Gabapentin; BOVA AUS; 10 mg/kg PO). Postoperative analgesia included methadone (Methone; Ceva Animal Health; 0.2 mg/kg IV). The cat recovered from the anaesthesia uneventfully and was monitored overnight until its normal eating habits returned. Postoperatively, the patient developed a grade 1 complication, which was moderate radial neuropraxia that was noted to resolve by the 2-week follow-up.<sup>7</sup>

The patient re-presented 5 days postoperatively with a separate grade 1 complication<sup>7</sup> owing to an acute onset of left pelvic lameness. Radiographs were performed



**Figure 3** (a) Intraoperative image depicting removal of the humeral osteosarcoma after bone-guide assisted ostectomy; (b, c) lateral view of the left humerus; intraoperative images after implantation of the three-dimensional printed endoprosthesis and 2.0 locking compression plate

and a left iliac wing fracture was diagnosed owing to corticomedullary bone harvest for autologous graft, although no further treatment was required. The patient recovered from this lameness within 2 weeks.

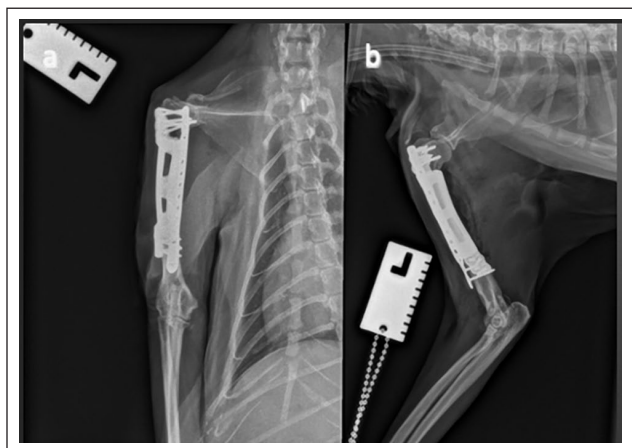
Histopathology testing confirmed that the lesion was an osteoblastic osteosarcoma with clean margins proximally and distally and a mitotic count of 24. The patient was referred to a radiation oncologist for stereotactic

radiation therapy 5 weeks after surgery. The radiation oncologist reported adequate limb function on the operated leg when compared with the contralateral limb and grade 2/5 lameness. During pre-radiation planning, pulmonary metastasis was observed on CT. The clients elected to proceed with palliative therapy instead of radiation. This patient deteriorated with respiratory signs and was euthanased 90 days postoperatively. A post-mortem CT was performed, which showed there was evidence of new bone formation at the implant–bone interface (Figure 5).

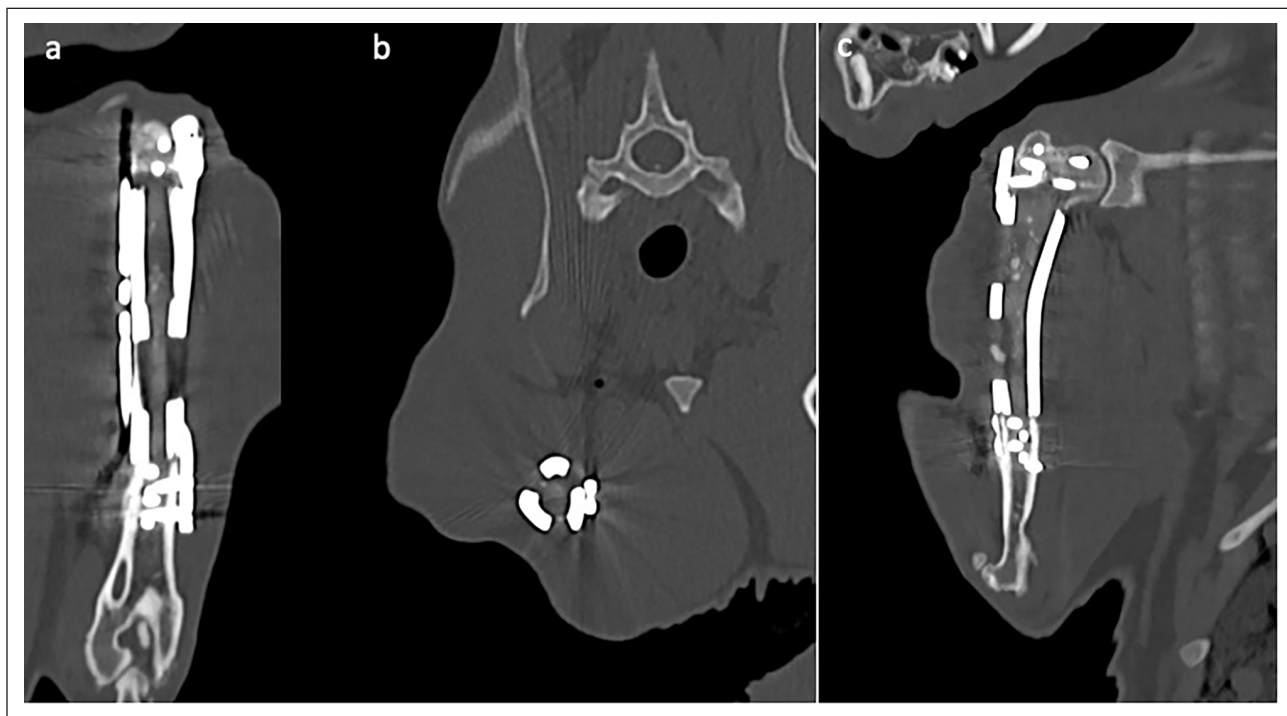
## Discussion

This case report demonstrates the use of a humeral endoprosthesis in a cat. The cat had subjectively good use of the affected forelimb; however, it later succumbed to metastatic disease. Although osteosarcoma in cats has previously been reported to have a better prognosis than in dogs, recent evidence suggests that there is a high rate of distant metastasis (40%).<sup>3</sup>

The recommended treatment for feline osteosarcoma tends to be limb amputation alone, and there is open debate on whether adjuvant therapy will prolong survival times.<sup>5</sup> In one study of cats after limb amputation, most cats returned to a normal quality of life; however, there were reduced levels of activity and speed in approximately 50% of cats with amputated limbs.<sup>4</sup>



**Figure 4** Immediate postoperative radiographs in (a) craniocaudal and (b) lateral views depicting appropriate implant positioning and limb alignment



**Figure 5** Multiplanar reconstruction of the CT images collected post mortem. There are hyperattenuating regions within the interstices of the implant. CT images in (a) transverse; (b) dorsal; and (c) sagittal planes.

Limb-sparing surgeries have previously been reported in two cats using a femoral endoprosthesis with an integrated total knee replacement with subjectively good outcomes.<sup>5</sup> Although the use of a humeral endoprosthesis has been reported as a treatment strategy for canine humeral osteosarcoma, it has not yet been described in cats. In the previous canine study, a frozen canine allograft was used; however, there was a high rate of implant-associated complications that deemed the outcome to be unacceptable.<sup>8</sup>

The benefit of patient-specific implants is that they are designed to have a perfect fit with the recipient bone that allows for optimised load transmission through the limb. One of the disadvantages is the delay from diagnosis to implant design and production, which can result in tumour progression. In this particular case, the delay was 14 days, which was considered to be reasonable in a previous study.<sup>9</sup> Although extensive preoperative planning was required in this case, surgical time was optimised with the use of a custom three-dimensional printed cutting guide assisting in the maintenance of anatomic alignment during osteotomy of the humerus and bone models, allowing for a locking plate to be pre-contoured before surgery.

The centre column of the implant was designed such that an autologous bone graft could be harvested and embedded within it, allowing for true osseointegration within the humerus as it heals. The surface was roughened to allow for the ingrowth of bone similar to that seen in other osseointegration designs.<sup>10</sup> On post-mortem CT, there was evidence of new bone formation within the cage of the prosthesis; however, further studies with histopathology of cement-embedded specimens would be required to confirm this finding.

There are no guidelines regarding how much bone can be safely resected to reduce the risk of implant failure; however, there needs to be enough bone stock proximal and distal to the osteotomy to ensure that the endoprosthesis can be adequately fixed to the bone. With this in mind, not every cat will be a candidate for a patient-specific endoprosthesis once surgical margins are accounted for. The authors would also have reservations in recommending an endoprosthesis to manage osteosarcoma of the feline humerus, given the poor outcome despite the appropriate preoperative staging of this case; however, it may be suitable for patients with other osteolytic disease, such as osteodestructive bone cysts, fibrosarcoma, chondrosarcoma, trauma or necrosis.

## Conclusions

This case report highlights the use of a custom three-dimensional printed humeral endoprosthesis as a limb-sparing technique for the treatment of osteosarcoma in a

cat. Although the survival time of the cat was short, the quality of life, adequate limb function and improved pain control were notable after the surgery. Further prospective studies with larger case numbers and longer follow-up are required to assess the feasibility and success of patient-specific implants in cats as a limb salvage procedure.

**Acknowledgements** The authors would like to thank Dr David Lurie for his continued input and advice on the oncologic management of this case. They would also like to thank the Giffin family for providing consent to publish the details of Simba's surgery and follow-up.

**Conflict of interest** WCHP is the co-founder of 3D Morphic Pty Ltd.

**Funding** The authors received no financial support for the research, authorship, and/or publication of this article.

**Ethical approval** The work described in this manuscript involved the use of non-experimental (owned or unowned) animals. Established internationally recognised high standards ('best practice') of veterinary clinical care for the individual patient were always followed and/or this work involved the use of cadavers. Ethical approval from a committee was therefore not specifically required for publication in *JFMS Open Reports*. Although not required, where ethical approval was still obtained it is stated in the manuscript.

**Informed consent** Informed consent (verbal or written) was obtained from the owner or legal custodian of all animal(s) described in this work (experimental or non-experimental animals, including cadavers) for all procedure(s) undertaken (prospective or retrospective studies). For any animals or people individually identifiable within this publication, informed consent (verbal or written) for their use in the publication was obtained from the people involved.

**ORCID iD** Anthony Malak  <https://orcid.org/0009-0009-4167-0290>

Rachel M Basa  <https://orcid.org/0000-0002-9599-3054>

## References

- 1 Heldmann E, Anderson M and Wagner-Mann C. **Feline osteosarcoma: 145 cases (1990–1995)**. *J Am Anim Hosp Assoc* 2000; 36: 518–521.
- 2 Bitetto WV, Patnaik AK, Schrader SC, et al. **Osteosarcoma in cats: 22 cases (1974–1984)**. *J Am Vet Med Assoc* 1987; 190: 91–93.
- 3 Nakano Y, Kagawa Y, Shimoyama Y, et al. **Outcome of appendicular or scapular osteosarcoma treated by limb amputation in cats: 67 cases (1997–2018)**. *J Am Vet Med Assoc* 2022; 260 Suppl 1: S24–S28.
- 4 Forster LM, Wathes CM, Bessant C, et al. **Owners' observations of domestic cats after limb amputation**. *Vet Rec* 2010; 167: 734–739.

- 5 Kvale E, Rueda RC and Fitzpatrick N. **Limb-sparing surgery in two cats using a femoral endoprosthesis with an integrated total knee replacement implant.** *Vet Comp Orthop Traumatol* 2022; 35: 134–142.
- 6 Johnson KA. Piermattei's atlas of surgical approaches to the bones and joints of the dog and cat. 5th ed. Missouri: Elsevier, 2014.
- 7 Dindo D, Demartines N and Clavien PA. **Classification of surgical complications: a new proposal with evaluation in a cohort of 6336 patients and results of a survey.** *Ann Surg* 2004; 240: 205–213.
- 8 Kuntz CA, Asselin TL, Dernell WS, et al. **Limb salvage surgery for osteosarcoma of the proximal humerus: outcome in 17 dogs.** *Vet Surg* 1998; 27: 417–422.
- 9 Timercan A, Brailovski V, Petit Y, et al. **Personalized 3D-printed endoprostheses for limb sparing in dogs: modeling and in vitro testing.** *Med Eng Phys* 2019; 71: 17–29.
- 10 Hoellwarth JS, Tetsworth K, Akhtar MA, et al. **The clinical history and basic science origins of transcutaneous osseointegration for amputees.** *Adv Orthop* 2022; 2022: 1–14.